

Generalized Joint Hypermobility Is Predictive of Hip Capsular Thickness

Brian M. Devitt,^{*†} MD, FRCS, FRACS, Bjorn N. Smith,[†] FRACS, Robert Stapf,[†] MD, Mark Tacey,[‡] MBIostat, BSc, and John M. O'Donnell,[†] FRACS

Investigation performed at Bellbird Private Hospital, Blackburn, Victoria, Australia

Background: The pathomechanics of hip microinstability are not clearly defined but are thought to involve anatomical abnormalities, repetitive forces across the hip, and ligamentous laxity.

Purpose/Hypothesis: The purpose of this study was to explore the relationship between generalized joint hypermobility (GJH) and hip capsular thickness. The hypothesis was that GJH would be predictive of a thin hip capsule.

Study Design: Cross-sectional study; Level of evidence, 3.

Methods: A prospective study was performed on 100 consecutive patients undergoing primary hip arthroscopy for the treatment of hip pain. A Beighton test score (BTS) was obtained prior to each procedure. The maximum score was 9, and a score of ≥ 4 was defined as hypermobile. Capsular thickness at the level of the anterior portal, corresponding to the location of the iliofemoral ligament, was measured arthroscopically using a calibrated probe. The presence of ligamentum teres (LT) pathology was also recorded.

Results: Fifty-five women and 45 men were included in the study. The mean age was 32 years (range, 18-45 years). The median hip capsule thickness was statistically greater in men than women (12.5 and 7.5 mm, respectively). The median BTS for men was 1 compared with 4 for women ($P < .001$). A statistically significant association was found between BTS and capsular thickness; a BTS of < 4 is strongly predictive of having a capsular thickness of ≥ 10 mm, while a BTS ≥ 4 correlates with a capsular thickness of < 10 mm. There was a statistically greater incidence of LT tears in patients with a capsular thickness of ≤ 7.5 mm and a BTS of ≥ 4 ($P < .001$).

Conclusion: Measurement of the GJH is highly predictive of hip capsular thickness. A BTS of < 4 correlates significantly with a capsular thickness of ≥ 10 mm, while a BTS ≥ 4 correlates significantly with a thickness of < 10 mm.

Keywords: generalized joint hypermobility; hip arthroscopy; capsular thickness; microinstability

The capsule of the hip assumes an important role in normal hip function and kinematics.²⁷ A key static constraint through a wide range of physiological motion, the hip capsule is comprised of 4 capsular ligaments linked together by fibrous connective tissue: the iliofemoral, pubofemoral, ischiofemoral, and zona orbicularis.^{13,16,27,39} Of these structures, the iliofemoral ligament (IFL) has been recognized as the primary stabilizing structure for controlling anterior translation and external rotation of the hip.²⁴ In order to

achieve arthroscopic exposure of the hip and facilitate surgical intervention, capsulotomies and capsulectomies are routinely performed as part of the arthroscopic procedure.^{9,31,35} The location of the IFL on the anterior aspect of the capsule renders it susceptible to violation at the time of arthroscopic interportal capsulotomy.³⁰ Therefore, it has been postulated that failure to repair the capsule in this region after hip arthroscopy may contribute to iatrogenic instability in certain patients.¹³

The notion of microinstability of the hip is a relatively recent concept but one that is gaining increased acceptance.^{26,37} An improved understanding of the factors that contribute to microinstability has helped in identifying “at-risk” patients, in whom a capsular repair should be considered after hip arthroscopy to achieve optimal results and avoid iatrogenic instability (dislocation or microinstability).²⁷ Despite a paucity of conclusive evidence-based indications, experts have recommended capsular repair in the settings of borderline hip dysplasia, hip hypermobility, connective tissue disorders, and traumatic or atraumatic instability. Although some of these “at-risk” patients are

*Address correspondence to Brian M. Devitt, MD, FRCS, FRACS, OrthoSport Victoria, 89 Bridge Road, Richmond, Victoria 3121, Australia (email: bdevitt@hotmail.com).

[†]Hip Arthroscopy Australia, Richmond, Victoria, Australia.

[‡]Department of Epidemiology and Preventative Medicine, Monash University, The Alfred Centre, Melbourne, Victoria, Australia.

The authors declared that they have no conflicts of interest in the authorship and publication of this contribution.

Ethical approval for this study was waived by Bellbird Private Hospital.

relatively easy to identify, others present a diagnostic challenge pre- and intraoperatively, particularly in the context of hip hypermobility.

Generalized joint hypermobility (GJH) is a relatively common condition in healthy populations, with an overall prevalence of 26.2%.³⁴ Interestingly, Naal et al²⁵ reported that the prevalence of GJH was even higher in patients with femoroacetabular impingement (32.7%), as measured by the Beighton test score (BTS).⁵ Although this information is potentially useful in forewarning the clinician about those patients who may be susceptible to hip hypermobility, there is currently no information on how GJH relates to the thickness of the hip capsule. An appreciation of hip capsule thickness at the time of hip arthroscopy may have a bearing on those patients who warrant capsular repair compared with those who may not. To date, there are limited data on normative values for hip capsular thickness, which is limited to cadaveric and radiological studies.^{20,30,41,43}

Therefore, the aim of this study was to explore the relationship between GJH and hip capsular thickness measured intraoperatively at hip arthroscopy. The hypothesis was that GJH would be predictive of a thin hip capsule. A secondary aim was to investigate the relationship between hip dysplasia and ligamentum teres (LT) pathology with GJH and capsular thickness.

METHODS

Between February 2015 and June 2015, a prospective study was carried out on 100 consecutive patients presenting for primary hip arthroscopy. The study was carried out in accordance with the institutional ethical review board. The inclusion criteria were patients between the ages of 18 and 45 years undergoing primary hip arthroscopy for any condition. Exclusion criteria included patients who had prior hip surgery of any kind, radiographic evidence of osteoarthritis (Kellgren-Lawrence grade 2 or greater¹⁸ or joint space narrowing <2 mm), gross morphological changes to the hip, Marfan syndrome, Ehlers-Danlos syndrome, avascular necrosis of the hip, or oncological conditions affecting the hip.

Beighton Test Score

Joint hypermobility was evaluated in each patient by an independent examiner prior to surgery using the BTS.⁵ The BTS is an ordinal scale with a maximum score of 9. A score of ≥ 4 was defined as hypermobility. One point was given for each positive result on each side: passive hyperextension of the fifth metacarpophalangeal joint (MCPJ) ($>90^\circ$), thumb touching the volar aspect of the forearm, active hyperextension of the elbow ($>10^\circ$), active hyperextension of the knee ($>10^\circ$), and placing hands flat on the floor with straight legs.

Arthroscopic Assessment of Capsular Thickness

An experienced hip arthroscopist, blinded to the result of the BTS, performed all hip arthroscopies. The surgeries were performed in the lateral decubitus position. With the hip under traction, a lateral viewing portal was placed

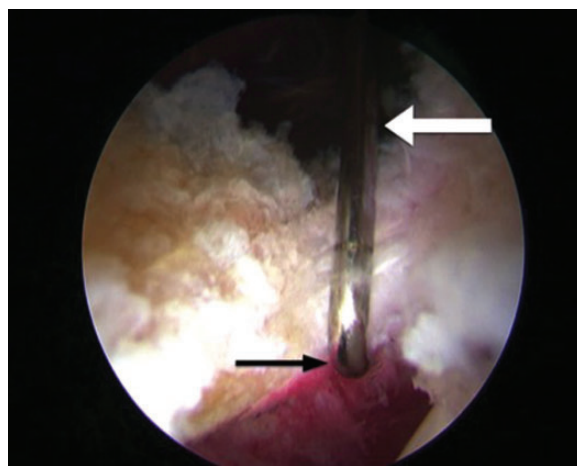


Figure 1. Arthroscopic image of measurement of hip capsular thickness using a calibrated arthroscopic probe. White arrow, the 10-mm calibration laser line; black arrow, probe hooked onto the inner aspect of the hip capsule perpendicular to the capsulotomy.

immediately superior to the midpoint of the tip of the greater trochanter, and a mid-anterior working portal was placed 2 cm anterior to the anterior margin of the greater trochanter. The position of the mid-anterior portal was confirmed arthroscopically with a needle prior to dilatation. The position on the mid-anterior portal was consistent in all cases; it was always superior and posterior to the psoas-U and corresponded to the 2 o'clock position on the clockface, as defined by Philippon et al.²⁹ An interportal capsulotomy was made using an electrocautery device (Super MultiVac 50; ArthroCare) when performing an acetabular osteotomy, femoral osteotomy, and labral repair/reconstruction. In cases requiring minimal intervention (eg, treatment of LT pathology), not requiring labral repair or femoral osteoplasty, a portal capsulotomy alone was used. An arthroscopic hook probe (3-mm; Smith & Nephew) calibrated with 5-mm laser etching was used to measure the capsular thickness. The hook was placed on the internal surface of the capsule at the most extreme anterior margin of the capsulotomy (Figure 1), which corresponded with the location of the IFL. To avoid overestimating the thickness of the capsule, all extra-articular soft tissue was cleared from the capsule at this point and care was taken to hold the probe vertically and not obliquely across the capsule. In cases where a portal capsulotomy was made, if the calibrations could not be viewed from within the joint, the camera was introduced extra-articularly to obtain an accurate reading. The capsular measurement was taken immediately after diagnostic arthroscopy in all cases (within 5 minutes of the commencement of the procedure) to ensure that there was no capsular swelling due to extravasation of fluid, which may have given a false reading. Given that the probes were marked with only 5-mm calibrations, if the thickness of the capsule fell between these marks, the surgeon made a best-estimate reading to the closest millimeter (Figure 1). A photograph of each measurement was taken.

Radiographic Analysis

The center-edge angle (CEA) was measured from supine anteroposterior pelvis radiographs. The CEA was formed by the intersection of the vertical line through the center of the femoral head with the line extending to the lateral edge of the sourcil² (Figure 2).

Statistical Analysis

The descriptive results are presented as both mean \pm SD and median and interquartile range, with Mann-Whitney (rank-sum) or Kruskal-Wallis tests applied to test for differences in these continuous variables across groups. Categorical variables, including dichotomized capsular thickness, were assessed using the chi-square test or the Fisher exact test on occasions when counts were fewer than 5 for any group. Statistical analyses were performed using Stata, version 12.1 (StataCorp), with a 2-sided alpha value of less than 0.05 assumed to indicate statistical significance.

RESULTS

Demographics

The mean age of the patients included in this study was 32 years (range, 18-45 years). Of the 100 patients, there were 55 women and 45 men. Right hip arthroscopy was carried out in 54 cases and left hip in 46 cases. LT pathology was noted in 63 cases. There were no cases of hip dysplasia ($CEA < 21^\circ$). However, 9 cases were considered to have borderline hip dysplasia (CEA range, 21° - 25°), while the rest had no dysplasia.

Capsular Thickness

Male patients had a significantly thicker capsule than female patients, with a median thickness of 12.5 and 7.5 mm, respectively ($P < .001$) (Table 1). In female patients, 67.3% of patients had a capsular thickness of ≤ 7.5 mm, with the rest being > 7.5 mm ($P < .001$). In contrast, 88.9% of male patients had a capsular thickness of > 7.5 mm.

No significant association was found between capsular thickness, age, or hip laterality. Patients without LT tears had a significantly thicker capsule compared with those with a pathological tear, with median values of 12.5 and 7.5 mm, respectively ($P < .001$). Of the 37 patients without an LT tear, 94.6% ($n = 35$) had a capsular thickness of > 7.5 mm, while 63.5% of patient with a tear had values ≤ 7.5 mm ($P < .001$).

Finally, patients identified as having a CEA of $> 25^\circ$ were found to have significantly thicker capsules than those with borderline dysplasia, with median values of 10.0 and 7.5 mm, respectively ($P = .022$). It is important to note that only 9 patients were considered to have borderline dysplasia.

Beighton Test Score

A significant difference was found between the BTS of men and women. The median BTS for men was 1 versus 4 for

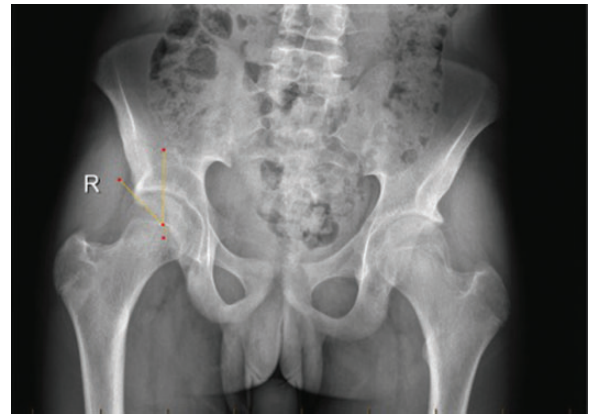


Figure 2. Measurement of the center-edge angle on anterior-posterior pelvis radiograph. The yellow lines depict the angle subtended between a vertical line through the center of the femoral head and a line extending to the lateral edge of the sourcil. R, right.

women ($P < .001$) (Table 2). There was no significant difference between age ($P = .392$) and laterality ($P = .440$) of the hip with respect to BTS. Patients with LT tears had a significantly higher median BTS than those without a tear (4 and 0, respectively; $P < .001$). Also, patients with a capsular thickness of ≤ 7.5 mm had a significantly higher median BTS than those with a capsule of > 7.5 mm (5 and 0, respectively; $P < .001$). Borderline dysplastic patients were also discovered to have a significantly higher median BTS than patients without dysplasia (6 versus 2, respectively; $P = .014$).

Association Between Beighton Test Score and Capsular Thickness

Figure 3 demonstrates the associations between BTS and capsular thickness, when considering binary thresholds of ≥ 4 for BTS and ≥ 10 mm for capsular thickness ($P < .001$). That is, one can confidently predict that a patient with a BTS of < 4 will have a capsular thickness of ≥ 10 mm, while a patient with a BTS ≥ 4 will have a capsular thickness of < 10 mm. The predictive value is also independent of sex. Although only 5 of the 45 male patients included in this study had a BTS of ≥ 4 , each of them was found to have a capsular thickness of < 10 mm.

Components of the Beighton Test Score

With a thin capsule being defined as being ≤ 7.5 mm, positive testing of hypermobility at the MCPJ, elbows, and knees and hands flat on the floor was significantly associated with a thin capsule (Table 3). A positive hyperextension test at the thumb was not significantly related to a thin capsule ($P = .056$). The predictive performance of elbow and knee hyperextension was particularly high ($P < .001$), with hands flat on the floor ($P = .007$) and MCPJ hyperextension ($P = .008$) also showing strong associations with capsular thickness.

TABLE 1
Relationship Between Capsular Thickness and Patient Variables^a

Variable	Capsular Thickness			P Value	Capsular Thickness, n (%)		P Value
	Count	Mean (SD)	Median (IQR)		>7.5 mm	≤7.5 mm	
Sex				<.001			<.001
Female	55	7.8 (2.8)	7.5 (5-10)		18 (32.7)	37 (67.3)	
Male	45	12.5 (2.7)	12.5 (12.5-15)		40 (88.9)	5 (11.1)	
Age, y				.939			.782
<35	54	9.9 (3.7)	10 (7.5-12.5)		32 (59.3)	22 (40.7)	
35+	46	9.9 (3.6)	10 (7.5-12.5)		26 (56.5)	20 (43.5)	
Hip				.591			.896
Right	54	9.7 (3.6)	10 (7.0-12.5)		31 (57.4)	23 (42.6)	
Left	46	10.1 (3.6)	10 (7.5-12.5)		27 (58.7)	19 (41.3)	
Pathology				<.001			<.001
Nil	37	12.4 (2.2)	12.5 (10-15)		35 (94.6)	2 (5.4)	
LT PT	63	8.5 (3.5)	7.5 (5-10)		23 (36.5)	40 (63.5)	
CEA group				.022			.116
<21° (dysplastic)	0	—	—		—	—	
21°-25° (borderline)	9	7.3 (2.3)	7.5 (5-10)		3 (33.3)	6 (66.7)	
>25° (normal)	91	10.2 (3.6)	10 (7.5-12.5)		55 (60.4)	36 (39.6)	

^aCEA, center-edge angle; IQR, interquartile range; LT PT, ligamentum teres pathology.

TABLE 2
Relationship Between Beighton Test Score and Patient Variables^a

Variable	Beighton Test Score			P Value
	Count	Mean (SD)	Median (IQR)	
Sex				<.001
Female	55	4.0 (2.4)	4 (2-6)	
Male	45	1.1 (1.8)	0 (0-2)	
Age, y				.392
<35	54	2.9 (2.6)	2 (0-5)	
35+	46	2.5 (2.5)	2.5 (0-4)	
Hip				.440
Right	54	2.9 (2.7)	2 (0-6)	
Left	46	2.5 (2.3)	2.5 (0-4)	
Pathology				<.001
Nil	37	0.9 (1.4)	0 (0-2)	
LT PT	63	3.7 (2.6)	4 (0-6)	
Capsular thickness, mm				<.001
≤7.5	42	5.3 (1.3)	5 (4-6)	
>7.5	58	0.8 (1.1)	0 (0-2)	
CEA group				.014
<21° (dysplastic)	0	—	—	
21°-25° (borderline)	9	4.8 (2.8)	6 (2-6)	
>25° (normal)	91	2.5 (2.5)	2 (0-4)	

^aCEA, center-edge angle; IQR, interquartile range; LT PT, ligamentum teres pathology.

DISCUSSION

The main finding of this study was that joint hypermobility, as measured by BTS, is highly predictive of hip capsular thickness. A BTS of <4 correlates significantly with a capsular thickness of ≥10 mm, while a BTS ≥4 correlates significantly with a thickness of <10 mm. Analysis of 100

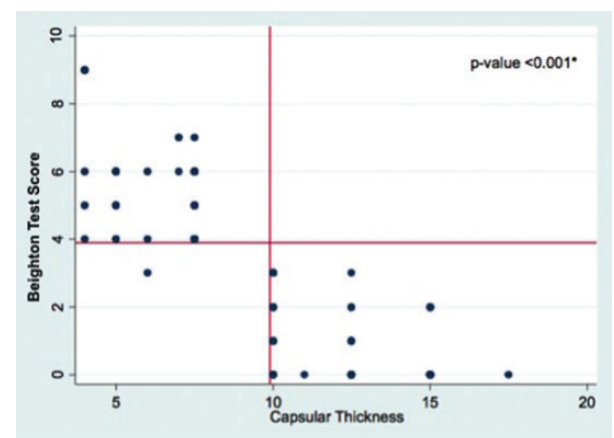


Figure 3. Scatterplot demonstrating the correlation between Beighton test score (BTS) and capsular thickness. *P value based on association between BTS and capsular thickness based on thresholds of ≥4 and ≥10 mm, respectively.

consecutive patients presenting for primary hip arthroscopy patients revealed that there was a significant sex difference both in capsular thickness and BTS; the median capsular thickness was 12.5 mm in male patients and 7.5 mm in female patients, and the median BTS was found to be 1 and 4 in men and women, respectively. In addition, those patients with borderline dysplasia had statistically thinner capsules than patients with no dysplasia and a higher BTS. There was also a higher rate of LT pathology in those patients with a capsular thickness of ≤7.5 mm. This is the first study to compare joint hypermobility and hip capsular thickness in a large series of patients. The clinical significance of these results relates to the ability to predict preoperatively patients who are likely to have a

TABLE 3
Correlation Between the Individual Components of the BTS and Capsular Thickness^a

Variable	Capsular Thickness			P Value	Capsular Thickness, n (%)		P Value
	Count	Mean (SD)	Median (IQR)		>7.5 mm	≤7.5 mm	
MCP				<.001			.008
No	49	11.3 (3.5)	12.5 (7.5-15)		35 (71.4)	14 (28.6)	
Yes	51	8.6 (3.3)	7.5 (5-10)		23 (45.1)	28 (54.9)	
Thumb				.056			.549
No	88	10.1 (3.7)	10 (7.5-12.5)		52 (59.1)	36 (40.9)	
Yes	12	8.2 (2.7)	8.8 (6.5-10)		6 (50.0)	6 (50.0)	
Elbow				<.001			<.001
No	56	12.5 (2.3)	12.5 (10-15)		54 (96.4)	2 (3.6)	
Yes	44	6.5 (1.7)	7.3 (5-7.5)		4 (9.1)	40 (90.9)	
Knee				<.001			<.001
No	59	12.5 (2.1)	12.5 (10-15)		58 (98.3)	1 (1.7)	
Yes	41	6.2 (1.4)	7 (5-7.5)		0	41 (100)	
Hands				.007			.007
No	95	10.1 (3.6)	10 (7.5-12.5)		58 (61.1)	37 (38.9)	
Yes	5	5.9 (1.7)	7 (4-7)		0	5 (100)	

^aBTS, Beighton test score; IQR, interquartile range; MCP, metacarpophalangeal.

thin capsule, which may have implications in terms of intraoperative capsular management.

The role of the capsule as a static stabilizer in the hip is well recognized.^{13,16,27,39} More recently, the concept of microinstability has emerged, which has increased the focus on what role the hip capsule plays in this process.^{26,37} In a magnetic resonance arthrography (MRA) study of 27 patients, Magerkurth et al²⁰ identified 17 patients who were positive and 10 who were negative for hip joint laxity at hip arthroscopy²⁰; the diagnosis of hip laxity was confirmed when patients exhibited displacement of the operative hip with minimal traction force. The authors determined that there was a significant difference in the mean anterior hip capsule thickness between patients with hip laxity and those without ($P = .0043$), which measured 2.5 mm (95% CI, 2.3-2.8 mm) and 3.3 mm (95% CI, 2.8-3.8 mm), respectively. The capsular measurements were considerably thinner than the values in the current study but the measurements were taken in a location lateral to the zona orbicularis and not from the IFL, which was the focus of this work and the key stabilizing ligament of the hip. Furthermore, the arthroscopic assessment of laxity was very subjective, without any objective measurements to determine laxity. Another MRA study by Weidner et al,⁴³ studied 30 patients with clinical symptoms of femoroacetabular impingement (FAI). The authors determined that the joint capsule was thickest anterosuperiorly between 1 and 2 o'clock and measured 6 mm. The capsule was measured after injection of the gadolinium on radial MR images around the axis of the femoral neck. Similarly, a significant difference existed between men and women, although the values were less than the current study. One explanation is the use of the arthrogram solution, which may stretch the capsule, and the position of the hip during the MR examination, which may influence how thick the capsule appears.

Philippon et al,³⁰ in a cadaveric study of 13 fresh-frozen cadavers, measured capsular thickness using a coordinate measuring device. The authors determined that at 2 o'clock, which corresponds with the location of the IFL, the capsule had a maximum thickness of 8.3 mm (95% CI, 6.8-9.8 mm). Although these measurements would be on the lower end of the spectrum of the findings of this study, they would be consistent. The authors did not declare the sex of the cadaveric specimens or the time between thawing, dissection and measurement, which could all affect the recorded thickness.

Hip capsule closure after hip arthroscopy has been the source of much debate.¹³ One of the big concerns is causing iatrogenic instability by not closing the capsule.¹¹ While cases of dislocation and subluxation following hip arthroscopy are rare, they are discussed frequently at hip arthroscopy conferences, which suggests that these complications are underreported.^{15,42} There have been at least 8 published case reports documenting postoperative hip dislocation after hip arthroscopy.^{3,6,12,21,23,31,32,35} This is a potentially devastating complication, and one needs to be acutely aware of the risk factors associated with it; these include open capsulotomy without repair, acetabular dysplasia, hypermobility, or ligamentous laxity.^{1,13,16} In a report of 25 patients requiring revision hip arthroscopy for treatment of FAI, McCormick et al²² documented that 9 patients had capsular abnormalities on MRA, 7 of whom required surgery to repair the nonhealing portions of the capsule. The importance of the findings of the current study relate to identifying preoperatively those patients who are likely to have a thin capsule. As has been demonstrated, a BTS of ≥ 4 correlates significantly with a capsular thickness of <10 mm. In such a case with hypermobility and a thin capsule, the surgeon may wish to make a smaller capsulotomy or close or plicate the capsule postoperatively to limit the risk of instability.

Atraumatic microinstability has also been reported in patients with borderline dysplasia.^{19,22} Hip dysplasia results in femoral head undercoverage by the acetabulum. The hip joint biomechanics are altered as a result, which places additional stress on the labrum, anterior capsule, and dynamic stabilizers.^{14,33} Consequently, there is an overreliance on the hip soft tissue stabilizers (cartilage, labrum, capsule, and LT) for stability of the hip through the full range of motion in patients with dysplasia and borderline dysplasia. In this study, patients with borderline dysplasia had a significantly thinner hip capsule. Domb et al,¹⁴ in a study of 22 patients with borderline dysplasia and labral tears, reported good outcomes at 2 years in patients treated with labral preservation and repair with capsular plication. It is recognized that capsular management is especially important in patients with borderline dysplasia, as iatrogenic injury to the capsule without appropriate repair will destabilize the hip joint.^{34,35} It is also interesting to note that there was a significantly higher prevalence of LT pathology in patients with a BTS ≥ 4 , which correlates with a thinner capsule. This would concur with the findings of Chahla et al,¹⁰ who reported that joint hypermobility is a risk factor for LT pathology.

GJH has increasingly been recognized as a risk factor for many joint injuries, including recurrent shoulder dislocation, patellar instability, anterior cruciate injuries, lumbar disc pathology, and ankle instability.^{7,8,17,28,40} In a large cohort study of 721 military personnel, Azma et al⁴ demonstrated an increased incidence of ankle sprain and temporomandibular joint dislocation in hypermobile individuals compared with a control group. The authors advocated the usefulness of screening to identify at-risk individuals. The overall prevalence rates of joint hypermobility ranged from 12% to 32.7%, with a greater preponderance in female patients.^{4,8,25} The prevalence of GJH in this study was 41%. Notably, the majority of studies focusing on joint hypermobility used a BTS value of ≥ 4 to define hypermobility^{4,34,36,38}; this is the same cutoff value that was identified in this study.

Limitations

The authors acknowledge that there are limitations in this study. The selection of patients was not made according to a specific pathology but as a consecutive series of patients. The arthroscopic measurement of capsular thickness was made by a single arthroscopist who was blinded to the preoperative BTS readings. The measurements were made using an arthroscopic probe, which had laser etching at 5-mm increments and necessitated estimation of the thickness when the measurement fell between the lines. However, particular attention was focused on ensuring the measurement was orthogonal to the capsule at the anterior portal at the 1- to 2- o'clock position.

CONCLUSION

The measurement of GJH is highly predictive of hip capsular thickness. A BTS of <4 correlates significantly with a

capsular thickness of ≥ 10 mm, while a BTS ≥ 4 correlates significantly with a thickness of <10 mm. Women had a significantly increased BTS compared with men and also had a thinner hip capsule. Patients with borderline dysplasia had a significantly thinner capsule than those without. There was a greater incidence of LT pathology in patients with a capsular thickness of ≤ 7.5 mm. The BTS is a simple preoperative assessment, which can assist in predicting hip capsular thickness and may influence capsular management strategies.

REFERENCES

- Abrams GD, Hart MA, Takami K, et al. Biomechanical evaluation of capsulotomy, capsulectomy, and capsular repair on hip rotation. *Arthroscopy*. 2015;31:1511-1517.
- Anderson LA, Giulland J, Pelt C, Linford S, Stoddard GJ, Peters CL. Center edge angle measurement for hip preservation surgery: technique and caveats. *Orthopedics*. 2011;34:86.
- Austin DC, Horneff JG 3rd, Kelly JD 4th. Anterior hip dislocation 5 months after hip arthroscopy. *Arthroscopy*. 2014;30:1380-1382.
- Azma K, Mottaghi P, Hosseini A, Abadi HH, Nouraei MH. Benign joint hypermobility syndrome in soldiers: what is the effect of military training courses on associated joint instabilities? *J Res Med Sci*. 2014;19:639-643.
- Beighton P. Hypermobility scoring. *Br J Rheumatol*. 1988;27:163.
- Benali Y, Katthagen BD. Hip subluxation as a complication of arthroscopic debridement. *Arthroscopy*. 2009;25:405-407.
- Bilsel K, Ceylan HH, Yildiz F, Erden T, Toprak A, Tuncay I. Acetabular dysplasia may be related to global joint hyperlaxity. *Int Orthop*. 2016;40:885-889.
- Bin Abd Razak HR, Bin Ali N, Howe TS. Generalized ligamentous laxity may be a predisposing factor for musculoskeletal injuries. *J Sci Med Sport*. 2014;17:474-478.
- Byrd JW, Jones KS. Arthroscopic femoroplasty in the management of cam-type femoroacetabular impingement. *Clin Orthop Relat Res*. 2009;467:739-746.
- Chahla J, Soares EA, Devitt BM, et al. Ligamentum teres tears and femoroacetabular impingement: prevalence and preoperative findings. *Arthroscopy*. 2016;32:1293-1297.
- Chandrasekaran S, Vemula SP, Martin TJ, Suarez-Ahedo C, Lodhia P, Domb BG. Arthroscopic technique of capsular plication for the treatment of hip instability. *Arthrosc Tech*. 2015;4:e163-e167.
- Dierckman BD, Guanche CA. Anterior hip capsuloligamentous reconstruction for recurrent instability after hip arthroscopy. *Am J Orthop (Belle Mead NJ)*. 2014;43:E319-E323.
- Domb BG, Philippon MJ, Giordano BD. Arthroscopic capsulotomy, capsular repair, and capsular plication of the hip: relation to atraumatic instability. *Arthroscopy*. 2013;29:162-173.
- Domb BG, Stake CE, Lindner D, El-Bitar Y, Jackson TJ. Arthroscopic capsular plication and labral preservation in borderline hip dysplasia: two-year clinical outcomes of a surgical approach to a challenging problem. *Am J Sports Med*. 2013;41:2591-2598.
- Harris JD, McCormick FM, Abrams GD, et al. Complications and reoperations during and after hip arthroscopy: a systematic review of 92 studies and more than 6,000 patients. *Arthroscopy*. 2013;29:589-595.
- Harris JD, Slikker W 3rd, Gupta AK, McCormick FM, Nho SJ. Routine complete capsular closure during hip arthroscopy. *Arthrosc Tech*. 2013;2:e89-e94.
- Huang B, Kim YT, Kim JU, Shin JH, Park YW, Kim HN. Modified Brostrom procedure for chronic ankle instability with generalized joint hypermobility. *Am J Sports Med*. 2016;44:1011-1016.
- Kellgren JH, Lawrence JS. Radiological assessment of osteo-arthrosis. *Ann Rheum Dis*. 1957;16:494-502.
- Kuhns BD, Weber AE, Levy DM, et al. Capsular management in hip arthroscopy: an anatomic, biomechanical, and technical review. *Front Surg*. 2016;3:13.

20. Magerkurth O, Jacobson JA, Morag Y, Caoili E, Fessell D, Sekiya JK. Capsular laxity of the hip: findings at magnetic resonance arthrography. *Arthroscopy*. 2013;29:1615-1622.
21. Matsuda DK. Acute iatrogenic dislocation following hip impingement arthroscopic surgery. *Arthroscopy*. 2009;25:400-404.
22. McCormick F, Slikker W 3rd, Harris JD, et al. Evidence of capsular defect following hip arthroscopy. *Knee Surg Sports Traumatol Arthrosc*. 2014;22:902-905.
23. Mei-Dan O, McConkey MO, Brick M. Catastrophic failure of hip arthroscopy due to iatrogenic instability: can partial division of the ligamentum teres and iliofemoral ligament cause subluxation? *Arthroscopy*. 2012;28:440-445.
24. Myers CA, Register BC, Lertwanich P, et al. Role of the acetabular labrum and the iliofemoral ligament in hip stability: an in vitro biplane fluoroscopy study. *Am J Sports Med*. 2011;39(suppl):85S-91S.
25. Naal FD, Hatzung G, Muller A, Impellizzeri F, Leunig M. Validation of a self-reported Beighton score to assess hypermobility in patients with femoroacetabular impingement. *Int Orthop*. 2014;38:2245-2250.
26. Nepple JJ, Clohisy JC. The dysplastic and unstable hip: a responsible balance of arthroscopic and open approaches. *Sports Med Arthrosc*. 2015;23:180-186.
27. Nepple JJ, Smith MV. Biomechanics of the hip capsule and capsule management strategies in hip arthroscopy. *Sports Med Arthrosc*. 2015;23:164-168.
28. Niedzielski KR, Malecki K, Flont P, Fabis J. The results of an extensive soft-tissue procedure in the treatment of obligatory patellar dislocation in children with ligamentous laxity: a post-operative isokinetic study. *Bone Joint J*. 2015;97-B:129-133.
29. Philippon MJ, Michalski MP, Campbell KJ, et al. An anatomical study of the acetabulum with clinical applications to hip arthroscopy. *J Bone Joint Surg Am*. 2014;96:1673-1682.
30. Philippon MJ, Michalski MP, Campbell KJ, et al. A quantitative analysis of hip capsular thickness. *Knee Surg Sports Traumatol Arthrosc*. 2015;23:2548-2553.
31. Ranawat AS, McClincy M, Sekiya JK. Anterior dislocation of the hip after arthroscopy in a patient with capsular laxity of the hip. A case report. *J Bone Joint Surg Am*. 2009;91:192-197.
32. Rosenbaum A, Roberts T, Flaherty M, Phillips N, Patel N, Das P. Posterior dislocation of the hip following arthroscopy—a case report and discussion. *Bull Hosp Jt Dis (2013)*. 2014;72:181-184.
33. Ross JR, Clohisy JC, Baca G, Sink E; ANCHOR Investigators. Patient and disease characteristics associated with hip arthroscopy failure in acetabular dysplasia. *J Arthroplasty*. 2014;29(9 suppl):160-163.
34. Russek LN, Errico DM. Prevalence, injury rate and, symptom frequency in generalized joint laxity and joint hypermobility syndrome in a "healthy" college population. *Clin Rheumatol*. 2016;35:1029-1039.
35. Sansone M, Ahlden M, Jonasson P, Sward L, Eriksson T, Karlsson J. Total dislocation of the hip joint after arthroscopy and ileopsoas tenotomy. *Knee Surg Sports Traumatol Arthrosc*. 2013;21:420-423.
36. Scheper MC, de Vries JE, Juul-Kristensen B, Nollet F, Engelbert RH. The functional consequences of generalized joint hypermobility: a cross-sectional study. *BMC Musculoskelet Disord*. 2014;15:243.
37. Shu B, Safran MR. Hip instability: anatomic and clinical considerations of traumatic and atraumatic instability. *Clin Sports Med*. 2011;30:349-367.
38. Sohrbeck-Nohr O, Kristensen JH, Boyle E, Remvig L, Juul-Kristensen B. Generalized joint hypermobility in childhood is a possible risk for the development of joint pain in adolescence: a cohort study. *BMC Pediatr*. 2014;14:302.
39. Telleria JJ, Lindsey DP, Giori NJ, Safran MR. An anatomic arthroscopic description of the hip capsular ligaments for the hip arthroscopist. *Arthroscopy*. 2011;27:628-636.
40. Vaishya R, Hasija R. Joint hypermobility and anterior cruciate ligament injury. *J Orthop Surg (Hong Kong)*. 2013;21:182-184.
41. Walters BL, Cooper JH, Rodriguez JA. New findings in hip capsular anatomy: dimensions of capsular thickness and pericapsular contributions. *Arthroscopy*. 2014;30:1235-1245.
42. Weber AE, Harris JD, Nho SJ. Complications in hip arthroscopy: a systematic review and strategies for prevention. *Sports Med Arthrosc*. 2015;23:187-193.
43. Weidner J, Buchler L, Beck M. Hip capsule dimensions in patients with femoroacetabular impingement: a pilot study. *Clin Orthop Relat Res*. 2012;470:3306-3312.