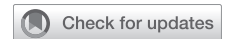

# Univentricular palliation for a child with severe Uhl's anomaly



Chuhao Du, MD,<sup>a</sup> Shuo Dong, MD, PhD,<sup>a</sup> Haitao Xu, MD, PhD,<sup>a</sup> Yangxue Sun, MD,<sup>a</sup> Mengxuan Zou, MD,<sup>a</sup> Jie Dong, MD,<sup>a</sup> Kunjing Pang, MD, PhD,<sup>b</sup> Xuan Ma, MD,<sup>c</sup> Hongyue Wang, MD, PhD,<sup>d</sup> and Jun Yan, MD, PhD,<sup>a</sup> Beijing, China

From the Departments of <sup>a</sup>Pediatric Cardiac Surgery, <sup>b</sup>Ultrasound, <sup>c</sup>Magnetic Resonance Imaging, and <sup>d</sup>Pathology, National Center for Cardiovascular Disease and Fuwai Hospital, Chinese Academy of Medical Sciences, Peking Union Medical College, Beijing, China.

This study was supported by the National Key R&D Program of China (2017YFC1308100).

Disclosures: The authors reported no conflicts of interest.

The *Journal* policy requires editors and reviewers to disclose conflicts of interest and to decline handling or reviewing manuscripts for which they may have a conflict of interest. The editors and reviewers of this article have no conflicts of interest.

Drs Du and Dong contributed equally to this article.

Received for publication Feb 20, 2022; revisions received April 13, 2022; accepted for publication April 27, 2022; available ahead of print April 30, 2022.

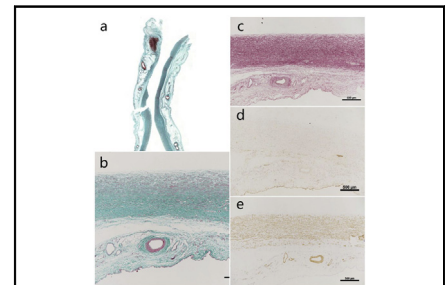
Address for reprints: Jun Yan, MD, PhD, Department of Pediatric Cardiac Surgery, National Center for Cardiovascular Disease and Fuwai Hospital, Chinese Academy of Medical Sciences, Peking Union Medical College, Beijing, China (E-mail: [yanjun@fuwaihospital.org](mailto:yanjun@fuwaihospital.org)).

JTCVS Techniques 2022;14:207-11

2666-2507

Copyright © 2022 The Author(s). Published by Elsevier Inc. on behalf of The American Association for Thoracic Surgery. This is an open access article under the CC BY-NC-ND license (<http://creativecommons.org/licenses/by-nc-nd/4.0/>).

<https://doi.org/10.1016/j.xjtc.2022.04.026>



Pathologic staining of the right ventricular wall revealed complete absence of myocardium.

## CENTRAL MESSAGE

This report demonstrates the features of severe Uhl's anomaly and presents a successful univentricular palliation for this rare congenital heart defect.

▶ Video clip is available online.

Uhl's anomaly, originally described by Uhl in 1952, is an extremely rare congenital heart defect that is characterized by complete or partial absence of the right ventricular (RV) myocardium, with unknown etiology.<sup>1</sup> Uhl's anomaly commonly presents with congestive right-side heart failure, massive peripheral edema, and cyanosis.<sup>1-3</sup> Fewer than 100 cases have been described, and there are no more than 10 patients who have received successful surgical treatment.<sup>4</sup> At present, there is no consensus on the surgical strategy for Uhl's anomaly.<sup>2-8</sup> We present our surgical experience of a 20-month-old child with Uhl's anomaly and discuss the surgical approach for this anomaly.

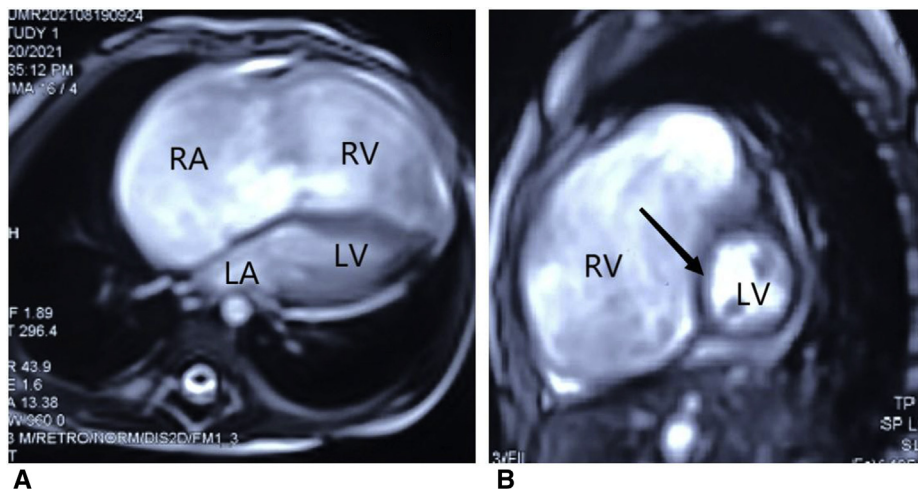
## CASE REPORT

A 20-month-old child (weight 10.9 kg) was admitted to our hospital with severe cyanosis for a period of 2 months and right heart failure. Uhl's anomaly was diagnosed. Physical examination revealed a low saturation of oxygen of 80% at rest and 48% when crying in room air. Exome

sequencing did not reveal any gene mutations, and the electrocardiogram was normal. The parents of this child provided informed written consent for the publication of the study data.

A transthoracic echocardiography (TTE) demonstrated a patent foramen ovale with bidirectional shunting, severe tricuspid regurgitation with normally inserted tricuspid valve leaflet, severe right atrium, and RV dilation. Cardiac magnetic resonance (CMR) conformed severe dilated and thin-walled right atrium and RV, fibrosis of the RV myocardium and small left ventricle with left displacement of the ventricular septum, as the dilated and akinetic RV was compressing it (Figure 1). Functionally, the ejection fraction, end-diastolic volume, and end-systolic volume of RV were 14%, 89.1 mL, and 77.1 mL, respectively, whereas those of the left ventricle were normal. Cardiac catheterization revealed that mean pulmonary arterial pressure, right atrium pressure and total lung resistance were 6 mm Hg, 6 mm Hg, and 105 dyne units, respectively.

After a multidisciplinary discussion, we decided to adopt a univentricular strategy for this child. A

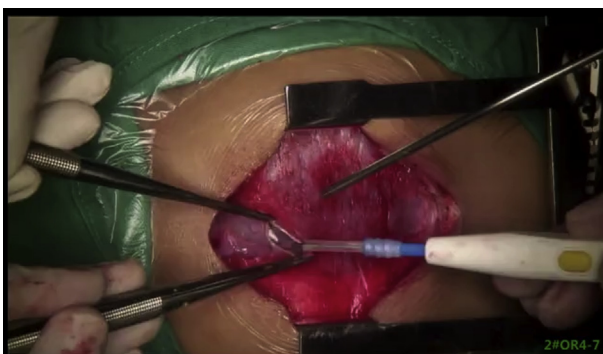

**FIGURE 1.** Preoperative cardiac magnetic resonance imaging of the child. A, Severe dilated and thin-walled right atrium and right ventricle. B, Small left ventricle with left displacement of ventricular septum as the dilated and akinetic right ventricle was compressing it. The *arrow* points at the interventricular septum which is shifted to the left. RA, Right atrium; RV, right ventricle; LA, left atrium; LV, left ventricle.

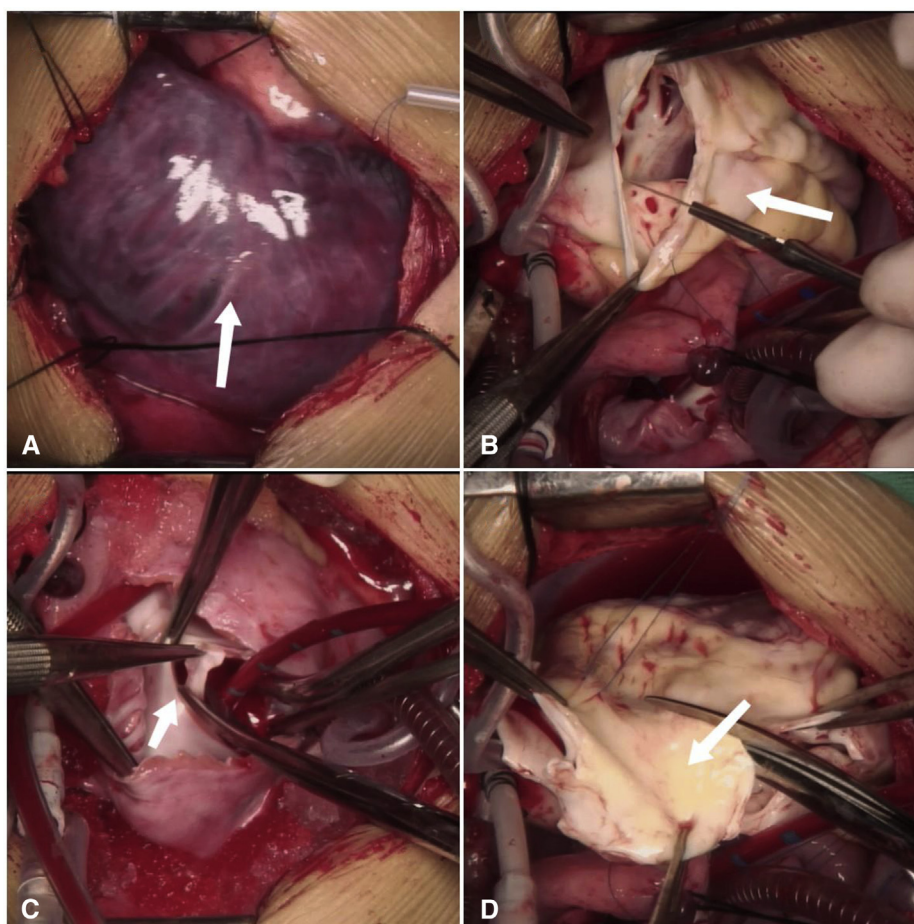
bidirectional cavopulmonary shunt (BCPS), atrial septectomy, partial right ventriculectomy, plication of RV, closure of tricuspid valve covered with bovine pericardium, and transection of main pulmonary artery were carried out (Video 1). At surgery, severe enlargement of right heart, poor tricuspid valve coaptation, and severely dilated tricuspid annulus without displacement were found, which was consistent with imaging findings. The right ventricle wall was white, extremely thin, and grossly fibrotic, which was well demarcated with left ventricle and right atrium (Figure 2). After the right atrium was incised, atrial septectomy was performed. Partially fibrotic RV was removed and the remnant flaps were

sutured together (Figure 2). The root of main pulmonary was transected and the proximal and distal pulmonary arteries were sutured. A bovine pericardium was sutured to the tricuspid valve after the leaflets of tricuspid were sutured. BCPS was created by anastomosing the superior vena cava to the superior surface of the right pulmonary artery. Pathologic examination of RV revealed fibrous proliferation, myocardial absence, and smooth muscle compensatory hyperplasia (Figure 3).

After surgery, patient’s oxygen saturation was up to 88%, and superior and inferior vena cava pressure were 10 mm Hg and 5 mm Hg, respectively. The child was extubated 2 days after surgery. CMR revealed that the connection between the superior vena cava and the right pulmonary artery was unobstructed (Figure 4). A transesophageal echocardiogram performed on postoperative day 8 showed a thrombus, 19 × 14 mm in size, which was located in the endocardium of the right atrial incision. The patient had no symptoms. An anticoagulant regimen combined with warfarin and heparin was used, with target international normalized ratio being 2.0 to 3.0. The thrombus gradually reduced in size and disappeared 3 weeks later. Postoperative course was uneventful. At follow-up, the child was doing well 2 and a half months after surgery, with oxygen saturations of 83% in room air at rest. The TTE demonstrated a sutured RV, a well-functioning left ventricle (ejection fraction of 64%), widely patent BCPS, and unrestrictive atrial septal defect. The patient is currently doing well at 6 months after surgery and awaiting completion of Fontan circulation.



**VIDEO 1.** The operation technique of univentricular palliation for severe Uhl’s anomaly. Video available at: [https://www.jtcvs.org/article/S2666-2507\(22\)00264-4/fulltext](https://www.jtcvs.org/article/S2666-2507(22)00264-4/fulltext).



**FIGURE 2.** Intraoperative images. A, The large and congested right atrium, as indicated by the *arrow*. B, Large thin-walled completely fibrotic right ventricle, as indicated by the *arrow*. C, Atrial septectomy. The *arrow* points at the interatrial septum. D, Partial right ventriculectomy. The *arrow* refers to the removed part of right ventricle.

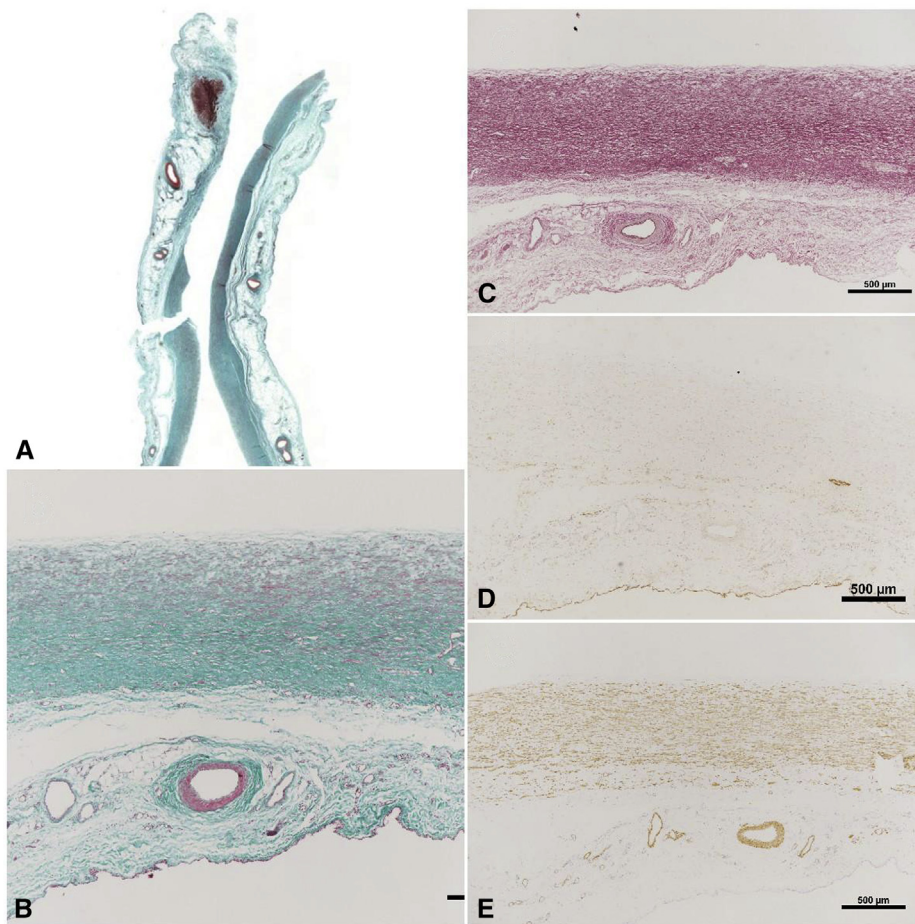
## DISCUSSION

Uhl's anomaly is a rare congenital heart malformation characterized by a partial or complete absence of the RV muscle.<sup>1</sup> In patients with Uhl's anomaly, the myocardium of the left ventricle and the position of tricuspid valve are normal, even though tricuspid valve dysplasia may be presented in some cases.<sup>1,7,9</sup> The main manifestation of Uhl's anomaly is right heart failure, and some other manifestations may also appear, such as cyanosis, arrhythmia, thromboembolism, and conduction block.<sup>7,10,11</sup> Uhl's anomaly needs to be distinguished from the parchment heart, arrhythmogenic RV cardiomyopathy, and Ebstein anomaly.<sup>1,9</sup>

Combined with CMR, ultrasound, and pathology results, we concluded that this case was one of the more severe forms of Uhl's anomaly, in which almost all of the right

ventricular myocardium was missing, as a result, we performed a univentricular palliation rather than one and a half ventricle repair. To prevent the huge RV from compressing the left ventricle and affecting its function,<sup>10</sup> we closed the remaining RV, and to eliminate the residual stagnant blood flow in the RV, which can possibly form thrombus that may fall into the systemic circulation and pulmonary circulation,<sup>3</sup> we closed the tricuspid valve and transected the pulmonary artery. Also, we enlarged the atrial septal defect to facilitate the flow of blood from the inferior vena cava through the atrial septum and into the left heart.

There are few reports of successful surgery in the literature, which included one-and-one half ventricular correction,<sup>4,5,7</sup> RV volume reduction and atrial septal fenestration,

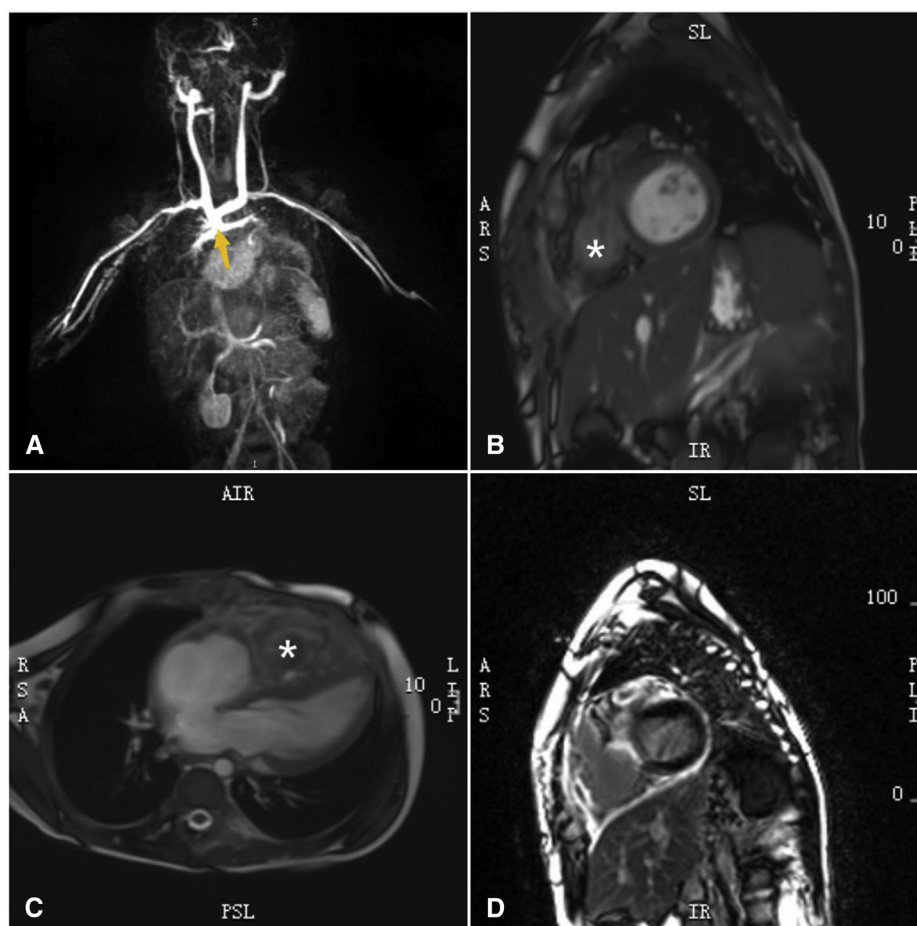


**FIGURE 3.** Pathologic staining of a right ventricular wall section. A and B, Masson trichrome staining 0.5× revealed increased collagen and fibrosis; C, Elastic fiber dyeing shows elastic fiber hyperplasia. D, Myosin staining shows no myocardium. E, Smooth muscle actin staining shows compensatory hyperplasia of smooth muscle (*brown deposits*).

univentricular palliation,<sup>3,6,7</sup> and heart transplantation.<sup>12</sup> Although the optimal surgical strategy and the timing for the operation are uncertain, in some cases, univentricular palliation has been considered as a more appropriate approach,<sup>3,6</sup> in which the RV exclusion was considered a necessary procedure.<sup>3,7</sup> Hoschitzky and colleagues<sup>3</sup> reported that, during the BCPS, the dead chamber of the RV and the opening of the tricuspid valve were preserved. The postoperative TTE demonstrated thrombus in the RV outflow tract and paradoxical ventricular septal motion. Therefore, a reoperation was performed, during which the thrombus was removed, thin-walled RV cavity was plicated to prevent distension of the RV with septal displacement toward the left ventricular cavity, and the tricuspid valve was closed with a patch of bovine pericardium. That patient was in good condition

15 months after operation. According to the authors' experience, RV exclusion is extremely important to prevent thrombosis and eliminate ventricular interaction.<sup>3</sup> It is worth mentioning that several reports have described the formation of thrombus in Uhl's anomaly both pre- and postoperatively.<sup>3,8,12</sup> In addition, although the RV exclusion and tricuspid valve closure were performed in our case, right atrial thrombus still occurred postoperatively, as a result, anticoagulation therapy should be an important treatment for Uhl's anomaly. In our case, we removed most of the RV as we considered the severe fibrosis of the RV as the basis of arrhythmias.<sup>5,13</sup>

A successful univentricular repair of a child with severe Uhl's anomaly can be achieved with extensive resection and plication of the right ventricle.



**FIGURE 4.** Postoperative cardiac magnetic resonance imaging of the child. A, The connection between the superior vena cava and the right pulmonary artery is unobstructed. The *yellow arrow* refers to the junction of the superior vena cava with the right pulmonary artery. B, The right ventricle is shrunk and not developed. C, After atrial septectomy, the blood flow of right atrium–left atrium–left ventricle is clear. D, LGE shows the fibrosis of residual right ventricle wall. \*Refers to the sutured right ventricle. *LGE*, Late gadolinium enhanced.

## References

1. Uhl HS. A previously undescribed congenital malformation of the heart: almost total absence of the myocardium of the right ventricle. *Bull Johns Hopkins Hosp.* 1952;91:197-209.
2. Yoshii S, Suzuki S, Hosaka S, Osawa H, Takahashi W, Takizawa K, et al. A case of Uhl anomaly treated with one and a half ventricle repair combined with partial right ventriculectomy in infancy. *J Thorac Cardiovasc Surg.* 2001;122:1026-8. <https://doi.org/10.1067/mtc.2001.116319>
3. Hoschtitzky A, Rowlands H, Ilina M, Khambadkone S, Elliott MJ. Single ventricle strategy for Uhl's anomaly of the right ventricle. *Ann Thorac Surg.* 2010;90:2076-8. <https://doi.org/10.1016/j.athoracsur.2009.12.084>
4. Chounoune R, Lowry A, Ramakrishnan K, Pearson GD, Moak JP, Nath DS. Uhl's anomaly: a one and a half ventricular repair in a patient presenting with cardiac arrest. *J Saudi Heart Assoc.* 2018;30:52-4. <https://doi.org/10.1016/j.jsha.2017.03.011>
5. Tanoue Y, Kado H, Shikawa Y. Uhl's anomaly complicated with critical ventricular arrhythmia in a 2-month-old infant. *Eur J Cardiothorac Surg.* 2003;24:1040-2. <https://doi.org/10.1016/j.ejcts.2003.09.016>
6. Takizawa K, Suzuki S, Honda Y, Kaga S, Inoue H, Matsumoto M. Long-term survival of Uhl's anomaly with total cavopulmonary conversion. *Asian Cardiovasc Thorac Ann.* 2009;17:203-5. <https://doi.org/10.1177/0218492309103328>
7. Kalita JP, Dutta N, Awasthy N, Chowdhuri KR, Girotra S, Radhakrishnan S, et al. Surgical options for Uhl's anomaly. *World J Pediatr Congenit Heart Surg.* 2017; 8:470-4. <https://doi.org/10.1177/2150135117710940>
8. Azhari N, Assaqqat M, Bulbul Z. Successful surgical repair of Uhl's anomaly. *Cardiol Young.* 2002;12:192-5. <https://doi.org/10.1017/s1047951102000410>
9. van der Palen RL, van der Wal AC, Robles de Medina PG, Blom NA, Clur SA. Uhl's anomaly: clinical spectrum and pathophysiology. *Int J Cardiol.* 2016;209: 118-21. <https://doi.org/10.1016/j.ijcard.2016.02.048>
10. Rizk J, Shehu N, Wolf C, Meierhofer C. A case of Uhl's anomaly presenting with ventricular tachycardia. *Eur Heart J Cardiovasc Imaging.* 2018;19:1312. <https://doi.org/10.1093/ehjci/jej122>
11. James TN, Nichols MM, Sapire DW, DiPatre PL, Lopez SM. Complete heart block and fatal right ventricular failure in an infant. *Circulation.* 1996;93: 1588-600. <https://doi.org/10.1161/01.cir.93.8.1588>
12. Yanagi Y, Amaki M, Kato Y, Kanzaki H, Kusano K, Yasuda S, et al. A case of right ventricular thrombus formation in Uhl's anomaly: usefulness of 3D trans-thoracic echocardiography for treatment follow-up. *J Med Ultrason (2001).* 2020;47:141-2. <https://doi.org/10.1007/s10396-019-00988-6>
13. Sano S, Ishino K, Kawada M, Kasahara S, Kohmoto T, Takeuchi M, et al. Total right ventricular exclusion procedure: an operation for isolated congestive right ventricular failure. *J Thorac Cardiovasc Surg.* 2002;123:640-7. <https://doi.org/10.1067/mtc.2002.121160>