

Protective effect of dietary supplementation of *Bupleurum falcatum* L saikosaponins on ammonia exposure–induced ileum injury in broilers

Gang Shu,^{*,1,2} Dan Xu,^{*,1} Chonglin Ran,^{*} Lizi Yin,^{*} Juchun Lin,^{*} Hualin Fu,^{*} Wei Zhang,^{*} Shiping Bai,[†] Xi Peng,[‡] Xiaoling Zhao,[§] and Felix Kwame Amevor[§]

^{*}Department of Basic Veterinary Medicine, Sichuan Agricultural University, Chengdu, Sichuan, China; [†]Institute of Animal Nutrition, Feed Engineering Research Centre of Sichuan Province, Sichuan Agricultural University, Chengdu 611130, Sichuan, China; [‡]Sichuan Industrial Institute of Antibiotics, Chengdu University, Chengdu, Sichuan, China; and [§]Farm Animal Genetic Resources Exploration and Innovation Key Laboratory of Sichuan Province, Sichuan Agricultural University, Chengdu, Sichuan, China

ABSTRACT Ammonia (NH₃) at a high concentration has been recognized as a highly poisonous pollutant affecting both air and water quality. NH₃, as a stimulus, exerts negative impact on broiler growth and production, but the molecular mechanisms are not clear yet. This study was designed to evaluate the effects of dietary supplementation of *Bupleurum falcatum* L saikosaponins (SP) on the growth and ileum health status in broilers exposed to NH₃. Day-old Arbor Acers broilers (n = 480) were randomly allocated into 1 of 4 treatments. The main factors were dietary SP supplementation (0 or 80 mg/kg of diet) and NH₃ challenge (with or without 70 ± 5 ppm

NH₃). The data of growth, intestinal morphology, and mRNA expression related to ileal function were collected from broilers exposed to NH₃ for 7 d. Results showed that NH₃ remarkably suppressed growth performance and intestinal development as well as induced biological injuries in the ileum of broilers, resulting from oxidative stress, mucous barrier damage, and immune dysfunction as well as upregulated apoptosis. These negative effects of NH₃ were alleviated by the SP supplement. In conclusion, dietary supplementation of SP may be helpful in alleviating the detrimental effects of NH₃ on the ileum development in broilers.

Key words: ammonia, *Bupleurum falcatum* L saikosaponins, ileum, injury, broiler

2021 Poultry Science 100:100803

<https://doi.org/10.1016/j.psj.2020.10.057>

INTRODUCTION

The intestine is an essential organ for nutrients digestion and absorption as well as an intrinsic barrier in animals including poultry (Ghareeb et al., 2015). A series of intestinal protective mechanisms including physical, chemical, and immunological barriers work combinedly to resist invasion of pathogens and other harmful contaminants to maintain biological homeostasis of animals (Awad et al., 2015). Intestinal health is the basis of optimal healthy condition and plays an important role in improving the growth performance of animals (Tao et al., 2019). Factors such as breeding program,

management practices, environmental stressors (temperature, harmful gas, and noise), and nutrient levels can potentially affect intestinal health in broilers (Kers et al., 2018).

Ammonia (NH₃), a colorless and highly water-soluble toxicant with pungent odor, is harmful in poultry production (Xing et al., 2016). In animal houses, ammonia mainly emits from animal manure by hydrolysis, mineralization, and volatilization (Zhang et al., 2015). The concentration of atmospheric NH₃ inside poultry houses is relevant to its harmful degree. According to the National Institute of Safety and Health Administration and the Occupational Safety and Health Administration, the highest acceptable level of NH₃ in poultry houses is within a range from 25 ppm to 50 ppm (Tao et al., 2019). However, to meet the demand for poultry meat products and reduce production costs, farmers increase the stocking size and density of broilers; hence, the levels of NH₃ inside poultry houses often exceed 80 ppm, especially during winter. Ammonia is regarded as an important factor with great impacts on broiler's health and welfare (David et al., 2015; Naseem

© 2020 The Authors. Published by Elsevier Inc. on behalf of Poultry Science Association Inc. This is an open access article under the CC BY-NC-ND license (<http://creativecommons.org/licenses/by-nc-nd/4.0/>).

Received August 11, 2020.

Accepted October 19, 2020.

¹These authors contributed equally to this work.

²Corresponding author: dysyng2005@sicau.edu.cn

and King, 2018). Reports showed that excessive exposure of NH₃ may directly decrease growth and productive performance of poultry (Soliman et al., 2017), endanger the respiratory tract (Wei et al., 2015), cause neurotoxicity and immunotoxicity (Xiong et al., 2016), and severely interfere with broiler welfare (Wei et al., 2012), resulting in a variety of diseases such as necrotic enteritis or even death (Olanrewaju et al., 2008). Moreover, studies have also revealed that the gastrointestinal tract is one of the target organ damaged by NH₃ inhalation; high concentrations of this toxin can significantly induce upregulation of some genes and proteins expression in the intestine as well as trigger intestinal flora disturbance, inflammatory response, immune dysfunction, oxidative stress, or apoptosis (Zhang et al., 2015). Compared with other animals, poultry produces the highest ammonia emission (Aardenne et al., 2001), whereas poultry is one of the most sensitive animals to NH₃ (Wathes et al., 1984). However, the effects of NH₃ on the small intestine of poultry are often neglected and inconclusive. Therefore, it is necessary to find out the molecular mechanisms that underlie the toxicity of NH₃ on the ileum of broilers. Meanwhile, effective methods for prevention and treatment of the NH₃ exposure-induced intestine injury are in great demand. Because NH₃ is reported as one of the most harmful stressors in animal husbandry, the use of antistress agents to enhance the host defense is considered the most promising solution to this toxin (Quarles and Kling, 1974; Guo, 2017).

Recently, traditional Chinese herb medicinal products have been showed to possess potential antistress properties and strengthen the host resistance to NH₃ stress (Ma et al., 2012). Saikosaponins (SP) represent a group of oleanane derivatives, usually as glucosides, which are ubiquitously found in plants (Cheng et al., 2010). Saikosaponins (a, c, and d) extracted from the roots of *Bupleurum falcatum* L are biologically active components (Tsai et al., 2010). Saikosaponins have been used as a treatment supplement for various medicinal efficacy including immunomodulation (Chiang et al., 2003), hepatoprotection (Zhang et al., 2018), antitumor (Li et al., 2017), antiviral (Chang et al., 2007), and antiinflammation (Benito et al., 1998). Furthermore, SP are widely used as antistress agents in traditional Chinese medicine. It has been reported that *Radix Bupleuri* extracts containing SP-mitigated negative effects of heat stress (Pan et al., 2014). However, its protective effect against NH₃ stress in chickens is poorly understood. Therefore, with the aim to develop a novel anti-NH₃ stress agent, we conducted experiments to investigate the potential for the use of SP to protect broilers from NH₃ exposure-induced intestinal injuries. In addition, the possible damage mechanism of NH₃ exposure and protective mechanism of SP in broilers were revealed.

MATERIALS AND METHODS

Reagents

B. falcatum L saikosaponins (purity > 99%, mainly contained 32.1% saikosaponin a, 11.8% saikosaponin c, 43.9% saikosaponin d, 4.7% saikosaponin e, 7.5%

saikosaponin f) were provided by Zhejiang Shengshi Biotechnology Co. Ltd. (Zhejiang, P. R. China). Total reactive oxygen species (ROS) assay kit, TRIzol reagent (Invitrogen, China), mitochondrial membrane potential (MMP) detection JC-1 kit (BD Bioscience, Franklin Lakes, NJ), and reverse transcription reagents (TaKaRa, Shiga, Japan) as well as the chicken-specific ELISA assay kits for total antioxidant capacity (T-AOC), malondialdehyde (MDA), superoxidase dismutase (SOD), glutathione (GSH), and secretory immunoglobulin A (sIgA) (Nanjing Jiancheng Bioengineering Institute, Jiangsu, P. R. China) were purchased from companies.

Experimental Animals

The animal experiment was performed at the Poultry Farm of Sichuan Agricultural University. All procedures were conducted in accordance with the national standard Laboratory Animal-Requirements of Environment and Housing Facilities (GB 14925-2001). Animal handling and care were approved by the Sichuan Agricultural University's Institutional Animal Care and Use Committee under permit number DYY-2018203007.

A total of four hundred eighty 1-day-old male Arbor Acers (AA) broilers with initial body weight of 38.83 ± 3.45 g were used in this study (Poultry Breeding Farm of Sichuan Agricultural University). Broilers were randomly assigned to environmentally controlled chambers (4,500 × 3,000 × 2,500 mm; length × width × height) of 30 broilers per chamber (Wei et al., 2012).

The airflow, photoperiod, temperature, and relative humidity were basically maintained at the same level according to poultry management guidelines (Zheng et al., 2018). Gas concentration in the chicken chambers was continuously monitored using LumaSense Photoacoustic Field Gas-Monitor Innova-1412 (Santa Clara, CA). Water and regular diets were provided based on the standard brooding practices throughout the whole period. The formulation and nutrient levels of the regular diets were based on the National Research Council requirements for chicken (Supplementary Table 1) (Pesti, 1995).

Experimental Design

The 16 chambers were randomly assigned into 4 groups, and 120 broilers per group with 4 replicates (a chamber was a replicate, and 30 broilers per replicate): 1) negative control group (CON; birds fed regular diets, the concentration of NH₃ < 5 ppm); 2) SP control group (CSP; birds fed the regular diets mixed with 80 mg/kg SP, the concentration of NH₃ < 5 ppm); 3) NH₃-exposed group (NH; birds fed the regular diets and exposed to 70 ± 5 ppm NH₃); and 4) NH₃-exposed group + SP (NSP; birds fed the regular diets mixed with 80 mg/kg SP and exposed to 70 ± 5 ppm NH₃). After acclimation for day 1, the treatment was applied from day 2 to 8. The concentration of NH₃ was selected based on previous

studies, which caused severe intestinal damage (Wei et al., 2012; Zhang et al., 2015; Tao et al., 2019). The dose of SP was chosen based on our previous experiment (Bai et al., 2020). Daily weight gain (DWG), daily feed intake (DFI), and final body weight were measured and recorded from all the experimental birds and were ultimately used to calculate the feed conversion ratio (FCR) as DWG/DFI. These growth performance parameters were adjusted by mortality.

Sample Collection and Ileal Cell Separation

On day 8, 12 chickens per group close to the average body weight were euthanized by injecting pentobarbital sodium intravenously at a dose of 100 mg/kg within 2 min from the time removed from its chamber. Thereafter, each segment of the small intestine was immediately weighed after removing the content, and the relative weight of the intestine was expressed as the ratio of the intestinal weight to body weight (mg/g). Then, the tissue samples at the midpoint of each segment of the small intestine (2 cm of the duodenum, jejunum, and ileum) were dissected and fixed in 4% (wt/vol) buffered paraformaldehyde for histological observation, and the remaining ileum tissue samples were collected for further analyses. The mucosa layer of the ileum tenue was scraped as directed by Luo et al. (Luo et al., 2013), whereas the ilea cells were harvested following the method described by Lin et al. (Lin et al., 2019). In brief, the ileum mucosa was cut, centrifuged, and suspended to 1×10^6 cell/mL in 4°C PBS solution which was used for flow cytometry analysis (Lin et al., 2019).

Relative Organ Index, Antioxidant Indices, and Immunoglobulin

In brief, 1 g of ileum mucosa was homogenized with 0.9% saline at 4°C and centrifuged; then, the supernatant was collected for subsequent test. Specific ELISA kits were used to measure the contents of T-AOC, SOD, MDA, GSH, and sIgA in the ileum tissues according to the manufacturer's instructions.

Histopathological Observation and Morphometric Parameters of the Intestine

Histological analysis was performed adhering to the guidelines described in the previous study (Uni et al., 2001). Trimmed samples were dehydrated, cleared, and then embedded in paraffin. The samples were sectioned into 5 µm slices using a RM2235 microtome (Leica, Wetzlar, Germany), flattened onto glass slides, and then dried. After dewaxing with xylene, the sections were stained with hematoxylin and eosin (Thermo, Waltham, MA) and then sealed with neutral resin. Five sections of each of the chicken's intestinal specimen (duodenum, jejunum, and ileum) were taken, and pictures (400 ×) taken on them (5 each) were examined under a CX22 microscope (Olympus, Tokyo, Japan) with DM1000 microimaging system (Leica) randomly. The villus height as

well as crypt depth were determined by Image Pro Plus 6.0. The villus/crypt ratio was calculated according to villus height/crypt depth.

Alcian Blue/Periodic Acid-Schiff Stain for Goblet Cells

Dewaxed sections were stained with 1% Alcian blue and Schiff's reagent. After the samples were dehydrated and cleared, then they were sealed with neutral resin, and photographed under light microscope. The mucus secretion was calculated by mean optical density value, and the number of goblet cells was expressed as the total number per µm² (Wang et al., 2018).

Transmission Electron Microscope Observation

Transmission electron microscopy analysis was performed according to the procedure described in the literature (Wang et al., 2018). The ileum pieces were carved into small pieces and immediately fixed in 2.5% glutaraldehyde (pH = 7.4, 4°C), and OsO₄ was used for postfixation. After dehydrating, the samples were soaked in epoxy resin acetone solution and finally embedded in epoxy resin. Microtome was used to slice the trimmed tissue blocks into 80 nm slices. The sections were double stained with lead citrate and uranyl acetate solution. Ultrastructural architectures of the ileum were observed by HT7700 transmission electron microscopy (Hitachi, Tokyo, Japan) and photographed with GANTAN830.10 W CCD camera (Hitachi).

Reactive Oxygen Species of Ileum by Flow Cytometry

The prepared ileal cells were incubated for 15 min at 37°C with DCFH-DA (total ROS assay kit) in the dark. The ROS (%) generation in ileum was determined using a flow cytometer.

Mitochondrial Membrane Potential, Apoptosis, and T Lymphocyte Cell Subsets of Ileum by Flow Cytometry

The prepared ileal cells were incubated for 15 min at 37°C with JC-1 in the dark, and the MMP was measured using flow cytometry analysis. The result of MMP was described as mitochondrial depolarization ratio. In addition, the cells were incubated for 15 min at 37°C with 5 µL Annexin V-FITC and 5 µL proliferation index (PI). Another sample was subsequently incubated for 20 min at 22°C with Mouse Anti-Chicken CD3-SPRD, Mouse Anti-Chicken CD4-PE/CY7, and Mouse Anti-Chicken CD8α-PE in dark. Furthermore, the percentage of apoptosis and T lymphocyte cell subsets were measured using flow cytometry (Bio-Rad), and all the data collected were analyzed by Kaluza 2.1 software.

Cell Life Cycle of Ileum by Flow Cytometry

The separated ileal cells were exposed for 30 min at 4°C with PI (5 mL/L propidium iodide, 0.5% Tritonx-100, RNase) in the dark, and the life cycle was immediately measured by flow cytometry. The percentage of cells at the rest phase (G_0/G_1 phase), DNA synthesis phase (S phase), and division phase ($G_2 + M$ phase) were analyzed by Kaluza 2.1 software. The PI was calculated as $(S + G_2M)/(G_0/1 + S + G_2M)$.

Fluorescence Real-Time Quantification PCR

The samples of ileum mucosa were washed with pre-frozen diethyl pyrocarbonate water and immediately frozen in liquid nitrogen and stored at -80°C . Approximately 60 mg of the preserved sample was ground thoroughly with liquid nitrogen in a precooled mortar. Total RNA was extracted with TRIzol (Invitrogen). RNA concentration was determined by a nucleic acid protein analyzer, of which the D260/D280 range eligible for reverse transcription was 1.8–2.0. The cDNA was stored at -80°C .

According to the specific steps of SYBR Green Remix Ex Taq kit specification of TaKaRa and with GAPDH as the internal reference, QRT-PCR was used to detect the expression levels of the following genes: *Claudin1*, *Zo1*, *Muc2*, *Nrf2*, *HO-1*, *Caspase 3*, *Caspase 9*, *Bax*, *Bcl-2*, *VDAC*, *TNF- α* , and *IFN- γ* . The $2^{-\Delta\Delta\text{CT}}$ method was used to calculate the relative expression levels of these genes. All primers (Supplementary Table 2) were designed using Premier 5 (PREMIER Biosoft International, Palo Alto, CA) and synthesized by Chengke BioTech Co., Ltd.

Statistical Analysis

One-way analysis of variance was performed using statistical software SPSS 19.0 (SPSS Inc., Chicago, IL). Duncan's multiple range test was used to determine the differences among treatment groups. All parameters determined in this study were presented as mean \pm SE. Significance was determined at a level of $P < 0.05$.

RESULTS

Effect of SP on Growth Performance of NH_3 -Exposed Broilers

In general, the negative effect of NH_3 on growth performance indices was reversed by SP during the experimental period (Figure 1). The results showed that the NH groups had the lowest DWG ($P < 0.05$). Compared with the CON, the NH group recorded lower DFI and final body weight ($P < 0.05$) as well as higher FCR ($P < 0.05$).

Effect of SP on Intestinal Development of NH_3 -Exposed Broilers

The treatment-related morphometric variables are presented in Figure 2. The dietary supplementation of SP had an advanced effect on both the relative organ index and morphometric parameters of intestine (the duodenum, jejunum, and ileum) in broilers. Compared with the CON group, exposure to high concentration of NH_3 (the NH group) significantly reduced the villus height in the jejunum and ileum as well as the ratio of villus/

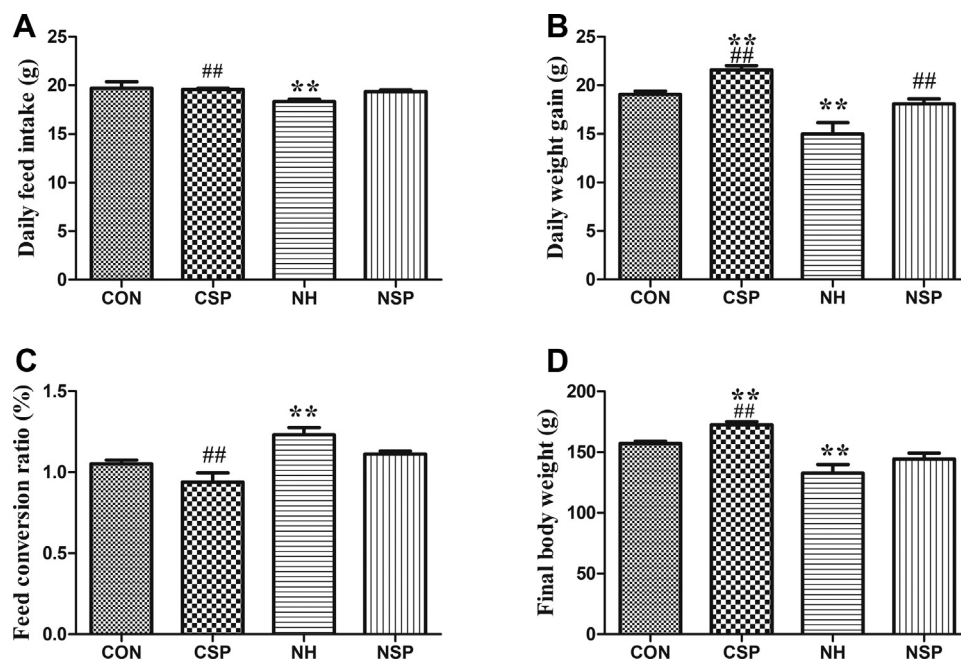


Figure 1. *Bupleurum falcatum* L saikosaponins antagonized growth inhibition in NH_3 -exposed chickens. (A) daily feed intake (DFI, g), (B) daily weight gain (DWG, g), (C) feed conversion ratio (FCR, %), and (D) final body weight (FBW, g) of broilers in different groups. $P < 0.05$ was considered statistically significant. ** $P < 0.05$ vs. control group; ## $P < 0.05$ vs. NH_3 -treated group.

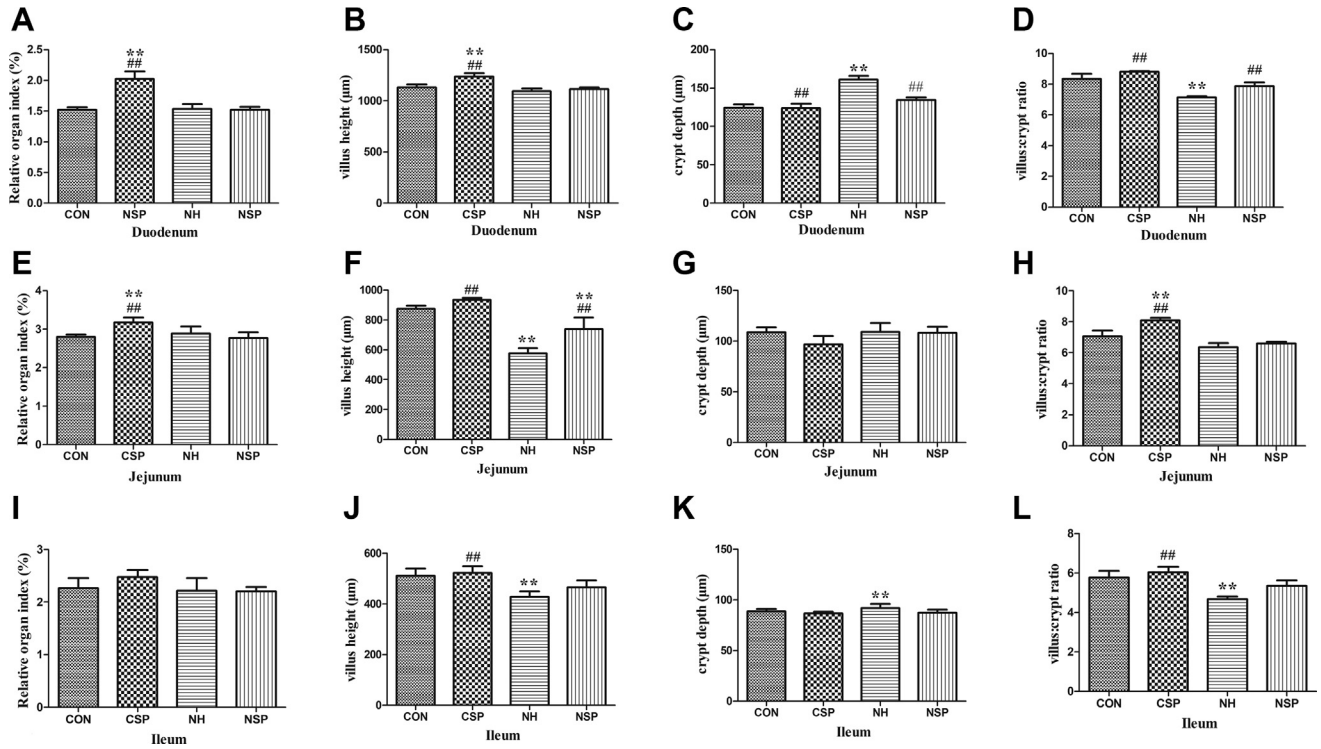


Figure 2. The data of relative organ index (%), villus height (μm), crypt depth (μm), and villus:crypt ratio of duodenum (A–D), jejunum (E–H), and ileum (I–L) in different groups. $P < 0.05$ was considered statistically significant. ** $P < 0.05$ vs. control group; ## $P < 0.05$ vs. NH₃-treated group. Abbreviations: CON, negative control group; CSP, SP control group; NH, NH₃-exposed group; NSP, NH₃-exposed group + SP; PI, proliferation index.

crypt in the duodenum and ileum ($P < 0.05$), whereas these parameters in the NSP group suggested SP normalized the alterations of the intestinal morphology. Moreover, the relative organ index of the duodenum and jejunum in CSP group was higher than that in CON and in NH group ($P < 0.05$).

Histopathological examinations (Figure 3A) exhibited a normal structure in the ileum of the CON group with complete villi, densely arrayed columnar cells as well as obvious crypt. The CSP (Figure 3B) and NSP group (Figure 3D) also showed a normal structure, similar to the CON group. Nevertheless, in NH group

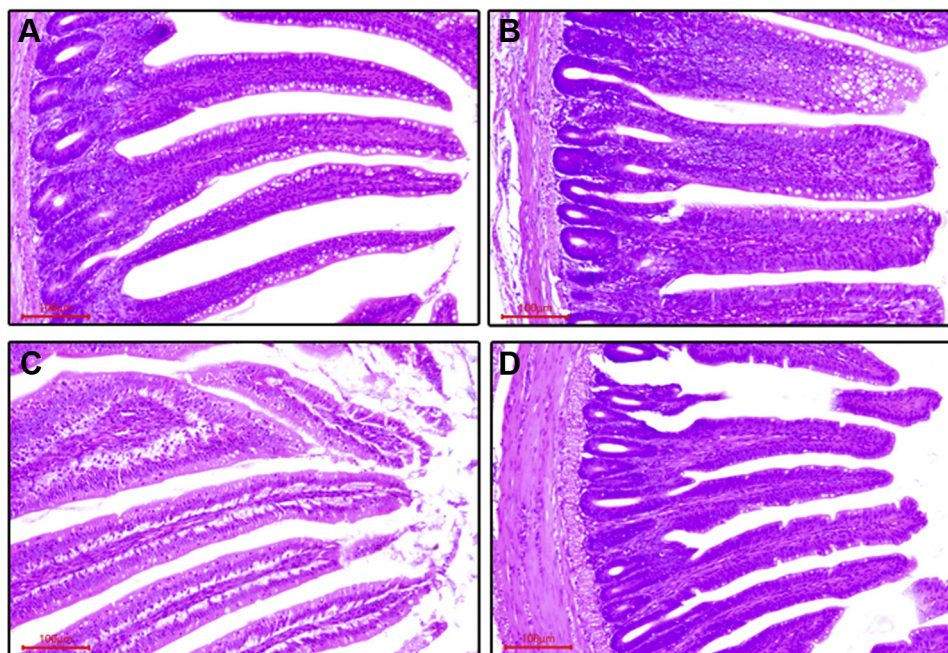


Figure 3. *Bupleurum falcatum* L saikosaponins protect the epithelial cells of ileum in NH₃-exposed broilers. Histopathological observation of ileum in different experimental groups. (A) CON group, (B) CSP group, (C) NH group, (D) SP group. H.E. stain, scale bar = 100 μm. Abbreviations: CON, negative control group; CSP, SP control group; NH, NH₃-exposed group; NSP, NH₃-exposed group + SP.

(Figure 3C), the epithelia of villi in the ileum were slightly shedding, and the lamina propria became loose because of edema, resulting in the widened gap between the intestinal epithelium and the lamina propria.

The ileum ultrastructure is presented in Figure 4. The ultrastructure of the ileum in the CON group (Figure 4A) appeared normal. They displayed closely packed microvilli of the mucosal epithelial cells and abundant organelles with normal ultrastructure located in the cytoplasm, which seems to be an enlarged endoplasmic reticulum. The CSP group (Figure 4B) also showed a normal structure, similar to that of the CON group. In the ileum of NH group, the round vesicles could easily be observed in the cytoplasm of the mucous epithelia (Figures 4C and 4D). The mitochondria in the cytoplasm became swollen and vacuolated with degenerated cristae and membranes, and some of high electron density inclusions can be found within the

mitochondria (Figure 4E), leading to greater amount of electron density (Figures 4D and 4E). At the same time, the vesicles of Golgi expanded, thereby resulting in increased vacuoles with very low electron density (Figure 4F). This ultrastructural damage was alleviated in the NSP group compared with those in the NH group. However, some broken and shed microvilli, swollen mitochondria as well as secondary lysosomes were still observed in the NSP group (Figure 4B).

Figure 5 summarized the changes of the ileal cell life cycle of the experimental birds. The amount of ileal cells in the S phase of NH group was the lowest ($P < 0.05$), concomitant with the reduction of the PI index ($P < 0.05$). However, SP promoted ileal cells into both the S and G_2M phase in the NH_3 -exposed chickens, which gave a clear indication of an effective ileum protective characteristic of SP (Supplementary Figure 1).

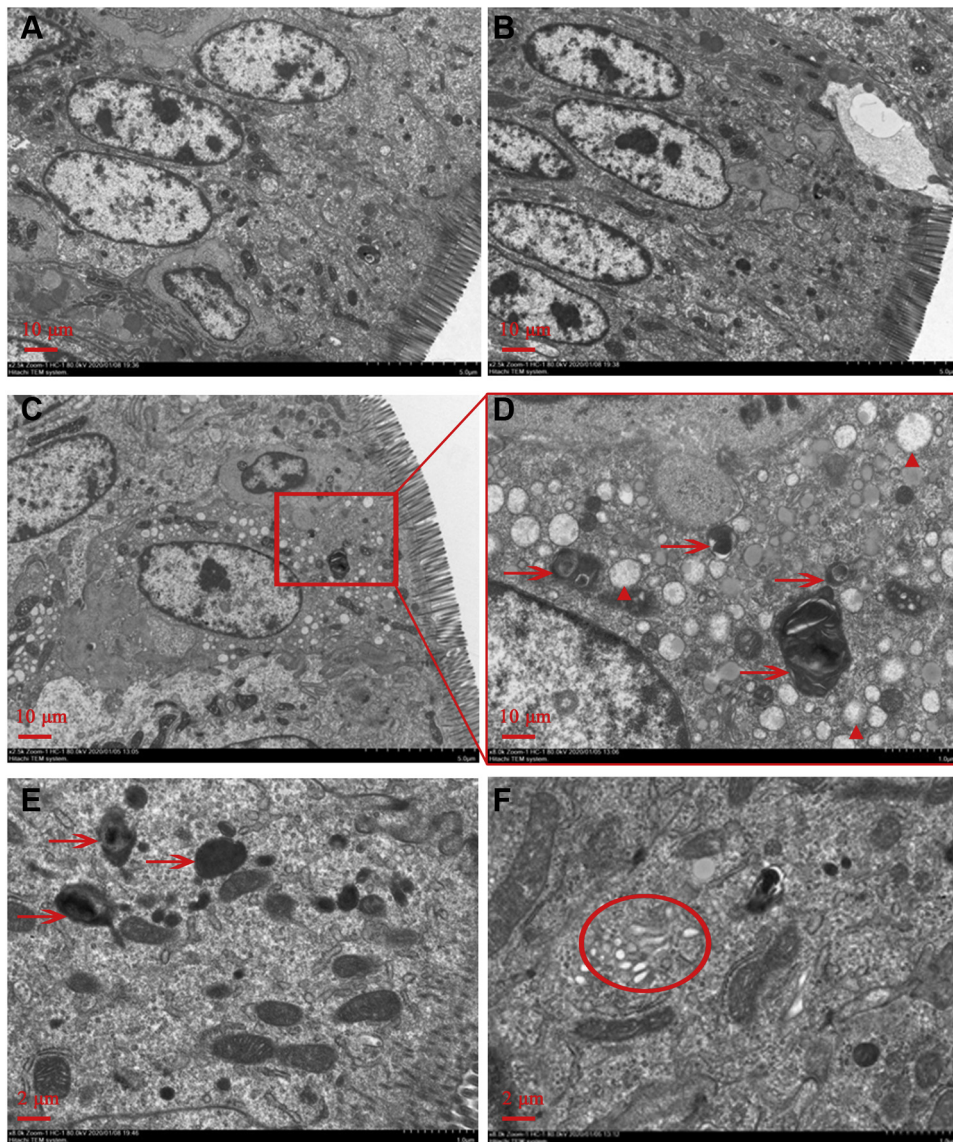


Figure 4. *Bupleurum falcatum* L saikosaponins protected mitochondria in NH_3 -exposed broilers. The ultrastructural changes of the ileum in different groups. (A) CON group, (B) NSP group, (C) NH group, scale bar = 10 μ m; (D) the enlargement of the red frame area in the image of C, (E-F) NH group, scale bar = 2 μ m. The arrows in red pointed to the mitochondrial degeneration, the triangles in red marked the vesicle, and the circle in red pointed to the expansion of Golgi vesicles. Abbreviations: CON, negative control group; NH, NH_3 -exposed group; NSP, NH_3 -exposed group + SP.

SP Protects the Epithelial Cells of Ileum of NH₃-Exposed Broilers

Regarding the total number of goblet cell (GC) (Figure 6A), results revealed that the NH group recorded the lowest count of GC in the ileum compared with other groups ($P < 0.05$). The reduction in the GC density indicated a decreased mucus secretion. The mucus secretion record (Figure 6B) in the NH group was significantly lower than that in the CON and CSP group ($P < 0.05$).

SP Modulates the Ileal Immune of NH₃-Exposed Broilers

After NH₃ exposure, the generation of sIgA and the content of T lymphocyte cell subsets in the broiler ileum are presented in Figure 6C, respectively. The NH₃ significantly decreased the sIgA values in birds ($P < 0.05$). The sIgA value in the NSP group was higher than that of the NH group ($P < 0.05$); however, it was still lower than that of the CON group ($P < 0.05$).

As shown in Figure 6, the NH group recorded the lowest CD³⁺, CD³⁺CD⁴⁺, and CD³⁺CD⁸⁺ counts in ileum compared with other groups ($P < 0.05$). Compared with the NH group, SP exhibited greater ileum immunomodulation ability via elevated levels of T lymphocyte cell subsets (NSP group), whereas the CD³⁺ and CD³⁺CD⁴⁺ content in the NSP group were still lower than those in the CON groups ($P < 0.05$). The flow cytometry quadrant diagrams were showed in Supplementary Figure 2.

SP Regulates Activities of Antioxidant Enzymes/Indices in the Ileum of NH₃-Exposed Broilers

Figure 7 showed how SP reverted the negative effects of NH₃ on the ileal antioxidant-related biochemistry. Levels of SOD, T-AOC, and GSH were reduced in the NH group compared with other groups ($P < 0.05$). Moreover, these levels in the NSP group had a remission in comparison to the NH group ($P < 0.05$). Furthermore, all the experimental groups recorded no significant differences for MDA levels, but the NH group recorded the highest level ($P > 0.05$).

Furthermore, ROS level in the ileum of the chickens was quantified to evaluate oxidative stress. As shown in Figure 7E, the ROS level in the NH group was significantly higher than that in all other groups ($P < 0.05$). Conversely, SP had a positive effect to resist oxidative stress in NH₃-exposed chickens, because NSP group recorded the lower ROS level compared with the NH group ($P < 0.05$). The flow cytometry quadrant diagrams were showed in Supplementary Figure 3.

SP Reduces Ileal Apoptosis and Protect Mitochondria in NH₃-Exposed Broilers

Figures 7F and 7G showed SP supplementation reduced ileum profound apoptosis which was stimulated by NH₃ in chickens. The highest percentage of apoptosis was found in the NH group compared with other groups ($P < 0.05$). Moreover, NH₃ caused an

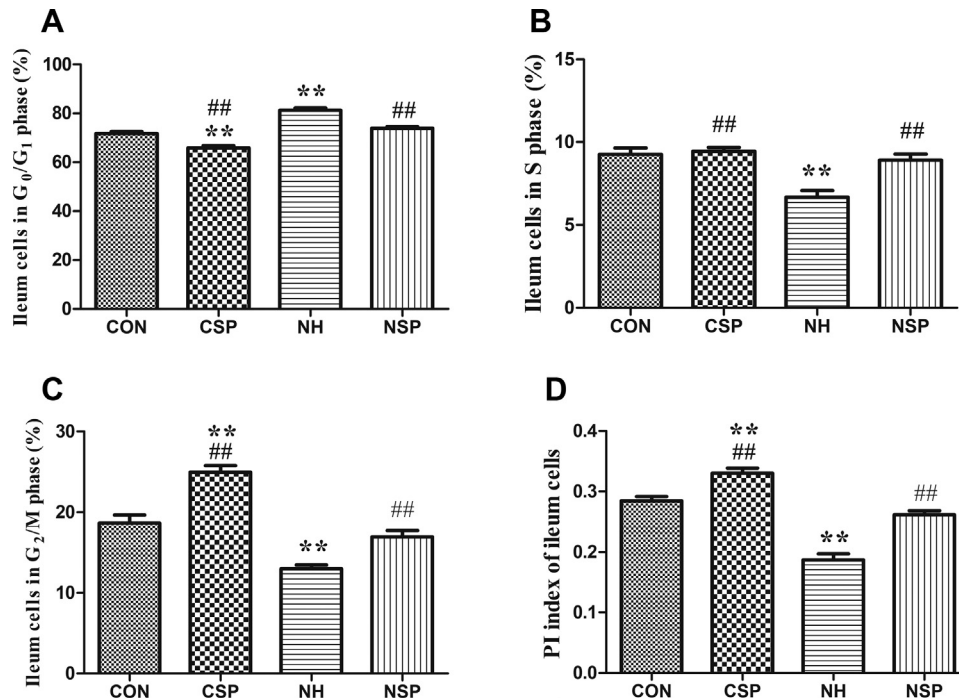


Figure 5. *Bupleurum falcatum* L saikosaponins improved the intestine development in NH₃-exposed broilers. Treatment effects on life cycle of ileal cells (A) G₀/G₁ phase (DNA pre-synthesis phase of cell life cycle, %), (B) S phase (DNA synthesis phase of cell life cycle, %), (C) G₂/M phase (prophase of division and division phase of cell life cycle, %); and (D) PI index (proliferation index). $P < 0.05$ was considered statistically significant. ** $P < 0.05$ vs. control group; ## $P < 0.05$ vs. NH₃-treated group. Abbreviations: CON, negative control group; CSP, SP control group; NH, NH₃-exposed group; NSP, NH₃-exposed group + SP.

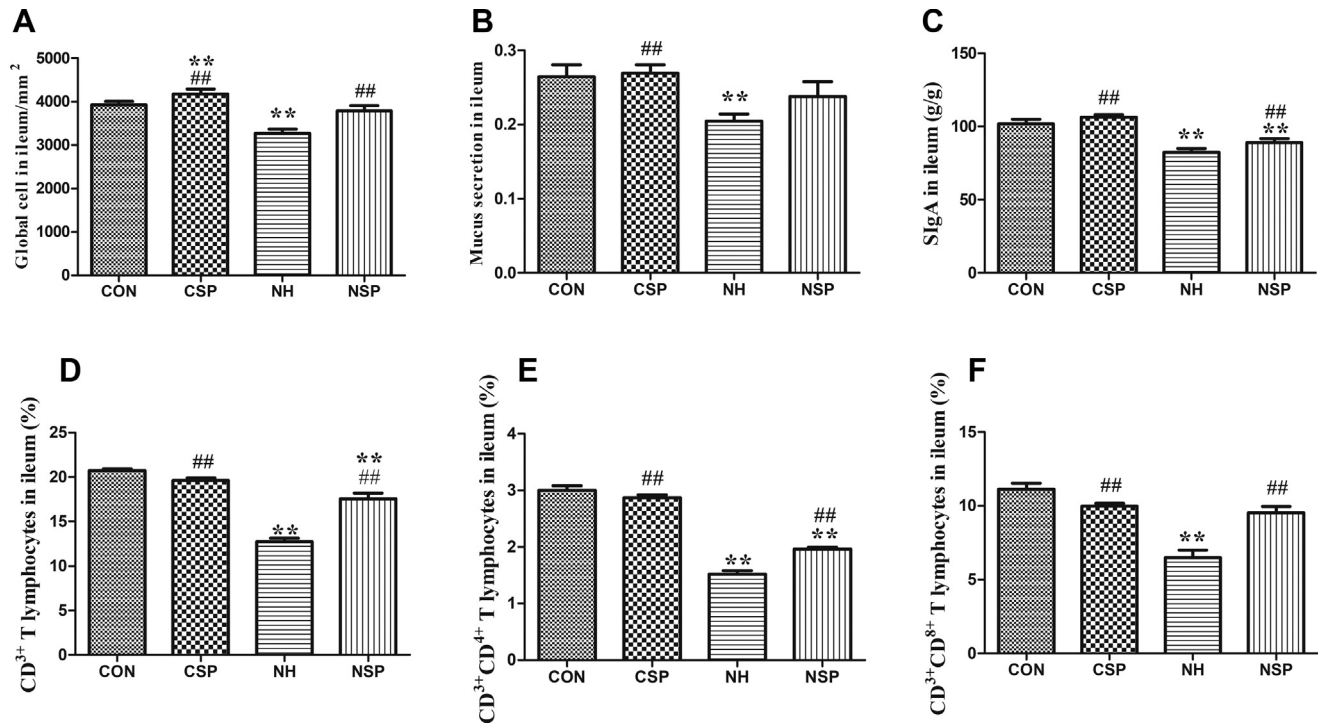


Figure 6. *Bupleurum falcatum* L saikosaponins protected the epithelial cells of ileum as well as modulated the ileal immune in NH₃-exposed broilers. The data of global cell (A) and Mucus secretion content (B) of ileum in different groups. Note: mm² was the unit area of one field under 400 × magnification. OD represented the mean optical density value. The secretory immunoglobulin A content (sIgA, g/g) of ileum in different groups (C). The T lymphocyte cell subsets (D) CD³⁺ T lymphocytes, (E) CD³⁺CD⁴⁺ peripheral T lymphocytes, (F) CD³⁺CD⁸⁺ peripheral T lymphocytes; (%) of ileum in different groups. $P < 0.05$ was considered statistically significant. $**P < 0.05$ vs. control group; $##P < 0.05$ vs. NH₃-treated group. Abbreviations: CON, negative control group; CSP, SP control group; NH, NH₃-exposed group; NSP, NH₃-exposed group + SP.

excessively higher ratio of mitochondrial depolarization in the ileum than all other groups ($P < 0.05$), whereas compared with the NH group, SP normalized mitochondrial membrane potential and resulted in a

reduction of mitochondrial depolarization ratio in the NH₃-exposed chickens (the NSP group). The flow cytometry quadrant diagrams were showed in [Supplementary Figure 4](#).

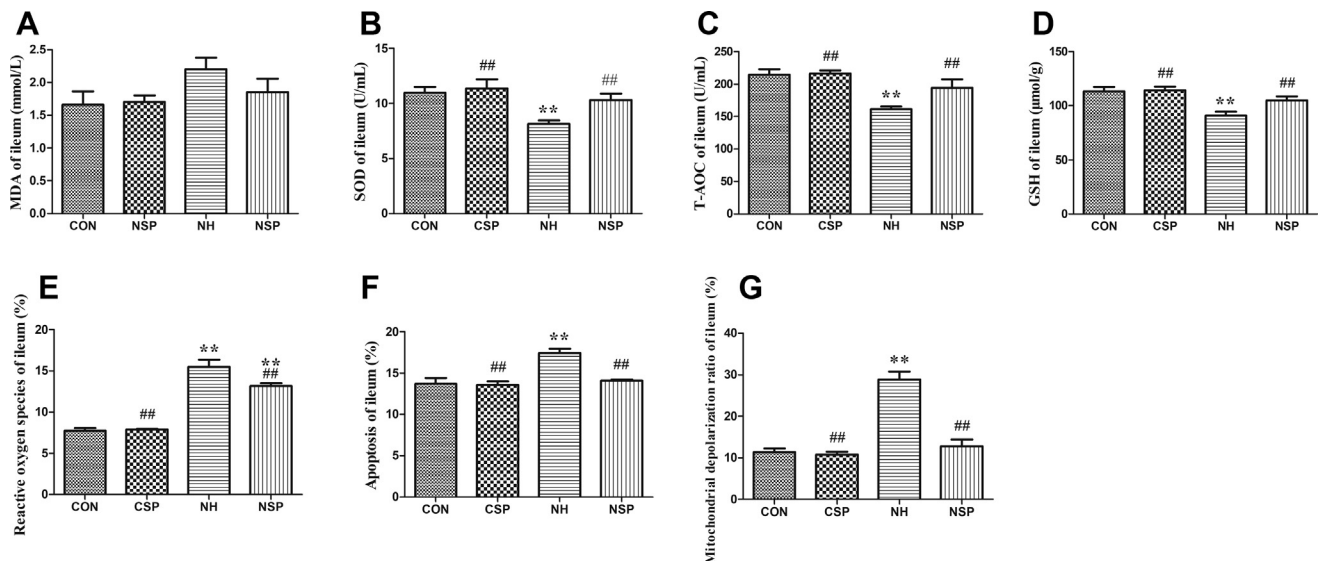


Figure 7. *Bupleurum falcatum* L saikosaponins balanced ileal antioxidant system against oxidative stress, reduced the ileal apoptosis and protected mitochondria in NH₃-exposed broilers. (A) MDA (malondialdehyde, mmol/L), (B) SOD (superoxidase dismutase, U/mL), (C) T-AOC (total antioxidant capacity, U/mL), and (D) GSH (glutathione, μmol/g), (E) Reactive oxygen species (ROS, %) generations, (F) Apoptosis, (G) Mitochondrial depolarization ratio levels of ileum in different groups. $P < 0.05$ was considered statistically significant. $**P < 0.05$ vs. control group; $##P < 0.05$ vs. NH₃-treated group. Abbreviations: CON, negative control group; CSP, SP control group; NH, NH₃-exposed group; NSP, NH₃-exposed group + SP.

SP Inhibits NH₃-Induced Ileal Damage by Regulating mRNA Expressions Associated With the Functions of Mucosal Barrier, Immunity, Oxidative Stress, and Apoptosis in Broilers

Figure 8 illustrated that NH₃ impaired mucosal barrier of ileum via downregulation of tight junction proteins (*Claudin1*, *Zo1*) and the primary secreting mucoprotein (*Muc2*) genes in comparison to the CON and CSP groups ($P < 0.05$). The SP only significantly affected *Zo1* upregulation in birds after NH₃ exposure in comparison to the NH group ($P < 0.05$). Moreover, Figure 8 summarized the changes in the expression of ileal immune-related genes. The mRNA level of *TNF- α* in NH group was the highest among all the experimental groups ($P < 0.05$), while it was mildly upregulated in the NSP group compared with CON group ($P < 0.05$). The NH group recorded lower expression of *IFN- γ* than CSP group ($P < 0.05$), comparatively. In addition, the mRNA levels of the oxidative stress-related gene *Nrf2* and *HO-1* were significantly reduced in the ileal of chickens in the NH group compared with those in all other groups ($P < 0.05$), but SP effectively increased the expressions of both *Nrf2* and *HO-1* to the same level as the CON group. Figure 8 showed the influence of NH₃ inhalation on apoptotic-related genes. In the NH group, the mRNA levels of *caspase 3*, *caspase 9*, and *Bax* were higher ($P < 0.05$), whereas the *Bcl-2* expression in the same group (NH group) was lower ($P < 0.05$) in the ileum than all other treatments. Meanwhile, the

expression of *VDAC* in NH group was the highest compared with CON and CSP groups ($P < 0.05$).

DISCUSSION

Ammonia is a highly toxic pollutant which can influence different organs and physiological functions in animals including chickens. The poultry management guidelines have set the limit of 20 ppm ammonia concentration in chicken house to protect their health and welfare (Zhang et al., 2015). Numerous evidence has demonstrated that the concentrations of NH₃ beyond the prescribed limit may impair the gastrointestinal tract by pathways of apoptosis and mitochondrial damage, causing health problems to animals (Tsuji et al., 1992; Igarashi et al., 2001). The molecular mechanisms underlying the damages caused by exogenous NH₃ on broilers' ileum remain unclear. In the current study, we examined the growth parameters, intestinal morphology and gene expression, and ileum injury in broilers exposed to excess concentration of NH₃ with or without SP supplementation. Results in this study showed that exposure to high concentrations of NH₃ can induce growth inhibition with multiple ileum injurious in broilers. In addition, our study, for the first time, confirmed that SP can protect the ileum against NH₃-induced lesion in the ileum of broilers through several pathways: (1) improving intestinal development; (2) protecting ileal mucosal barrier via immunity promotion; (3) antagonizing oxidative stress; (4) suppressing apoptosis. The

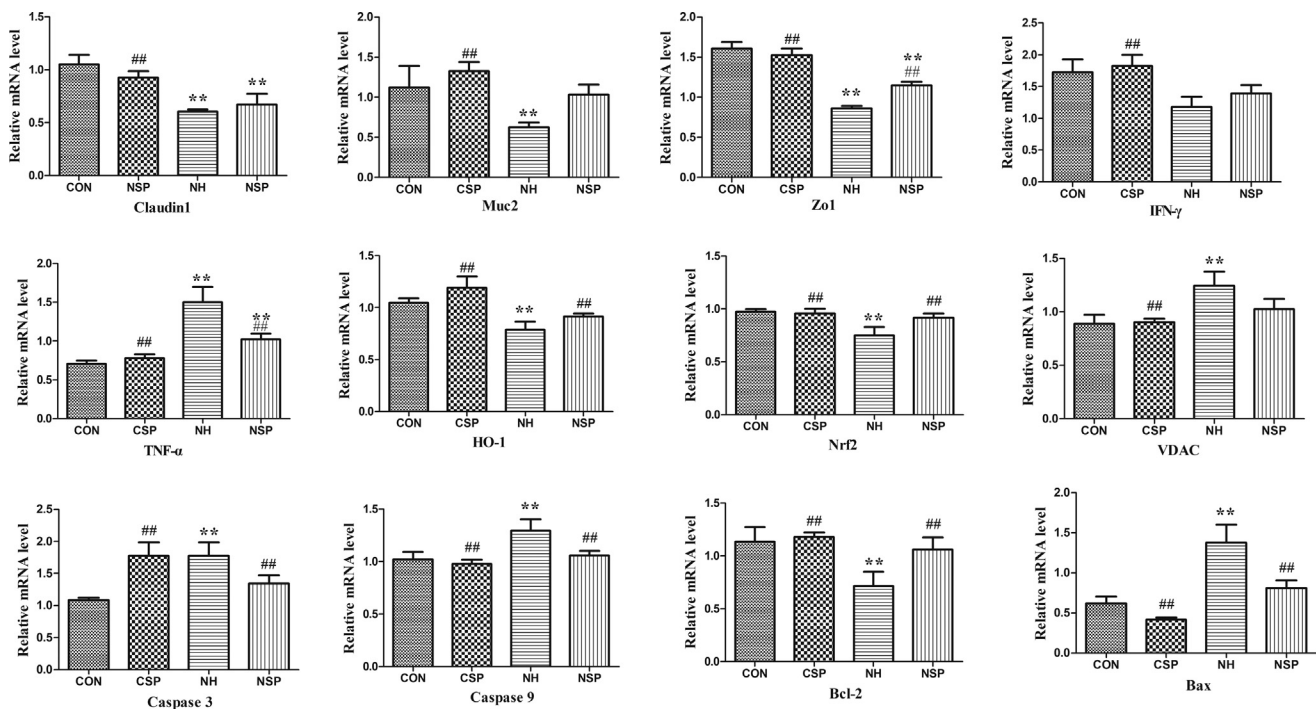


Figure 8. *Bupleurum falcatum* L saikosaponins protected ileum against NH₃-stress by regulating mRNA expression of mucosal barrier-related genes (*Claudin1*, *Muc2*, *Zo1*, *TNF- α* , *IFN- γ* , *HO-1*, *Nrf2*, *VDAC*, *Caspase 3*, *Caspase 9*, *Bax*, and *Bcl-2*) in NH₃-exposed broilers. $P < 0.05$ was considered statistically significant. * $P < 0.05$ vs. control group; ## $P < 0.05$ vs. NH₃-treated group. Abbreviations: CON, negative control group; CSP, SP control group; NH, NH₃-exposed group; NSP, NH₃-exposed group + SP.

SP have therapeutic potential against NH_3 -associated damage.

Studies have reported that high concentrations of NH_3 directly resulted in poor growth performance, low DWG and high mortality rate in poultry (Miles et al., 2004; Soliman et al., 2017). Similarly, NH_3 showed inhibitory effect on growth with lower DWG and higher FCR in our study. Moreover, supplementation of SP regained the growth performance of chickens exposed to NH_3 through enhancing DWG and reducing FCR. With regard to the pharmacological effects of SP, we hypothesized that this phenomenon may be attributed to its improvement in immune functions and inhibition of emotional disorder caused by NH_3 -stress (Li et al., 2018); however, further studies are recommended to prove this hypothesis.

In addition to the reduction of growth performance, exposure to excess concentrations of NH_3 also interfered with intestinal health of broilers. The intestinal layers, including the lining epithelium, lamina propria with gland, and lamina muscularis, maximize nutrients digestion and absorption by providing a large mucosal surface which has been studded with the intestinal villi (Hernández et al., 2006). An increase in the intestinal villus resulted in a great mucosa surface area, and the migration of proliferating crypt cells to the villi ensures the rapid renewal of the villus (Awad et al., 2009). Therefore, the height of the intestinal villus and the ratio of villus/crypt are positively related to the absorptive efficiency of the small intestine in chickens, while the crypt depth is negatively related (Geyra et al., 2001). Our study indicated that exposure to high concentrations of NH_3 exerted negative impacts on intestinal mucosal structure and development in broilers by decreasing the indices, villus height, and villus/crypt ratio of different intestinal segments, which may inhibit nutrients absorption. Interestingly, this observation is in line with previous studies (Uni et al., 2001; Zhang et al., 2015). Moreover, histopathology analysis demonstrated that NH_3 could cause shedding of the epithelia of villi in the ileum of broilers. Improvement in those morphometric variables in the NSP group suggested that SP maintained the integrity of intestinal morphology and structure to improve the intestinal development. In addition, our study also showed that NH_3 blocked the entry of ileal cells into the S and G₂/M phases, resulting in the remarkable reduction of the PI index. The loss of cell-cycle control in the NH_3 treatment represented a hallmark of severe lesion in the ileum. Comparably, the results in the NSP group indicated that SP promoted the proliferation activity of ileal cells to improve the development of ileum in the NH_3 -exposed broilers.

To further identify the mechanism by which NH_3 impaired the ileum, we examined the number of goblet cells and mucus secretion. The density of GC and relative functions in mucus synthesis and secretion are direct indicators reflecting the health status of intestinal epithelial cells of the animal, which can exert the protective activities of the mucous barrier (Taupin and

Podolsky, 2003). NH_3 reduced the total GC count as well as the mucus secretion in the ileum, by which it leads to mucous barrier dysfunction. Moreover, supplementation of SP enhanced both total GC count and mucus production as observed in our study. As yet, the underlying effect of NH_3 on the differentiation of the GC has not been clearly illustrated in broilers. The GC differentiation is associated with the mucin gene expression (Baurhoo et al., 2007) and the intestinal immunity (McDole et al., 2012). Therefore, we speculated that falling of the ileal GC count in NH group might relate to the repressed immunity in ileum. Furthermore, relative mRNA expression of ileal mucosal barrier-related genes supported this speculation, since NH_3 exposure downregulated the expression of genes which encoded tight junction proteins (Claudin1 and Zo1) and the primary secreting muco-protein (Muc2) in ileum. Previous studies suggested that reduced gene expression of tight junction proteins and Muc2 was usually associated with pathological conditions of the mucous immunity (Lee et al., 2017; Palamidi and Mountzouris, 2018). The noted increased expression of those (ileal mucosal barrier-related) genes in the NSP group could be regarded as beneficial recovery of the mucous barrier.

Generally, the intestine is the largest immune organ that continuously defends against pathogenic invasion when exposed to an array of challenges (Buchan, 1999). Hence, a damage on the potential of intestinal immunity prompts the pathological status. Zhang et al. had reported that high concentration of NH_3 impaired the adaptive immunity of the small intestine in chickens by downregulating 8 differential protein species related to immune response in chickens (Zhang et al., 2015). Similarly, our results demonstrated that NH_3 decreased the content of sIgA, T cell subsets (CD3^+ , $\text{CD3}^+\text{CD4}^+$, and $\text{CD3}^+\text{CD8}^+$), and affected the expression of cytokine profile (TNF- α and IFN- γ) in the ileum of broilers. Importantly, the status of intestinal immunity is associated with the levels of sIgA, the main immunoglobulin prohibits the entry of pathogen into subepithelial areas (Dasgupta et al., 2014), the capability of mucous T cell proliferation in response to exogenous antigens (Grewal and Flavell, 1998) as well as cytokine profile (Lee et al., 2013). In this study, the changes observed in regard to these parameters in the NSP group suggested that SP attenuated NH_3 -induced ileal immune dysfunction to protect ileal mucous barrier in NH_3 -exposed broilers, which probably inhibits or prevents inflammation and infection, leading to a greater growth rate.

Emerging evidence demonstrated that the oxidative stress is one of the extreme important factors by which the immune dysfunction is easily induced. In broilers jejunum, H_2S , a harmful gas, induces inflammatory reaction via redox homeostasis disorder (Zheng et al., 2018). In mice, oxidative stress induces immune dysfunction by upregulating the expression of proinflammatory cytokines (TNF- α , IFN- γ and the like) (Tewari et al., 2015). Based on the above studies, we revealed the immune dysfunction in the ileum caused by NH_3 might

link to the oxidative stress. Oxidation as well as reduction is a procedure for energy production, which is common to many fundamental responses of organisms. Oxidative stress disrupts the redox balance (reduction-oxidation) with high levels of ROS generation (Noctor et al., 2016). In our study, increased levels of ileal ROS and MDA along with decreased activity of ileal antioxidant compounds (SOD, T-AOC, and GSH) were observed in the NH group, which revealed that oxidative stress has been induced in NH₃-exposed broilers (Zhang et al., 2015). NH₃-induced oxidative stress was also revealed by the downregulation of the Nrf2/HO-1 pathway. Nrf2/HO-1 pathway plays a crucial function in stress-protection, which exerts beneficial effects through inhibiting oxidative injury, regulating apoptosis as well as modulating inflammation (Loboda et al., 2016). Specifically, the results obtained in this study showed a marked decrease in the expression of Nrf2 and HO-1 genes following NH₃ treatment, suggesting that NH₃ could break down the redox homeostasis and cause oxidative stress in the broiler ileum. Moreover, SP in broilers can restore ileal antioxidative status by directly scavenging ROS and attenuating NH₃-induced disturbances in cellular redox state.

Apoptosis is another adverse effect induced by oxidative stress in organisms, whereas excessive ROS promotes cell degradation and death (Zhu et al., 2013). Igarashi et al. reported that excess concentration of NH₃ initiates apoptosis by oxidative stress pathway (Igarashi et al., 2001). Our study corroborated with the previous study, suggesting that NH₃ exposure significantly elevated the incidence of apoptosis via redox homeostasis disorder in the ileum of broilers. Mitochondrion not only functioned in producing ATP but also involved in controlling cell death processes, including apoptosis (Borutaite, 2010). Once the free radicals attack mitochondrion, the mitochondrial transmembrane potential collapses, which elevates the ratio of mitochondrial depolarization, a sensitive index used in evaluating mitochondrial function. Loss of transmembrane potential in cells is considered as a major determinant of apoptosis (Gao et al., 2012; Sinha et al., 2013). Therefore, the microstructural and functional integrity of the mitochondria is important in resisting apoptosis and maintaining the normal function of cells. This study revealed that NH₃-induced cytotoxicity damaged the integrity of the mitochondria and further increased mitochondrial depolarization ratio, which resulted in an increased apoptosis. In addition, the expression of mitochondrial porin *VDAC*, which is in positive correlation with the mitochondria-mediated apoptosis, was upregulated in the NH₃ group. The outcome further indicated that NH₃ aroused apoptosis in the ileum by damaging mitochondrion. Again, this study revealed that SP exerted protective effect against NH₃-induced ileal injury and reduced incidence of apoptosis by the inhibition of oxidative stress and protection of mitochondrion.

The mitochondrial dysfunction leading to disorders of energy generation might be an explanation of the poor growth performance observed in NH₃-exposed broilers (Zhang et al., 2015). The mRNA expressions of the 4

apoptosis-related biomarkers (caspase 3, caspase 9, Bax and Bcl-2) were examined. Caspase family is essentially involved in cell apoptosis, such that caspase 3 and caspase 9 are the 2 downstream effectors involved in death-receptor pathway of apoptosis, and their activation commits the cells to apoptosis (Zhu et al., 2012). Bcl-2 is an antiapoptotic protein, whereas Bax protein plays a proapoptotic effect; they together participate in the control of apoptosis (Gobé et al., 2002). Upregulation of caspase 3, caspase 9, and Bax along with downregulation of Bcl-2 in the NH₃ treatment group was correlated with the high incidence of apoptosis in the ileum. Integrating with our previous results, it showed that NH₃ could trigger ileum apoptosis from variety of pathways. Therefore, antiapoptotic therapy may be beneficial for the NH₃-associated damage. Our results also demonstrated that SP blocked NH₃-induced apoptosis by regulating caspase 3, caspase 9, Bax, and Bcl-2 to normal physiological levels. However, further studies are required to elucidate specific signal pathways, especially the inflammation pathway.

CONCLUSION

In this study, reduced growth rate was observed in NH₃-exposed broilers, and it may be relevant with the intestinal health status. The SP showed a positive effect on anti-NH₃ damage via alleviating growth inhibition and intestinal lesions. Collectively, the current study indicated that exposure to high concentrations of ambient NH₃ causes poor development of the small intestine and ileum injury in broilers. These impacts might be resulted from the NH₃-induced oxidative stress along with the immune dysfunction and apoptosis because the mRNA levels of genes related to mucosal barrier, immune, oxidative stress, and apoptosis were upregulated in NH₃ exposed broilers. In addition, this study identified the potential mechanisms underlying the SP protective functions in the NH₃-exposed broilers. The SP effectively promote intestinal development, modulate the immunity of the ileum, and potentially block the apoptosis by exerting antioxidant and mitochondrial protective effects. This study provides new information about pathways of NH₃ impacting broiler health and reveals that SP could be a potential feed additive to defense against NH₃ damage in chickens.

ACKNOWLEDGMENTS

The authors would like to thank Prof. Hengwei Cheng from Department of Animal Sciences, Purdue University, USA, for his great comments on this paper. This work was supported by the [National Natural Science Foundation of China] under Grant [number 31872347] and the [National Key Research and Development Program of China] under Grant [number 2016YFD05005504], and the funders conceived and designed the experiments, also purchased all the test consumables. There is no competing interest.

DISCLOSURES

There is no competing interest.

SUPPLEMENTARY DATA

Supplementary data associated with this article can be found in the online version at <https://doi.org/10.1016/j.psj.2020.10.057>.

REFERENCES

- Aardenne, J. V., F. Dentener, J. Oliver, C. G. M. K. Goldewijk, and J. Lelieveld. 2001. A $1^\circ \times 1^\circ$ resolution data set of historical anthropogenic trace gas emissions for the period 1890–1990. *Glob. Biogeochem. Cycles* 15:909–928.
- Awad, W. A., K. Ghareeb, S. Abdel-Raheem, and J. Böhm. 2009. Effects of dietary inclusion of probiotic and synbiotic on growth performance, organ weights, and intestinal histomorphology of broiler chickens. *Poult. Sci.* 88:49–56.
- Awad, W. A., A. Molnár, J. R. Aschenbach, K. Ghareeb, B. Khayal, C. Hess, D. Liebhart, K. Dublec, and M. Hess. 2015. *Campylobacter* infection in chickens modulates the intestinal epithelial barrier function. *Innate Immun.* 21:151–160.
- Benito, P. B., M. J. A. Martínez, A. M. S. Sen, A. S. Gómez, L. F. Matellano, S. S. Contreras, and A. M. D. Lanza. 1998. In vivo and in vitro anti-inflammatory activity of saikosaponins. *Life Sci.* 63:1147–1156.
- Buchan, A. M. 1999. Nutrient Tasting and signaling mechanisms in the gut III. Endocrine cell recognition of luminal nutrients. *Am. J. Physiol.* 277:922–928.
- Baurhoo, B., L. Phillip, and C. A. Ruiz-Feria. 2007. Effects of Purified Lignin and Mannan Oligosaccharides on intestinal integrity and Microbial Populations in the Ceca and Litter of broiler chickens. *Poult. Sci.* 86:1070–1078.
- Borutaite, V. 2010. Mitochondria as decision-makers in cell death. *Environ. Mol. Mutagen.* 51:406–416.
- Bai, S., C. He, K. Zhang, X. Ding, Q. Zeng, J. Wang, H. Peng, J. Bai, H. Lu, Y. Xuan, and Z. Su. 2020. Effects of dietary inclusion of Radix Bupleuri and Radix Astragali extracts on the performance, intestinal inflammatory cytokines expression, and hepatic antioxidant capacity in broilers exposed to high temperature. *Anim. Feed Sci. Technol.* 259:1–12.
- Chiang, L., L. T. Ng, L. Liu, D. Shieh, and C. Lin. 2003. Cytotoxicity and anti-Hepatitis B Virus activities of saikosaponins from Bupleurum species. *Planta Med.* 69:705–709.
- Chang, J., K. Wang, H. Liu, M. Chen, L. Chiang, and C. Lin. 2007. Sho-saiko-to (Xiao-Chai-Hu-Tang) and Crude saikosaponins inhibit hepatitis B Virus in a stable HBV-producing cell line. *Am. J. Chin. Med.* 35:341–351.
- Cheng, P., L. Ng, L. Chiang, and C. Lin. 2010. Antiviral effects of saikosaponins on human coronavirus 229E in vitro. *Clin. Exp. Pharmacol. Physiol.* 33:612–616.
- Dasgupta, S., D. E. Hasdemir, J. O. Reparaz, H. Reinecker, and D. L. Kasper. 2014. Plasmacytoid dendritic cells mediate anti-inflammatory responses to a gut Commensal molecule via both Innate and adaptive mechanisms. *Cell Host Microbe* 15:413–423.
- David, B., C. Mejdell, V. Michel, V. Lund, and R. O. Moe. 2015. Air quality in Alternative housing systems may have an impact on laying hen welfare. Part II—Ammonia. *Animals (Basel)* 5:886–896.
- Grewal, I. S., and R. A. Flavell. 1998. CD40 and CD154 in cell-mediated immunity. *Annu. Rev. Immunol.* 16:111–135.
- Geyra, A., Z. Uni, and D. Sklan. 2001. Enterocyte Dynamics and mucosal development in the Posthatch Chick. *Poult. Sci.* 80:776–782.
- Gobé, G., M. Rubin, G. Williams, I. Sawczuk, and R. Buttyan. 2002. Apoptosis and expression of Bcl-2, Bcl-XL, and Bax in renal cell Carcinomas. *Cancer Invest* 20:324–332.
- Gao, Z., X. Kang, J. Hu, Y. Ju, and C. Xu. 2012. Induction of apoptosis with mitochondrial membrane depolarization by a glycyrrhetic acid derivative in human leukemia K562 cells. *Cyto-technology* 64:421–428.
- Ghareeb, K., W. A. Awad, J. Böhm, and Q. Zebeli. 2015. Impacts of the feed contaminant deoxynivalenol on the intestine of mono-gastric animals: poultry and swine. *J. Appl. Toxicol.* 35:327–337.
- Guo, Y. 2017. Isolation and identification of the respiratory tract bacteria in broilers under NH₃ stress. *Heilongjiang Anim. Husbandry Vet.* 96-98:249, 000.
- Hernández, F., V. García, J. Madrid, J. Orenge, P. Catalá, and M. D. Megías. 2006. Effect of formic acid on performance, digestibility, intestinal histomorphology and plasma metabolite levels of broiler chickens. *Br. Poult. Sci.* 47:50–56.
- Igarashi, M., Y. Kitada, H. Yoshiyama, A. Takagi, T. Miwa, and Y. Koga. 2001. Ammonia as an Accelerator of tumor necrosis factor Alpha-induced apoptosis of gastric epithelial cells in *Helicobacter pylori* infection. *Infect. Immun.* 69:816–821.
- Kers, J. G., F. C. Velkers, E. A. J. Fischer, G. D. A. Hermes, J. A. Stegeman, and H. Smidt. 2018. Host and environmental factors affecting the intestinal microbiota in chickens. *Front Microbiol.* 9:235.
- Lee, K. W., H. S. Lillehoj, S. I. Jang, S. H. Lee, D. A. Bautista, and G. R. Siragusa. 2013. Effect of Bacillus Subtilis-based direct-fed Microbials on immune status in broiler chickens Raised on Fresh or used Litter. *Asian-Australas. J. Anim. Sci.* 26:1592–1597.
- Luo, J., A. Zheng, K. Meng, W. Chang, Y. Bai, K. Li, H. Cai, G. Liu, and B. Yao. 2013. Proteome changes in the intestinal mucosa of broiler (*Gallus gallus*) activated by probiotic *Enterococcus faecium*. *J. Proteomics* 91:226–241.
- Loboda, A., M. Damulewicz, E. Pyza, A. Jozkowicz, and J. Dulak. 2016. Role of Nrf2/HO-1 system in development, oxidative stress response and diseases: an evolutionarily conserved mechanism. *Cell. Mol. Life Sci.* 73:3221–3247.
- Lee, Y., S. Lee, U. D. Gadde, S. Oh, S. Lee, and H. S. Lillehoj. 2017. Dietary Allium hookeri reduces inflammatory response and increases expression of intestinal tight junction proteins in LPS-induced young broiler chicken. *Res. Vet. Sci.* 112:149–155.
- Li, R., J. Fu, X. Lyu, Z. Gao, H. Wang, and J. Wang. 2017. Saikosaponins-b suppresses tumor growth and angiogenesis of hepatocellular carcinoma by regulating VEGF/ERK/HIF-1 α signal pathway. *Zhongguo Yaolixue Yu Dulixue Zazhi* 31:962–963.
- Li, X., Y. Song, S. Wang, K. Rahman, J. Zhu, and H. Zhang. 2018. Saikosaponins: a review of pharmacological effects. *J. Asian Nat. Prod. Res.* 20:399–411.
- Lin, S., D. Xu, X. Du, C. Ran, and G. Shu. 2019. Protective effects of Salidroside against Carbon Tetrachloride (CCl₄)-induced liver injury by initiating mitochondria to resist oxidative stress in mice. *Int. J. Mol. Sci.* 20:3187.
- Miles, D., S. L. Branton, and B. D. Lott. 2004. Atmospheric ammonia is detrimental to the performance of modern Commercial broilers. *Poult. Sci.* 83:1650–1654.
- Ma, H., F. Wu, S. Han, C. Zheng, J. Li, and J. Bao. 2012. Analgesia and anti-stress effect of two groups of traditional Chinese medicine on mice. *Xiandai Yufang Yixue* 39:2797–2798.
- McDole, J. R., L. W. Wheeler, K. G. McDonald, B. Wang, V. Konjufca, K. A. Knoop, R. D. Newberry, and M. J. Miller. 2012. Goblet cells deliver luminal antigen to CD103+ dendritic cells in the small intestine. *Isr. Med. Assoc. J.* 483:345–349.
- Olanrewaju, H. A., J. P. Thaxton, W. A. Dozier, J. Purswell, S. D. Collier, and S. L. Branton. 2008. Interactive effects of ammonia and light intensity on Hematochemical variables in broiler chickens. *Poult. Sci.* 87:1407–1414.
- Noctor, G., A. Mhamdi, and C. H. Foyer. 2016. Oxidative stress and antioxidative systems: recipes for successful data collection and interpretation. *Plant Cell Environ.* 39:1140–1160.
- Naseem, S., and A. J. King. 2018. Ammonia production in poultry houses can affect health of humans, birds, and the environment—techniques for its reduction during poultry production. *Environ. Sci. Pollut. Res.* 25:15269–15293.
- Pesti, G. M. 1995. Nutrient requirements of poultry. *Anim. Feed Sci. Technol.* 56:177–178.
- Pan, L., D. P. Bu, J. Q. Wang, J. B. Cheng, X. Z. Sun, L. Y. Zhou, J. J. Qin, X. K. Zhang, and Y. M. Yuan. 2014. Effects of Radix Bupleuri extract supplementation on lactation performance and rumen fermentation in heat-stressed lactating Holstein cows. *Anim. Feed Tech.* 187:1–8.
- Palamidi, I., and K. C. Mountzouris. 2018. Diet supplementation with an organic acids-based formulation affects gut microbiota and expression of gut barrier genes in broilers. *Anim. Nutr.* 4:33–43.

- Quarles, C. L., and H. F. Kling. 1974. Evaluation of ammonia and infectious Bronchitis Vaccination stress on broiler performance and carcass quality. *Poult. Sci.* 53:1592–1596.
- Sinha, K., J. Das, P. B. Pal, and P. C. Sil. 2013. Oxidative stress: the mitochondria-dependent and mitochondria-independent pathways of apoptosis. *Arch. Toxicol.* 87:1157–1180.
- Soliman, E. S., S. A. Moawed, and R. A. Hassan. 2017. Influence of microclimatic ammonia levels on productive performance of different broilers' breeds estimated with univariate and multivariate approaches. *Vet. World* 10:880–887.
- Tsujii, M., S. Kawano, S. Tsuji, H. Fusamoto, T. Kamada, and N. Sato. 1992. Mechanism of gastric mucosal damage induced by ammonia. *Gastroenterology* 102:1881–1888.
- Taupin, D., and D. K. Podolsky. 2003. Trefoil factors: initiators of mucosal healing. *Nat. Rev. Mol. Cell Biol.* 4:721–732.
- Tsai, Y., I. L. Chen, L. Y. Horng, and R. T. Wu. 2010. Induction of differentiation in rat C6 glioma cells with saikosaponins. *Phytother. Res.* 16:117–121.
- Tewari, P., R. Roy, S. Mishra, P. Mandal, A. Yadav, B. P. Chaudhari, R. K. Chaturvedi, P. D. Dwivedi, A. Tripathi, and M. Das. 2015. Benzanthrone induced immunotoxicity via oxidative stress and inflammatory mediators in Balb/c mice. *Immunobiology* 220:369–381.
- Tao, Z., W. Xu, C. Zhu, S. Zhang, Z. Shi, W. Song, H. Liu, and H. Li. 2019. Effects of ammonia on intestinal microflora and productive performance of laying ducks. *Poult. Sci.* 98:1947–1959.
- Uni, Z., O. Gal-Garber, A. Geyra, D. Sklan, and S. Yahav. 2001. Changes in growth and function of Chick small intestine epithelium due to Early Thermal conditioning. *Poult. Sci.* 80:438–445.
- Wathes, C. M., C. D. Jones, and A. J. Webster. 1984. Ventilation, air hygiene and animal health. *Vet. Rec.* 113:554–559.
- Wei, F., B. Xu, X. Hu, S. Li, F. Liu, Q. Sun, Y. Jiao, and L. Wang. 2012. The effect of ammonia and humidity in poultry houses on intestinal morphology and function of broilers. *J. Anim. Vet. Adv.* 11:3641–3646.
- Wei, F. X., X. F. Hu, B. Xu, M. H. Zhan, S. Y. Li, Q. Y. Sun, and P. Lin. 2015. Ammonia concentration and relative humidity in poultry houses affect the immune response of broilers. *Gmr, Genet. Mol. Res.* 14:3160–3169.
- Wang, F., Z. Zuo, K. Chen, C. Gao, Z. Yang, S. Zhao, J. Li, H. Song, X. Peng, J. Fang, H. Cui, P. Ouyang, Y. Zhou, G. Shu, and B. Jing. 2018. Histopathological injuries, ultrastructural changes, and Depressed TLR expression in the small intestine of broiler chickens with Aflatoxin B1. *Toxins (Basel)* 10:131.
- Xiong, Y., X. Tang, Q. Meng, and H. Zhang. 2016. Differential expression analysis of the broiler tracheal proteins responsible for the immune response and muscle contraction induced by high concentration of ammonia using iTRAQ-coupled 2D LC-MS/MS. *Sci. China: Life Sci.* 59:1166–1176.
- Xing, H., S. Luan, Y. Sun, R. Sa, and H. Zhang. 2016. Effects of ammonia exposure on carcass traits and fatty acid composition of broiler meat. *Anim. Nutr.* 2:34–39.
- Zhu, L., H. Yuan, C. Guo, Y. Lu, S. Deng, Y. Yang, Q. Wei, L. Wen, and Z. He. 2012. Zearalenone induces apoptosis and necrosis in porcine granulosa cells via a caspase-3- and caspase-9-dependent mitochondrial signaling pathway. *J. Cell. Physiol.* 227:1814–1820.
- Zhu, W., M. Li, C. Liu, J. Qu, Y. Min, S. Xu, and S. Li. 2013. Avermectin induced liver injury in pigeon: mechanisms of apoptosis and oxidative stress. *Ecotoxicol. Environ. Saf.* 98:74–81.
- Zhang, J., C. Li, X. Tang, Q. Lu, R. Sa, and H. Zhang. 2015. Proteome changes in the small intestinal mucosa of broilers (*Gallus gallus*) induced by high concentrations of atmospheric ammonia. *Proteome Sci.* 13:9.
- Zhang, Q., W. Huang, Y. Gao, Z. Han, W. Zhang, Z. Zhang, and F. Xu. 2018. Metabolomics reveals the efficacy of caspase inhibition for saikosaponin D-induced Hepatotoxicity. *Front. Pharmacol.* 9:732.
- Zheng, S., X. Jin, M. Chen, Q. Shi, and H. Zhang. 2018. Hydrogen sulfide exposure induces jejunum injury via CYP450s/ROS pathway in broilers. *Chemosphere* 214:25–34.