



Lumbosacral agenesis in a cat

Gabrielle C Hybki¹, Lisa A Murphy², Joseph P Marchi¹,
 Jeffrey E Patlogar¹, Jennifer O Brisson³ and
 Reid K Nakamura¹

Journal of Feline Medicine and Surgery
Open Reports
 1–3

© The Author(s) 2016
 Reprints and permissions:
sagepub.co.uk/journalsPermissions.nav
 DOI: 10.1177/2055116916628555
jfmsopenreports.com



Abstract

Case summary Lumbosacral agenesis is a rare congenital condition reported in children. We report a 17-week-old female domestic shorthair cat with lumbosacral agenesis on whole-body radiographs. The cat was euthanized shortly thereafter presentation. A necropsy was not permitted.

Relevance and novel information This is the first reported feline case of lumbosacral agenesis.

Accepted: 21 December 2015

Introduction

Lumbosacral agenesis (LSA) is a rare congenital condition found in people, where segments of the lumbar spine are missing with total or partial absence of the sacrum.^{1–4} The exact etiology is unknown, although several theories exist, including a potential association with maternal insulin-dependent diabetes, inherited genetic mutations and failure of certain mechanisms of embryonic differentiation of parts of the vertebral column.^{3,4} The purpose of this case report is to describe a clinical feline case of LSA.

Case description

A 17-week-old female intact domestic shorthair cat presented on emergency for acute onset of lethargy and open-mouth breathing. The owner had adopted the cat at approximately 2 weeks of age from the local shelter. The physical condition of the parents or any littermates was unknown. The cat was paralyzed in the hind end with severe muscle wasting in both hindlimbs and ankylotic joints. The owner reported that other than hindlimb paralysis the cat was bright, alert and responsive, and appeared otherwise normal. The cat ambulated quite well on the forelimbs, urinated and defecated regularly, and always ate well. Approximately 2 days prior to presentation, the cat became lethargic and lost its appetite. The cat was taken to its regular veterinarian, who identified a left-sided inguinal hernia and the cat was given 20 ml/kg of a balanced crystalloid solution subcutaneously (SC), maropitant 1 mg/kg SC, a warm soapy enema and

was scheduled for surgical repair of the hernia. The cat declined rapidly at home and presented on emergency for lethargy and open-mouth breathing. Physical examination on presentation revealed dull mentation, open-mouth breathing and cyanotic mucous membranes. The cat's heart rate was 200 beats per minute, with no identifiable heart murmur and the lungs were clear. The hindlimbs were noted to be ankylotic and have severe muscle wastage; they were crossed behind the body with no attempts at ambulation. Abdominal palpation revealed a very large and distended firm colon with feces. The visible external genitalia appeared normal, but there was poor anal tone and no movement of the tail. Whole body radiographs were performed (Figure 1a, b). There was visible malformation of ribs 12 and 13, as well as of the first and second lumbar vertebrae. There was no evidence of any other lumbar or sacral vertebrae. There was a large colon distended with feces with a left inguinal hernia and possible bowel entrapment. The kidneys were not visible radiographically. Shortly after

¹Inland Valley Veterinary Specialists and Emergency Center, Upland, CA, USA

²Oradell Animal Hospital, Paramus, NJ, USA

³Massachusetts Veterinary Referral Hospital, Woburn, MA, USA

Corresponding author:

Reid K Nakamura DVM, DACVECC, DACVIM (Cardiology), Inland Valley Veterinary Specialists and Emergency Center, 10 West 7th Street, Upland, CA 91786, USA
 Email: r.kiyoshi.nakamura@gmail.com



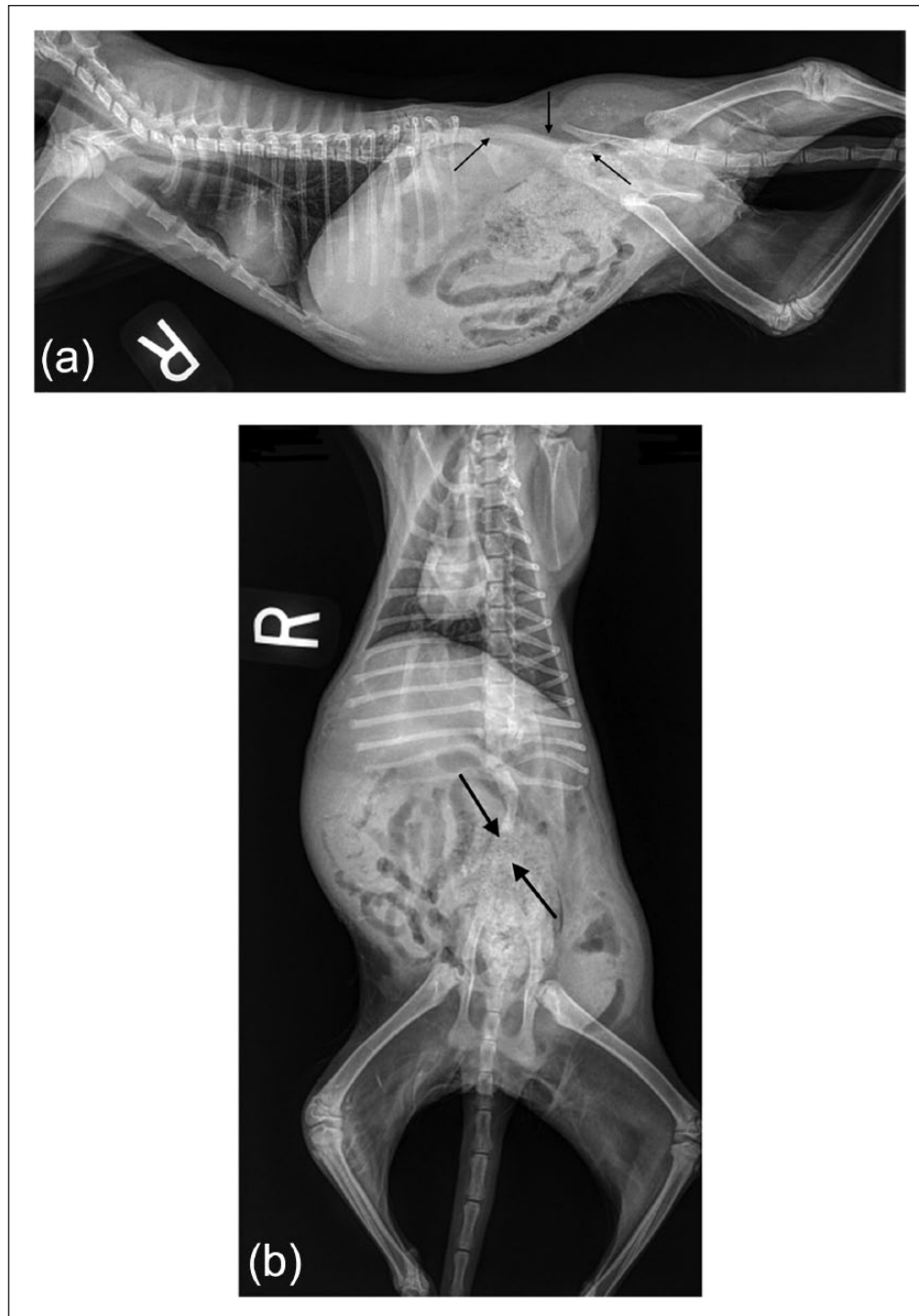


Figure 1 (a) Lateral and (b) ventrodorsal whole-body radiographic projection. There is visible malformation of ribs 12 and 13, as well as of the first and second lumbar vertebrae. There is no evidence of any other lumbar or sacral vertebrae as indicated by the arrows. There is a large colon distended with feces with a left inguinal hernia and possible bowel entrapment. The kidneys were not visible radiographically

radiographs were performed the cat became agonal and had an episode of respiratory arrest. Owing to the significant pre-existing congenital malformations, the owner elected euthanasia. A necropsy was declined.

Discussion

LSA is a rare malformation occurring in approximately 1 of 25,000 live births in people.³ It is part of a group of

disorders characterized by the absence of different portions of the caudal spine, otherwise known as caudal regression syndrome.³ Newborn children exhibit similar physical examination findings to those found in this case, with severe hindlimb muscle atrophy most common. Concurrent malformations in children include hydrocephalus, myelomeningocele, kidney malformations, inguinal hernia, atresi ani, rectovaginal fistulas

and congenital heart defects. Concurrent orthopedic abnormalities include cervical vertebral fusion particularly at C2–C3, malformed ribs, hemivertebrae and kyphosis.^{3,4} The cat in the case reported here had a left inguinal hernia with possible bowel entrapment, no visible kidneys radiographically, and malformed ribs 12 and 13. To the owner, the cat appeared to be neurologically normal in the cranial body but an occult neurological defect cannot be completely ruled out. Other intra-abdominal abnormalities may have been present but, owing to the absence of a necropsy, not identified.

LSA is classified into four types, based on the extent of malformation.^{5,6} Type I is total or partial unilateral sacral agenesis. Type II involves partial sacral agenesis with a partial but bilaterally symmetrical defect and a stable articulation between the ilia and a normal or hypoplastic first sacral vertebra. Type II is the most commonly identified form in children. Type III is variable lumbar and total sacral agenesis with the ilia articulating with the sides of the lowest vertebra. Finally, type IV is variable lumbar and a total sacral agenesis. Considering this human classification as there is no veterinary classification available, the cat presented in this report would be classified as type IV.^{5,6}

Treatment in children involves either amputation of the lower extremities and long-term prosthesis or spinal pelvic fusion.^{3,4,7} Many children will still have some proprioception in their lower extremities so correction of limb deformities is also pursued in some.

Although LSA has never been reported in any veterinary species, the malformed cat shared several important lesions with perosomus elumbis (PE), which has been documented in various species.^{8–15} In animals with PE the hindlimbs have severe muscle wastage and the joints are ankylotic owing to the absence of nervous innervation from the absence of the coccygeal, sacral and portions of the lumbar vertebrae.^{8–15} This is in contrast to LSA, where patients only have agenesis of the lumbar and sacral portions of the spine.^{1–4} Abdominal abnormalities identified in both PE and LSA include atresia ani, cryptorchidism, renal abnormalities and hernias.^{1–4,8–15} However, PE can lead to altered pelvic bone structure, with the pubic bone sometimes being absent, leading to pelvic narrowing;^{11,13} this does not occur in people with LSA.

The long-term prognosis of caudal spinal malformations is usually poor as most animals are stillborn or die shortly after birth.^{9,11,12,14} The cat reported herein lived longer than similar reported cases in the veterinary literature; the previous reported longest survival was 12 days in a Holstein calf with PE.¹⁶ It is unclear what caused the sudden demise of the cat but, as in PE, it appears the identification of LSA in a cat warrants a poor prognosis.

Conclusions

We report the first identification of LSA in the cat. The clinical presentation in this cat is similar to PE reported in other species and, as in other species, the prognosis for caudal spinal vertebral malformations appears poor.

Funding The authors received no financial support for the research, authorship, and/or publication of this article.

Conflict of interest The authors declared no potential conflicts of interest with respect to the research, authorship, and/or publication of this article.

References

- 1 Harlow CL, Partington MD and Thieme GA. **Lumbosacral agenesis: clinical characteristics, imaging and embryogenesis.** *Pediatr Neurosurg* 1995; 23: 140–147.
- 2 Bohring A, Lewin SO, Reynolds JF, et al. **Polytopic anomalies with agenesis of the lower vertebral column.** *Am J Med Genet* 1999; 87: 99–114.
- 3 Joshi M and Yadav S. **Lumbosacral agenesis.** *Indian J Radiol Imaging* 2005; 15: 251–254.
- 4 Gullie JT, Benevides R, DeAlba CC, et al. **Lumbosacral agenesis: a new classification correlating spinal deformity and ambulatory potential.** *J Bone Joint Surgery Am* 2002; 84: 32–38.
- 5 Igelzi RJ and Lehman RA. **Lumbosacral agenesis: management and embryological implications.** *J Neurol Neurosurg Psychiatry* 1974; 37: 1273–1276.
- 6 Dumont CE, Damsin JP, Forin V, et al. **Lumbosacral agenesis. Three cases of reconstruction using Cotrel-Dubousset or L-rod instrumentation.** *Spine (Phila Pa 1976)* 1993; 18: 1229–1235.
- 7 Rieger MA, Hall JE and Dalury DF. **Spinal fusion in a patient with lumbosacral agenesis.** *Spine (Phila Pa 1976)* 1990; 15: 1382–1384.
- 8 Bezek DM, Williams JF and Biller DS. **What is your diagnosis? Perosomus elumbis in a bovine fetus.** *J Am Vet Med Assoc* 1994; 205: 1685–1686.
- 9 Jones CJ. **Perosomus elumbis (vertebral agenesis and arthrogryposis) in a stillborn Holstein calf.** *Vet Pathol* 1999; 36: 64–70.
- 10 Dennis SM. **Perosomus elumbis in sheep.** *Aust Vet J* 1975; 51: 135–136.
- 11 Gerhauser I, Geburek F and Wohlsein P. **Perosomus elumbis, cerebral aplasia, and spina bifida in an aborted thoroughbred foal.** *Res Vet Sci* 2012; 92: 266–268.
- 12 Castro MB, Szabo MP, Hokamura HK, et al. **Perosomus elumbis in a Holstein calf in Brazil.** *Vet Rec* 2003; 152: 753.
- 13 Avedillo LJ and Camon J. **Perosomus elumbis in a pig.** *Vet Rec* 2007; 160: 127–129.
- 14 Amaral CB, Romao MA and Ferreira AM. **Perosomus elumbis in a puppy.** *J Comp Pathol* 2012; 147: 495–498.
- 15 Karakaya E, Alpay G, Yilmazbas-Mecitoglu G, et al. **Perosomus elumbis in a Holstein calf infected with bovine viral diarrhoea virus.** *Tierarztl Prax Ausg G Grosstiere Nutztiere* 2013; 41: 387–391.
- 16 Son JM, Yong HW, Lee DS, et al. **A case of perosomus elumbis in a Holstein calf.** *J Vet Med Sci* 2003; 70: 521–523.