

Multimodal imaging of eyes with metamorphopsia after vitrectomy for rhegmatogenous retinal detachment

Vinod Kumar, Anand Naik, Devesh Kumawat¹, Dheepak Sundar, Rohan Chawla, Parijat Chandra, Atul Kumar

Purpose: To assess the retinal features in eyes with postoperative metamorphopsia (POM) following rhegmatogenous retinal detachment (RRD) repair using multimodal imaging (MMI). **Methods:** In this cross-sectional; case-control study, patients after successful RRD repair following 25-gauge vitrectomy, clear vitreous cavity, and corrected distance visual acuity (CDVA) > 20/200 were categorized using Amsler chart: cases with POM and controls without POM. MMI was performed on swept-source platform (Triton, Topcon Inc) and the confocal scanning laser ophthalmoscope system (Spectralis HRA, Heidelberg). The measures assessed were CDVA, morphological features on optical coherence tomography, autofluorescence, and multicolor imaging (MCI). **Results:** Thirty-nine eyes were included in each group. Cases had greater number of eyes with total RRD ($P = 0.029$) preoperatively; abnormal foveal contour ($P = 0.036$), ellipsoid zone (EZ) disruption ($P < 0.001$) and poorer postoperative CDVA ($P = 0.046$) as compared to controls. Outer retinal folds and retinal shift (unintentional translocation of retina after reattachment surgery for RRD) did not differ significantly between the groups ($P = 0.48$ and 0.35 , respectively). On MCI, the distribution of detected ERM was similar between the groups ($P = 0.25$). Postoperative CDVA was significantly worse in eyes with POM. **Conclusion:** POM is affected by extent of RRD, postoperative foveal contour, and EZ status but not by retinal shift.

Key words: Amsler chart, metamorphopsia, multimodal imaging, rhegmatogenous retinal detachment, vitrectomy

Pars plana vitrectomy (PPV) is an effective treatment procedure for rhegmatogenous retinal detachment (RRD) with reattachment rates above 90% in most cases.^[1-3] Despite such good anatomical outcomes, the functional outcomes are not always in-hand. It is a common occurrence following successful RRD surgery; reported to occur in between 24–89% of the patients depending upon the time after surgery, status of macula before and during surgery, and the tool used to assess POM.^[4-13] It can hamper the quality of vision despite good distance and near visual acuity.^[11,13]

The exact pathophysiology behind occurrence of POM following successful RRD surgery is not clear. Retinal microstructure has been extensively studied on spectral-domain optical coherence tomography (SD-OCT) platforms in patients with POM following successful RRD surgery. The microstructural changes that have been variably noted in POM include presence of subretinal fluid (SRF),^[10,12] disruption of outer layers such as external limiting membrane (ELM),^[12] and junction of inner segment and outer segment (IS-OS) of photoreceptors or ellipsoid zone (EZ),^[4,5,7] decrease in thickness of ELM–retinal pigment epithelium complex,^[4] outer retinal folds (ORFs),^[7] epiretinal membrane (ERM),^[6,9,12] macular hole,^[6,12] and macular edema.^[6,9,12] Majority of these studies have

limitations related to the sample size, lack of control group, retrospective study type, and their tendency to rely heavily on only SD-OCT parameters.

Multimodal imaging (MMI) of the retina is being extensively used these days to provide better assessment of the disease process by efficient integration of two or more retinal imaging modalities. There is only a single study on MMI use in evaluation of the cause of POM. Schawkat *et al.*^[8] reported retinal shift on fundus autofluorescence (FAF) images to be the main reason for POM after successful RRD surgery in macula-off cases. However, optical coherence tomography (OCT) parameters were not found to have correlation with POM in this study.

We performed this MMI-based case-control study to assess the retinal changes occurring in eyes with POM following successful RRD repair (both macula-on and -off cases) with PPV.

Methods

A cross-sectional case-control study was carried out at our tertiary care referral center after obtaining the clearance from Institutional Ethics Committee. Yes I obtained ethical

This is an open access journal, and articles are distributed under the terms of the Creative Commons Attribution-NonCommercial-ShareAlike 4.0 License, which allows others to remix, tweak, and build upon the work non-commercially, as long as appropriate credit is given and the new creations are licensed under the identical terms.

For reprints contact: WKHLRPMedknow_reprints@wolterskluwer.com

Cite this article as: Kumar V, Naik A, Kumawat D, Sundar D, Chawla R, Chandra P, *et al.* Multimodal imaging of eyes with metamorphopsia after vitrectomy for rhegmatogenous retinal detachment. Indian J Ophthalmol 2021;69:2757-65.

Access this article online

Website:
www.ijo.in

DOI:
10.4103/ijo.IJO_3658_20

Quick Response Code:



Department of Ophthalmology, Dr. Rajendra Prasad Centre for Ophthalmic Sciences, All India Institute of Medical Sciences, New Delhi, ¹Department of Ophthalmology, All India Institute of Medical Sciences, Rishikesh, Uttarakhand, India

Correspondence to: Dr. Vinod Kumar, Dr. Rajendra Prasad Centre for Ophthalmic Sciences, All India Institute of Medical Sciences, New Delhi - 110029, India. E-mail: drvinod_agg@yahoo.com

Received: 16-Dec-2020

Revision: 07-Mar-2021

Accepted: 16-May-2021

Published: 25-Sep-2021

clearance. reference number of my clearance certificate is IECPG-548/20.12.2017. And I submitted this certificate in journal submission forms. The study adhered to the tenets of the Declaration of Helsinki. The study was carried out over a span of 18 months (January 2018 to June 2019) as a part of postgraduate thesis.

Recruitment: All patients who had successful RRD repair with 25-gauge PPV and sulfur hexafluoride tamponade by a

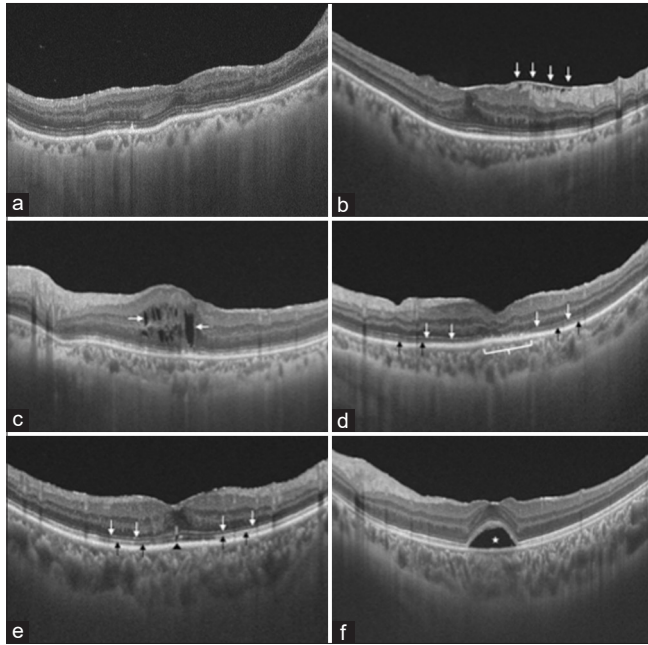


Figure 1: The SS-OCT scans were seen for the foveal contour (flattening and widening of retinal layers) (a), presence of ERM (b), and cystoid macular edema (c), disruption of ELM (d), IS/OS junction (e), and presence of SRF (f)

single surgeon (VK) and presented during the study period for follow-up were assessed for eligibility. The inclusion criteria were attached retina, clear fluid-filled vitreous cavity at the time of assessment, and corrected distance visual acuity (CDVA) >20/200. The exclusion criteria were presence of media opacity, inability to fixate for retinal imaging, presence of clinically visible ERM/cystoid edema retinal hole at the macula, and patients unwilling for participation. All eligible patients were enrolled after obtaining written informed consent.

Surgical technique: Twenty-five gauge pars plana vitrectomy was performed in all cases using Constellation Vitrectomy system (Alcon, USA). Three standard 25-gauge ports were made through the pars plana, and infusion was checked and started. Port site vitrectomy was done, and this was followed by core vitrectomy. Triamcinolone acetonide (0.5 mL, 1:4 dilution with balanced salt solution) was used in all cases to either aid in the

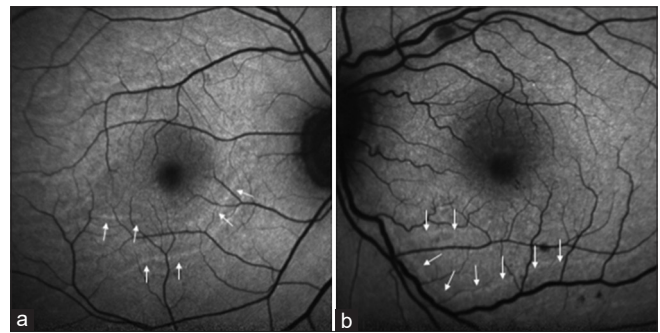


Figure 2: FAF images were seen as outer retinal folds as concentric bands of hyper- or hypoautofluorescence (white arrows) at the posterior pole (a); retinal displacement was present. Lines of increased autofluorescence (white arrows) were seen parallel to the retinal vessels, which indicates the original location of retinal vessels before RRD. These retinal vessels were displaced unintentionally after successful RRD repair from their original location (b)

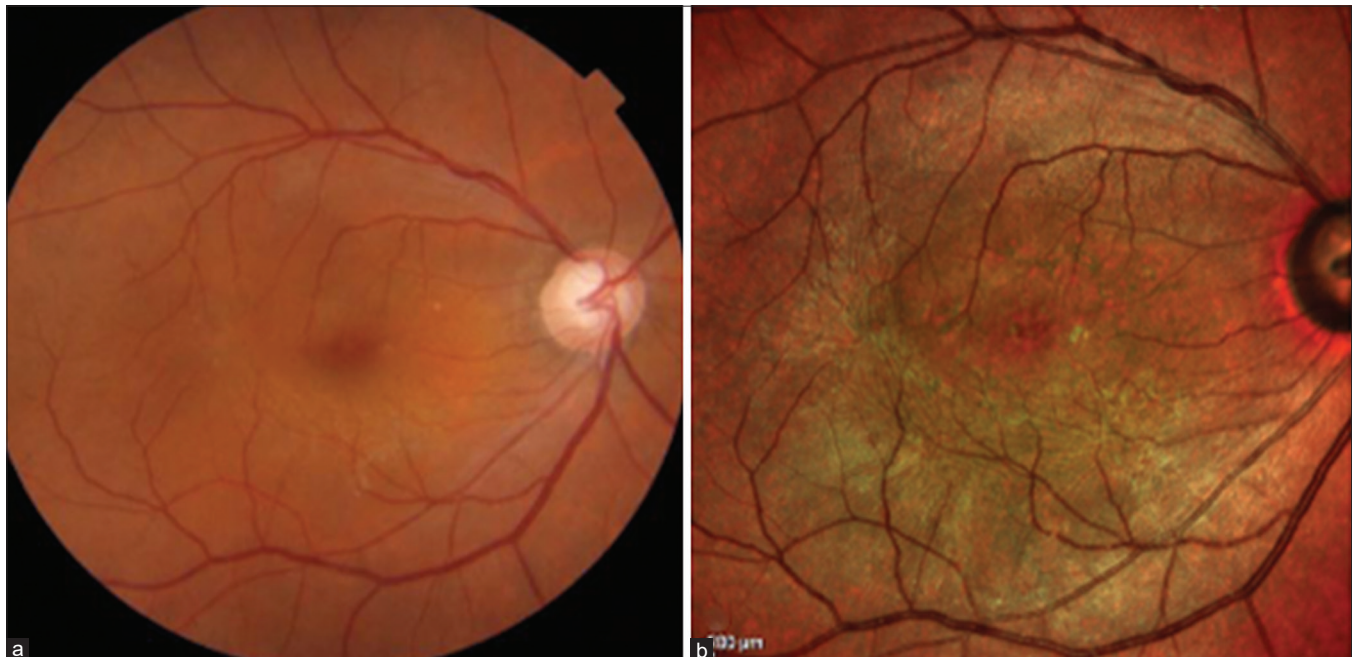

Figure 3: Multicolor images were studied for the presence of ERM (a and b) and other abnormal macular structures

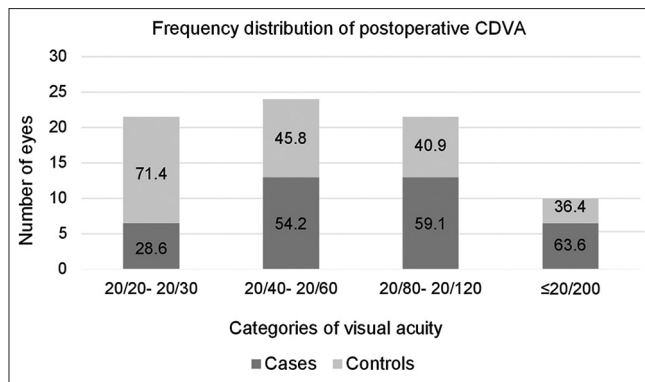


Figure 4: Frequency distribution of postoperative CDVA bar chart showing that postoperative metamorphopsia was more commonly and higher percentage complained in patients with $\leq 20/200$ (lower CDVA) category and almost equal and very less percentage of patients in 20/40–20/120 and 20/20–20/30 (better CDVA) category, respectively

induction of posterior vitreous detachment or to confirm the same if already present. Peripheral vitrectomy was completed. A posterior drainage retinotomy, preferably supero-nasal, was made to drain the SRF completely and achieve homogeneity in the surgical steps. Fluid-air exchange was done. Breaks and retinotomy were lasered. A 360° peripheral laser (2–3) rows was done in all cases, and 25 sulfur hexafluoride (SF₆) gas was used to provide short-term tamponade. Ports were removed, and port site was sutured with 7-0 Vicryl sutures, if required. The patients were advised for prone/lateral position depending on the position of primary breaks for 1 week. In the postoperative period, patients were prescribed a combination of topical steroid and antibiotics along with mydriatic–cycloplegic drugs in tapering fashion for 4 weeks.

Group distribution: Irrespective of the time of follow-up, the enrolled patients of both the group were questioned for metamorphopsia and examined with Amsler grid by a single author (AN). If present, the patients were asked to draw the shape and location of the distorted lines on the grid and included as cases. Postoperative metamorphopsia (POM) was defined as deviation of either vertical or horizontal lines reported by the patient after repair of RRD. If no metamorphopsia was observed, the patients were included as controls.

Patient evaluation: Demographic and preoperative disease characteristics were noted for all the patients, including the duration and extent of RRD, status of macula and baseline visual acuity. CDVA was measured using Snellen chart and converted to log minimum angle of resolution (logMAR) units, with counting fingers and hand motion vision at 2 feet corresponding to 2.0 and 3.0 units, respectively.^[14] Postoperative CDVA and dilated fundus examination details were recorded at the time of recruitment into the study.

Imaging: Retinal imaging was performed after pupillary dilation by experienced optometrists on a swept-source platform (DRI Triton, Topcon, Oakland, New Jersey, USA) and a confocal scanning laser ophthalmoscope-based imaging system (Spectralis HRA, Heidelberg, Germany) for all patients. Swept-source OCT (SS-OCT) was performed on DRI Triton and 12 radial B-scans centered on the fovea were acquired. FAF imaging and multicolor imaging (MCI) were performed on Spectralis HRA. We used blue autofluorescence (AF) for acquiring FAF images. For MCI, three different laser

wavelengths (blue 486 nm, green 518 nm, and near-infrared 815 nm) are used simultaneously to obtain diagnostic images that show distinct structures at different depths within the retina. A pseudocolor image is then obtained by combining these three wavelengths.

Imaging analysis: The retinal imaging scans were analyzed after the study recruitment was completed by a single author (VK) who was not aware of the status of POM during image analysis. The SS-OCT scans were looked for the foveal contour (flattening and widening of retinal layers) [Fig. 1a], presence of ERM [Fig. 1b] and cystoid macular edema [Fig. 1c], disruption of ELM and IS/OS junction [Fig. 1d and e], and presence of SRF [Fig. 1f]. A normal foveal contour had foveal depression relative to surrounding macula, while abnormal contour had relative flatness or fovea thicker than the surrounding macula.^[15] FAF images were assessed for ORFs and retinal shift/displacement. ORFs were seen as concentric bands of hyper- or hypo-AF at the posterior pole [Fig. 2a].^[16] Retinal displacement was present if lines of increased AF were seen parallel to the retinal vessels [Fig. 2b].^[18] Multicolor images were studied for the presence of ERM [Fig. 3a, b] and other abnormal macular structures.

Statistical Analysis: The data was entered into excel spreadsheet and analyzed using STATA v12.1 (Texas, USA). For comparison between cases and controls, two-sample Student's *t*-test was used for parametric data and Mann–Whitney test for nonparametric data. Categorical data was compared between the groups with Pearson's χ^2 test or Fisher's exact test. Pre-post comparison of visual acuity was done using two-sample Wilcoxon signed-rank test. A *P* value ≤ 0.05 was considered statistically significant.

Results

Thirty-nine eyes of 39 patients were included in each group during the study period. The baseline characteristics of cases and controls ARE shown in Table 1. The two groups were statistically comparable in terms of age, sex distribution, duration of RRD, number of retinal tears, macular status, and baseline CDVA [Table 1]. The extent of RRD was different between the groups with a statistically significant difference (*P* = 0.029). Metamorphopsia group had significant greater number of eyes with total RRD as compared to controls (43.6% vs 20.5%). Multiple logistic regression analysis revealed that extent of RRD (*P* = 0.008, Odds ratio = 4.6136, 95% CI = 1.4918–14.2680) significantly associated with POM.

The comparison of postoperative findings is given in Table 2. Postoperative CDVA was significantly better in controls (mean 0.45, SD 0.36, range 0.00–1.78) as compared to cases (mean 0.56, SD 0.31, range 0.00–1.48) (*P* = 0.046). The frequency distribution of postoperative CDVA is given in Fig. 4. Maximum number of eyes with POM were in 20/40–20/60 and 20/80–20/120 categories (since large number of eyes were in this group). However, maximum percentage of eyes with POM belonged to $\leq 20/200$ category.

Among the OCT parameters, abnormal foveal contour and disruption of EZ were seen in significantly greater number of cases than controls (*P* = 0.036 and 0.0001, respectively). Other postoperative findings such as ERM and ELM disruption were not statistically different between the groups (*P* = 0.14 and 0.47, respectively). Cystoid macular edema and residual SRF were noted in three and one cases, respectively, and were not

Table 1: Baseline demographics and clinical characteristics

Parameter	Cases (with metamorphopsia)	Controls (without metamorphopsia)	p (statistical test)
Number of eyes	39	39	-
Age (years), mean±SD	51.6±11.3	51.4±14.1	0.061 (Two sample t-test)
Sex			
Male (n, %)	28 (71.8)	34 (87.2)	0.092 (Chi-square test)
Female (n, %)	11 (28.2)	5 (12.8)	
Baseline CDVA (logMAR), mean±SD (median, range)	2.18±0.81 (2.00, 0.18-3.00)	1.73±1.10 (2.00, 0.00-3.00)	0.11 (Mann-Whitney test)
Duration of RRD days), mean±SD (median, range)	56.5±73.8 (26, 4-365)	52.0±60.6 (30, 6-300)	0.92 (Mann-Whitney test)
Extent of RRD (n, %)			
1-3 quadrant	22 (56.4)	31 (79.5)	0.029 (Chi-square test)
4 quadrant or total	17 (43.6)	8 (20.5)	
Macular status (n, %)			
On	3 (7.7)	9 (23.1)	0.11 (Fisher exact test)
Off	36 (92.3)	30 (76.9)	
Number of breaks, median (range)	2 (1-8)	2 (1-8)	0.55 (Mann-Whitney test)
Single vs multiple breaks (n, %)	13 (33.3) vs 26 (66.7)	14 (35.9) vs 25 (64.1)	0.81 (Chi-square test)

Table 2: Postoperative visual and anatomical outcomes of cases and controls

Parameter	Cases (with metamorphopsia)	Controls (without metamorphopsia)	p (Statistical test)
Number of eyes	39	39	-
Post-operative CDVA ^a (logMAR ^b), mean±SD (median, range)	0.56±0.31 (0.48, 0.00-1.48)	0.45±0.36 (0.30, 0.00-1.78)	0.046 (Mann-Whitney test)
OCT ^c characteristic			
Foveal contour (n, %)			
Normal dip	28 (77.8)	36 (92.3)	0.036 (Fisher exact test)
Flat	11 (28.2)	3 (7.7)	
Epimacular membrane (n, %)			
Absent	29 (74.4)	23 (59)	0.14 (Chi-square test)
Present	10 (25.6)	16 (41)	
ELMd (n, %)			
Continuous	24 (61.5)	27 (69.2)	0.47 (Chi-square test)
Disrupted	15 (38.5)	12 (30.8)	
Ellipsoid zone (n, %)			
Continuous	9 (23.1)	24 (61.5)	0.0001 (Chi-square test)
Disrupted	30 (76.9)	15 (38.5)	
Cystoid macular edema (n)	3	0	-
Subretinal fluid (n)	1	0	-
FAF ^e characteristic			
Outer retinal fold (n, %)			
Absent	33 (84.6)	36 (92.3)	0.48 (Fisher exact test)
Present	6 (15.4)	3 (7.7)	
Retinal shift (n, %)			
Absent	35 (89.7)	38 (97.4)	0.35 (Fisher exact test)
Present	4 (10.3)	1 (2.6)	
Multicolor imaging feature			
Epimacular membrane (n, %)			
Absent	27 (69.2)	29 (74.4)	0.25 (Chi-square test)
Present	12 (30.8)	10 (25.6)	

^aCDVA corrected distance visual acuity; ^bMAR minimum angle of resolution; ^cOCT optical coherence tomography; ^dELM external limiting membrane; ^eFAF fundus autofluorescence

seen in controls. On FAF, ORFs and retinal shift (unintentional translocation of retina after reattachment surgery for RRD) did not differ significantly between the groups ($P = 0.48$ and 0.35 , respectively). On MCI, the distribution of detected ERM was similar between the groups ($P = 0.25$).

The positive predictive values of extent of RRD (68%), postoperative foveal contour (78.6%), and EZ disruption (66.7%) were higher compared to negative predictive values (58.5, 56.3, 52.9%, respectively) for occurrence of POM. The highest positive predictive value was for abnormal foveal

Table 3: Postoperative visual acuity and its association with other variables

Parameter	LogMARa CDVA ^b - mean±SD (median, range)	p (Statistical test)
Age	-	rho=0.21, p=0.053 (Spearman correlation)
Duration of RRD	-	rho=0.49, p<0.0001 (Spearman correlation)
Preoperative macula		
On	0.20±0.19 (0.18, 0.00-0.78)	0.0001 (Mann-Whitney test)
Off	0.58±0.33 (0.48, 0.00-1.78)	
Extent of RRD		
1-3 quadrants	0.53±0.36 (0.48, 0.00-1.78)	0.68 (Mann-Whitney test)
4 quadrants	0.47±0.27 (0.48, 0.00 P 1.00)	
Foveal contour		
Normal	0.51±0.34 (0.48, 0.00-1.78)	0.63 (Mann-Whitney test)
Flat	0.58±0.35 (0.48, 0.18-1.48)	
Ellipsoid zone		
Normal	0.43±0.39 (0.30, 0.00-1.78)	0.003 (Mann-Whitney test)
Disrupted	0.59±0.28 (0.60, 0.00-1.08)	

^aMAR minimum angle of resolution; ^bCDVA corrected distance visual acuity; ^cRRD Rhegmatogenous retinal detachment

Table 4: Factors affecting the postoperative status of Ellipsoid zone

Parameter	EZ ^a normal	EZ disrupted	P (Statistical test)
Age (years), mean±SD	52.0±13.3	51.3±12.2	0.79 (Student' t-test)
Duration of RRD ^b (days)			
mean±SD	39.9±58.1	64.8±70.5	0.020 (Mann-Whitney test)
(median, range)	(15, 6-300)	(40, 4-365)	
Extent of RRD			
1-3 quadrants (n, %)	26	27	0.079 (Chi-square test)
4 quadrants (n, %)	7	18	
Preoperative macular status			
On (n, %)	8	4	0.10 (Fisher exact test)
Off (n, %)	25	41	

^aEZ ellipsoid zone; ^bRRD Rhegmatogenous retinal detachment

contour (78.6%), while the negative predictive value was less than 60% for all the factors.

The association of postoperative visual acuity was studied with duration and extent of RRD, preoperative macular status, postoperative foveal contour, and EL disruption [Table 3]. A moderately strong positive correlation was noted between the duration of RRD and postoperative logMAR CDVA (rho = 0.49, $P < 0.0001$). Postoperative CDVA was significantly better in eyes with macula-on RRD as compared to macula-off ($P = 0.0001$) and significantly worse in eyes with postoperative EZ disruption as compared to eyes with intact EZ ($P = 0.003$).

The association between preoperative characteristics and postoperative EZ status was also studied [Table 4]. The duration of RRD was significantly greater in eyes with EZ disruption ($P = 0.02$), but the extent of RRD and macular status did not have statistically significant effect on EZ status.

Discussion

In this cross-sectional case-control study, we evaluated the factors associated with the occurrence of POM following successful RRD repair with PPV such as demographic and clinical characteristics, SS-OCT features, FAF, and MCI findings. The factors associated

significantly with POM are preoperative extent of RRD, postoperative foveal contour, and EZ continuity on OCT.

Age, sex, duration of RRD, and number of breaks did not differ between cases and controls in the present study. Zhou *et al.*^[12] had reported younger patients to be at risk of POM due to possible incomplete drainage and persistence of thick SRF in these cases. However, rest of the studies have not found such an association [Table 5]. Moreover, none of the studies have found duration of RRD as a significant factor [Table 5], keeping in mind that old RRD are likely to have thick SRF.

Macular involvement in RRD carries great importance when postoperative anatomical and visual outcomes are considered.^[17,18] Likewise, in our study, preoperative macular detachment and duration of detachment governed the visual outcomes. The majority of previous studies on POM have also found macula-off RRD cases to more likely develop POM.^[4-7,12] Separation of macula from underlying RPE adversely affects the metabolic function of the photoreceptors-RPE complex and may be the reason for POM development.^[19] However, prolonged duration of detachment is then expected to cause greater dysfunction of the photoreceptor-RPE complex and more POM, but this has not been observed in literature as well as in our study. Borowicz *et al.*^[9] found equal occurrence of POM in macula-on and -off cases. Similarly, we did not find any

Table 5: Review of literature on associations of postoperative metamorphopsia following rhegmatogenous retinal detachment repair

Author, Year	Type of study	Recruitment	Number of eyes- POM ^a (Gp1) vs. no POM (Gp2)	Macular status and POM	ERM ^b and POM	CME ^c /SRF ^d and POM	ELM ^e disruption and POM	EZ/IZ ^g disruption and POM	Retinal folds and POM	Retinal shift (FAF ^h)	Additional remarks
Schawkat ⁸ (2019)	Retrospective record review	Operated PPV + Gas for Macula-off RRDJ (50 eyes), Amsler chart, 3-6weeks	Gp1: 12 Gp2: 38	All cases were macula-off	Gp1: 1/12 vs Gp2: 4/38, P=1.0	Gp1: 0/12 vs Gp2: 8/38, P=0.17 (CME+SRF)	-	Gp1: 8/12 vs Gp2: 20/38, P=0.13 (EZdk)	Gp1: 5/12 vs Gp2: 4/38, P=0.03 (FAF based)	Gp1: 10/12 vs Gp2: 7/38, P<0.001	Only retinal shift significant in logistic regression
Borowicz ⁹ (2019)	Prospective case series	Operated PPV + Gas for Macula-on (28) and -off (34) RRD, Amsler and M-chart, 6 months	Gp1: 38 Gp2: 24	POM in macula-on cases - 60%, macula-off cases - 62% P=1.0	-	-	-	-	-	-	Improvement in M-scores for 6 months follow-up in both macula-on and -off cases
Saleh ⁷ (2018)	Prospective case series	Operated PPV + Gas for Macula-on (22) and -off (36) RRD, M questionnaire, 6 months	Gp1: 20 Gp2: 38	Macula-on cases in Gp1: 3/20; Gp2: 19/38 P=0.01	Gp1: 13/20 vs Gp2: 22/38, P=0.8	CME- Gp1: 7/20, Gp2: 11/38; P=0.8 SRF- Gp1: 4/20, Gp2: 5/38; P=0.7	-	Gp1: 19/20 vs Gp2: 25/38, P=0.04 (EZ/IZ hypo-intensity)	Gp1: 7/20 vs Gp2: 4/38, P=0.03 (OCT-based ORFs)	-	Most severe distortion associated with ORFs
Murakami ⁴ (2017)	Prospective case series	Operated PPV + Gas for Macula-on and -off RRD, M-chart, 12 months	Gp1: 23, Gp2: 24 (Based on M score ≥0.2)	M-score=Macula-on: 0.08±0.22; Macula-off: 0.40±0.40; P=0.005	M-score=ERM+ 0.27±0.28; ERM-: 0.29±0.40; P=0.883	-	-	M-score EZD+: 0.30±0.10 EZD-: 0.28±0.39, P=0.936 IZDm+: 0.52±0.44 IZD-: 0.12±0.21 P=0.0002	-	-	Improvement in M-scores related with increase of ELM-RPE thickness in macula-off cases
Okuda ⁵ (2017)	Prospective case series	Operated PPV + Gas for Macula-on (14) and -off (26) RRD, M-chart, 6 months	Gp1: 26, Gp2: 14 (Based on M score ≥0.2)	Macula on cases in Gp1: 3/26; Gp2: 11/14 P<0.001	-	-	-	M-score less in EZD- cases than EZD + /IZD+or EZD-/IZD + cases (P<0.01 for both)	-	-	Improvement in M-scores from 6 to 12 months; M-scores correlate with amount of IZD
Zhou ¹² (2016)	Cross-sectional study	Operated PPV + Gas/oil for Macula-on and -off RRD, Amsler chart, mean 35 months	Gp1: 177 Gp2: 203	Macula on cases in Gp1: 33/177; Gp2: 93/203 P<0.01	Gp1: 25/177 vs Gp2: 19/203, P=0.15	CME- Gp1: 3/177, Gp2: 3/203; P=1.0 SRF- Gp1: 20/177, Gp2: 6/203; P<0.01	Gp1: 79/177 vs Gp2: 52/203, P<0.01	Gp1: 77/177 vs Gp2: 56/203, P<0.01 (EZD)	-	-	Younger age, macula-off, ELM disruption and SRF significant in logistic regression

Contd...

Table 5: Contd...

Author, Year	Type of study	Recruitment	Number of eyes- POM ^a (Gp1) vs. no POM (Gp2)	Macular status and POM	ERM ^b and POM	CME ^c /SRF ^d and POM	ELM ^e disruption and POM	EZ/IZ ^g disruption and POM	Retinal folds and POM	Retinal shift (FAF ^h)	Additional remarks
Okamoto ^f (2014)	Prospective case series	Operated PPV + Gas or SB for Macula-on (69) and -off (60) RRD, M- chart, 6-12 months	Gp1: 50 Gp2: 79 (Based on M score ≥ 0.2)	POM in macula-off cases - 13%, macula-off cases - 68% $P < 0.001$	Gp1: 6/50	Gp1: 3/50 (CME), 2/50 (SRF)	-	Gp1: EZD in 5/50	-	-	Larger area of RRD associated with POM in univariate analysis but not in logistic regression; 64% of Gp1 eyes with no OCTo changes
Present study	Prospective Case-control study	Operated PPV + Gas for Macula-on (12) and -off (66) RRD, Amsler chart, variable follow-up	Gp1: 39 Gp2: 39	Macula on cases in Gp1: 3/39; Gp2: 9/39 $P = 0.11$	OCT based Gp1: 10/39 vs Gp2: 16/39, $P = 0.14$ MCIp-based Gp1: 12/39 vs Gp2: 10/39, $P = 0.25$	Gp1: 3/39 (CME), 1/39 (SRF) Gp2: None	Gp1: 15/39 vs Gp2: 12/39, $P = 0.47$	Gp1: 30/39 vs Gp2: 15/39, $P < 0.001$ (EZD)	Gp1: 6/39 vs Gp2: 3/39, $P = 0.48$ (FAF based)	Gp1: 4/39 vs Gp2: 1/39, $P = 0.35$	Flat foveal contour associated with POM; POM and CDVA both related to EZD; Duration of RRD related to EZD

^aPOM postoperative metamorphopsia; ^bepiretinal membrane; ^ccystoid macular edema; ^dexternal limiting membrane; ^eEZ ellipsoid zone; ^fIZ interdigitation zone; ^gFAF fundus autofluorescence; ^hPPV pars-plana vitrectomy; ⁱRRD rhegmatogenous retinal detachment; ^jEZD ellipsoid zone disruption; ^kIZD interdigitation zone disruption; ^lORFs outer retinal folds; ^mIZD interdigitation zone disruption; ⁿRPE retinal pigment epithelium; ^oOCT optical coherence tomography; ^pMCI multicolor imaging

significant difference in preoperative macular status in cases and controls. Majority of patients present late to our tertiary care referral center and are likely to have macular detachment at presentation. It is possible that with small number of eyes with macula-on RRD (12 vs 66), the significance could not be reached.

The association of POM and extent of RRD has been poorly studied.^[6] We observed in our study that eyes with total RRD are more likely to have metamorphopsia postoperatively. Okamoto *et al.*^[6] had reported that larger area of RRD was significantly associated with POM in univariate analysis, but the significance was lost in logistic regression, but in our study, multiple logistic regression analysis revealed that extent of RRD ($P=0.008$, odds ratio = 4.6136, 95% CI = 1.4918–14.2680) significantly associated with POM. It is possible that large extent or total RRD are more likely to have postoperative inferior displacement of the retina than RRD involving 1–3 quadrants, thereby causing dislocation of macula from its desired location.^[20] However, this should translate into greater incidence of retinal shift in total RRD cases, which was not observed in our study. Factors other than extent of RRD are also likely to contribute to POM.

Among the OCT parameters, abnormal foveal contour is a novel finding from our study and its association with POM not been previously studied. Foveal contour changes have been studied following ERM surgery and is an easy way to assess the morphology of retina.^[15,21] An abnormal foveal contour indicates retinal traction by glial proliferations, which may not necessarily be clinically visible.^[15] The effect of this traction onto the photoreceptor alignment and spacing may possibly result in POM. However, we did not observe worse visual outcomes in eyes with abnormal foveal contour in our study supporting the previous literature that foveal contour is not related to visual acuity outcomes.^[15,21,22] It is possible that visual acuity manifestations of abnormal foveal contour does not occur until significant traction is present.

Subclinical ERM was picked up on OCT and MCI in both cases and control in our study. Till date no study had applied MCI in eyes with metamorphopsia after successful RRD repair to detect ERM. However, we did not find any statistical difference between the groups, suggesting that the presence of such ERM alone does not affect POM after RRD repair. This has been observed consistently in previous literature as well [Table 5]. Metamorphopsia occurs when alteration of retinal layers occurs with increasing severity/thickness of ERM.^[23] As cases with clinical ERM were excluded, this may be the reason for the lack of relation observed in our study.

The integrity of outer retinal membranes/zones such as ELM, IS-OS junction or EZ, and interdigitation zone (IZ) is often used for predicting the visual function outcomes in macular diseases.^[4,5,7,12,21,22] In our study, EZ disruption was significantly associated with POM, but ELM integrity did not affect its occurrence. While some studies report greater EZ disruption in eyes with POM,^[7,12] others report equal distribution in eyes with and without POM.^[4,8] Okuda *et al.*^[5] reported higher metamorphopsia scores in eyes with IZ disruption irrespective of EZ disruption as compared to those with intact EZ and IZ. Similarly, Murakami *et al.*^[4] found significantly greater IZ disruption than EZ disruption in eyes with POM. In prospective studies by Murakami *et al.*^[4] and Okuda *et al.*^[5] the improvement in metamorphopsia scores correlated with microstructural restoration of photoreceptor layers on SD-OCT.

A strong correlation has been found between postoperative visual acuity outcomes and restoration of EZ.^[4,5] We also found significantly poor CDVA in eyes with EZ disruption than those with normal EZ. Therefore, a strong evidence is available from the literature and supported by our study that disruption of EZ/IZ on OCT results in significant metamorphopsia and relatively poor postoperative visual acuity outcomes. Other than the study by Zhou *et al.*^[12] which found ELM disruption to be significant greater in POM eyes, ELM integrity has not been extensively studied. However, there is evidence to support its role in preservation of EZ/IZ^[24] and it will be premature to refute its association with POM. Apart from these, outer retinal folds@ (ORFs) on SD-OCT may also predict the development of severe POM.^[7] However, we did not observe such changes on OCT in any of the cases and controls.

OCT changes have not been consistently reported in eyes with POM. Van de Put *et al.*^[11] did not find any SD-OCT findings to be associated with metamorphopsia after macula-off RRD repair. Zhou *et al.*^[12] reported intact IS/OS junction in 65% of eyes with POM, while Okamoto *et al.*^[6] found no OCT changes in 64% of eyes with POM. Rossetti *et al.*^[25] also observed that long-standing metamorphopsia can occur after successful macula-off RRD repair even without detectable photoreceptor layer disruption on OCT. Such cases of POM without any identifiable SD-OCT changes may have retinal displacement as the cause behind POM.^[8] FAF is a valuable tool to assess retinal displacement following RRD.^[8,20,26] Schawkat *et al.* reported retinal shift on FAF as significant factor determining POM in logistic regression, but the groups had small and varied sample size (10/12 in POM group vs 7/38 in non-POM group).^[8] We observed morphologic FAF features such as ORFs and retinal shift in both cases (10/39) and controls (4/39), but they did not significantly affect POM.

An association was noted between different categories of postoperative CDVA and prevalence of POM [Table 3]. The prevalence of POM increased with worsening visual acuity. This is supported by the observation that metamorphopsia occurred greater in eyes with EZ disruption and hence had poorer postoperative visual acuity. The visual acuity outcomes in eyes with POM were significantly poor as compared to those with POM in our study. While some studies report poor CDVA in eyes with POM,^[11,12] others report no effect of POM on visual acuity.^[5,7,8] On ascertaining the factors affecting postoperative visual acuity, we found EZ disruption as significant factor. This association has also been previously reported in several studies.^[4,5,8] From existing literature and observations from our study, we believe that in certain situations, metamorphopsia occurs due to the presence of EZ disruption and is associated with poorer visual acuity outcomes as well. However, in other situations where OCT changes are not present, retinal shift may be the contributory factor. In such conditions, the visual acuity remains relatively unaffected.

The study explores the associations of demographic, clinical, and multimodal retinal imaging features with occurrence of POM. The strengths of this study include cross-sectional case-control nature with equal and greater number of patients in both groups compared to previous studies, single-surgeon, use of swept-source platform for OCT, use of 12 radial scans for evaluation of foveal microstructure, and masking of author to the group type at the time of image analysis. The study carries certain limitations. Quantitative assessment of POM was not performed, and relevant associations may therefore have been

missed. This study had varying intervals of postoperative follow-up for individual patients though most patients were assessed within 3 months of surgery. Longitudinal observations were not made, and hence the cross-sectional observations do not establish causation.

Conclusion

In conclusion, the study demonstrates that POM is affected by the extent of RRD, postoperative foveal contour, and EZ status. The visual acuity outcomes are governed by preoperative macular status, presence of POM, and EZ status. Further studies with larger sample sizes are warranted to elucidate the role of retinal displacement following RRD repair in POM.

Financial support and sponsorship

Nil.

Conflicts of interest

There are no conflicts of interest.

References

- Sborgia G, Niro A, Sborgia L, Grassi MO, Gigliola S, Romano MR, *et al.* One-year outcomes of 27-gauge versus 25-gauge pars plana vitrectomy for uncomplicated rhegmatogenous retinal detachment repair. *Int J Retina Vitreous* 2019;5:13.
- Lumi X, Lužnik Z, Petrovski G, Petrovski BÉ, Hawlina M. Anatomical success rate of pars plana vitrectomy for treatment of complex rhegmatogenous retinal detachment. *BMC Ophthalmol* 2016;16:216.
- Mohamed YH, Ono K, Kinoshita H, Uematsu M, Tsuiki E, Fujikawa A, *et al.* Success rates of vitrectomy in treatment of rhegmatogenous retinal detachment. *J Ophthalmol* 2016;2016:2193518.
- Murakami T, Okamoto F, Sugiura Y, Okamoto Y, Hiraoka T, Oshika T. Changes in metamorphopsia and optical coherence tomography findings after successful retinal detachment surgery. *Retina* 2018;38:684-91.
- Okuda T, Higashide T, Sugiura Y, Sugiura K. Metamorphopsia and outer retinal morphologic changes after successful vitrectomy surgery for macula-off rhegmatogenous retinal detachment. *Retina* 2018;38:148-54.
- Okamoto F, Sugiura Y, Okamoto Y, Hiraoka T, Oshika T. Metamorphopsia and optical coherence tomography findings after rhegmatogenous retinal detachment surgery. *Am J Ophthalmol* 2014;157:214-20.e1.
- Saleh M, Gauthier A-S, Delbosc B, Castelbou M. Impact of metamorphopsia on quality of life after successful retinal detachment surgery. *Ophthalmologica* 2018;240:121-8.
- Schawkat M, Valmaggia C, Lang C, Scholl HP, Guber J. Multimodal imaging for detecting metamorphopsia after successful retinal detachment repair. *Graefes Arch Clin Exp Ophthalmol* 2020;258:57-61.
- Borowicz D, Nowomiejska K, Nowakowska D, Brzozowska A, Toro MD, Avitabile T, *et al.* Functional and morphological results of treatment of macula-on and macula-off rhegmatogenous retinal detachment with pars plana vitrectomy and sulfur hexafluoride gas tamponade. *BMC Ophthalmol* 2019;19:118.
- Wang Y, Li S-Y, Zhu M, Chen S-J, Liu Y, Men X-H, *et al.* Metamorphopsia after successful retinal detachment surgery: An optical coherence tomography study. *Acta Ophthalmol Scand* 2005;83:168-71.
- van de Put MA, Vehof J, Hooymans Johanna MM, Los LI. Postoperative metamorphopsia in macula-off rhegmatogenous retinal detachment: Associations with visual function, vision related quality of life, and optical coherence tomography findings. *PLoS One* 2015;10:e0120543.
- Zhou C, Lin Q, Chen F. Prevalence and predictors of metamorphopsia after successful rhegmatogenous retinal detachment surgery: A cross-sectional, comparative study. *Br J Ophthalmol* 2017;101:725-9.
- Lina G, Xuemin Q, Qinmei W, Lijun S. Vision-related quality of life, metamorphopsia, and stereopsis after successful surgery for rhegmatogenous retinal detachment. *Eye (Lond)* 2016;30:40-5.
- Holladay JT. Visual acuity measurements. *J Cataract Refract Surg* 2004;30:287-90.
- Mathews NR, Tarima S, Kim DG, Kim JE. Foveal contour changes following surgery for idiopathic epiretinal membrane. *Invest Ophthalmol Vis Sci* 2014;55:7754-60.
- Gupta RR, Iaboni DS, Seamone ME, Sarraf D. Inner, outer, and full-thickness retinal folds after rhegmatogenous retinal detachment repair: A review. *Surv Ophthalmol* 2019;64:135-61.
- Thelen U, Amler S, Osada N, Gerding H. Outcome of surgery after macula-off retinal detachment-results from MUSTARD, one of the largest databases on buckling surgery in Europe. *Acta Ophthalmol* 2012;90:481-6.
- Diederer RM, La Heij EC, Kessels AG, Goezinne F, Liem AT, Hendrikse F. Scleral buckling surgery after macula-off retinal detachment: Worse visual outcome after more than 6 days. *Ophthalmology* 2007;114:705-9.
- Kubay OV, Charteris DG, Newland HS, Raymond GL. Retinal detachment neuropathology and potential strategies for neuroprotection. *Surv Ophthalmol* 2005;50:463-75.
- Shiragami C, Shiraga F, Yamaji H, Fukuda K, Takagishi M, Morita M, *et al.* Unintentional displacement of the retina after standard vitrectomy for rhegmatogenous retinal detachment. *Ophthalmology* 2010;117:86-92.e1.
- Suh MH, Seo JM, Park KH, Yu HG. Associations between macular findings by optical coherence tomography and visual outcomes after epiretinal membrane removal. *Am J Ophthalmol* 2009;147:473-80.e3.
- Falkner-Radler CI, Glittenberg C, Hagen S, Benesch T, Binder S. Spectral-domain optical coherence tomography for monitoring epiretinal membrane surgery. *Ophthalmology* 2010;117:798-805.
- Okamoto F, Sugiura Y, Okamoto Y, Hiraoka T, Oshika T. Associations between metamorphopsia and foveal microstructure in patients with epiretinal membrane. *Invest Ophthalmol Vis Sci* 2012;53:6770-5.
- Wakabayashi T, Oshima Y, Fujimoto H, Murakami Y, Sakaguchi H, Kusaka S, *et al.* Foveal microstructure and visual acuity after retinal detachment repair: Imaging analysis by Fourier-domain optical coherence tomography. *Ophthalmology* 2009;116:519-28.
- Rossetti A, Doro D, Manfrè A, Midena E. Long-term follow-up with optical coherence tomography and microperimetry in eyes with metamorphopsia after macula-off retinal detachment repair. *Eye (Lond)* 2010;24:1808-13.
- Lee E, Williamson TH, Hysi P, Shunmugam M, Dogramaci M, Wong R, *et al.* Macular displacement following rhegmatogenous retinal detachment repair. *Br J Ophthalmol* 2013;97:1297-302.