

Clinical Application of 3-Dimensional Printed Navigation Templates in Treating Femoral Head Osteonecrosis With Pedicled Iliac Bone Graft

Xingbo Cai, MM, Yongqing Xu, MD, Kaifu Yu, MM, Xiaoqing He, MD, Haotian Luo, MM, Jiazhang Duan, MM, and Yipeng Wu, MM

Objective: The aim of the study was to explore the feasibility and early effect of digital design combined with 3-dimensional (3D) printing technique in the transplantation of vascular pedicled iliac bone flap in the treatment of avascular necrosis of the femoral head.

Methods: The navigation template was designed according to computed tomography scan and printed in 3D printing technique before operation, which was used to guide the localization and clearance of osteonecrosis of the femoral head in vascular pedicled iliac bone flap transplantation. In blank control group, 28 cases (32 hips) of osteonecrosis of the femoral head were treated with vascular pedicled iliac bone flap without the assistance of 3D navigation template from February 2002 to February 2009, including 19 males (21 hips) and 9 females (11 hips), with an average age of 37 years (range, 20–61 years). There were 12 cases of left hip, 16 cases of right hip, and 4 cases of double hip. According to the International Association of Bone Circulation staging, there were 8 hips in stage II B, 9 hips in stage II C, 8 hips in stage III B, and 7 hips in stage III C. In the experimental group, from February 2014 to June 2014, 15 patients (24 hips) with avascular necrosis of the femoral head were treated with vascular pedicled iliac bone flap with the aid of 3D navigation template. There were 11 males (17 hips) and 4 females (7 hips) with an average age of 38 years (range, 18–56 years). There were 2 cases of left hip, 4 cases of right hip, and 9 cases of double hip. According to the International Association of Bone Circulation staging, there were 5 hips in stage II B, 8 hips in stage II C, 6 hips in stage III B, and 5 hips in stage III C. The operation time, bleeding volume, and postoperative Harris score of the experimental group and the control group were statistically analyzed.

Results: The incisions in both groups healed in the first stage, and there were no operation-related complications such as deep venous thrombosis and infection of lower extremities. All patients were followed up for 12 to 16 months (with an average of 14 months). On the second day after operation, X-ray and computed tomography showed that the necrotic focus of the femoral head and the surrounding sclerotic bone was completely removed, and the position of the vascular pedicled iliac bone flap was satisfactory and did not penetrate the articular surface. The iliac bone flap and bone graft achieved bony fusion. In the navigation template group, the mean \pm SD operation time was 135.38 ± 9.49 minutes, the mean \pm SD

blood loss was 225.13 ± 13.41 mL, the mean \pm SD postoperative Harris score was 89.53 ± 5.83 , 12 hips were excellent, 10 hips were good, and 2 hips were moderate, whereas in the group without navigation template, the mean \pm SD operation time was 151.00 ± 15.28 minutes, the mean \pm SD blood loss was 283.56 ± 30.60 mL, the mean \pm SD postoperative Harris score was 83.32 ± 3.75 , 15 hips were excellent, 14 hips were good, and 3 hips were fair. By independent sample *t* test, there were significant differences in average operation time, average blood loss, and postoperative Harris score between the 2 groups ($P < 0.05$).

Conclusions: Compared with not using navigation template, vascular pedicled iliac bone flap combined with navigation template in the treatment of osteonecrosis of femoral head could locate the area of osteonecrosis of femoral head more accurately, shorten the time of operation, and reduce the amount of bleeding during operation. Postoperative hip joint function recovery was better, and the early effect was satisfactory.

Key Words: avascular necrosis of femoral head, 3D printing technology, navigation template, iliac bone graft

(*Ann Plast Surg* 2020;84: S230–S234)

Avascular necrosis of the femoral head (ANFH) is a severe disabling disease that usually occurs in people between the ages of 20 and 50 years.¹ It is reported that there are 10 to 20,000 new cases of ANFH in the United States each year, of which 5% to 12% will be treated by total hip replacement.² However, there are some problems after replacement, such as infection, thrombosis, loosening of the prosthesis, and limited service life. These problems often need to be modified repeatedly, affecting the quality of life of the patient and increasing the economic burden. Therefore, exploring effective methods to prevent femoral head collapse and delayed joint replacement has become a hot topic. Vascular pedicled bone grafting is one of the most common surgical methods, but the removal of the necrotic foci of the femoral head depends mainly on the experience of the surgeon. There are some risks, such as incorrect location of the lesion, incomplete removal of necrotic lesions or excessive removal of normal bone tissue, and penetration of the cartilage surface of the femoral head.^{3–7} Therefore, on the basis of traditional vascularized bone transplantation for the treatment of ANFH, we propose a digital design combined with a 3-dimensional (3D) printed navigation template to accurately locate the necrotic area of femoral head and completely remove the necrotic focus. From February 2002 to June 2014, 15 patients (24 hips) with ANFH were treated with 3D printing navigation template combined with vascular pedicled iliac bone flap graft, and 28 patients (32 hips) with ANFH were treated with vascular pedicled iliac bone flap graft without the assistance of 3D printing navigation template. The report is as follows.

CLINICAL DATA

General Information

In the experimental group, there were 11 males (17 hips) and 4 females (7 hips) with an average age of 38 years (range, 18–56 years).

Received December 1, 2019, and accepted for publication, after revision January 27, 2020. From the The 920th Hospital of the Joint Logistic Support Force of the PLA, Kunming, Yunnan, China.

Conflicts of interest and sources of funding: none declared.

National Natural Science Foundation of China (81360274); Academician workstation of Zhong Shizhen of Yunnan Province (2015IC030); Kunming General Hospital of Chengdu Military Region Project (2012YG12); Science and Technology Project of Yunnan Province (2014FZ106).

Reprints: Xingbo Cai, MM, The 920th Hospital of the Joint Logistic Support Force of the PLA, 212 Dagan Rd, Xishan District, Kunming, Yunnan, China. E-mail: caixingbo@yeah.net.

Copyright © 2020 The Author(s). Published by Wolters Kluwer Health, Inc. This is an open-access article distributed under the terms of the Creative Commons Attribution-Non Commercial-No Derivatives License 4.0 (CCBY-NC-ND), where it is permissible to download and share the work provided it is properly cited. The work cannot be changed in any way or used commercially without permission from the journal.

ISSN: 0148-7043/20/8403–S230

DOI: 10.1097/SAP.0000000000002362

There were 2 cases of left hip, 4 cases of right hip, and 9 cases of double hip. The course of the disease ranged from 1 to 24 months, with an average of 7.5 months. All patients had hip pain, lameness, positive “4” test, and limited movement of hip joint. According to the Association Research Circulation Osseous (ARCO) staging of the International Association of Bone Circulation, there were 5 hips in stage II B, 8 hips in stage II C, 6 hips in stage III B, and 5 hips in stage III C.

In the blank control group, there were 19 males (21 hips) and 9 females (11 hips), with an average age of 37 years (range, 20–61 years). There were 12 cases of left hip, 16 cases of right hip and 4 cases of double hip. The course of the disease ranged from 1 to 24 months, with an average of 8 months. All patients had hip pain, lameness, positive “4” test, and limited movement of hip joint. According to the International Association of Bone Circulation (ARCO) staging, there were 8 hips in stage II B, 9 hips in stage II C, 8 hips in stage III B, and 7 hips in stage III C.

Navigation Template Preparation

Sixty-four–slice spiral CT (computed tomography, GE) was used to scan bilateral hip joints. That scan conditions were as follows: voltage 120 V, thickness 0.625 mm, and matrix 512×512 . Import the raw data obtained into the Mimics 15.0 software in DICOM format (Materialize, Belgium). Firstly, a section line is created by selecting the profile line in the axial window, and the femoral head is thresholded by selecting a certain pixel gray value. Crop mask tool was used to limit region of interest to the necrotic side of femoral head, so as to reduce the workload of data segmentation in the later stage. Then, the soft tissue and some discrete voxels are separated from the bone by the region growing method, and a new mask is generated. Use multilayer editing tools to extract femoral and femoral head necrotic areas from bones at each axial view level, and reconstruct newly added masks to generate 3D models of femoral and femoral head necrotic areas. With Mimics 15.0 software, templates can be pre-designed for navigation tubes. Based on the 2D sagittal, coronal, and axial views, adjust the navigation tube in the 3D image area to pass through the femoral head necrosis area and determine the best window opening direction. Adjust the needle depth of the navigation tube and use Mimics 15.0 software. Measurements measure the depth of the navigation catheter and use the junction of the femoral head and neck as a template domain. Geomagic studio 12.0 software (Geomagic) was used to create a reverse template, which was consistent with the anatomical shape at the junction of the femoral head and neck. The stereolithography virtual navigation template is generated after precise registration between the reverse template and the anatomy at the junction of the femoral head and neck. Finally, using SPSS350B solid-state laser rapid prototyping machine (Shaanxi Hengtong Intelligent Machinery Co, Ltd) to manufacture photosensitive resin 14120 (DSM Somos).

Surgical Methods

In the experimental group, bilateral simultaneous operation was performed in 4 cases. Staged operation was performed in 5 cases with an interval of 1 month. Under general anesthesia, the patient was placed in a supine position. The operation was performed according to the method of Yongqing Xu et al.⁸ A modified Smith-Peterson incision was made to protect the lateral femoral cutaneous nerve. The rectus muscle is cut at the anterior inferior spine and bends downward. The ascending branch of the lateral circumflex femoral artery can be seen below the fascia. It is divided along the direction to the beginning of the tensor fascia reticulum and is marked with blood vessels. According to the preoperative design, the navigation template was fixed on the bone surface at the junction of the front of the femoral head and the neck, and a 2.0-mm-diameter mark-length score line was pushed through the navigation tube of the navigation template into the femoral head necrosis region. Then, cut the femoral head along the Kirschner wire with a 9.0-mm-diameter hollow drill with a significantly longer diameter and drive it into the necrotic area, remove the osteonecrosis and

surrounding sclerotic bone, and establish a bone tunnel. Residual osteonecrosis and surrounding hardened bone were further moved into the femoral head tunnel by high-speed abrasive drilling. The exuding blood from the femoral head grinding wound was satisfactory, indicating that the necrotic area of the femoral head had been completely cleared. According to the diameter and depth of the slit area after necrosis, the bone graft of the lateral part of the anterior superior spine was removed, and part of the periosteum and tensor fascia reticulum cuff flap were protected on the bone to protect the cancellous bone. An autologous cancellous bone is implanted to clear the necrotic area, and then, a bone graft with a vascular pedicle is implanted along the bone tunnel. Finally, the wound is cleaned routinely and the incision is closed layer by layer. The 3.5-bone skin flap was harvested from 3.5×1.5 cm to 4.0×2.0 cm.

In the blank control group, simultaneous bilateral surgery was performed in 4 patients with bilateral hips. After exposing the front of the neck junction of the femoral head by the same method during the operation, the 3D printing navigation template was not used to remove the necrotic part of the femoral head, but a bone knife was used to make a slot in front of the neck junction of the femoral head, with an area of approximately 3.5×1.5 cm to 4.0×2.0 cm, and then Kirschner needle, grinding drill, and scraper were used to break the sclerosing zone of the femoral head, remove the necrotic tissue in the femoral head, and grind the wound surface into the femoral head and ooze blood satisfactorily. It was suggested that the area of osteonecrosis of the femoral head was completely cleared. The cancellous bone was pressed and grafted into the femoral head, and the vascular pedicled iliac bone flap was filled with the same method as the experimental group.

Postoperative Management and Evaluation Index of Curative Effect

The hip joint was fixed with gypsum for 1 month and the patient was in bed for 3 to 6 months. After 3 months, leg-lifting and hip-flexing exercises were started in bed, and 6 months later, partial weight bearing was started out of bed and gradually changed to full weight bearing. The operative time, bleeding volume, wound healing, and deep venous thrombosis of lower extremity were recorded. On the second day after operation, X-ray and CT were reexamined to check whether the necrotic foci of femoral head were completely removed and the position of iliac bone graft with vascular pedicle. During the follow-up period, X-ray films were reviewed regularly to evaluate the development of femoral head necrosis, which was divided into 4 grades,⁹ including improvement, invariance, deterioration, and failure. The recovery of hip function was evaluated by Harris score.

Statistical Methods

SPSS 20.0 statistical software was used for analysis. The data were expressed as “mean \pm standard deviation,” independent sample *t* test was used for comparison between groups, and the test α level was 0.05.

RESULTS

The incisions in both groups healed in the first stage, and there were no operation-related complications such as deep venous thrombosis and infection of lower extremities. All patients were followed up for 12 to 16 months (with an average of 14 months). On the second day after operation, X-ray and CT showed that the necrotic focus of the femoral head and the surrounding sclerotic bone were completely removed, and the position of the vascular pedicled iliac bone flap was satisfactory and did not penetrate the articular surface. The iliac bone flap and bone graft reached bony fusion (Fig. 1G). In the navigation template group, the mean \pm SD operation time was 135.38 ± 9.49 minutes, the mean \pm SD blood loss was 225.13 ± 13.41 mL, the postoperative Harris score was 89.53 ± 5.83 , 12 hips were excellent, 10 hips were good, and 2 hips were

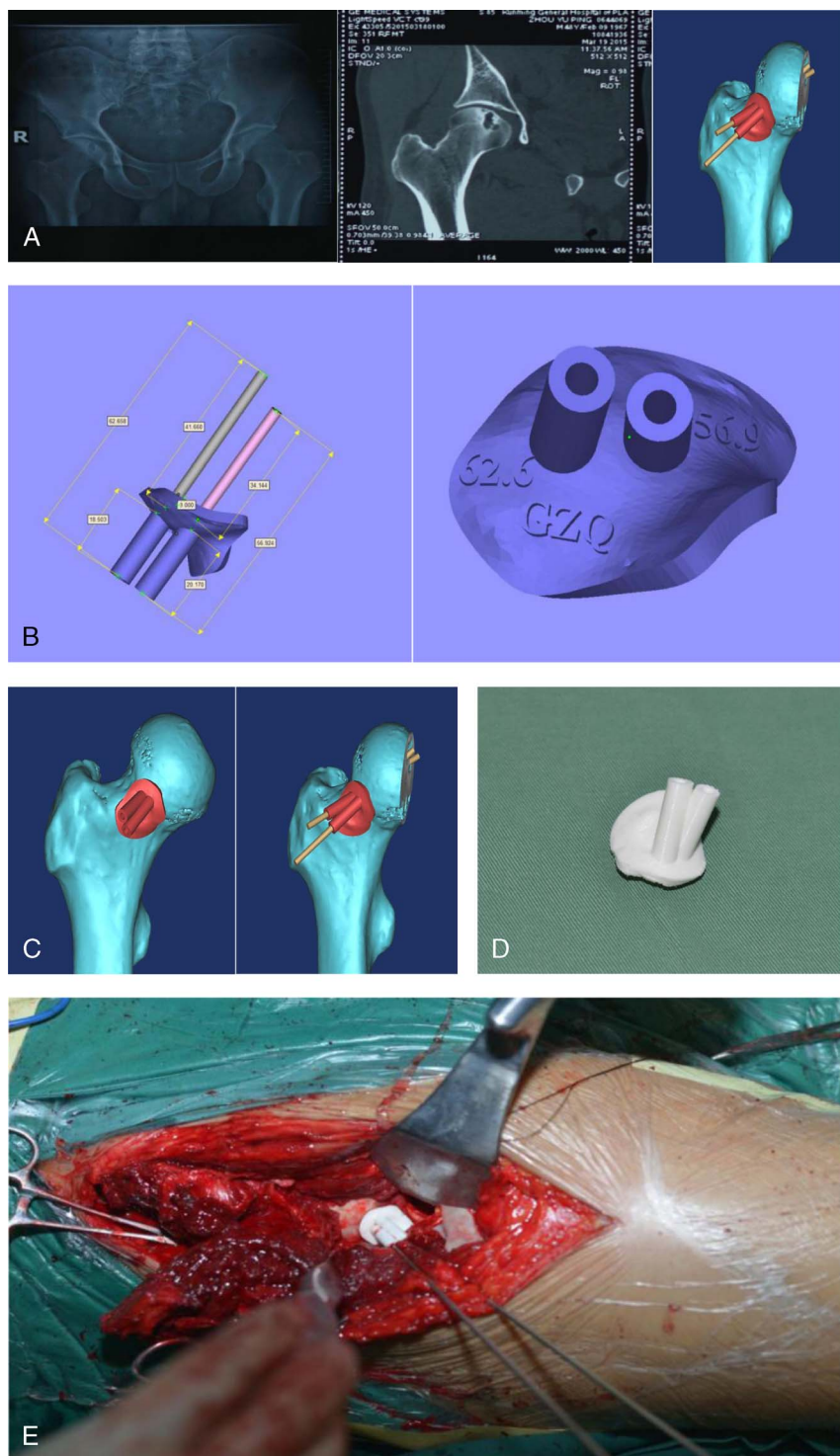


FIGURE 1. A 48-year-old male patient with right osteonecrosis of the femoral head (ARCO stage IIC). A, Computed tomography scanning data were imported into Mimics 15.0 software to define the center of femoral head necrosis. B, Determining the length of tube and size of navigation template according to the specific femoral head necrosis. C, Location of designed navigation template at the junction of the femoral head and neck. D, Three-dimensional–printed navigation template. E, A 2.0-mm Kirschner wire with marks inserted into necrosis area along the tube after navigation template was fitted at the junction of the femoral head and neck. F, The location of Kirschner wire was in accordance with preoperative design on intraoperative X-ray. G, X-ray film and CT scanning at 2 days after operation, showing completely removed necrosis area and satisfactory position of pedicled iliac bone graft. H, The patient was a 36-year-old woman with hip pain and weakness for 3 years. The X-ray diagnosis was bilateral ARCO stage IIIc (January 2009). I, Bilateral joint space was widened, the joint interface was clear, the femoral head had a good recovery, and the bone graft had been completely healed (January 2015). [full color online](#)

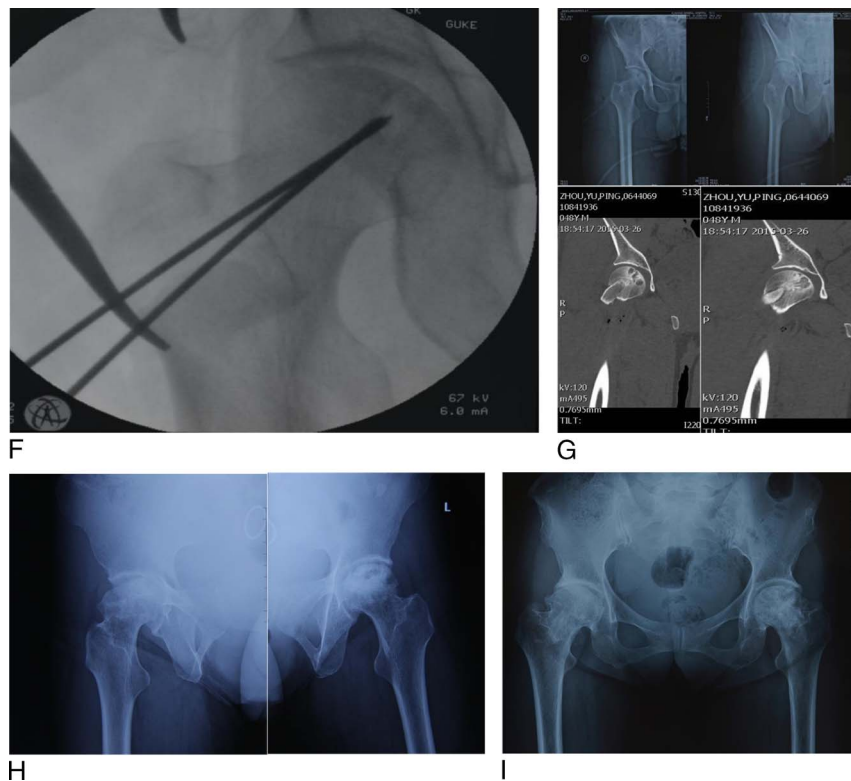


FIGURE 1. (Continued).

moderate, whereas in the group without navigation template, the mean \pm SD operation time was 151.00 ± 15.28 minutes, the mean \pm SD blood loss was 283.56 ± 30.60 mL, and the mean \pm SD postoperative Harris score was 83.32 ± 3.75 , 15 hips were excellent, 14 hips were good, and 3 hips were fair. By independent sample *t* test, there were significant differences in average operation time, average blood loss, and postoperative Harris score between the 2 groups ($P < 0.05$). The pain of the hip joint was significantly relieved and the range of motion of the joint was significantly increased in the 2 groups, and there were no complications of the iliac flap during the follow-up.

Case Reports

The patient was a 36-year-old woman with hip pain and weakness for 3 years. The X-ray diagnosis was bilateral ARCO stage IIIc (Fig. 1H), and the Harris score was 63.34. In January 2009, bilateral iliac bone flap revascularization of femoral head was performed in our hospital, and the patient was fixed in bed with braces for 6 months. The X-ray examination in January 2015 showed that the bilateral joint space was widened (Fig. 1), the joint interface was clear, the femoral head had a good recovery, and the bone flap had been completely healed. Pain disappeared, activity was satisfactory, and Harris score was 80.40.

DISCUSSION

With the development of computer technology, various surgical positioning systems have been gradually applied in clinical practice to improve the accuracy and efficacy of surgery. At present, the main surgical positioning systems used in clinical practice are CT positioning, computer-aided navigation, surgical robots, and so on. Traditional vascular bone transplantation for the treatment of ANFH mainly depends on the experience of the surgeon, and there are problems such as inaccurate positioning. To solve these problems, scholars have done some

research, such as Tong Dedi and others.¹⁰ Three-dimensional computer-assisted fibula transplantation was performed for the treatment of ANFH during surgery. Each of these assisted positioning systems has its own advantages and disadvantages. Among them, CT positioning is easy to apply, but because it absorbs a large amount of radiation, the operation time is long, the operation is not flexible, and it is easy to cause intraoperative pollution. Computer-aided navigation and positioning are accurate and can provide real-time image support, but the learning curve is long, the equipment is expensive and large, and the operating room takes up too much space. The positioning device installed during surgery is prone to cause secondary injuries and needs to be registered. Therefore, the operation is troublesome, aseptic steps are added, and the infection rate of patients is increased. The positioning of the surgical robot is accurate, but it is expensive and has limited applications.

Three-dimensional printing technique provides a new way to locate and clear that lesion in the operation of ANFH.^{11,12} Digital design combined with 3D print navigation template can restore the preoperative design in the course of operation, guide the operator to perform the operation according to the preoperative design, and digitally analyze the structure of the operation area, so as to improve the accuracy and safety of the operation.^{13–17} Fu Jun et al¹⁸ used digital design combined with 3D print navigation template to locate the bone tumors in all parts of the body and achieved accurate intraoperative location and complete tumor resection. Three-dimensional–printed personalized transdermal navigation template designed by Jin et al.¹⁹ achieve precise puncture around the shoulder joint. The CT scan data were imported into Mimics 15.0 software before surgery, and the femoral head was reconstructed in 3D. The scope and location of femoral necrosis can be directly understood, and the position of femoral necrosis can be accurately located from the coronary, sagittal, and axial positions. Based on these data, a navigation template was designed and the anterior and posterior positions of the femoral head were revealed during the procedure. The

interface between the femoral head and neck is used to design the contact surface of the navigation template, and the navigation tube is used as a guide during the surgery. The blood supply to the femoral head is mainly from the medial orbiting femoral artery that passes through the posterior joint capsule. When designing the navigation template, the front of the femoral head-neck junction is used as the connection point for the template, so the blood supply to the femoral head is not affected when the joint capsule is opened to show the junction of the femoral head. Femoral head and neck were exposed during the operation. During the surgery, the navigation template was completely fitted to the bone surface at the junction of the femoral head and neck, and the diameter of the marked length was 2.0 mm. The Kirschner wire penetrates the necrotic area of femoral head along the navigation tube, thereby achieving the accurate determination of the position, direction, and depth of the necrotic area of femoral head. Then, a hollow drill with a diameter of 9.0 mm was drilled into the necrotic area along the Kirschner wire to clear the lesions, and a localized, directional, and fixed-depth bone tunnel was established. Finally, a high-speed grinding drill was used to further polish along the bone tunnel to remove the residual bone necrosis lesions around the bone tunnel until blood oozed out on the wound surface in the necrotic area, so as to completely remove the necrotic femoral head. Be careful not to exceed the fixed depth when polishing and removing lesions to avoid breaking through the articular cartilage surface and damaging the articular cartilage. In addition, it can obtain a good prognosis to prolong the loading time after operation.

Through the application of this group, we believe that 3D-printed navigation templates have the following advantages: (1) through the use of navigation templates, the problem of penetrating the joint surface is effectively avoided, and the operation safety is improved; (2) under the guidance of the navigation template, only one perspective inspection can verify the accuracy of the navigation template. The digital design of 3D positioning is more accurate than the C-arm perspective inspection. (3) Achieve personalized processing; (4) because the posture during surgery is different from the posture during the CT scan design before surgery, the attachment of the navigation template to the bone surface will not change, thereby avoiding the impact of registration changes on positioning accuracy. In posture in infrared navigation, (5) no special computer-aided navigation equipment is needed, nor does it take up space in the operating room; and (7) simple operation during operation. Disadvantages: (1) the preoperative design of the navigation template should be completed by professionals and plastic surgeons proficient in related computer software; (2) the navigation template design, physical printing, and disinfection took a long time (>1 day), so it is not suitable for emergency use by patients; (3) the error range between the designed navigation template and the printed object is 0 to 1 mm.¹⁷ To sum up, it is feasible to apply the individualized navigation template made by digital design and 3D printing technology to the treatment of avascular necrosis of femoral head with pedicled iliac bone grafting. The location of the lesions is accurate, the necrotic lesions and the surrounding sclerotic bones are completely removed during

the operation, and the operation is simple and the early clinical effect is satisfactory. However, this group sample size is small, follow-up time is short, the lack of traditional surgical treatment compared with the study, and the previously mentioned conclusions need further study.

REFERENCES

1. Marker DR, Seyler TM, McGrath MS, et al. Treatment of early stage osteonecrosis of the femoral head. *J Bone Joint Surg Am.* 2008;90(suppl 4):175–187.
2. Mont MA, Hungerford DS. Non-traumatic avascular necrosis of the femoral head. *J Bone Joint Surg Am.* 1995;77:459–474.
3. Nakamura Y, Kumazawa Y, Mitsui H, et al. Combined rotational osteotomy and vascularized iliac bone graft for advanced osteonecrosis of the femoral head. *J Reconstr Microsurg.* 2005;21:101–105.
4. Zhao D, Zhang Y, Wang W, et al. Tantalum rod implantation and vascularized iliac grafting for osteonecrosis of the femoral head. *Orthopedics.* 2013;36:789–795.
5. Elmali N, Ertem K, Karakaplan M, et al. Vascular pedicled iliac bone grafting is effective in patients with an early stage of femoral head avascular necrosis. *Ekleml Hastalik Cerrahisi.* 2014;25:2–7.
6. Zhao D, Liu B, Wang B, et al. Autologous bone marrow mesenchymal stem cells associated with tantalum rod implantation and vascularized iliac grafting for the treatment of end-stage osteonecrosis of the femoral head. *Biomed Res Int.* 2015;2015:240506.
7. Babhulkar S. Osteonecrosis of femoral head: treatment by core decompression and vascular pedicle grafting. *Indian J Orthop.* 2009;43:27–35.
8. Beckmann J, Tingart M, Perlick L, et al. Navigated drilling for femoral head necrosis experimental and clinical results. *Orthopade.* 2007;36:458–465.
9. Chung KJ, Hong DY, Kim YT, et al. Preshaping plates for minimally invasive fixation of calcaneal fractures using a real-size 3d-printed model as a preoperative and intraoperative tool. *Foot Ankle Int.* 2014a;35:1231–1236.
10. Jeong HS, Park KJ, Kil KM, et al. Minimally invasive plate osteosynthesis using 3D printing for shaft fractures of clavicles: technical note. *Arch Orthop Trauma Surg.* 2014;134:1551–1555.
11. Kunz M, Ma B, Rudan JF, et al. Image-guided distal radius osteotomy using patient-specific instrument guides. *J Hand Surg Am.* 2013;38:1618–1624.
12. Tricot M, Duy KT, Docquier PL. 3D-corrective osteotomy using surgical guides for posttraumatic distal humeral deformity. *Acta Orthop Belg.* 2012;78:538–542.
13. Lu S, Xu YQ, Lu WW, et al. A novel patient-specific navigational template for cervical pedicle screw placement. *Spine (Phila Pa 1976).* 2009;34:E959–E966.
14. Won SH, Lee YK, Ha YC, et al. Improving pre-operative planning for complex total hip replacement with a rapid prototype model enabling surgical simulation. *Bone Joint J.* 2013;95-B:1458–1463.
15. Omori S, Murase T, Kataoka T, et al. Three-dimensional corrective osteotomy using a patient-specific osteotomy guide and bone plate based on a computer simulation system: accuracy analysis in a cadaver study. *Int J Med Robot.* 2014a;10:196–202.
16. Wang W, Hu W, Yang P, et al. Patient-specific core decompression surgery for early-stage ischemic necrosis of the femoral head. *PLoS One.* 2017;12:e0175366.
17. Van Dijk M, Smit TH, Jiya TU, et al. Polyurethane real-size models used in planning complex spinal surgery. *Spine (Phila Pa 1976).* 2001;26:1920–1926.
18. Jun F, Zhen W, Zheng G, et al. The design and processing of 3D printed individual guide plate and its application in bone tumor surgery. *Chin J Traumatol Orthop.* 2015;17:50–54.
19. Jin Z, Jialiang T, Li S, et al. Preliminary application of digital design combined with 3D printing personalized percutaneous guide plate in peripheral puncture of shoulder joint. *Chin J Traumatol Orthop.* 2015;17:45–49.