

CASE REPORT

Platypnea–orthodeoxia syndrome after right lower lobectomy for lung cancer

Andre C. D’Mello^{1,*}, Kawa Haji², Stuart Moir^{1,3} and Paul Leong^{3,4}

¹Monash Heart, Monash Health, Clayton, Victoria 3168, Australia, ²Department of Cardiology, Western Health, Melbourne 3011, Australia, ³Monash University, Clayton, Victoria 3168, Australia, and ⁴Monash Lung & Sleep, Monash Health, Clayton, Victoria 3168, Australia

*Correspondence address. Monash Heart, Monash Health, Clayton, Victoria 3168, Australia. Tel: +61-39-594-6666; Fax: +61-39-594-6111; E-mail: andre.dmello@monashhealth.org.au

Abstract

Platypnea–orthodeoxia syndrome (POS) is a rare condition characterized by dyspnoea and deoxygenation in an upright position that is relieved by supine positioning. There are only five published accounts of it occurring post-lobectomy. We present the case of a 72-year-old male with 3 months of supposedly unexplained dyspnoea after right lower lobectomy for lung cancer who was confirmed to have POS. We highlight the importance of recognition and management as well as provide a brief summary of the pathophysiology.

INTRODUCTION

Platypnea–orthodeoxia syndrome (POS) is a rare condition with the pathognomonic finding of dyspnoea and deoxygenation in an upright position ameliorated by supine positioning. This commonly arises as a result of blood redirection through an intracardiac shunt. Prompt recognition is of key importance as POS can be readily treated by correction of the anatomical shunt. We report a case post-lobectomy, which highlights the manifestations, clinical suspicion, diagnosis and management in POS.

CASE REPORT

A 72-year-old non-English speaking male with a past history of hypertension and hyperlipidaemia presented to a major metropolitan hospital with 3 months of dyspnoea following radical right lower lobectomy for recently diagnosed adenocarcinoma pT2aN2M0 (stage IIIa, IASLC TNM seventh edition). Prior to the

operation, he was functionally independent, able to walk at least 2 km and had normal pulmonary function tests. Six weeks after lobectomy, he developed subacute, progressive dyspnoea with an exercise tolerance of <10 m at admission. He was taking rosuvastatin 10 mg daily for dyslipidemia, as well as perindopril 5 mg daily and metoprolol 25 mg twice daily for hypertension.

Two hospital admissions in the preceding 6 weeks had failed to uncover a cause for symptoms and he had been empirically treated for pneumonia with antibiotics and for heart failure with diuretics. Despite this, his dyspnoea continued to worsen.

On admission, a blood panel of full blood count, urea and electrolytes and c-reactive protein were unremarkable. A CT chest was performed and revealed non-specific left predominant bilateral ground glass changes (Fig. 1). Bronchoscopy was performed: bronchoalveolar lavage revealed normal cell count and differential, no pathogens were isolated with standard culture, acid fast bacilli or fungal media. Polymerase chain

Received: July 28, 2017. Revised: March 13, 2018. Accepted: November 26, 2018

© The Author(s) 2019. Published by Oxford University Press.

This is an Open Access article distributed under the terms of the Creative Commons Attribution Non-Commercial License (<http://creativecommons.org/licenses/by-nc/4.0/>), which permits non-commercial re-use, distribution, and reproduction in any medium, provided the original work is properly cited. For commercial re-use, please contact journals.permissions@oup.com

reaction tests were negative for *P. jiroveci*, herpes simplex virus 1&2, varicella zoster virus, cytomegalovirus and influenza A, B, enterovirus/rhinovirus, picornavirus, parainfluenzae 1/2/3, adenovirus, human metapneumovirus and *B. pertussis* and respiratory syncytial virus. Antinuclear antibody, double stranded DNA, extractable nuclear antigens (Sm, Sm/RNP, SSA/Ro, SSB/La, Scl-70, Jo-1, PCNA, Ribosomal P Pm-Scl. Centromere protein B), antineutrophil cytoplasmic antibody, anti-glomerular basement membrane, creatinine kinase and myositis antibody panel were negative.

Despite intravenous ceftriaxone and azithromycin and diuresis with IV furosemide, his dyspnoea progressively deteriorated over the first week of admission with development of platypnea (dyspnoea after assuming the upright position).

On careful assessment by the authors, the patient was observed to have orthodeoxia with pulse oximetry falling from 93% on room air whilst supine to 86% whilst upright. Lying and upright arterial blood gases confirmed a drop in pO_2 from 75 to 56 mmHg after remaining upright for 5 min (Table 1).

The presence of an intracardiac shunt was confirmed on transthoracic (TTE) and transoesophageal echocardiogram (TOE) with intravenous agitated saline contrast, which demonstrated a lipomatously hypertrophied atrial septum with aneurysmal fossa ovalis membrane, a patent foramen ovale (PFO) and right

to left shunting that increased significantly on upright positioning (Fig. 2a and b). Right ventricular contraction (RVC) was severely reduced with a suggestion of external compression on ultrasound images but no extrinsic compression was demonstrated on either the initial CT chest, nor subsequent cardiac CT or CT pulmonary angiogram. It is hypothesized that decreased RVC resulted from the relatively sudden onset of a low volume state through a previously chronically volume overloaded right ventricle related to the underlying PFO. A technetium-99m macroaggregated albumin shunt study quantified the presence of a right to left shunt of 17%. Left and right heart catheter revealed mild coronary artery disease and normal pulmonary pressures. Qp/Qs was unable to be calculated due to insufficient data.

The patient subsequently underwent successful and uncomplicated percutaneous closure of his PFO with a 27/30 mm Occlutech occluder device via right femoral venous catheter access. Intra-procedural TOE confirmed satisfactory placement and follow up TTE performed at 24 h and 8 weeks demonstrated stable placement with no interatrial shunting and return of RVC to low normal.

Follow up arterial blood gas in the upright position demonstrated an improved A-a gradient with normal saturation (Table 1). The patient reported immediate improvement in both dyspnoea and exercise tolerance and was discharged home. 1 month after discharge, he was able to walk 200–300 m without walking aid, and enlisted in community rehabilitation with good effect. Unfortunately, oncological surveillance demonstrated widespread skeletal metastasis and the patient died 7 months post procedure from progression of lung adenocarcinoma.

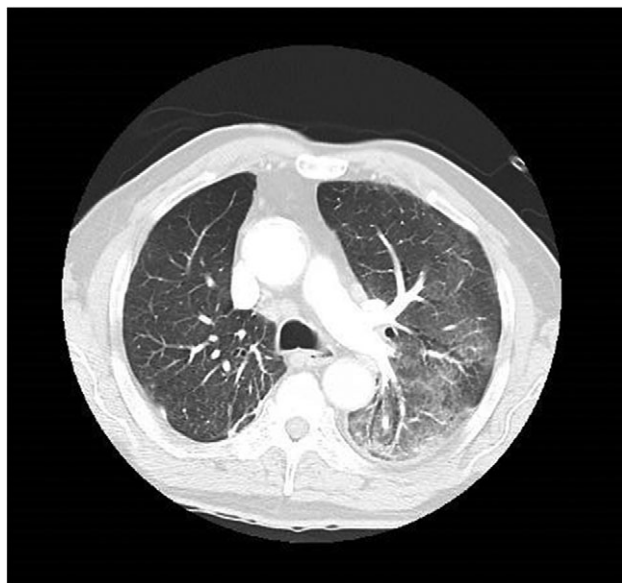

Figure 1: Representative computed tomography section at the pulmonary outflow tract level demonstrating non-specific ground glass infiltrate.

Table 1: Arterial blood gas results

	Supine	Upright (after 5 min)	Upright post PFO closure
FiO ₂	0.21 (room air)	0.21 (room air)	0.21 (room air)
pH	7.41	7.42	7.43
pO ₂	75	56	69
SaO ₂	95	88	95
pCO ₂	37	37	37
HCO ₃	23	23	24
A-a gradient	28.5	47.5	34.5

DISCUSSION

POS was originally reported in 1949 and to date there have been more than 150 accounts in the literature [1]. Current understanding of POS centres on a '2 hit' hypothesis that requires both a pre-existing anatomical defect and subsequent physiologic change that facilitates a right to left shunt [2]. Numerous causes (Table 2) have been identified and the most common associated defects are intracardiac communications such as PFO, atrial septal defect or atrial septal aneurysm [2]. Pneumonectomy, (in particular right sided) has previously been implicated as a cause of POS in both the presence and absence of elevated right heart pressures [3]. Of note, there are only five published cases of POS after right lower lobectomy [4–7].

The proposed mechanism for POS post-lobectomy in the context of normal right heart pressures is anatomical remodeling that facilitates a 'flow phenomenon' favouring right to left shunting in the upright position [8]. Post operatively, there is a slow shift of the mediastinum towards the operated side such that when the patient assumes an upright position, the atrial septum is dragged down by the weight of the shifted heart and the interatrial communication is brought directly in line with the inferior vena caval orifice. This facilitates streaming of blood into the left atrium and augmentation of the shunt [9].

The definitive management for POS is closure of the interatrial communication. Literature suggests that for intracardiac shunts, percutaneous closure is both safe and effective in improving dyspnoea and oxygen saturation [10].

The diagnosis in our patient was delayed due to a language barrier, and to the fact that we considered relatively common conditions first to explain the persistently elevated A-a gradient. Nevertheless, careful history taking, examination and prompt

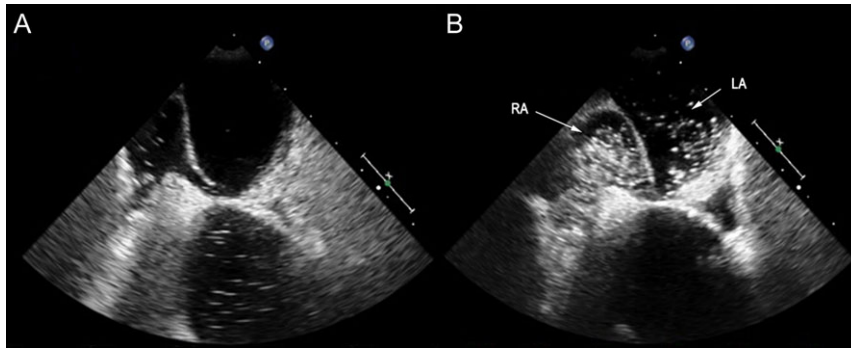


Figure 2: Transoesophageal echo performed in (A) supine and (B) upright position (head of bed at 75°). In an upright position there is marked increase of right atrial (RA) inflow with shunting of agitated saline contrast into the left atrium (LA).

Table 2: Causes of platypnea–orthodeoxia syndrome

Intracardiac shunt (patent foramen ovale, atrial septal defect or atrial septal aneurysm)	With right to left pressure gradient	<ul style="list-style-type: none"> • Pulmonary thromboembolism • Idiopathic pulmonary hypertension • Right hydrothorax • Post-pneumectomy • Right atrial (RA) compression by aortic dilatation/aneurysm • Pericardial effusion • Constrictive pericarditis • Post-pneumectomy • Decreased atrial compliance post myocardial infarction • Eosinophilic endomyocardial disease • Abnormally long Eustachian valve/Chiari network • Kyphosis • RA lipomatous hypertrophy • RA myxoma
	No right to left pressure gradient	
Ventilation/perfusion mismatch	<ul style="list-style-type: none"> • Chronic obstructive pulmonary disease • Other causes 	
Pulmonary–arteriovenous shunt	<ul style="list-style-type: none"> • Hepatopulmonary syndrome • Pulmonary arteriovenous malformation/fistulae • Osler–Weber–Rendu syndrome 	

management after diagnosis were able to significantly improve symptoms and quality of life.

ACKNOWLEDGEMENTS

None.

CONFLICT OF INTEREST STATEMENT

No conflicts of interest identified.

FUNDING

No sources of funding.

ETHICAL APPROVAL

No approval required.

CONSENT

Verbal consent was obtained from the patient for publication; following death, written consent was obtained from the next of kin for publication.

GUARANTORS

Andre D’Mello and Paul Leong.

REFERENCES

1. Shah AH, Osten M, Leventhal A, Bach Y, Yoo D, Mansour D, et al. Percutaneous intervention to treat platypnea–orthodeoxia syndrome: the Toronto Experience. *JACC Cardiovasc Interv* 2016;**9**:1928–38. <http://dx.doi.org/10.1016/j.jcin.2016.07.003>.
2. Cheng TO. Platypnea-orthodeoxia syndrome: etiology, differential diagnosis, and management. *Catheter Cardiovasc Interv* 1999;**47**:64–6. [http://dx.doi.org/10.1002/\(SICI\)1522-726x\(199905\)47:1<64::AID-CCD15>3.0.CO;2-6](http://dx.doi.org/10.1002/(SICI)1522-726x(199905)47:1<64::AID-CCD15>3.0.CO;2-6).
3. Marini C, Miniati M, Ambrosino N, Formichi B, Tonelli L, Di Ricco G, et al. Dyspnoea and hypoxaemia after lung surgery: the role of interatrial right-to-left shunt. *Eur Respir J* 2006;**28**:174–81. <http://dx.doi.org/10.1183/09031936.06.00006405>.
4. Springer RM, Gheorghiadu M, Chakko CS, Bell GM, Cannon RO, Urquhart J, et al. Platypnea and interatrial right-to-left shunting after lobectomy. *Am J Cardiol* 1983;**51**:1802–3. [http://dx.doi.org/10.1016/0002-9149\(83\)90238-2](http://dx.doi.org/10.1016/0002-9149(83)90238-2).
5. Vacek JL, Foster J, Quinton RR, Savage PJ. Right-to-left shunting after lobectomy through a patent foramen ovale. *Ann Thorac Surg* 1985;**39**:576–8. [http://dx.doi.org/10.1016/S0003-4975\(10\)62005-X](http://dx.doi.org/10.1016/S0003-4975(10)62005-X).
6. Landzberg MJ, Sloss LJ, Faherty CE, Morrison BJ, Bittl JA, Bridges ND, et al. Orthodeoxia-platypnea due to intracardiac shunting relief with transcatheter double umbrella closure. *Cathet Cardiovasc Diagn* 1995;**36**:247–50. <http://dx.doi.org/10.1002/ccd.1810360312>.
7. Carbonelli C, Vezzani G, Grimaldi T, Lococo F, Rapicetta C, Zucchi L. An unusual diagnosis of increasing respiratory failure after lung resection. *Intern Emerg Med* 2014;**9**:891–2. <http://dx.doi.org/10.1007/s11739-014-1134-z>.

8. Godart F, Rey C. Platypnea-orthodeoxia syndrome a probably underestimated syndrome? *Chest* 2001;119:1624–5. <http://dx.doi.org/10.1378/chest.119.5.1624>.
9. Rodrigues P, Palma P, Sousa-Pereira L. Platypnea-orthodeoxia syndrome in review: defining a new disease? *Cardiology* 2012; 123:15–23. <http://dx.doi.org/10.1159/000339872>.
10. Guérin P, Lambert V, Godart F, Legendre A, Petit J, Bourlon F, et al. Transcatheter closure of patent foramen ovale in patients with platypnea-orthodeoxia: results of a multicentric French registry. *Cardiovasc Intervent Radiol* 2005;28:164–8. <http://dx.doi.org/10.1007/s00270-004-0035-3>.