

BRIEF COMMUNICATION

Vitamin D concentration and focal brain atrophy in older adults: a voxel-based morphometric study

Pauline Ali^{1,2} , Matthieu Labriffe^{1,3}, Nastassia Navasiolava⁴ , Marc-Antoine Custaud^{4,5} , Mickaël Dinomais^{1,2}  & Cédric Annweiler^{6,7,8,9,10}  on behalf of the SAM group

¹Laboratoire Angevin de Recherche en Ingénierie des Systèmes, EA7315, University of Angers – Université Angers, Angers, France

²Department of Physical and Rehabilitation Medicine, Angers University Hospital, Angers, France

³Department of Radiology, Angers University Hospital, Angers, France

⁴Clinical Research Center, Angers University Hospital, Angers, France

⁵MITOVASC Institute, UMR CNRS 6015, UMR INSERM 1083, University of Angers, Angers, France

⁶Department of Geriatric Medicine, Angers University Hospital, Angers, France

⁷Memory Clinic, Angers University Hospital, Angers, France

⁸Research Center on Autonomy and Longevity, Angers University Hospital, Angers, France

⁹UPRES EA 4638, University of Angers, Angers, France

¹⁰Department of Medical Biophysics, Schulich School of Medicine and Dentistry, Robarts Research Institute, University of Western Ontario, London, Ontario, Canada

Correspondence

Pauline Ali, Les Capucins, Centre de Réadaptation Spécialisée et Soins Longue Durée, 11 Boulevard Jean Sauvage F-49100 Angers. Tel: +33 2 41 35 15 15; Fax: +33 2 41 35 18 05; E-mail: pauline.ali@hotmail.fr

Funding Information

The research was supported by the University Hospital of Angers, France (eudract number 2014-A01593-44). The funder had no role in study design, data collection, and analysis, decision to publish, or preparation of the manuscript.

Received: 4 December 2019; Revised: 20 January 2020; Accepted: 4 February 2020

Annals of Clinical and Translational Neurology 2020; 7(4): 554–558

doi: 10.1002/acn3.50997

Introduction

Besides its classical function of bone metabolism regulation, vitamin D exhibits multiple biological targets mediated by its nuclear hormone receptor, the Vitamin D Receptor (VDR). VDRs are present in neurons and influence a number of physiological processes in the nervous system including the synthesis of neurotrophic agents, anti-inflammatory factors, and antioxidants.^{1,2} Consistently, lower serum concentrations of 25-hydroxyvitamin D (25OHD) have been associated in older adults with brain

Abstract

Vitamin D is involved in brain health and function. Our objective was to determine whether lower 25-hydroxyvitamin D (25OHD) concentration was associated with focal brain volume reduction in older adults. Serum 25OHD concentration was measured among 53 older adults (72 ± 5 years; 38% female; mean 25OHD = 67.3 ± 20.8 nmol/L). Gray matter volume (GMV) was automatically segmented using voxel-based morphometry with CAT12 software. Covariables were age, gender, education, total intracranial volume, and season. Serum 25OHD was positively associated with GMV in left calcarine sulcus ($P < 0.05$, TFCE, FWE-corrected). We found atrophy of the calcarine sulcus with lower 25OHD concentrations in older adults.

volumetric changes, including lower whole-brain volume and larger lateral ventricles,³ with possible consequences on cognitive decline⁴ and fall risk.⁵ However, it remains unelucidated thus far which brain regions undergo atrophy in the case of hypovitaminosis D, and would explain the decrease in the overall volume of the brain in this population. Better understanding the neuroanatomical correlates of vitamin D status would yet offer a powerful mechanism to act on brain changes in older adults and maintain function later in life. We had the opportunity to examine the associations of serum 25OHD concentration with the

volume of gray matter (GM) in a cohort of community-dwelling older adults, the IRMarche study.⁶ The objective of this cross-sectional analysis was to determine whether lower 25OHD concentrations were associated with focal brain volume reductions.

Methods

Participants

We studied participants from the IRMarche study enrolled between 2015 and 2017. Main inclusion criteria were: age over 60 years, absence of clinical dementia according to the consensual DSM IV criteria, and no neurological, depression, or orthopaedic disorders. We excluded participants with contraindication to MRI. All participants included in the present analysis received a full medical examination, a neuropsychological assessment, a blood test with 25OHD assay, and a 3.0-Tesla magnetic resonance imaging (MRI) scan of the brain.

Serum 25OHD concentration

Blood samples were collected from resting participants at the same time as the brain imaging acquisition. Serum 25OHD concentration, which reflects the vitamin D status, was measured using radioimmunoassay (DiaSorin Inc., Stillwater, MN) in nmol/L at the University Hospital of Angers, France. Vitamin D deficiency was defined for 25OHD concentrations ≤ 50 nmol/L according to the definition of the Institute of Medicine (to convert to ng/mL, divide by 2.496).⁷

MRI procedure

MRI data acquisition

MRI data were acquired on the same 3.0-Tesla MRI scanner (MAGNETOM Trio Tim system, Siemens, Erlangen, Germany) at the University Hospital of Angers, France, using a standard protocol. Acquisition parameters for sequences including a high-resolution 3D T1-weighted volume using a magnetization-prepared rapid acquisition gradient-echo sequence, covering the whole brain (cerebellum included) were: 176 slices, repetition time (TR) = 2300 msec, echo time (TE) = 4.18 msec, slice thickness = 1 mm, field of view (FOV) = 256 × 256, flip angle = 9, voxel size: 1 × 1 × 1 mm³.

Voxel-based morphometry

Voxel-based morphometry across the entire brain were conducted with the Computational Anatomy Toolbox 12 (CAT12) (<http://www.neuro.uni-jena.de/cat>) implemented

in the Statistical Parametric Mapping 12 (SPM12) software (<https://www.fil.ion.ucl.ac.uk/spm/software/spm12/>) using a 2017a Matlab platform (The MathWorks, Natick, MA, USA), following the standard procedure. First 3D T1 volumes were segmented in native-space to obtain three tissues classes: GM, white matter, (WM) and cerebrospinal fluid (CSF).⁸ Then, nonlinear modulation GM and WM volumes were aligned using the default DARTEL (diffeomorphic anatomical registration using exponential Lie algebra) template and were spatially normalized into the Montreal Neurological Institute space (ICBM).⁹ Finally, images were smoothed by an isotropic Gaussian kernel of 8mm full-width at half-maximum (FWHM). All data were inspected and visually checked after the automated procedure by two authors (PA and MD).

Covariates

Age, gender, high education level, season, and total intracranial volume (TIV) were included as potential confounders for the analysis. Education level was reported with a structured questionnaire. Participants who passed at least the Elementary School Recognition Certificate were considered to have higher education level compared with those who did not. The TIV was approximated for each participant by calculating the sum of GM, WM, and CSF maps obtained from the preprocessing steps.

Statistics

Statistical analyses were performed using Tanagra 2.0 software (<http://eric.univ-lyon2.fr/~ricco/tanagra/fr/tanagra.html>), Excel (Microsoft office Professional Plus 2013) and CAT12. For neuroimaging, smoothed, modulated and normalized data were used. With CAT12, morphometric data from participants were associated with a linear regression model with 25OHD concentration. We used threshold-free cluster enhancement (TFCE) for a combined nonparametric analysis about height and size of the effects (<http://www.neuro.uni-jena.de/tfce>), and applied FWE (family wise error) corrected threshold of $P < 0.05$ to control for multiple comparisons. Anatomy toolbox 2.1 was used for anatomical localizations.¹⁰

Ethics

The study was conducted in accordance with the ethical standards set forth in the Helsinki Declaration (1983). The entire study protocol was approved by the Angers Ethical Review Committee (Comité de protection des personnes, CPP ouest II, Angers, France, n° A.C.D 2014-A01593-44, n° CPP: 2014/32). Written informed consent was obtained at enrollment.

Results

Fifty-three participants (mean \pm SD, 72 ± 5 years; 38% female) met the selection criteria and were included in the present analysis. The mean serum 25OHD concentration was 67.3 ± 20.8 nmol/L [95% confidence interval (CI): 62–73] (range, 28–113 nmol/L) among studied participants, and the mean TIV was 1533 ± 154 cm³ [95% CI: 1492–1574] (range, 1212–1822 cm³). Twenty-nine participants (54%) had a high level of education. Twenty subjects (38%) were assessed (blood and MRI) in the autumn, 16 (30%) in the winter, 12 (23%) in the spring, and 5 (9%) in the summer.

Figure 1 illustrates the brain area that were positively associated with the serum 25OHD concentration after adjusting for potential confounders. The VBM analysis identified one cluster of 110 voxels located in the left calcarine sulcus (MNI coordinates (xyz) [−11 −44 8], TFCE = 1366, $P < 0.05$ FWE-corrected). No other regions were positively or negatively associated with serum 25OHD concentration.

Discussion

Our results show that, among community-dwelling older adults, lower serum 25OHD concentration was associated with lower GMV in the left calcarine sulcus specifically. This finding provides insights into elucidating the role of vitamin D in older adults' brain, notably in the treatment of visual stimuli.

A growing body of preclinical evidence supports a role for vitamin D in brain health and morphology. In particular, vitamin D appears to have a trophic function in the differentiation and maturation of neurons by controlling the rate of mitosis and the levels of neurotrophins such as the Nerve Growth Factor (NGF) or the neurotrophin 3.¹ Vitamin D also promotes neuronal calcium homeostasis by downregulating the expression and density of calcium channels, and via the synthesis of calcium-related cytoplasmic proteins such as parvalbumine or calbinding protein.¹ As an illustration, in one study, vitamin D treatment protected neurons against amyloid- β peptide toxicity by downregulating calcium channels and inducing

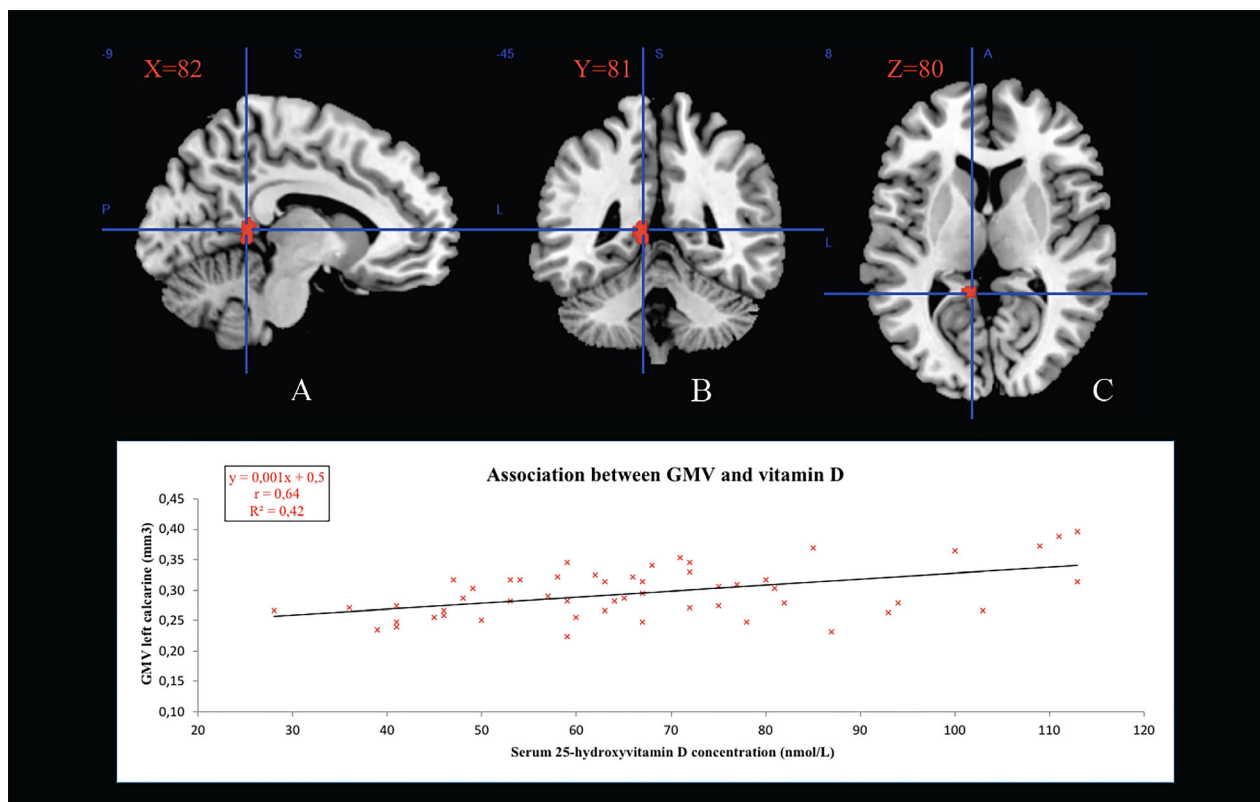


Figure 1. Gray matter region showing a positive association with serum 25-hydroxyvitamin D concentration (red color). GMV: gray matter volume. The statistical map was co-registered and superimposed on 3D-T1 (A) sagittal slice (MNI coordinates: X = 82), (B) coronal slice (MNI coordinates: Y = 81), and (C) axial slice (MNI coordinates: Z = 80) (MNI T1 template available on MRICRON software; TFCE from 10 to 1397). Results are shown with a significance of $P < 0.05$ corrected for multiple comparisons (TFCE, FWE-corrected).

NGF release.¹¹ Vitamin D also has antioxidant effects in cultures of rat mesencephalic cells.¹² Finally, vitamin D exhibits anti-inflammatory effects in the brain,¹³ consistent with reduced inflammatory brain injury following vitamin D repletion.¹⁴

The identification of focal brain atrophy related to vitamin D has received little attention to date. Previous studies mostly focused on the changes of whole-brain volume,¹⁵ ventricular volume,¹⁶ and hippocampal volume^{17,18} according to the vitamin D status.

The present analysis provides additional information on the morphological brain changes related to vitamin D, by providing that some specific subvolumes of GM are affected with lower (i.e., worse) 25OHD concentration. Another recent study evokes that vitamin D deficiency is associated with thinner cingulate cortex.¹⁹

We found that lower 25OHD concentrations were associated with GM atrophy in the left calcarine sulcus. Since the calcarine sulcus is part of the primary visual cortex, which is essential for the conscious treatment of visual stimuli, our result is in agreement with previous epidemiological findings that hypovitaminosis D is associated with reduced visual performance among older adults.²⁰ This association was tentatively explained by the onset of age-related macular degeneration (AMD),²¹ glaucoma,²² or optic neuropathy²³ in the case of hypovitaminosis D. However, no causal relationship has been established thus far, and the result of the present study suggests a novel mechanism possibly explaining how vitamin D influences vision, by an effect on the primary visual cortex trophicity rather than on the eye.

Some potential limitations of our study should be considered. Firstly, the study cohort was restricted to community-dwelling older adults recruited in one single research center who might be unrepresentative of all older adults. Secondly, although we were able to control for important characteristics that could modify the association, residual potential confounders such as the eye condition or reduced sunlight exposure might still be present. Thirdly, the cross-sectional design did not allow any causal inferences making it difficult to determine whether the focal brain atrophy precipitated hypovitaminosis D or whether hypovitaminosis D played a role in the onset of focal brain atrophy. Fourthly, VBM has been criticized because of segmentation and normalization defects. Segmentation of brain into GM and WM is a major difficulty due to partial volume effects at the boundary between GM and WM, and because of mislabeling. We minimized these limitations by using SPM12 software that performs better than previous versions.

In conclusion, we found that lower serum 25OHD concentration was associated in older adults with GM atrophy in the calcarine sulcus, part of the primary visual cortex.

This finding highlights for the first time that specific brain areas are altered with hypovitaminosis D, and helps understanding the effects of vitamin D on brain health and function in older adults, notably the brain treatment of visual stimuli. Further prospective observational cohorts and randomized clinical trials, preferentially on a variety of adult populations, are needed to clarify whether those with hypovitaminosis D are more likely to experience loss of GM in the visual cortex, and whether vitamin D supplementation could prevent or limit this change.

Acknowledgments

The authors warmly thank the nurses of the Clinical Research Center, the technicians of the Department of Radiology at the University hospital of Angers for their sustained help with the acquisition of the MRI data, and the participants for their kind contribution in this challenging research. We thank Elena Tomilovskaya from the Institute of Biomedical Problems, Russian Academy of Sciences, Moscow, Russia for her help.

Author Contributions

Each author has made substantial contributions to the conception or design of the work; or the acquisition, analysis, or interpretation of data; or the creation of new software used in the work; or have drafted the work or substantively revised it; AND has approved the submitted version; AND agrees to be personally accountable for the author's own contributions and for ensuring that questions related to the accuracy or integrity of any part of the work, even ones in which the author was not personally involved, are appropriately investigated, resolved, and documented in the literature. Mickaël Dinomais has full access to all of the data in the study, takes responsibility for the data, the analyses and interpretation, and the conduct of the research, and has the right to publish any and all data, separate and apart from the attitudes of the sponsor. Study concept and design: Mickaël Dinomais, Cédric Annweiler, Marc-Antoine Custaud. Acquisition of data: Matthieu Labriffe, Mickaël Dinomais, Nastassia Navasiolava. Analysis and interpretation of data: Pauline Ali, Mickaël Dinomais, Cédric Annweiler. Drafting of the manuscript: Pauline Ali, Mickaël Dinomais, Cédric Annweiler. Critical revision of the manuscript for important intellectual content: Matthieu Labriffe, Mickaël Dinomais, Nastassia Navasiolava, Pauline Ali, Marc-Antoine Custaud. Obtained funding: Mickaël Dinomais. Statistical expertise: Pauline Ali, Mickaël Dinomais. Administrative, technical, or material support: Nastassia Navasiolava, Mickaël Dinomais, Marc-Antoine Custaud. Study supervision: Mickaël Dinomais.

Conflict of Interest

C. Annweiler serves as an editor for *Maturitas*. All authors declare they do not have any other financial and personal conflicts of interest with this manuscript.

References

- Annweiler C, Schott A-M, Berrut G, et al. Vitamin D and ageing: neurological issues. *Neuropsychobiology* 2010;62:139–150.
- Harms LR, Burne THJ, Eyles DW, McGrath JJ. Vitamin D and the brain. *Best Pract Res Clin Endocrinol Metab* 2011;25:657–669.
- Annweiler C, Annweiler T, Montero-Odasso M, et al. Vitamin D and brain volumetric changes: systematic review and meta-analysis. *Maturitas* 2014;78:30–39.
- Annweiler C, Dursun E, Féron F, et al. ‘Vitamin D and cognition in older adults’: updated international recommendations. *J Intern Med* 2015;277:45–57.
- Bischoff-Ferrari HA, Dawson-Hughes B, Staehelin HB, et al. Fall prevention with supplemental and active forms of vitamin D: a meta-analysis of randomised controlled trials. *BMJ* 2009;339:b3692–b3692.
- Labriffe M, Annweiler C, Amirova LE, et al. Brain activity during mental imagery of gait versus gait-like plantar stimulation: a novel combined functional MRI paradigm to better understand cerebral gait control. *Front Hum Neurosci* 2017;11:106.
- Ross AC, Manson JE, Abrams SA, et al. The 2011 report on dietary reference intakes for calcium and vitamin D from the Institute of Medicine: what clinicians need to know. *J Clin Endocrinol Metab* 2011;96:53–58.
- Ashburner J, Friston KJ. Voxel-based morphometry—the methods. *NeuroImage* 2000;11:805–821.
- Ashburner J. A fast diffeomorphic image registration algorithm. *NeuroImage* 2007;38:95–113.
- Eickhoff SB, Stephan KE, Mohlberg H, et al. A new SPM toolbox for combining probabilistic cytoarchitectonic maps and functional imaging data. *NeuroImage* 2005;25:1325–1335.
- Dursun E, Gezen-Ak D, Yilmazer S. A novel perspective for Alzheimer’s disease: vitamin D receptor suppression by amyloid- β and preventing the amyloid- β induced alterations by vitamin D in cortical neurons. *J Alzheimers Dis*. 2011;23:207–219.
- Ibi M, Sawada H, Nakanishi M, et al. Protective effects of 1 α ,25-(OH)(2)D(3) against the neurotoxicity of glutamate and reactive oxygen species in mesencephalic culture. *Neuropharmacology* 2001;40:761–771.
- Moore ME, Piazza A, McCartney Y, Lynch MA. Evidence that vitamin D3 reverses age-related inflammatory changes in the rat hippocampus. *Biochem Soc Trans* 2005;33(Pt 4):573–577.
- Mowry EM, Waubant E, McCulloch CE, et al. Vitamin D status predicts new brain magnetic resonance imaging activity in multiple sclerosis. *Ann Neurol* 2012;72:234–240.
- Buell JS, Dawson-Hughes B, Scott TM, et al. 25-Hydroxyvitamin D, dementia, and cerebrovascular pathology in elders receiving home services. *Neurology* 2010;74:18–26.
- Annweiler C, Montero-Odasso M, Hachinski V, et al. Vitamin D concentration and lateral cerebral ventricle volume in older adults. *Mol Nutr Food Res* 2013;57:267–276.
- Karakis I, Pase MP, Beiser A, et al. Association of serum vitamin D with the risk of incident dementia and subclinical indices of brain aging: the Framingham Heart Study. *J Alzheimers Dis* 2016;51:451–461.
- Al-Amin M, Bradford D, Sullivan RKP, et al. Vitamin D deficiency is associated with reduced hippocampal volume and disrupted structural connectivity in patients with mild cognitive impairment. *Hum Brain Mapp* 2019;1:394–406.
- Foucault G, Duval GT, Simon R, et al. Serum vitamin D and cingulate cortex thickness in older adults: quantitative MRI of the brain. *Curr Alzheimer Res* 2019;16:1063–1071.
- Beauchet O, Milea D, Graffe A, et al. Association between serum 25-hydroxyvitamin D concentrations and vision: a cross-sectional population-based study of older adults. *J Am Geriatr Soc* 2011;59:568–570.
- Annweiler C, Drouet M, Duval GT, et al. Circulating vitamin D concentration and age-related macular degeneration: Systematic review and meta-analysis. *Maturitas* 2016;88:101–112.
- Goncalves A, Milea D, Gohier P, et al. Serum vitamin D status is associated with the presence but not the severity of primary open angle glaucoma. *Maturitas* 2015;81:470–474.
- Annweiler C, Beauchet O, Bartha R, et al. Association between serum 25-hydroxyvitamin D concentration and optic chiasm volume. *J Am Geriatr Soc* 2013;61:1026–1028.