

ORIGINAL PAPER

Potential Role of Lung Ventilation Scintigraphy in the Assessment of COPD

Vesna Cukic¹, Amela Begic²Clinic for pulmonary disease and TB "Podhrastovi", Clinical center of Sarajevo University¹
Institute for nuclear medicine, Clinical center of Sarajevo University²

Corresponding author: Vesna Cukic, MD. Phone: 00 387 061 480 228. E-mail : vesna-cukic@hotmail.com.

ABSTRACT

Objective: To highlight the importance of the lung ventilation scintigraphy (LVS) to study the regional distribution of lung ventilation and to describe most frequent abnormal patterns of lung ventilation distribution obtained by this technique in COPD and to compare the information obtained by LVS with the that obtained by traditional lung function tests. **Material and methods:** The research was done in 20 patients with previously diagnosed COPD who were treated in Intensive care unit of Clinic for pulmonary diseases and TB "Podhrastovi" Clinical Center, University of Sarajevo in exacerbation of COPD during first three months of 2014. Each patient was undergone to testing of pulmonary function by body plethysmography and ventilation/perfusion lung scintigraphy with radio pharmaceuticals Technegas, 111 MBq Tc-99m-MAA. We compared the results obtained by these two methods. **Results:** All patients with COPD have a damaged lung function tests examined by body plethysmography implying airflow obstruction, but LVS indicates not only airflow obstruction and reduced ventilation, but also indicates the disorders in distribution in lung ventilation. **Conclusion:** LVS may add further information to the functional evaluation of COPD to that provided by traditional lung function tests and may contribute to characterizing the different phenotypes of COPD. **Key words:** COPD, lung functional tests, LVS

1. INTRODUCTION

Redistribution of pulmonary ventilation is the one of the leading disorders in patients with chronic obstructive pulmonary disease (COPD) and is one of the targets of treatments, either by drugs or mechanical ventilation. Lung ventilation scintigraphy (LVS) is a well known technique that is used to study the distribution of ventilation (1) However, its application in current clinical practice has been poorly developed mainly because of methodological problems (1).

Several patterns of distribution of pulmonary ventilation can be described in different airway diseases including COPD. These abnormalities are too subtle to be recognized by traditional lung function tests (1).

Wider use of LVS may increase the knowledge and the management of COPD. Inhaled radio nuclide – labeled aerosols remain the most important clinical tools used to assess regional ventilation (2). However, Robertson (3) points out, according to earlier observation (4), that aerosol deposition on the large conducting airways can significantly impair evaluation of the regional distribution of ventilation in patients with severe airflow obstruction.

Robertson (3) suggests that this artifact can be minimized with the use of Technegas as the aerosol labels, since the mean particle diameter is < 0.01 micron. This size gives a higher functional deposition due to enhanced motion and is small enough to avoid impacting on airway walls. A ventilation lung scan performed with a gaseous tracer yields a picture of

the total air space in the lungs. Inhaled particles have a smaller diffusion capacity; thus, they are carried only by convective airflow and can be considered as tracers for mass transport (respiratory space up to the 21st order bronchioles) (5, 6).

Qualitative evaluation of the ventilation consists of visual analysis of the intrapulmonary distribution of the inhaled radioactive aerosols, which allows identification of the predominant pattern of deposition (7). The ND (normal deposition) pattern is characterized by normal distribution of radioactivity in both lung fields with clearly defined peripheral lung edges and a physiological apex-to-base gradient.

The ID (inhomogeneous deposition) pattern shows patchy areas in the peripheral regions of the lungs due to altered deposition of the particles, so that the peripheral pulmonary edges are irregular or incomplete. In the CD (central deposition) pattern, radioactivity is predominant in the hilar-parahilar region (i.e. close to the first of central bronchial generations) with an associated background of ID ventilation. The SD (spotty deposition) pattern (which corresponds to the extreme degree of inhomogeneity for ID of the inhaled particles) is characterized by focal deposition of radioactivity (spots) within low-radioactivity count areas.

Finally, the MD (mixed deposition) pattern shows intermediate features in the distribution of ventilation. The CD that characterizes the MD can be associated not only with an ID pattern but also with SD

Serial number	Name (initials)	age	sex	Functional testing	LVS	
				FEV1 (%)	Distribution of ventilation in left lung	Distribution of ventilation in right lung
1.	KR	68	m	60%	ID; rv in two segments of upper lobe	ID; rv in two segments of upper lobe
2.	SS	77	m	65%	very rv in lower lobe	Normal?
3.	TD	48	m	59%	mild ID of whole lung	mild ID of whole lung
4	ST	65	m	60%	ID; rv in whole lung	ID; rv in whole lung
5	DR	57	m	45%	ID; very rv in whole lung	ID; very rv in whole lung
6	BA	73	f	69%	ID; rv in whole lung	ID; rv in whole lung
7	BI	64	m	39%	ID,CD; rv in whole lung	ID,CD; rv in whole lung
8	BT	66	m	69%	ID; rv in upper lobe	ID;rv inapicalsegmentofupper lobe
9	AG	72	f	50%	ID;rv in whole lung	ID; rv in whole lung expressed than left
10	DH	60	m	20%	ID, CD; rv in whole lung	ID,CD; rv in whole lung
11	BG	78	f	50%	ID, CD; rv in whole lung	ID,CD; rv in whole lung
12	MD	58	f	25 %	ID, CD; rv in whole lung	ID,CD; rv in whole lung
13	MR	56	f	20 %	ID, CD,SD; rv in whole lung	ID,CD, SD; rv in whole lung
14	PS	67	m	30%	ID, CD; rv in whole lung	ID, CD; rv in whole lung
15	ZH	48	m	50 %	ID, CD; rv in whole lung	ID, CD; rv in whole lung
16	MS	57	f	65%	ID; rv in whole lung	ID; rv in whole lung
17	CV	45	m	58%	ID; rv in two segments lower lobe	ID; rv in two segments of upper lobe
18	MC	70	f	35%	ID, CD; rv in whole lung	ID, CD,SD; rv in whole lung
19	MD	57	f	16%	ID, CD, SD; rv in whole lung	ID, CD, SD; rv in whole lung
20	SK	45	f	59%	ID , CD ; rv in whole lung	ID , CD ; rv in whole lung

Table 1. Results of functional testing and LVS. Legend: %FEV1= (forced expiratory volume in one second) expressed as per cent of normal value for that patient according to sex, age, height and weight. LVS =lung ventilation scintigraphy rv= reduced lung ventilation. ID= inhomogeneous deposition pattern of radioactivity. CD=central deposition pattern of radioactivity. SD =spotty deposition pattern of radioactivity m=male; f= female

pattern and with a mixed CD and SD pattern (1, 4, 7, 8). The use of radioactive aerosols provides more detailed information on regional ventilation abnormalities caused by COPD (4, 7).

Four specific patterns bearing a well defined pathophysiological meaning have been identified in addition to the normal deposition (ND) pattern. These are the inhomogeneous deposition (ID) pattern, the central deposition (CD) pattern, the spotty deposition (SD) pattern and the mixed deposition (MD) pattern (1,4,7,8).

In COPD the redistribution of lung ventilation is determined by the airway obstruction and the parenchymal damage because of associated emphysema. A mixture of ID, CD and SD (which is consistent with a diagnosis of emphysema) may be observed (1, 4, 7, 8).The abnormality in regional lung ventilation may contribute to explain the pathophysiological abnormalities observed in this disease (9, 10, 11). LVS may add further information to the functional evaluation of COPD, in addition to that obtained from the traditional lung function tests, and may contribute to characterizing the different phenotypes of COPD (1).

2. OBJECTIVE

To highlight the importance of the LVS to study the regional distribution of lung ventilation and to de-

scribe most frequent abnormal patterns of lung ventilation distribution obtained by this technique in COPD and to compare the information obtained by LVS with the that obtained by traditional lung function tests- body plethysmography.

3. MATERIAL AND METHODS

The research was done in 20 patients with previously diagnosed COPD who were treated in Intensive care unit of Clinic for pulmonary diseases and TB "Podhrastovi" CCU Sarajevo in exacerbation of illness during first three months of 2014. They were randomly selected. Patients were of different age, different sex and different duration of illness. Each patient was undergone to testing of pulmonary function: by traditional lung function tests: body plethysmography by standardized methodology, and ventilation/perfusion lung scintigraphy with radio pharmaceuticals Technegas,111 MBq Tc -99m-MAA iv. The functional testing was done in Clinic "Podhrastovi", LVS was done in The institute for nuclear medicine. We compared the results obtained by these two methods.

Before doing LVS all patients did a complete spirometric processing as follows: FVC (forced vital capacity), FEV1 (forced expiratory volume in one second), flow-volume curve, total pulmonary resis-

tance (Rt) including bronchodilator test, RV (residual volume), TLC (total lung capacity). The degree of impairment of lung function is primarily determined by FEV1 because it is the most objective parameter of lung function which indicates the obstructive and restrictive disorders of pulmonary function and indicates the type and degree of impairment of ventilatory pulmonary function. By ventilation/perfusion lung scintigraphy we followed the airflow obstruction and distribution of ventilation in both lungs. In all patients LVS showed the reduced ventilation and different types of distribution of lung ventilation.

4. RESULTS

Results shown at the Table 1 show that all patients have airflow obstruction (measured by FEV1), and disordered distribution of lung ventilation diagnosed by LVS

All patients have different degree of airflow obstruction according to FEV1 which is the basement of obstructive lung diseases including COPD, and all of them have different type of redistribution of ventilation. All have reduced ventilation, ID pattern of inhomogeneity of lung ventilation, alone or in combination with CD or with CD and SD pattern.

The examples of body plethysmography and LSV for patient number 19 are shown on Figure 1 and 2.

On Figure 1 body plethysmography shows the high degree of airflow obstruction

On Figure 2 ventilation- perfusion scintigraphy shows the reduction and redistribution of lung ventilation

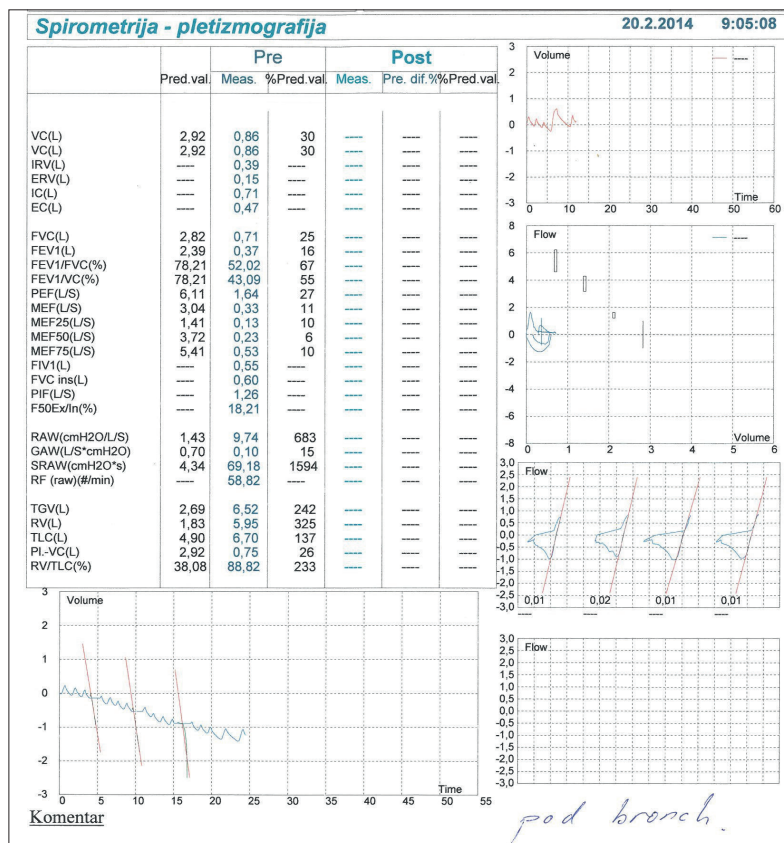


Figure 1. Bodyplethysmography of patient number 19

5. DISCUSSION

COPD is one of the obstructive pulmonary diseases. It is characterized by airflow obstruction and redistribution of ventilation. In COPD, the distribution of lung ventilation is determined by the airway obstruction and the parenchymal damage because of associated emphysema. Redistribution of pulmonary ventilation is one of the targets of treatments. Disorders of distribution of pulmonary ventilation are too subtle to be recognized by traditional lung function tests (1, Lung ventilation scintigraphy (LVS) is a well known technique that is used to study the distribution of ventilation. However, its application in current practice has been poorly developed mainly because of methodological problems. (1)

The use of radioactive aerosols provides more detailed information on regional ventilation abnormalities caused by COPD (4, 7). In particular, four specific patterns bearing a well defined pathological meaning have been identified in addition to the normal deposition (ND) pattern. These are the inhomogeneous deposition (ID) pattern, the central deposition (CD) pattern, the spotty deposition (SD) pattern and the mixed deposition (MD) pattern (1,4,7,8). This study was done on 20 patients with COPD. Each of them had damaged pulmonary function

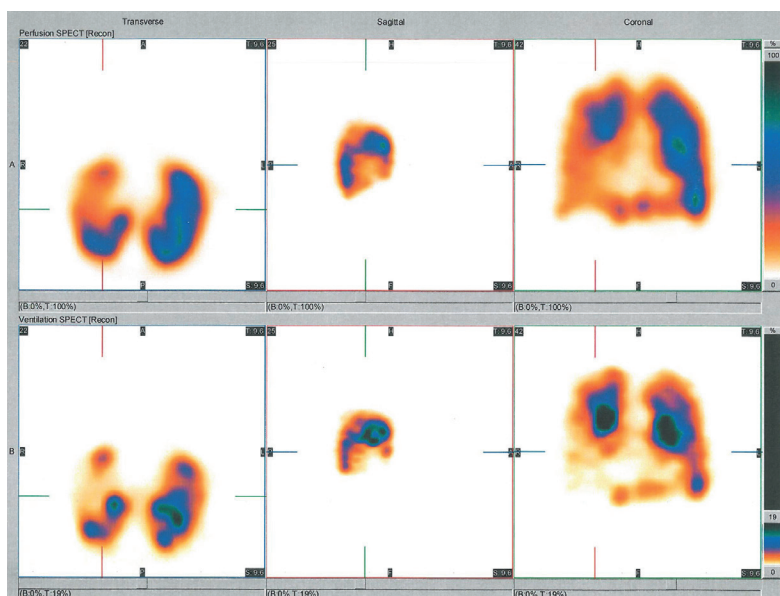


Figure 2. Ventilation/perfusion scintigraphy of patient number 19.

by examined by spiropletizmographic processing, but LVS gave information about the distribution of lung ventilation. We did not repeat LVS after the treatment (either drugs or mechanical ventilation) so we have no data of changing of distribution of lung ventilation after healing acute exacerbation of COPD.

In COPD mixture of ID, CD and SD may be observed that indicates on different degree of airflow obstruction in different parts of lungs. All our examined patients have different degree of airflow obstruction according to FEV1 which is the basement of obstructive lung diseases including COPD, and all of them have different type of redistribution of ventilation. All have reduced ventilation, ID pattern of inhomogeneity of lung ventilation, alone or in combination with CD or with CD and SD pattern (mixed pattern). That indicates on different degree of airflow obstruction in different parts of lungs most expressed in peripheral airways and the association of airflow obstruction and parenchymal lung damage e.g. emphysema.

There is the need to continue this examination for further evaluation of this technique (LVS) so to include this technique in routine diagnostics and assessment of COPD to provide the improvement in therapy of this illness which is the fourth of leading cause of death in the world (12). Preliminary observations suggest that the sensitivity of LVS for detecting abnormalities in subjects with airway obstructive diseases is high (>90%). Also, the specificity of specific patterns of lung ventilation (such as CD or SD for asthma or emphysema, respectively or ID for COPD) has been found to be high (13).

6. CONCLUSION

LVS may add further information to the functional evaluation of COPD, in addition to information obtained from the traditional lung functional tests, and may contribute to characterizing the different phenotypes of COPD and to improvement in diagnostics and therapy of COPD.

CONFLICT OF INTEREST: NONE DECLARED.

REFERENCES

1. Fazzi P, Alberteli R, Grana M, Paggiaro PL. Lung ventilation scintigraphy in the assessment of obstructive lung disease. *Breath*. 2009; 34(3): 252-262.
2. Anderson PJ, Dolowich MB. Aerosols as diagnostic tools. *J Aerosol Med*. 1994; 7: 77-88.
3. Robertson HT. Measurement of regional ventilation by aerosol deposition. In: Histala MP, Robertson HT. *Complexity in Structure and Function of the Lung*. New York, Marcel Dekker Inc, 1998: 379-399.
4. Santolicandro A, Rushi S, Formai E, Guintini C. Imaging of ventilation in chronic obstructive pulmonary disease. *J Thorac Imag*. 1986; 1: 36-53.
5. Landhal HD. On the removal of air-born droplets from the human respiratory tract: I. The lung. *Bull Math Biophysics*. 1950; 43-56.
6. Weibel ER. *Morphometry of the Human Lung*. Berlin, Goettingen, Heidelberg, Springer 1965: pp 139
7. Santolicandro A, Guintini C. Patterns of deposition of labeled mono-dispersed aerosols in obstructive lung disease. *J Nucl Med Allied Sci*. 1979; 23: 115-127.
8. Agnew JE, Wood EJ, Sutton PP. Krypton- 81m and 5-micron radio-aerosol images in asymptomatic asthma: a blind marking assessment. *Eur J Nucl Med*. 1984; 9: 502-507.
9. Kaneta T, Yamazaki T, Maruoka S. Correlation of pulmonary perfusion volume analysis with a pulmonary function in emphysema. *Kaku Igaku*. 2000; 37: 359-364.
10. Uchida K, Nakayama H. An application of semiquantitative analysis of pulmonary scintigram in tuberculosis sequels. *Kaku Igaku*. 1996; 33: 753-757.
11. Uchida K, Nakayama H, Yamagami I, Takahashi H. Correlation of semiquantitative analysis of the distribution of pulmonary perfusion with pulmonary function in chronic obstructive pulmonary disease. *Kaku Igaku*. 1997; 34: 145-149.
12. GOLD (Global Initiative for Chronic Obstructive Lung Disease) –<http://www.goldcopd.org>. : 1-100
13. Fazzi P, Borso E, Alberteli L. Regional ventilation with ^{99m}Tc nanocolloidal aerosol and perfusion lung scans versus lung function tests by testing new ventilation equipment. *QJ Nucl Med*. 2002; 46: Suppl.1: 90.