

Research Article

A Retrospective Study of a Chinese Traditional Medicine YIKEER in the Treatment of Verruca Patients in Liaoning District

S. B. Jiang , Y. S. Lu, Y. H. Zhang , Y. Wu , H. X. Wang , X. H. Gao, and H. D. Chen

Department of Dermatology, The First Hospital of China Medical University, Shenyang, China

Correspondence should be addressed to Y. Wu; jlwuyan@126.com and H. X. Wang; 1106525287@qq.com

Received 24 July 2019; Revised 31 October 2019; Accepted 4 December 2019

Academic Editor: Min Li

Copyright © 2019 S. B. Jiang et al. This is an open access article distributed under the Creative Commons Attribution License, which permits unrestricted use, distribution, and reproduction in any medium, provided the original work is properly cited.

Background. There are many possible ways to treat verruca, but no one is the single perfect treatment. YIKEER is a kind of compound preparation of Chinese traditional medicine, which has been used in the treatment of verruca for several years. **Aim.** To confirm the effects of YIKEER for verruca. **Method.** Patients with verruca vulgaris, verruca plantaris, or verruca plana were instructed to apply YIKEER stock solution or diluent to the lesions once or twice daily for 5–7 days. Then, the YIKEER was ceased for 3–4 days, and sea buckthorn oil was used for wound repairing. The total procession was defined as one session. **Result.** Respective 88.05% verruca vulgaris patients, 86.03% verruca plantaris patients, and 82.42% verruca plana patients achieved complete response. Most patients gained complete or partial responses after 4 treatment sessions. The percentage of patients who achieved at least 50% improvement was 90.34% for verruca vulgaris, 90.60% for verruca plantaris, and 80.91% for verruca plana after 4-session treatment. The efficacy of verruca vulgaris or verruca plantaris was better than that of verruca plana. **Conclusion.** YIKEER is an effective, safe, and well-tolerated agent for treating verruca including verruca vulgaris, verruca plantaris, and verruca plana.

1. Introduction

Verruca can be divided into four typical types, including verruca vulgaris, verruca plantaris, verruca plana, and genital warts. They are caused by different strains of human papilloma virus (HPV) and present as benign epidermal proliferation. Verruca vulgaris is known as a common wart, and it tends to affect epithelial tissues and mucous membranes [1]. Verruca plantaris tends to occur at points on the foot where the most pressure is applied. The virus is thought to make its way into the foot via small abrasions in the stratum corneum [2]. Verruca plana is represented as a slightly elevated, flat-topped papule. It is relatively common in teenagers and does not always show Koebner's phenomenon which is a very useful clue for the clinical diagnosis [3].

There are many possible ways to treat verruca including topical medications, intralesional immunotherapy, cryotherapy, laser, and photodynamic therapy [4]. These treatments are considered to be similar in terms of efficacy [5]. The choice may be determined by factors such

as wart location, availability of treatments at individual centers, convenience of use, aesthetic impact, patient preference, cost, and adverse effects. Besides, treatment responses are various with different types of verruca. Verruca plantaris tends to be more resistant to treatment than verruca at other sites. Warts with short-term duration are more likely to be cleared than those with long-term duration [5]. Although many local treatments are available, the problems in improving efficacy, decreasing recurrence rate, and ulcer formation still need to be solved. In some cases, verruca continues to increase in size and distribution, and it may become more resistant to treatment over time [6–8].

Natural medicines, including traditional Chinese medicines (TCMs), are commonly used for the treatment of skin disorders, especially for topical use. For example, Chyanprash shows a protective effect on skin photoaging by inhibiting roughness, erythema, and edema in UVB-induced hairless mice [9]; extracts and bioactive compounds from *Hygrophila auriculata* have been found to possess antimicrobial, antioxidant, and anti-inflammatory activities and

can alleviate skin itching and edema [10]; juglone and its synthetic triazolyl analogues present cytotoxic activity against skin cancer [11].

YIKEER is a kind of compound preparation of TCM. The main ingredients include *Brucea javanica*, *Folium Isatidis*, *Radix sophorae flavescentis*, *Lonicera japonica*, *Astragalus membranaceus*, *Fructus cnidii*, *Galla chinensis* [12, 13]. Phytochemical studies revealed that *Brucea javanica* is a rich source of quassinoids and oil-like lipids [14] and can make the epithelial cell degeneration and necrosis. *Folium isatidis* and *Radix sophorae flavescentis* have antibacterial, antiviral, antipyretic, and anti-inflammatory properties and can promote immunological response [15]. *Lonicera japonica*, *Astragalus membranaceus*, *Fructus cnidii*, and *Galla chinensis* have been reported to have many biological activities, such as antioxidative, anti-inflammatory, antibacterial, antiviral, and antifungal activities [16–18].

In China, YIKEER has been used in the treatment of verruca for several years [12, 13, 19]. The present retrospective study summarized the clinical results of YIKEER on verruca patients in Liaoning district.

2. Method

2.1. Enrollment of Patients. The study was conducted in 5 cities of Liaoning district, including Shenyang, Huludao, Dandong, Fuxin, and Jinzhou. The period of study was from January 2014 to October 2018. The patients were diagnosed as verruca vulgaris, verruca plantaris, or verruca plana, according to the diagnostic criteria [20]. The exclusion criteria of patients were pregnancy or lactating at the time of admission, allergic to any of the components of the study medications, with allergic skin diseases such as eczema, contact dermatitis, and other serious skin diseases, with other infectious diseases such as human immunodeficiency virus (HIV) infection, hepatitis B or C virus infection, or syphilis.

2.2. Components of the Medicine. The YIKEER kit was manufactured by Beijing PaiteBoen Biological Technology Co., Ltd. The components of the YIKEER liquid contained 5 main ingredients including *Folium isatidis* (1840 mg/L), *Radix sophorae flavescentis* (1600 mg/L), *Lonicera japonica* (1027 mg/L), *Fructus kochiae* (208 mg/L), and gallnut (5568 mg/L) and 4 secondary ingredients including *Astragalus membranaceus*, *Brucea javanica*, *Galla Chinensis*, and *Fructus cnidii*. A bottle of sea buckthorn oil was also included in the kit for repairing the wound.

2.3. Treatment Method. Patients with verruca vulgaris or verruca plantaris were instructed to apply YIKEER to the lesions with plastic occluding for at least 2 hours once daily for 5–6 days. For hard and big verruca plana, YIKEER was applied twice daily for 7 days without occlusion. For short-term and multiple verruca plana, the YIKEER was diluted to 1 : 10 to 1 : 20 with water and compressed with gauze for 15 to 20 minutes twice daily for 5–6 days. Then, the YIKEER was

ceased for 3–4 days, and sea buckthorn oil was used. The total procession was defined as one session. If the warts did not disappear, another session was required. The maximal treatment period was 3 months (9 sessions). If the warts disappeared, the 1 : 20 diluted YIKEER was applied to the local skin for 2 weeks to maintain the efficacy and prevent the recurrence.

During the treatment period, if any allergic or aggravated signs including itching, severe erythema, severe edema, or exudation appeared, the drug should be stopped immediately and sea buckthorn oil was applied until the conditions improved.

2.4. Efficacy Assessments. The patients were required to take photos at baseline and when each session completed. Two investigators separately evaluated the clinical response based on the photos. The efficacy of the treatment was assessed by counting the number of lesions as follows: complete response: disappearance of all lesions; partial response (3 grades): excellent (75% < 100%), good (50% < 75%), poor (25% < 50%); no response: <25% reduction in number. The recurrence was assessed by inquiring the patients by telephone at 3-month follow-up.

2.5. Statistical Analysis. SPSS Version 20.0 (SPSS, Inc., Chicago, IL, USA) was used for all analyses. Nonparametric tests including Kruskal–Wallis test and Mann–Whitney test were used for comparisons. A *p*-value of <0.05 was considered to indicate statistical significance.

3. Results

3.1. Patient Characteristics. A total of 1860 patients with 614 verruca vulgaris patients (51.79% male and 48.21% female), 716 verruca plantaris patients (47.49% male and 52.51% female), and 530 verruca plana patients (31.70% male and 68.30% female) were recruited in the study from January 2014 to October 2018. The mean age of patients with verruca vulgaris, verruca plantaris, and verruca plana was 36 years, 33 years, and 29 years, respectively. During the period, respective 28 verruca vulgaris, 28 verruca plantaris, and 18 verruca plana patients did not return for the follow-up visit. So, a total of 1786 patients, including 586 verruca vulgaris, 688 verruca plantaris, and 512 verruca plana patients, completed the treatment and evaluation. The demographic data are summarized in Table 1.

3.2. The Overall Efficacies. For verruca vulgaris, verruca plantaris, or verruca plana, respective 88.05%, 86.03%, and 82.42% patients achieved complete response, and only 4.78%, 4.37%, and 7.42% patients showed no response to the overall treatments (Tables 2–4). No significant differences were observed among the efficacies of the three diseases ($\chi^2 = 4.311$, $p > 0.05$). The treatment duration of verruca vulgaris or verruca plantaris was at least 2 sessions and that of verruca plana was at least 3 sessions, and most patients needed 4 or even more sessions (Table 1). For the three

TABLE 1: Demographic characteristics of the patients with verruca vulgaris, verruca plantaris, and verruca plana.

	Verruca vulgaris	Verruca plantaris	Verruca plana
No. of patients	614	716	530
Gender			
Male (<i>n</i>)	318	340	168
Female (<i>n</i>)	296	376	362
Mean age (range)	36 (3–69) years	33 (4–67) years	29 (6–55) years
Treatment duration			
1 session (<i>n</i>)	0	0	0
2 sessions (<i>n</i>)	8	8	0
3 sessions (<i>n</i>)	40	42	30
4 sessions (<i>n</i>)	306	316	196
5 sessions (<i>n</i>)	56	152	102
6 sessions (<i>n</i>)	38	14	36
7 sessions (<i>n</i>)	40	26	30
8 sessions (<i>n</i>)	28	14	12
9 sessions (<i>n</i>)	70	116	106

TABLE 2: Lesion therapeutic response over the sessions of treatments on verruca vulgaris.

	Complete response		Partial response		No response
	100%	75%–100%	50%–75%	25%–50%	<25%
Session 1 (<i>N</i> = 586)	0	6	36	510	34
Session 2 (<i>N</i> = 586)	6	36	264	248	32
Session 3 (<i>N</i> = 578)	36	298	54	158	32
Session 4 (<i>N</i> = 538)	202	66	118	22	30
Session 5 (<i>N</i> = 232)	58	34	86	24	30
Session 6 (<i>N</i> = 176)	30	44	60	14	30
Session 7 (<i>N</i> = 138)	20	74	16	0	28
Session 8 (<i>N</i> = 98)	24	46	0	0	28
Session 9 (<i>N</i> = 70)	0	42	0	0	28

TABLE 3: Lesion therapeutic response over the sessions of treatments on verruca plantaris.

	Complete response		Partial response		No response
	100%	75%–100%	50%–75%	25%–50%	<25%
Session 1 (<i>N</i> = 686)	0	14	124	512	38
Session 2 (<i>N</i> = 686)	6	42	314	288	36
Session 3 (<i>N</i> = 680)	34	344	200	68	34
Session 4 (<i>N</i> = 638)	316	220	42	26	34
Session 5 (<i>N</i> = 322)	138	116	30	6	32
Session 6 (<i>N</i> = 170)	14	110	16	0	30
Session 7 (<i>N</i> = 156)	20	88	16	0	30
Session 8 (<i>N</i> = 130)	14	72	14	0	30
Session 9 (<i>N</i> = 116)	22	48	16	0	30

TABLE 4: Lesion therapeutic response over the sessions of treatments on verruca plana.

	Complete response		Partial response		No response
	100%	75%–100%	50%–75%	25%–50%	<25%
Session 1 (<i>N</i> = 512)	0	36	186	248	42
Session 2 (<i>N</i> = 512)	0	52	200	218	42
Session 3 (<i>N</i> = 512)	6	206	142	116	42
Session 4 (<i>N</i> = 482)	194	124	72	52	40
Session 5 (<i>N</i> = 286)	62	78	82	24	40
Session 6 (<i>N</i> = 184)	36	72	16	20	40
Session 7 (<i>N</i> = 148)	20	52	20	16	40
Session 8 (<i>N</i> = 118)	10	42	28	0	38
Session 9 (<i>N</i> = 106)	16	26	26	0	38

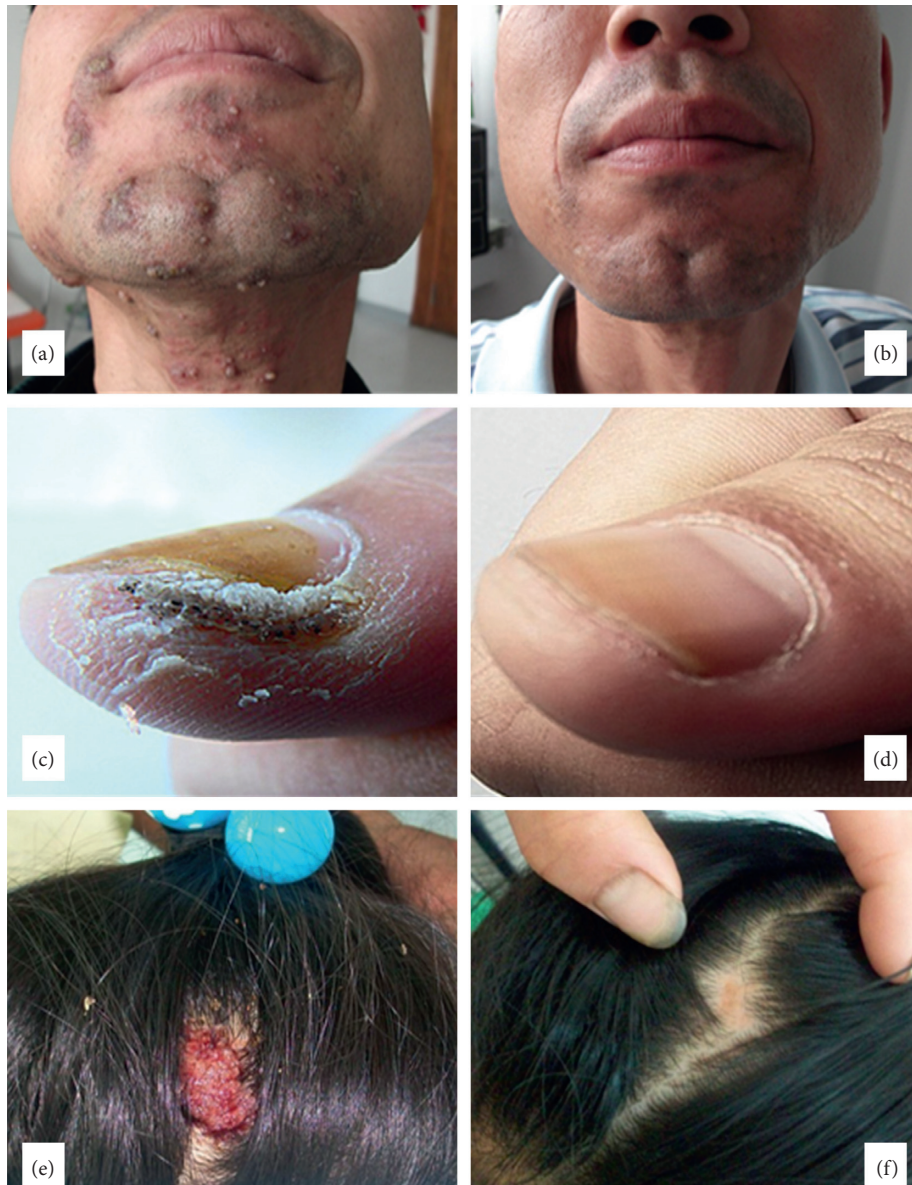


FIGURE 1: Three patients with verruca vulgaris before (a, c, e) and after (b, d, f) the treatment.

diseases, most patients gained complete or partial responses after 4 treatment sessions, and the number of patients gradually decreased with the continuous treatment sessions.

After 1 session of treatment, about 7% patients achieved at least 50% improvement of verruca vulgaris. The percentage markedly increased to more than 50% after 2 sessions of treatment and to more than 67% after 3 sessions of treatment. It reached a peak percentage of 90.34% after 4 sessions of treatment. After that, the percentage maintained at about 60–70% (Table 2, Figure 1).

Concerning of verruca plantaris, about 20% patients achieved at least 50% improvement after 1 session of treatment. The percentage sharply increased to more than 53% after 2 sessions of treatment and to more than 85% after 3 sessions of treatment. It reached a peak percentage of 90.60% after 4 sessions of treatment. After that, the percentage maintained at about 74–88% (Table 3, Figure 2).

And for verruca plana, about 43% patients achieved at least 50% improvement after 1 session of treatment and maintained at this level after 2 sessions. The percentage rapidly went up to more than 69% after 3 sessions of treatment. It reached a peak percentage of 80.91% after 4 sessions of treatment. After that, the percentage maintained at about 62–77% (Table 4, Figure 3).

3.3. The Results of 4 Sessions of Treatment. The percentage of patients who achieved at least 50% improvement was 90.34% for verruca vulgaris, 90.60% for verruca plantaris, and 80.91% for verruca plana. Differences were statistically significant among the three diseases ($\chi^2 = 14.416$, $p = 0.001$). The efficacy of verruca vulgaris or verruca plantaris was better than that of verruca plana ($Z = 3.012$, $p = 0.003$; $Z = 3.580$, $p = 0.000$). The efficacies of verruca

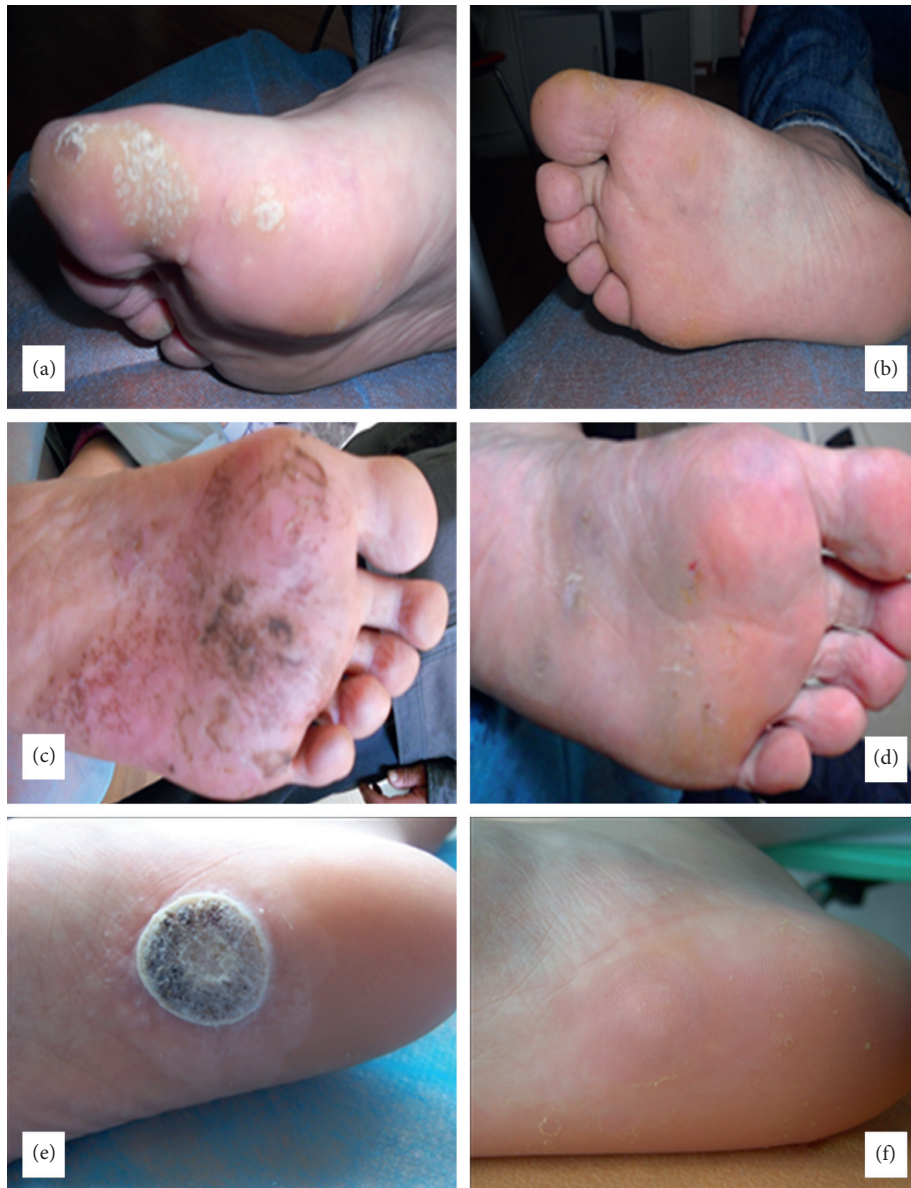

FIGURE 2: Three patients with verruca plantaris before (a, c, e) and after (b, d, f) the treatment.

vulgaris and verruca plantaris were similar ($Z=0.029$, $p>0.05$). Figure 4 shows the percentage of treatment responses in the three diseases after 4 sessions of treatment.

3.4. Adverse Effects and Recurrence. During the treatment, the most common adverse reactions were erythema, slight edema, crusting, and desquamation. After the warts fell off, isometrical wounds would form and patients would feel slight to moderate pain. All the adverse effects resolved soon, especially after using the sea buckthorn oil. No allergic or aggravated signs, including itching, severe erythema, severe edema, or exudation, developed in any patients. At month 3, respective 28 verruca vulgaris, 28 verruca plantaris, and 18 verruca plana patients received telephone follow-up, and no recurrence was reported.

4. Discussion

Topical agents such as salicylic acid and cantharidin may have beneficial effect on verruca vulgaris and verruca plantaris [21–23]. But these agents should not be used by patients themselves theoretically. Because it is difficult for patients to judge the depth of lesions and dermal condition, and the corrosive topical agents may increase the possibility of tissue damage [24]. Physical removal methods such as surgical excision and electrodesiccation may lead to scars and tend to have longer healing time [25]. Another commonly used method of physical destruction is cryotherapy. Despite not leaving scars, cryotherapy is not more effective than topical salicylic acid in some cases [21–23]. Besides, these aggressive treatments often cause intolerable pain, hyperpigmentation, hypopigmentation, or occasionally allergic contact dermatitis [26, 27]. These adverse effects may make both dermatologists and patients hesitate to

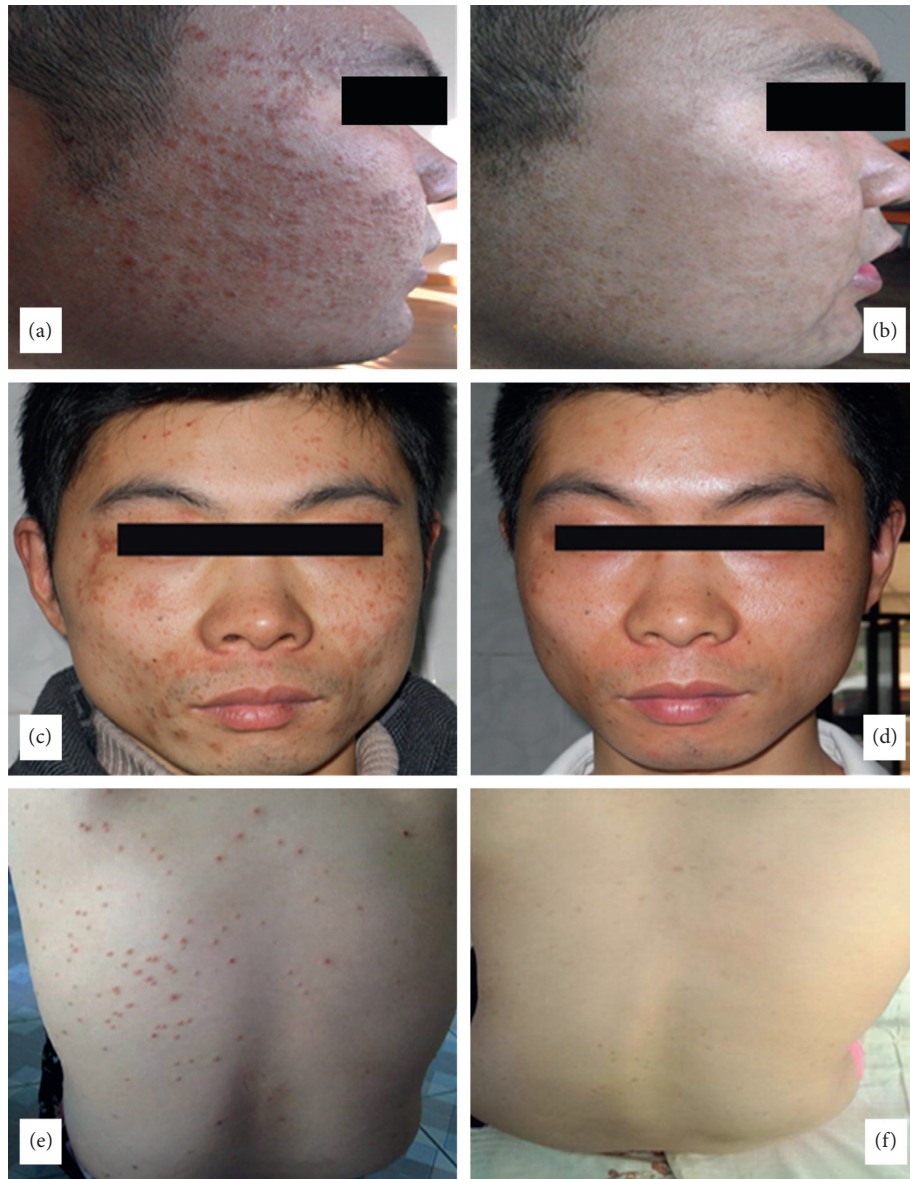


FIGURE 3: Three patients with verruca plana before (a, c, e) and after (b, d, f) the treatment.

start the treatment [8]. Currently, there is no standard method of treatment that is highly effective and without side effects. It is necessary to develop a reliable, easy-to-use, effective, economical minimal side-effect treatment for verruca.

The present study was a retrospective and multicenter study. The results were based on a relatively large-scale survey of over 1800 patients. Topical treatment with YIKEER enabled over 80% patients (regardless of verruca vulgaris, verruca plantaris, or verruca plana) to achieve complete response. Our overall efficacies were better than those of previous studies, such as treating with cryotherapy or neodymium-doped yttrium aluminium garnet laser with success rates of 63–70% [2, 28]. Specifically, the percentage of patients with verruca vulgaris or verruca plantaris who achieved complete response was over 86% by using the YIKEER, and the percentage of verruca vulgaris patients who achieved complete response was higher than 65% by using topical viable bacillus

Calmette–Guerin, and similarly, the percentage of verruca plantaris patients who achieved complete response was higher than 79.1% by a single sublesional injection of interferon- α 2a [4, 29]. In addition, 82.42% verruca plana patients gained the complete response by using YIKEER, which was higher than 53.33% auricular acupuncture in a previous study [8].

At least four treatment sessions of YIKEER were needed to gain complete or partial responses in most patients. The percentage of patients who achieved at least 50% improvement was about 90% for verruca vulgaris or verruca plantaris, which was higher than the 80.91% for verruca plana. It indicated that the efficacy of verruca vulgaris or verruca plantaris was better than that of verruca plana. However, the onset time of verruca vulgaris or verruca plantaris seemed to be relatively slower than that of verruca plana. As after 1 session of treatment, the percentages of patients with former two verrucae who achieved at least 50%

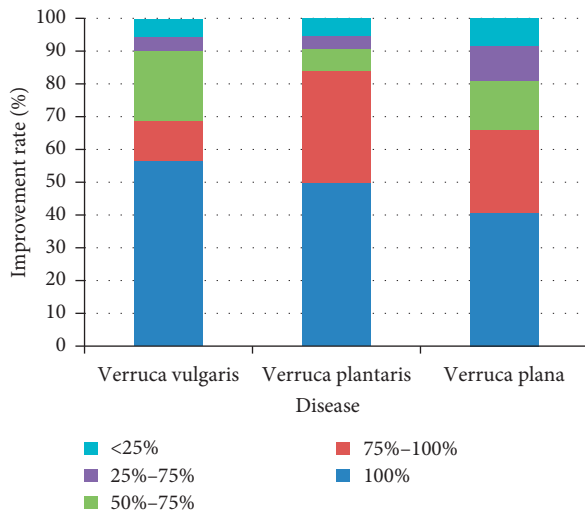


FIGURE 4: The percentages of treatment responses in the three diseases after 4 treatment sessions.

improvement were about 7% and 20%, in contrast to about 43% of verruca plana patients. After that, the efficacy of verruca vulgaris or verruca plantaris increased markedly and the efficacy of verruca plana became gentle.

In the present study, no adverse effects, such as hyperpigmentation or scarring, and no allergic or aggravated signs were observed. Although the treatment duration was longer than cryotherapy or laser, it was easier to be accepted by patients for the minimal pain. The patients who received telephone follow-up at 3 months all reported no recurrence, implying a low recurrence rate by the treatment.

Some limitations existed in the current study. Firstly, there were a small number of patients who showed no response to the treatment. The reasons may be as followings: patients being not sensitive to drugs, body resistance being not strong enough, and reexposure to infection. Secondly, the treatment methods did not unify to an extent and varied with patients owing to individual difference. Thirdly, as the natural shortcoming of a retrospective study, no control group was set and thus the evidence level was not very high. Finally, although the 3 diseases are caused by the same virus, different virus subtypes and different clinical characters lead to diverse responses to the treatment.

5. Conclusion

To sum up, YIKEER is an effective, safe, easy-to-use, and well-tolerated agent for verruca including verruca vulgaris, verruca plantaris, and verruca plana. And it is worthy of further clinical trial to verify the current results.

Data Availability

The data used to support the findings of this study are available from the corresponding author upon request.

Additional Points

Key Points. YIKEER is a kind of compound preparation of Chinese traditional medicine and has been used in the

treatment of verruca for several years. The vast majority of patients were cured after using YIKEER. During the treatment, the most common adverse reactions were erythema, slight edema, crusting, and desquamation.

Ethical Approval

All procedures performed in the study were in accordance with the ethical standards of the Institutional Medical Ethics and Human Research Committee and with the 1964 Helsinki declaration and its later amendments or comparable ethical standards.

Consent

Informed consent was obtained from all individual participants included in the study.

Conflicts of Interest

The authors declare that they have no conflicts of interest.

References

- [1] A. Ural, S. Arslan, S. Ersoz, and B. Deger Kulaksiz, "Verruca vulgaris of the tongue: a case report with a literature review," *Bosnian Journal of Basic Medical Sciences*, vol. 14, no. 3, pp. 136–138, 2014.
- [2] E. A. Smith, S. B. Patel, and M. S. Whiteley, "Evaluating the success of Nd: YAG laser ablation in the treatment of recalcitrant verruca plantaris and a cautionary note about local anaesthesia on the plantar aspect of the foot," *Journal of the European Academy of Dermatology and Venereology*, vol. 29, no. 3, pp. 463–467, 2015.
- [3] W.-J. Kim, W.-K. Lee, M. Song et al., "Clinical clues for differential diagnosis between verruca plana and verruca plana-like seborrheic keratosis," *The Journal of Dermatology*, vol. 42, no. 4, pp. 373–377, 2015.
- [4] A. Salem, A. Nofal, and D. Hosny, "Treatment of common and plane warts in children with topical viable Bacillus Calmette-Guerin," *Pediatric Dermatology*, vol. 30, no. 1, pp. 60–63, 2013.
- [5] S. Akhava, S. R. Mohammadi, M. Modarres Gillani, A. S. Mousavi, and M. Shirazi, "Efficacy of combination therapy of oral zinc sulfate with imiquimod, podophyllin or cryotherapy in the treatment of vulvar warts," *Journal of Obstetrics and Gynaecology Research*, vol. 40, no. 10, pp. 2110–2113, 2014.
- [6] S. Bohlooli, A. Mohebipoor, S. Mohammadi, M. Kouhnavard, and S. Pashapoor, "Comparative study of fig tree efficacy in the treatment of common warts (Verruca vulgaris) vs. cryotherapy," *International Journal of Dermatology*, vol. 46, no. 5, pp. 524–526, 2007.
- [7] J. A. Gladsjo, A. B. Alio Saenz, J. Bergman, G. Kricorian, and B. B. Cunningham, "5% 5-fluorouracil cream for treatment of verruca vulgaris in children," *Pediatric Dermatology*, vol. 26, no. 3, pp. 279–285, 2009.
- [8] S. Ning, F. Li, L. Qian et al., "The successful treatment of flat warts with auricular acupuncture," *International Journal of Dermatology*, vol. 51, no. 2, pp. 211–215, 2012.
- [9] Y. Takauji, K. Morino, K. Miki, M. Hossain, D. Ayusawa, and M. Fujii, "Chyawanprash, a formulation of traditional Ayurvedic medicine, shows a protective effect on skin

- photoaging in hairless mice," *Journal of Integrative Medicine*, vol. 14, no. 6, pp. 473–479, 2016.
- [10] N. K. Sethiya, N. M. Ahmed, R. M. Shekh, V. Kumar, P. Kumar Singh, and V. Kumar, "Ethnomedicinal, phytochemical and pharmacological updates on *Hygrophila auriculata* (Schum.) Hiene: an overview," *Journal of Integrative Medicine*, vol. 16, no. 5, pp. 299–311, 2018.
- [11] N. Panth, K. R. Paudel, and R. Karki, "Phytochemical profile and biological activity of *Juglans regia*," *Journal of Integrative Medicine*, vol. 14, no. 5, pp. 359–373, 2016.
- [12] P. Zhang, "Clinical observation on 35 cases of verruca plantaris treated with YIKEER," *Guide of China Medicine*, vol. 11, p. 512, 2013.
- [13] L. M. Kong and X. P. Xiong, "123 cases with warts treated by YIKEER," *Chinese Medicin Mordern Distense Education of China*, vol. 11, p. 18, 2013.
- [14] Q.-M. Ye, L.-L. Bai, S.-Z. Hu et al., "Isolation, chemotaxonomic significance and cytotoxic effects of quassinoids from *Brucea javanica*," *Fitoterapia*, vol. 105, pp. 66–72, 2015.
- [15] Z. Liu, Z.-Q. Yang, and H. Xiao, "Antiviral activity of the effective monomers from folium isatidis against influenza virus in vivo," *Virologica Sinica*, vol. 25, no. 6, pp. 445–451, 2010.
- [16] P. Wang, W. Liao, J. Fang et al., "A glucan isolated from flowers of *Lonicera japonica* Thunb. inhibits aggregation and neurotoxicity of A β 42," *Carbohydrate Polymers*, vol. 110, pp. 142–147, 2014.
- [17] C. D. Wu-Yuan, C. Y. Chen, and R. T. Wu, "Gallotannins inhibit growth, water-insoluble glucan synthesis, and aggregation of mutans streptococci," *Journal of Dental Research*, vol. 67, no. 1, pp. 51–55, 1988.
- [18] F. Tian, B. Li, B. Ji et al., "Antioxidant and antimicrobial activities of consecutive extracts from *Galla chinensis*: the polarity affects the bioactivities," *Food Chemistry*, vol. 113, no. 1, pp. 173–179, 2009.
- [19] X. W. He, S. L. Ning, F. Fang et al., "Clinical observation on 40 cases of phmas planta and perlungual warts treated with YIKEER demal dishfectant," *Chinese Journal of Dermato-Venereologica*, vol. 22, p. 412, 2008.
- [20] S. Z. Xu, *Andrews's Disease of Skin Clinical Dermatology*, Science Press, Beijing, China, 2004.
- [21] S. Cockayne, M. Curran, G. Denby et al., "EVerT: cryotherapy versus salicylic acid for the treatment of verrucas: a randomised controlled trial," *NIHR Health Technology Assessment*, vol. 15, no. 32, pp. 1–170, 2011.
- [22] S. C. Bruggink, J. Gussekloo, M. Y. Berger et al., "Cryotherapy with liquid nitrogen versus topical salicylic acid application for cutaneous warts in primary care: randomized controlled trial," *Canadian Medical Association Journal*, vol. 182, no. 15, pp. 1624–1630, 2010.
- [23] E. Stamuli, S. Cockayne, C. Hewitt et al., "Cost-effectiveness of cryotherapy versus salicylic acid for the treatment of plantar warts: economic evaluation alongside a randomised controlled trial (EVerT trial)," *Journal of Foot and Ankle Research*, vol. 5, no. 1, p. 4, 2012.
- [24] V. Nucci, D. Torchia, and P. Cappugi, "Condyloma acuminatum of the tongue treated with photodynamic therapy," *Clinical Infectious Diseases*, vol. 48, no. 9, pp. 1330–1332, 2009.
- [25] S. P. Chattopadhyay and P. K. Das, "Evaluation of vinca rosea for the treatment of wart," *Indian Journal of Dermatology*, vol. 56, pp. 107–108, 1990.
- [26] V. Lichon and A. Khachemoune, "Plantar warts: a focus on treatment modalities," *Dermatology Nursing*, vol. 19, no. 19, pp. 372–375, 2007.
- [27] D. Mizuki, T. Kaneko, and K. Hanada, "Successful treatment of topical photodynamic therapy using 5-aminolevulinic acid for plane warts," *British Journal of Dermatology*, vol. 149, no. 5, pp. 1087–1088, 2003.
- [28] K. J. Robson, N. M. Cunningham, K. L. Kruzan et al., "Pulsed-dye laser versus conventional therapy in the treatment of warts: a prospective randomized trial," *Journal of the American Academy of Dermatology*, vol. 43, no. 2, pp. 275–280, 2000.
- [29] A. A. Aksakal, M. G. Ozden, C. Atahan, and M. Onder, "Successful treatment of verruca plantaris with a single sublesional injection of interferon- α 2a," *Clinical and Experimental Dermatology*, vol. 34, no. 1, pp. 16–19, 2009.