



## Intolerance of a non-diffractive extended-depth-of-focus IOL with mini-monovision

Tyll Jandewerth, Marvin Biller, Thomas Kohnen \*

Department of Ophthalmology, Goethe-University Frankfurt am Main, Germany

### ARTICLE INFO

#### Keywords:

Presbyopia  
Mini-monovision  
Refractive lense exchange  
Non-diffractive EDOF-IOL  
Optical phenomena

### ABSTRACT

**Purpose:** The use of a non-diffractive extended-depth-of-focus (EDOF) intraocular lens (IOL) with slight myopia of  $-0.5$  D on the non-dominant eye increases the spectacle independence and has good subjective tolerance with optical phenomena comparable to those of a monofocal IOL. This case report describes the course of a myopic patient who underwent refractive lens exchange, didn't tolerate mini-monovision and received IOL exchange therefore.

**Observations:** A healthy, 62-year-old male with myopia of approximately  $-5$  D underwent refractive lens exchange with a non-diffractive EDOF-IOL on both eyes with slight myopia on the non-dominant left eye (mini-monovision). The operation was performed without any complications, postoperative treatment was due to the clinic's standard procedure. Two weeks postoperative the patient presented with uncorrected distance visual acuity of 0.0 logMAR, a subjective refraction of  $-0.25/-0.25/142^\circ$  and corrected distance visual acuity of 0.1 logMAR on the right eye. On the left eye, distance visual acuity was 0.4 logMAR with a subjective refraction of  $-0.5/-0.75/9^\circ$  (intended mini-monovision) and corrected distance visual acuity of 0.0 logMAR. Binocular distance visual acuity was 0.0 logMAR. The patient complained about the occurrence of optical phenomena at dim light while driving a car and subjective reduced visual acuity. After an IOL exchange on the left eye with the implantation of the same type of non-diffractive EDOF-IOL aimed for emmetropia, the patient was symptom-free and reported no more subjective complaints.

**Conclusions:** Despite the satisfying subjective and objective visual outcome which is proven in multiple studies, the subjective perception of a mini-monovision with a non-diffractive EDOF-IOL can vary individually. A pre-operative assessment of the patient's needs and tolerance of a mini-monovision is crucial for a satisfying post-operative outcome.

### 1. Case report

A 63-year old male with myopia of approximately  $-5$  D visited our department for planning a refractive surgery to achieve spectacle independence. His ophthalmic and past medical history was empty. No allergies were reported.

### 2. Clinical examination

Ophthalmic examination revealed a bilateral myopia with astigmatism (right eye:  $-5.0/-1.75/79^\circ$ , left eye:  $-5.5/-1.25/104^\circ$ ), a binocular uncorrected visual acuity of 1.1 logMAR and a corrected distance visual acuity of  $-0.1$  logMAR.

A scheinpflug examination (Pentacam AXL, Oculus, Wetzlar,

Germany) (Fig. 1) showed an anterior chamber depth of 2.68 mm on the right and 2.64 mm on the left eye. Total corneal refractive power (TCRP) in the 3 mm zone was 1.2 D at an axis of  $165^\circ$  on the right and 0.6 D at an axis of  $10^\circ$  on the left eye.

In the performed IOL-Master (IOL-Master 700, Zeiss Meditec, Jena, Germany), axial length was 24.73 mm with an astigmatism of  $-0.68$  D at an axis of  $79^\circ$  OD and 24.85 mm with an astigmatism of  $-0.62$  D at an axis of  $122^\circ$  OS.

Endothelial cell count was 2532 cells/mm<sup>2</sup> OD and 2545 cells/mm<sup>2</sup> OS.

Slit lamp examination showed a medium-deep to shallow anterior chamber with beginning nuclear sclerosis compatible to the age. Fundus examination in medical mydriasis was unremarkable.

\* Corresponding author. Department of Ophthalmology Goethe-University, Frankfurt, Germany, Theodor-Stern-Kai 7, D-60590, Frankfurt am Main, Germany.

E-mail address: [kohnen@em.uni-frankfurt.de](mailto:kohnen@em.uni-frankfurt.de) (T. Kohnen).

### 3. Preoperative planning

The findings and refractive opportunities were explained to the patient in detail. Due to the patient's age we decided against a corneal refractive surgery. A phakic intraocular lens was also not permitted due to the anterior chamber depth. Eventually we decided to perform a refractive lens exchange with the implantation of a non-diffractive EDOF-IOL to achieve the best situation concerning the patient's worries about optical phenomena and contrast sensitivity. To address the patient's wish for spectacle independence, the right eye was aimed at emmetropia and the non-dominant left eye on slight myopia of  $-0.5$  D to achieve mini-monovision.

IOL toricity calculation was performed using Pentacam and IOL-Master astigmatism data. For the left eye, a non-toric IOL would have resulted in a residual astigmatism of  $+0.65$  D at an axis of  $24^\circ$  under the assumption of a surgical induced astigmatism of  $0.25$  D. Our calculation program showed a toric IOL (T2) would result in a residual astigmatism of  $0.0$  D. So we finally decided for the implantation of a toric IOL in the left eye.

### 4. Operation

On both eyes, the AcrySof IQ Vivivity toric IOL (right:  $16.0$  D/ $1.0$  D/ $172^\circ$ ; left  $16.5$  D/ $1.0$  D/ $42^\circ$ ) (Alcon, Fort Worth, Texas, USA) was implanted in the capsular bag using laser refractive lens exchange (LensX, Alcon, Fort Worth, Texas, USA) and the Verion system (Alcon, Fort Worth, Texas, USA). The operation was performed in local anesthesia by the same experienced surgeon (T.K.).

### 5. Postoperative examinations

After one week, the right eye showed a well centered IOL with an uncorrected visual acuity of  $-0.1$  logMAR with  $\pm 0.0/-0.25/60^\circ$ , a corrected distance visual acuity of  $-0.1$  logMAR and a distance corrected intermediate visual acuity of  $0.0$  logMAR. The left eye had a slight corneal epithelial edema at the temporal main incision with an uncorrected visual acuity of  $0.5$  logMAR with  $-0.75/-0.25/50^\circ$ , a corrected distance visual acuity of  $-0.1$  logMAR and a distance corrected intermediate visual acuity of  $0.2$  logMAR. Therapy with non-steroidal anti-inflammatory eye drops, topical dexamethasone and artificial eye drops was continued.

Two weeks postoperative the finding on the right eye was unchanged with uncorrected distance visual acuity of  $0.0$  logMAR, subjective refraction of  $-0.25/-0.25/142^\circ$  and corrected distance visual acuity of  $-0.1$  logMAR. On the left eye, distance visual acuity was  $0.4$  logMAR with subjective refraction of  $-0.5/-0.75/9^\circ$  and a corrected distance visual acuity of  $0.0$  logMAR. Binocular distance visual acuity was  $0.0$  logMAR. However, the patient was not satisfied with the situation on the left eye. He was disturbed by halos in the left eye when driving a car in dim light, complained about binocular visual acuity and said he couldn't handle the mini-monovision. He asked for an IOL exchange on the left eye to achieve emmetropia on both eyes. A testing with glasses to correct for emmetropia showed an immediate subjective improvement with a binocular satisfied distance visual acuity without optical phenomena.

The different treatment options with corneal refractive surgery, add-on intraocular lens, intraocular lens exchange or wearing glasses were explained to the patient. He still wanted IOL exchange, so the procedure

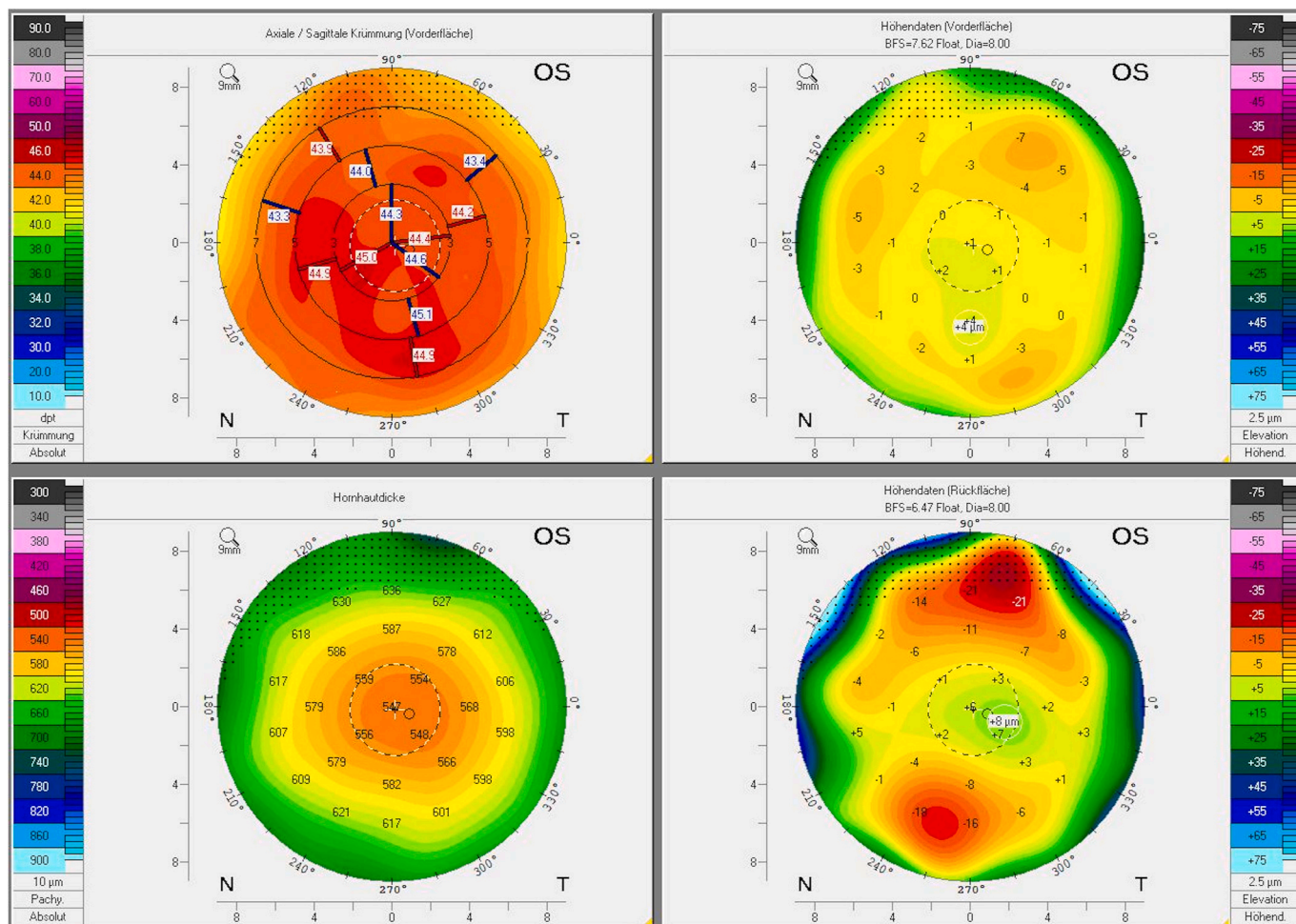


Fig. 1. Refractive map (Pentacam AXL, Oculus, Wetzlar, Germany).

was performed after another two weeks of control with no change of the subjective or objective outcome.

## 6. Intraocular lens exchange

IOL exchange was performed 5 weeks after the initial implantation with, at that time, an aimed refraction of slight myopia of  $-0.5$  D on the left eye. The first IOL was removed through a 3 mm incision and an AcrySof IQ Vivity IOL ( $+16.0$  D) aimed for emmetropia in vertical orientation was implanted in the capsular bag without any complications (Fig. 2). Further postoperative care was carried out to the clinical standardized guidelines.

One week postoperative the left eye showed an uncorrected distance visual acuity of 0.1 logMAR, an uncorrected intermediate visual acuity of 0.2 logMAR, an emmetropia with  $+0.25/-0.25/156^\circ$  and a corrected distance visual acuity of  $-0.2$  logMAR. The patient reported no complaints and was very satisfied with his binocular visual performance. Further postoperative examinations should be performed at his referring ophthalmologist.

## 7. Discussion

The wish for spectacle independence has increased in recent years not only in refractive but also after cataract surgery. Using conventional monovision was one of the earliest attempts to the patients' requirements and was first described in 1984 with monofocal IOLs.<sup>1</sup>

After multifocal IOLs with good uncorrected visual acuity in all distances but also the appearance of optical phenomena were introduced, mini-monovision with an EDOF-IOL seems to be an alternative with less optical phenomena.<sup>2</sup> In recent years, mini-monovision with a non-diffractive EDOF-IOL is used to achieve functional results in near distance and to avoid disturbing optical phenomena while maintaining good distance and intermediate visual acuity.<sup>3</sup>

The AcrySof IQ Vivity IOL (Alcon, Fort Worth, Texas, USA) is a single-piece, non-diffractive, wavefront shaping IOL with an extended depth of focus. It is made out of a hydrophobic acrylate with a high refractive index, has a blue light filter and is UV-absorbing. The IOL has 13 mm in diameter and the optical zone is 6 mm. On the anterior surface the patented X-Wave-Technology™ (Alcon, Fort Worth, Texas, USA) is located which creates an extended focus point in the central 2.2 mm. To compensate the positive spherical aberrations of the cornea, the front side has negative spherical aberrations.

Current studies with the IOL aimed for mini-monovision used in our case showed good visual outcome in all distances and high patient satisfaction while having optical phenomena comparable to those of a monofocal IOL.<sup>4,5</sup> Additionally, the bilateral implantation of the AcrySof IQ Vivity IOL aimed for slight myopia on the non-dominant eye ( $-0.5$  to  $-0.75$  D) increases the spectacle independence in all distances compared to the implantation aimed with bilateral emmetropia<sup>6,7</sup> without the occurrence of more optical phenomena.<sup>8,9</sup>

Our case shows, however, that in spite of the good visual outcome in all distances and spectacle independence of this non-diffractive EDOF-IOL aimed for slight myopia on the non-dominant eye, the subjective tolerance and acceptance can vary individually. Therefore, a detailed ophthalmological consultation of all patients is crucial. Preoperative spectacle or contact lens testing with creating a mini-monovision can help to estimate the patient's tolerance and satisfaction for a planned refractive lens exchange. Additionally, it is important to discuss all treatment possibilities like lens exchange, add-on IOL implantation or refractive corneal touch-up to achieve emmetropia in case of patient's distolerance to mini-monovision preoperatively.

## 8. Conclusion

Despite promising data for the implantation of a non-diffractive EDOF-IOL with creating a mini-monovision,<sup>4,5</sup> the patient's needs and

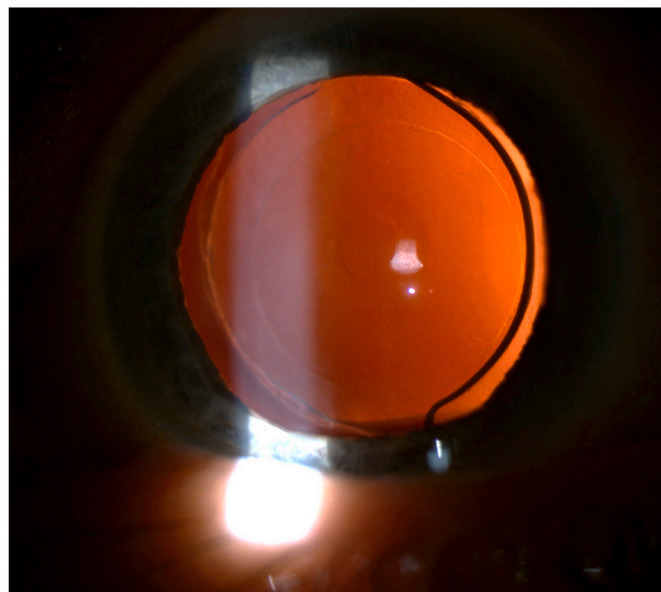


Fig. 2. Non-toric AcrySof IQ Vivity IOL in retroilluminated slit lamp picture.

subjective tolerance should be assessed preoperatively, if possible. This will improve the patient's visual and subjective outcome. Nevertheless, the creation of a slight myopia on the non-dominant eye with a non-diffractive EDOF-IOL increases the spectacle independence in all distances while reducing the risk of optical phenomena.

## Patient consent

The patient consented to publication of the case and the images in writing.

## Funding disclosures

No funding.

## Authorship

All authors attest that they meet the current ICMJE criteria for Authorship.

## Declaration of competing interest

TK: Consultant and Research for Alcon/Novartis, Avedro, J&J, Lensgen, Oculentis, Oculus, Presbia, Schwind, Zeiss. Consultant for Allergan, Bausch & Lomb, Dompé, Geuder, Med Update, Nevarkar, Santen, Staar, Tear Lab, Thieme, Ziemer.

TJ and MB have no conflicts to disclose.

## References

- Boerner CF, Thrasher BH. Results of monovision correction in bilateral pseudophakia. *J - Am Intra-Ocular Implant Soc.* 1984;10(1):49–50. [https://doi.org/10.1016/s0146-2776\(84\)80077-4](https://doi.org/10.1016/s0146-2776(84)80077-4). Winter.
- Labiris G, Giarmoukakis A, Patsiamanidi M, Papadopoulos Z, Kozobolis VP. Mini-monovision versus multifocal intraocular lens implantation. *J Cataract Refract Surg.* Jan 2015;41(1):53–57. <https://doi.org/10.1016/j.jcrs.2014.06.015>.
- Sandoval HP, Lane S, Slade SG, Donnenfeld ED, Potvin R, Solomon KD. Defocus curve and patient satisfaction with a new extended depth of focus toric intraocular lens targeted for binocular emmetropia or slight myopia in the non-dominant eye. *Clin Ophthalmol.* 2020;14:1791–1798. <https://doi.org/10.2147/oph.s247333>.
- van Amelsfort T, Webers VSC, Bauer NJC, Clement LHH, van den Biggelaar F, Nuijts R. Visual outcomes of a new nondiffractive extended depth-of-focus intraocular lens targeted for minimonovision: 3-month results of a prospective cohort study. *J Cataract Refract Surg.* Feb 1 2022;48(2):151–156. <https://doi.org/10.1097/j.jcrs.0000000000000825>.

5. Coassin M, Mori T, Di Zazzo A, et al. Effect of minimonovision in bilateral implantation of a novel non-diffractive extended depth-of-focus intraocular lens: defocus curves, visual outcomes, and quality of life. *Eur J Ophthalmol*. 2021;26, 11206721211064018. <https://doi.org/10.1177/11206721211064018>. Nov.
6. Bala C, Poyales F, Guarro M, et al. Multicountry clinical outcomes of a new nondiffractive presbyopia-correcting IOL. *J Cataract Refract Surg*. 2022;48(2): 136–143. <https://doi.org/10.1097/j.jcrs.0000000000000712>. Feb 1.
7. Kohnen T, Petermann K, Böhm M, et al. Nondiffractive wavefront-shaping extended depth-of-focus intraocular lens: visual performance and patient-reported outcomes. *J Cataract Refract Surg*. 2022;48(2):144–150. <https://doi.org/10.1097/j.jcrs.0000000000000826>. Feb 1.
8. Coassin M, Di Zazzo A, Antonini M, Gaudenzi D, Gallo Afflitto G, Kohnen T. Extended depth-of-focus intraocular lenses: power calculation and outcomes. *J Cataract Refract Surg*. 2020;46(11):1554–1560. <https://doi.org/10.1097/j.jcrs.0000000000000293>.
9. Newsom TH, Potvin R. Evaluation of quality of vision and visual outcomes with bilateral implantation of a non-diffractive extended vision intraocular lens with a target of slight myopia in the non-dominant eye. *Clin Ophthalmol*. 2022;16:183–190. <https://doi.org/10.2147/oph.S350850>.