

# Patient-specific Implant for Temporomandibular Joint Replacement in Juvenile Arthritis and Facial Asymmetry

Sergio Olate<sup>1,2</sup>, Victor Bahls<sup>3</sup>, Francisca Uribe<sup>1,4</sup>, Alejandro Unibazo<sup>2</sup>, Felipe Martínez<sup>1,4</sup>

<sup>1</sup>Center of Excellence in Morphological and Surgical Studies, Universidad de La Frontera, <sup>4</sup>Division of Oral and Maxillofacial Surgery, H.H.A. General Hospital, Temuco,

<sup>2</sup>Division of Oral and Maxillofacial Surgery, A.G.P. General Hospital, Lautaro, Chile, <sup>3</sup>Department of Biomedical Research Enterprises, Pinhais, Paraná, Brazil

## Abstract

The aim of this report is to present a patient with juvenile arthritis, condylar resorption, and residual facial asymmetry treated with orthognathic surgery and unilateral joint replacement with a full three-dimensional computer-aided design and computer-aided manufacture (CAD-CAM) temporomandibular joint (TMJ) prosthesis, including an increase in the left ramus and mandibular angle to achieve facial symmetry. The patient, a 30-year-old male, came to our department for orthosurgical treatment. The patient had been receiving treatment for juvenile arthritis for 15 years; at facial level, he had a chin deviation of 12 mm from the facial midline, maxillary retrusion, and Angle Class III. The computed tomography revealed a reduced height of the left condyle and a significant difference in the morphology of the mandibular ramus and angle. Using CAD-CAM technology and additive manufacturing, a TMJ prosthesis was produced, through the use of the mirror image, orthognathic surgery was realized using the right side as “esthetic side” with suitable shape and angulation. The prosthesis was created, and this was taken to the surgery. The surgery was performed without problems, a mouth opening of 35 mm and absence of pain were noted after 12 months of follow-up. The surgery remained stable, and facial symmetry was restored. In conclusion, it is viable to develop a TMJ prosthesis by CAD-CAM that includes esthetic modifications to the face; prospective and clinical studies must be conducted to confirm protocols.

Level of Evidence: V.

**Keywords:** Facial asymmetry, juvenile arthritis, patient-specific implant, temporomandibular joint replacement

## INTRODUCTION

Replacement of the temporomandibular joint (TMJ) has increased in its indication in relation to good results in the long-term stability and functional conditions;<sup>[1,2]</sup> also, manufacturing design and strategies to build the TMJ prosthesis have evolved favorably.<sup>[3]</sup>

Customized TMJ implants have important advantages, such as an immediate adaptation to the receptor site, no need to adapt anatomical structures, and reduced surgical time.<sup>[4]</sup> Customized design and production of TMJ prosthesis can be realized using biomodels by manual and computational approach, while another technique uses computer-aided design and computer-aided manufacture (CAD-CAM) from a three-dimensional (3D) model (computed tomography [CT]).

Customized TMJ prostheses have demonstrated that they can improve the function of patients with varying levels

of joint disease;<sup>[5]</sup> however, esthetic restoration of the face together with the functional restoration of the TMJ has not been fully evaluated in these devices. Thus, many cases of advanced degenerative alterations of the TMJ also present an alteration of the mandibular shape, and the resulting loss of facial symmetry associated with rotations of the mandibular angle or maxillomandibular morphologic changes;<sup>[6,7]</sup> in some of these cases, the implementation of a joint replacement with a design that recovers facial esthetics could optimize the results.

**Address for correspondence:** Prof. Sergio Olate,  
Center of Excellence in Morphological and Surgical Studies,  
Universidad de La Frontera, Claro Solar 115, Temuco, Chile.  
E-mail: sergio.olate@ufrontera.cl

**Received:** 03-04-2019

**Revised:** 13-11-2019

**Accepted:** 18-04-2020

**Published:** 08-06-2020

This is an open access journal, and articles are distributed under the terms of the Creative Commons Attribution-NonCommercial-ShareAlike 4.0 License, which allows others to remix, tweak, and build upon the work non-commercially, as long as appropriate credit is given and the new creations are licensed under the identical terms.

**For reprints contact:** WKHLRPMedknow\_reprints@wolterskluwer.com

**How to cite this article:** Olate S, Bahls V, Uribe F, Unibazo A, Martínez F. Patient-specific implant for temporomandibular joint replacement in juvenile arthritis and facial asymmetry. *Ann Maxillofac Surg* 2020;10:275-8.

### Access this article online

#### Quick Response Code:



**Website:**  
www.amsjournal.com

**DOI:**  
10.4103/ams.ams\_82\_19

The aim of this article is to present a case where the joint replacement was done with orthognathic surgery to improve function and return facial symmetry.

### CASE REPORT

The patient, a 30-year-old male, came to the oral, facial, and maxillofacial surgery clinic (Chile) complaining of malocclusion and pain in the area of the bilateral TMJ. The patient had been receiving treatment for juvenile arthritis for the past 15 years.

In consultation, the patient had significant facial asymmetry, with a chin deviation of 12 mm from the midline, associated with pain on palpation and restricted mouth opening [Figure 1]; initially, the treatment was conservative with local techniques, physiotherapy, and oral splint with poor results. The facial analysis also reported maxillary and mandibular retrusion. At the dental level, not only Class III occlusion and maxillomandibular but also maxilla-mandibular asymmetry was observed.

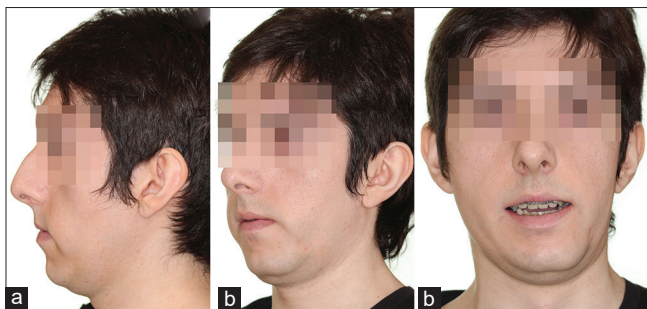In the study with CT [Figure 2], a difference was noted in the morphology of the mandibular region, particularly at the level of the mandibular angle, where the right angle-ramus complex was convex and continuous with the mandibular shape, whereas the left angle-ramus complex presented an area of extensive concavity. The image also revealed advanced

left mandibular condylar resorption and differences in the morphology of the mandibular fossa.

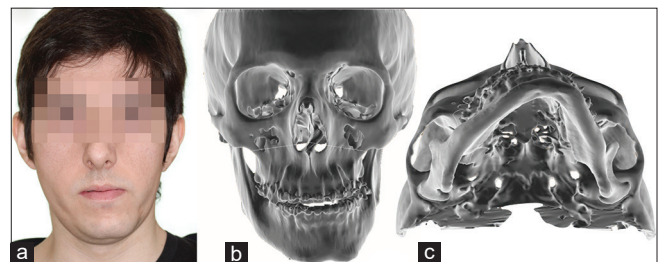
Bimaxillary orthognathic surgery was proposed together with the replacement of the left TMJ. The case was planned out on software with the responsible engineer (V.B.) [Figure 3]. The surgical treatment consisted of surgery starting at the mandible, performing a sagittal osteotomy of the mandibular ramus on the right side with a regression of 2.2 mm, and joint replacement of the TMJ on the left side where advancement of 9 mm was estimated, incorporating a condilectomy (with no coronoidectomy), and the augmentation of the lateral volume of the mandibular angle and the height of the gonion position based on the mirror image on the right side. Nonsegmental Le Fort I osteotomy was realized, making a maxillary advancement of 6 mm, ascent of 1.95 mm at the level of the right molar, and descent of 1.79 mm at the level of the left molar; genioplasty was performed with an advancement of 2 mm and lateral repositioning of 5 mm to achieve facial symmetry.

### Prosthesis design and production

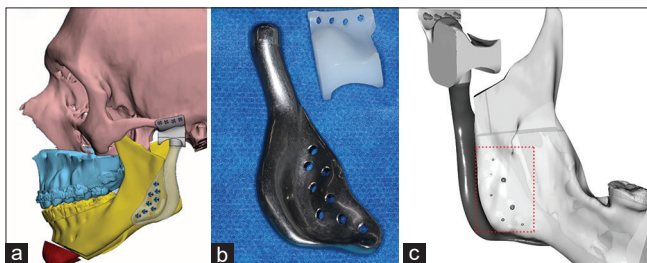
Once the maxillomandibular osteotomies had been done virtually, the mandibular component that includes the condylar area and the area of mandibular angle substitution was designed; the design includes the eight fixation points with screws (2.0 system, ANVISA record no. 10360930043, Brazil) prepared with a titanium alloy (6Al-4V ASTM 136) for the ramus-body unit. The condylar unit is pressed with a chromium-cobalt-molybdenum alloy (ASTM F1537) (Atfix®, Paraná, Brazil).



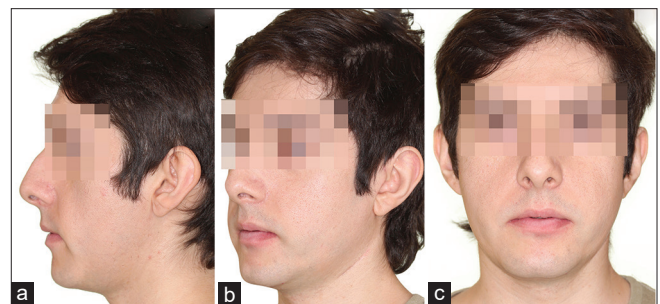**Figure 1:** (a) Lateral view showing short mandibular length and bad proportion in soft tissue in the mandibular area. (b) Three-fourth view with inadequately relation in the chin position and zygoma position. (c) Facial asymmetry, chin deviation 12 mm to the left



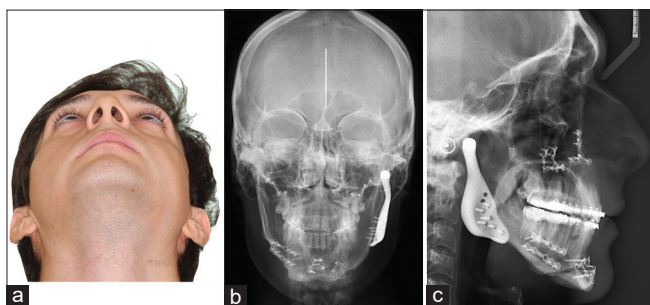
**Figure 2:** (a) Presurgical frontal view related to skeletal condition. (b and c) Show great deviation in the normal position of the mandible with a complex position in the mandibular angle



**Figure 3:** (a) Planning of the bimaxillary orthognathic surgery together with the design of the left temporomandibular joint prosthesis. (b) Constructed prosthesis maintaining the posterior mandibular contour in the internal area of the prosthesis. (c) Fit of the prosthesis in posterior area of mandibular ramus, maintaining contour and shape of the mandibular ramus and angle



**Figure 4:** (a) Lateral view observing better position in the mandible length and good relation between the mandible and neck. (b) Chin position in relation with zygoma area and (c) Frontal view showing a correct position in the midline with symmetry between the left and right side mandible contour



**Figure 5:** (a) Facial condition after 12 months, observing total facial symmetry and positioning of midline of the chin. (b and c) Showing stability of installed prosthesis, with no alterations of position or loss of screws in the area

The cranial component was designed and made in ultra-high-molecular-weight polyethylene (UHMWPE ASTM F648) and titanium alloy 6Al-4V ASTM F 136, integrating four holes for titanium screws of 10 mm length (2.0 system).

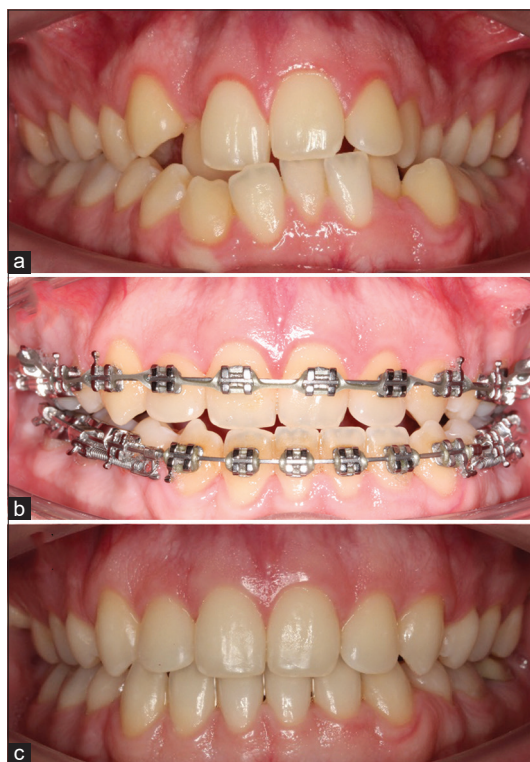
The patient follow-up for 12 months showed total stability of the surgery [Figure 4], maintaining the prosthetic system without complications; recovery of the facial symmetry was achieved and is maintained with a mouth opening >35 mm, and no pain is present [Figure 5]. Dental occlusion was stable, and normal midline was observed [Figure 6] with no complications.

## DISCUSSION

The volume increase based on facial implants are frequently applied for esthetic modifications to the face;<sup>[8]</sup> the use of 3D systems together with CAD-CAM technology for the creation of facial implants is relatively new and offers advantages such as a precise fit in the installation, reduction of intraoperative bone modeling, reduced surgery time, and a better assessment of the treatment by the patient;<sup>[9]</sup> disadvantages have been observed in increased preoperative time and higher associated economic costs; in terms of complications, the most important related to the mandibular region are associated with the potential exposure of the implant and infection, which are mainly related to the intraoral access<sup>[10]</sup> and no with the extraoral approach, as we used in this case.

Materials based on polymethyl methacrylate, polyethylene, silicone, and polyether ether ketone (PEEK) have been used to increase facial volume, with their construction varying from those that need some manual work to those manufactured completely by virtual systems. In this sense, PEEK and titanium have been used in completely virtual constructions,<sup>[6-11]</sup> demonstrating precision in the planning stage and the surgery stage, being friendly for installation and good postoperative stability.

In cases of facial asymmetry, like that in our patient, achieving a mirror image helps improve the design and manufacture of the implant. Although there is evidence of mandibular morphology and ideal mandibular angle formats in men,<sup>[12]</sup>



**Figure 6:** Dental condition and occlusion evolution from the (a) first condition in the initial stage, (b) presurgical dental relation with midline deviation of approximately 5 mm and left crossbite and (c) Stable occlusion, maintaining canine guide and sagittal relation

recovery of facial and mandibular angle symmetry was the main esthetic objective in this patient, where the mirror image may be the best alternative.

It is necessary to consider that in patients with rheumatoid arthritis, at least one joint has been replaced in 25% of the patients.<sup>[13]</sup> In the case of the TMJ, strategies with no use of TMJ prosthesis can present favorable functional results in some degenerative diseases;<sup>[14]</sup> however, structural modifications that allow esthetic and functional improvement can only be achieved with customized structures, so that the facial esthetic variable must be considered in the comparative analyses. Dimitroulis<sup>[7]</sup> indicated that patients in category 5 (TMJ end stage) and when it is necessary to maintain facial symmetry in the lower third and to preserve occlusion, the TMJ must be reconstructed where the TMJ prosthesis is a suitable option.

The method selected for this patients included orthognathic surgery and unilateral TMJ replacement. Stoor *et al.*<sup>[15]</sup> reported 12 patients with juvenile idiopathic arthritis treated with orthognathic surgery, including three patients treated with osteogenic distraction for vertical assessment in the mandible ramus and four patients treated with TMJ replacement with prosthetic device. They concluded that orthognathic surgery plus TMJ replacement in adults is a reliable and safe alternative. In the same line, Chigurupati and Mehra<sup>[16]</sup> showed that in cases of condylar resorption, the most published studies have demonstrated less than ideal outcomes;

in agreement with Chigurupati and Mehra,<sup>[16]</sup> the selection of orthognathic surgery and alloplastic TMJ reconstruction in the same surgical time has been related to (1) eliminates the morbidity of a second surgical time and relapse of orthognathic surgery, (2) the absent of postsurgical remodeling, and (3) the stability in a long-term follow-up.

New strategies to build a customized TMJ prostheses are constantly analyzed,<sup>[17]</sup> although Zou *et al.*,<sup>[4]</sup> when comparing different types of TMJ prostheses, found no differences in maximum interincisal opening or pain reduction or function levels. The stock prosthesis worked similarly to the customized ones, but the esthetics was not assessed. In the present case, the customization of the prosthesis made it possible to improve the characteristics of facial symmetry and to optimize the final esthetic result, confirming the versatility to improve the joint function and the esthetics of the face.

In terms of stability of customized TMJ prostheses, O'Connor *et al.*<sup>[5]</sup> reported 26 patients who underwent a joint replacement with a diagnosis of rheumatoid arthritis, psoriatic arthritis, or ankylosing spondylitis with an average age of 40 years, a significant improvement was determined in all the aspects evaluated with the use of customized prostheses after 1 year of follow-up. Gruber *et al.*<sup>[18]</sup> conducted a study with 3 and 5 years of follow-up, describing improvements in all the values associated with pain, mouth opening, and diet; a limited number of complications were noted, where revision surgery was applied in only 2 of the 58 patients. Similarly, in a report with 20 years of follow-up of patients treated with customized prostheses, Wolford *et al.*<sup>[2]</sup> also concluded high success rates in the treatments performed.

The idea of rebuilding the TMJ in function and improving the facial esthetic has been addressed superficially in the literature; however, the current technology for manufacturing a TMJ prosthesis using CAD-CAM to recover function makes it possible to integrate the esthetic recovery of face, mainly in patients under complex TMJ disease.

Finally, we can conclude that it is possible to work with full CAD-CAM TMJ prosthesis, including parameters of functional and esthetic improvement in its initial design in patients with end-stage TMJ disease.

### Financial support and sponsorship

Nil.

### Conflicts of interest

There are no conflicts of interest.

## REFERENCES

1. Mercuri LG, Edibam NR, Giobbie-Hurder A. Fourteen-year follow-up of a patient-fitted total temporomandibular joint reconstruction system. *J Oral Maxillofac Surg* 2007;65:1140-8.
2. Wolford LM, Mercuri LG, Schneiderman ED, Movahed R, Allen W. Twenty-year follow-up study on a patient-fitted temporomandibular joint prosthesis: The Techmedica/TMJ Concepts device. *J Oral Maxillofac Surg* 2015;73:952-60.
3. de Meurechy N, Braem A, Mommaerts MY. Biomaterials in temporomandibular joint replacement: Current status and future perspectives-a narrative review. *Int J Oral Maxillofac Surg* 2018;47:518-33.
4. Zou L, He D, Ellis E. a comparison of clinical follow-up of different total temporomandibular joint replacement prostheses: A systematic review and meta-analysis. *J Oral Maxillofac Surg* 2018;76:294-303.
5. O'Connor RC, Saleem S, Sidebottom AJ. Prospective outcome analysis of total replacement of the temporomandibular joint with the TMJ Concepts system in patients with inflammatory arthritic diseases. *Br J Oral Maxillofac Surg* 2016;54:604-9.
6. Mommaerts MY. The ideal male jaw angle - An Internet survey. *J Craniomaxillofac Surg* 2016;44:381-91.
7. Dimitroulis G. Comparison of the outcomes of three surgical treatments for end-stage temporomandibular joint disease. *Int J Oral Maxillofac Surg* 2014;43:980-9.
8. Goldsmith D, Horowitz A, Orentlicher G. Facial skeletal augmentation using custom facial implants. *Atlas Oral Maxillofac Surg Clin North Am* 2012;20:119-34.
9. Binder WJ. Custom-designed facial implants. *Facial Plast Surg Clin North Am* 2008;16:133-46, vii.
10. Cuzalina LA, Hlavacek MR. Complications of facial implants. *Oral Maxillofac Surg Clin North Am* 2009;21:91-104, vi-vii.
11. Guevara-Rojas G, Figl M, Schicho K, Seemann R, Traxler H, Vacariu A, *et al.* Patient-specific polyetheretherketone facial implants in a computer-aided planning workflow. *J Oral Maxillofac Surg* 2014;72:1801-12.
12. Mommaerts MY. Guidelines for patient-specific jawline definition with titanium implants in esthetic, deformity, and malformation surgery. *Ann Maxillofac Surg* 2016;6:287-91.
13. Wolfe F, Zwilllich SH. The long-term outcomes of rheumatoid arthritis: A 23-year prospective, longitudinal study of total joint replacement and its predictors in 1,600 patients with rheumatoid arthritis. *Arthritis Rheum* 1998;41:1072-82.
14. Ma J, Jiang H, Liang L. Interpositional arthroplasty versus reconstruction arthroplasty for temporomandibular joint ankylosis: A systematic review and meta-analysis. *J Craniomaxillofac Surg* 2015;43:1202-7.
15. Stoor P, Hodzic Z, Arte S. Surgical Treatment of Dentofacial Deformities Caused by Juvenile Idiopathic Arthritis. *J Craniofac Surg* 2018;29:e51-e57.
16. Chigurupati R, Mehra P. Surgical Management of Idiopathic Condylar Resorption: Orthognathic Surgery Versus Temporomandibular Total Joint Replacement. *Oral Maxillofac Surg Clin North Am* 2018;30:355-67.
17. Abel EW, Hilgers A, McLoughlin PM. Finite element analysis of a condylar support prosthesis to replace the temporomandibular joint. *Br J Oral Maxillofac Surg* 2015;53:352-7.
18. Gruber EA, McCullough J, Sidebottom AJ. Medium-term outcomes and complications after total replacement of the temporomandibular joint. Prospective outcome analysis after 3 and 5 years. *Br J Oral Maxillofac Surg* 2015;53:412-5.