

Cutaneous Manifestations of COVID-19 Observed in Indian Patients: A Case Series

Coronavirus disease 2019 (COVID-19) is caused by SARS-CoV-2 (severe acute respiratory syndrome coronavirus 2), which belongs to the Coronaviridae family.^[1] Patients have varied manifestations ranging from mild flu-like symptoms to fulminant pneumonia.^[2] These patients may also develop cutaneous manifestations. Many reports that focused on cutaneous manifestations of COVID-19 have been published by dermatologists of the Western world. This article is an attempt to enumerate the cutaneous manifestations of COVID-19 as observed in the dermatology outpatient department (OPD) in India.

Case 1

A 38-year-old female presented to our OPD with complaints of redness and swelling of hands and feet, associated with burning sensation and mild itching for 2 days. She was a known case of chronic spontaneous urticaria controlled with levocetirizine 5 mg HS. The patient presented with a history of low-grade fever, dry cough, and malaise for 5 to 6 days. There was no history of cold exposure or previous history suggestive of perniosis or Raynaud's disease. On examination, erythema and edema of hands and feet including fingers and toes were noted [Figure 1a and b]. A probable diagnosis of angioedema and pernio-like lesions of COVID-19 was made. Routine investigations and card rapid antigen test (RAT) were done for the patient. RAT was found to be positive. Other routine investigations were within normal limits. A final diagnosis of pernio-like acral lesions of COVID-19 (COVID toes) was made. She was continued on antihistamines and was advised betamethasone dipropionate cream twice a day for local application for COVID toes. The patient was advised

This is an open access journal, and articles are distributed under the terms of the Creative Commons Attribution-NonCommercial-ShareAlike 4.0 License, which allows others to remix, tweak, and build upon the work non-commercially, as long as appropriate credit is given and the new creations are licensed under the identical terms.

For reprints contact: WKHLRPMedknow_reprints@wolterskluwer.com

home isolation. The lesions subsided completely in 2 weeks without any residual pigmentation.

Case 2

A 31-year-old female presented to the OPD with complaints of a gradually progressive, red-colored rash on the neck, trunk, and upper limbs for the past 3 to 4 days. She presented with a history of high-grade fever, malaise, breathlessness (even at rest), excruciating headache, retro-orbital pain, and loss of appetite for a period of 8 to 10 days. On examination, non-palpable purpura was noted over the neck, chest, abdomen, back, upper limbs, and palms with islands of sparing noticed on the back. Pseudo-vesiculation was seen in purpuric lesions on the back [Figures 2a, b and 3]. A preliminary diagnosis of dengue rash was made. The platelet count was 100,000/mm³, and all other routine investigations were within normal limits. Lactate dehydrogenase, erythrocyte sedimentation rate, D-dimer and C-reactive protein levels were raised. Serum ferritin was within normal limits. NS1 antigen test for dengue was negative. Chest X-ray posterior–anterior view revealed peripheral and lower lobar predominant air space opacities and haziness, suggestive of COVID pneumonitis in the current scenario. RAT was negative, but reverse-transcriptase polymerase chain reaction (RT-PCR) was positive. The patient was referred to an advanced center for hospitalization. For cutaneous lesions, the patient was advised levocetirizine tablet 5 mg HS, betamethasone dipropionate cream, and an emollient for local application twice a day. On reviewing the discharge papers, we found that she was treated using paracetamol tablet 500 mg TDS (thrice a day; till the fever subsided),

Niharika Jha

*Dermatology, Senior Resident,
Acharya Shree Bhikshu
Government Hospital, Moti
Nagar, New Delhi, India*

Address for correspondence:

*Dr. Niharika Jha,
Department of
Dermatology, Acharya
Shree Bhikshu Government
Hospital, Moti Nagar,
New Delhi - 110 015, India.
E-mail: niharikajha88@gmail.
com*

Access this article online

Website: www.idoj.in

DOI: 10.4103/idoj.IDOJ_836_20

Quick Response Code:



How to cite this article: Jha N. Cutaneous manifestations of COVID-19 observed in Indian patients: A case series. *Indian Dermatol Online J* 2021;12:930-2.

Received: 30-Oct-2020. **Revised:** 04-Mar-2021.

Accepted: 15-May-2021. **Published:** 22-Nov-2021.

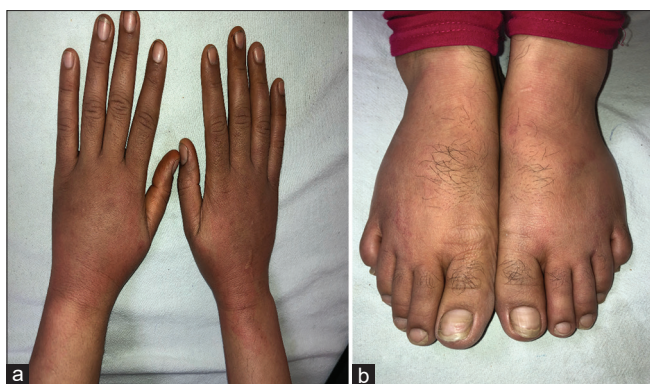

Figure 1: a and b: Erythema and edema of hands and feet including fingers and toes (COVID toes)

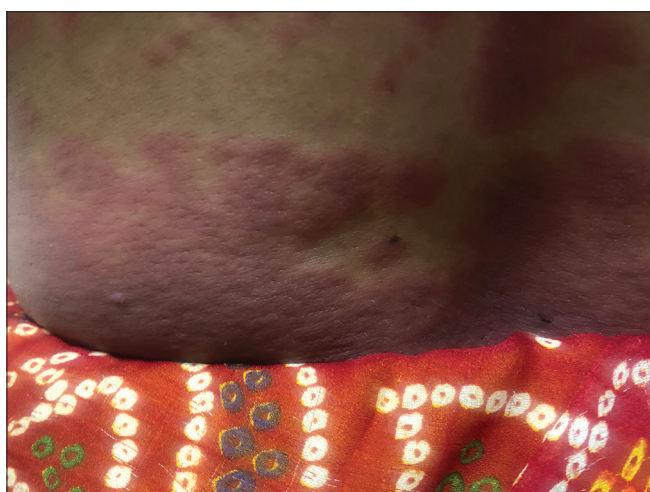

Figure 3: Pseudo-vesiculation over purpuric lesions

hydroxychloroquinone tablet 200 mg BD (twice a day), enoxaparin injection 4 mg s.c. (subcutaneous) BD for 2 weeks. Azithromycin tablet (500 mg) OD (once a day) was also given for 5 days. Oxygen support was given for breathlessness and inability to maintain the oxygen saturation (SpO₂). She was discharged after 17 days. The rash completely subsided in about 3 weeks from its appearance.

Case 3

A diabetic and hypertensive 70-year-old male had low-grade fever, malaise, dry cough, and anosmia for 4 days. RAT was negative, but RT-PCR was positive. The patient was hospitalized for observation and was managed symptomatically. The patient developed an itchy, red-colored, evanescent rash on the trunk and extremities on the 10th day of hospitalization that persisted even after the patient was discharged. On examination, wheals were present, predominantly on the trunk [Figure 4]. The persistence of wheals even after stopping medications ruled out the possibility of a drug-induced urticaria. A diagnosis of acute urticaria following COVID-19 was made. He was started on levocetirizine tablet 5 mg HS and

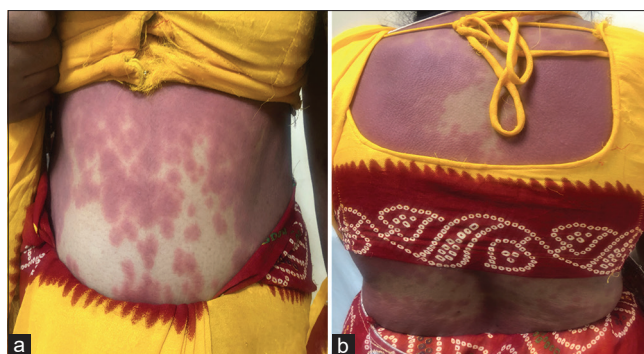


Figure 2: (a and b) Purpuric lesions on the trunk of a COVID-19 patient

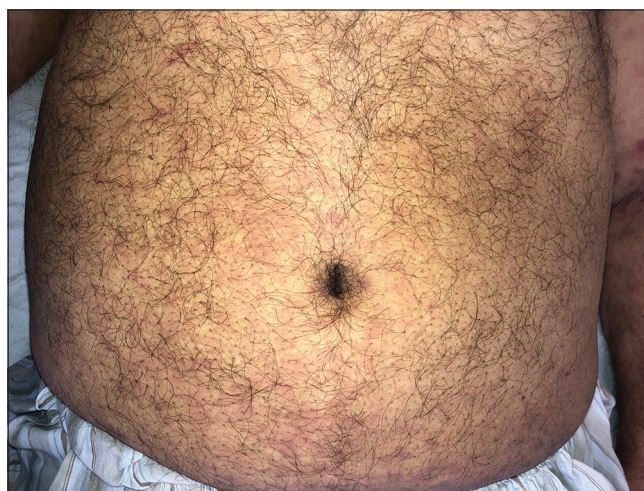

Figure 4: Urticarial wheals over abdomen in a COVID-19 patient

calamine lotion, and was relieved of his symptoms within 3 weeks.

Case 4

A 29-year-old female, known case of chronic spontaneous urticaria, previously controlled on levocetirizine tablet 5 mg HS, with no other comorbidities, presented to our OPD with complaints of fever along with exacerbation of urticaria for 2 days. The dose of levocetirizine was increased to 5 mg BD and paracetamol tablet 500 mg SOS (if required) was added for fever. The patient did not get relief from her symptoms. She also complained of malaise and weakness. She was started on a tapering dose of prednisolone tablet starting from 0.5 mg/kg/day (30 mg). Basic routine investigations along with RAT were advised, which were within normal limits. RT-PCR was positive. The patient was advised home isolation. She recovered without sequelae within 2 weeks.

Discussion

We have described cutaneous manifestations in four patients who were diagnosed with COVID-19 (COVID toes, purpura, and urticaria). All patients who had COVID-like symptoms and cutaneous manifestations were first subjected to RAT;

Table 1: Details of COVID-positive patients with cutaneous manifestations

Age/ Sex	Cutaneous Manifestations	Duration of onset of cutaneous symptoms	Treatment given	Prognosis/Outcome	Possible pathogenesis
38/F	COVID toes	3 days after the onset of systemic symptoms	Tab. levocetirizine (5mg) HS and betamethasone dipropionate cream L/A BD	Recovered in 2 weeks without residual pigmentation	Cutaneous expression of strong interferon-1 response ^[5]
31/F	Nonpalpable purpura	1 week after the onset of systemic symptoms	Tab. levocetirizine (5mg HS), betamethasone dipropionate cream and emollient L/A BD	Required oxygen support and prolonged admission. Recovered	Complement-induced microvascular injury ^[6]
70/M	Urticaria	2 weeks after onset of systemic symptoms	Tab. levocetirizine (5mg) HS and calamine lotion L/A BD	Recovered in 3 weeks without any sequelae	Viral infection-induced nonimmune urticaria ^[7] Antigen-antibody complex deposition in vascular wall, followed by complement activation and mast cell degranulation ^[8]
29/F	Exacerbation of previously controlled chronic spontaneous urticaria.	Along with systemic symptoms.	Tapering dose of Tab. prednisolone.	Recovered in 2 weeks.	Viral infection-induced nonimmune urticaria Antigen-antibody complex deposition in vascular wall, followed by complement activation and mast cell degranulation

COVID=Coronavirus disease, F=Female, M=Male, Tab. = Tablet, L/A=Local application, HS=At bedtime, BD=Twice daily

if found negative, RT-PCR was done. In three patients, other symptoms preceded cutaneous manifestations. In one patient, the lesions and COVID-19 symptoms appeared together. The patient who developed purpuric lesions required oxygen support and prolonged hospitalization, the other three had mild symptoms. All the patients recovered without any sequelae. All the relevant details along with the probable pathogenesis have been included in Table 1. Dermatologists from the West have noted morbilliform rash, urticaria, pernio-like lesions, livedo-reticularis-like lesions, purpura, polymorphic rash as noticed in Kawasaki disease, and vesicular lesions in COVID-19 patients.^[3,4]

Suspected COVID patients with negative RAT should be advised RT-PCR for confirmation. COVID patients can present directly to the dermatology OPD. It is imperative for all health care workers to take the required precautions while examining patients.

Declaration of patient consent

The authors certify that they have obtained all appropriate patient consent forms. In the form, the patient(s) has/have given his/her/their consent for his/her/their images and other clinical information to be reported in the journal. The patients understand that their names and initials will not be published and due efforts will be made to conceal their identity, but anonymity cannot be guaranteed.

Financial support and sponsorship

Nil.

Conflicts of interest

There are no conflicts of interest.

References

- Masters PS, Perlman S. Coronaviridae. In: Fields Virology Knipe DM, Howley PM, Cohen JI, Griffin DE, Lamb RA, Martin MA, *et al*, editors. Lippincott Williams & Wilkins. Vol. 2. 6th ed. Philadelphia: A Wolters Kluwer Business; 2013. p. 825.
- Li Q, Guan X, Wu P, Wang X, Zhou L, Tong Y, *et al*. Early transmission dynamics in Wuhan, China, of novel coronavirus-infected pneumonia. *N Engl J Med* 2020;13:1199-1207.
- Wollina U, Karadağ AS, Rowland-Payne C, Chiriac A, Lotti T. Cutaneous signs in COVID-19 patients: A review. *Dermatol Ther* 2020;33:e13549.
- Verdoni L, Mazza A, Gervasoni A, Martelli L, Ruggeri M, Ciuffreda M, *et al*. An outbreak of severe Kawasaki-like disease at the Italian epicentre of the SARS-CoV-2 epidemic: An observational cohort study. *Lancet* 2020;395:1771-8.
- Baeck M, Herman A. COVID toes: Where do we stand with the current evidence?. *Int J Infect Dis* 2021;102:53-5.
- Llamas-Velasco M, Muñoz-Hernández P, Lázaro-González J, Reolid- Pérez A, Abad- Santamaría B, Fraga J, *et al*. Thrombotic occlusive vasculopathy in a skin biopsy from a livedoid lesion of a patient with COVID-19. *Br J Dermatol* 2020;183:591-3.
- Wedi B, Raap U, Wiczorek D, Kapp A. Urticaria and infections. *Allergy Asthma Clin Immunol* 2009;5:10. doi: 10.1186/1710-1492-5-10.
- Hamming I, Timens W, Bulthuis MLC, Lely AT, Navis GJ, van Goor H. Tissue distribution of ACE2 protein, the functional receptor for SARS coronavirus. A first step in understanding SARS pathogenesis. *J Pathol* 2004;203:631-7.