

CASE REPORT

Atrial tachycardia related to local abnormal atrial activity

Yasuharu Matsunaga-Lee MD  | Sen Matsumoto MD | Nobutaka Masunaga MD |
Yuzuru Takano MDDepartment of Cardiology, JCHO
Hoshigaoka Medical Center, Hirakata, Japan**Correspondence**Yasuharu Matsunaga-Lee, Department of
Cardiology, JCHO Hoshigaoka Medical
Center, Hirakata, Japan.
Email: sumomo0304@gmail.com**Abstract**

A 42-year-old woman without a history of catheter ablation or cardiac surgery was referred to our institution for a paroxysmal atrial tachycardia (AT). Programed stimulation could not induce any AT. The AT spontaneously initiated during a continuous isoproterenol infusion. The earliest activation during the AT was recorded at the cavo-tricuspid isthmus, and local abnormal atrial activity (LAATA) was recorded during sinus rhythm at that same site. When rapid atrial activity was recorded at the cavo-tricuspid isthmus where the LAATA was recorded, an AT was induced. Radiofrequency ablation was performed over the entire area where the LAATA was recorded during sinus rhythm, rendering the AT non-inducible.

KEYWORDS

atrial tachycardia, local abnormal atrial activity, mid-diastolic period, radiofrequency ablation, rapid atrial activity

1 | INTRODUCTION

Catheter ablation is an effective therapeutic strategy for atrial tachycardia (AT). Precise mapping of the earliest activation site is critical to eliminate focal ATs. The focal AT origin is identified using a three-dimensional electro-anatomical mapping system. Substrate-based ablation has been used for ventricular tachycardia, and late potentials (LPs) and local abnormal ventricular activity (LAVA) should be eliminated during those substrate-based strategies.^{1,2} However, LPs and local abnormal activity have not been described in the field of AT. Here, we reported a patient with an AT, in whom the initiation was related to local abnormal atrial activity (LAATA). The AT was initiated when rapid atrial activity was recorded at a site where the LAATA was recorded during sinus rhythm.

2 | CASE REPORT

A 42-year-old woman was referred to our institution for paroxysmal AT. She had no history of catheter ablation or cardiac surgery. Echocardiography revealed a normal left ventricular ejection

fraction (58%) and no structural heart disease. Two 10 polar electrode catheters were placed on the lateral right atrium (RA) and inside the coronary sinus (CS). Programed stimulation could not induce any AT. The AT was spontaneously initiated by a continuous isoproterenol infusion (0.7 µg/min). The cycle length of the AT varied from 360 to 500 ms. The earliest activation site during the AT was recorded at the cavo-tricuspid isthmus, and a PentaRay[®] NAV catheter (Biosense Webster, Diamond Bar, CA) (PEN) was placed there. At that same PEN position, LAATA was recorded during sinus rhythm (Figure 1A) and it was recorded during the mid-diastolic period. The interval between the local systolic electrogram and LAATA increased (Figure 1A). The delay was associated with the induction of rapid atrial activity. The cycle length of the rapid atrial activity varied from 100 to 180 ms. When the rapid atrial activity was recorded, the AT was initiated (Figure 1B). The rapid atrial activity exhibited a three to one conduction pattern to the atrium. Catheter ablation was performed using an open-irrigated contact force catheter (ThermoCool Smart-Touch SF, Biosense Webster). No rapid atrial activity was recorded by the ablation catheter during the AT (Figure 2), and radiofrequency ablation (30–35 W) rendered the AT non-inducible.

This is an open access article under the terms of the Creative Commons Attribution-NonCommercial License, which permits use, distribution and reproduction in any medium, provided the original work is properly cited and is not used for commercial purposes.

© 2018 The Authors. *Journal of Arrhythmia* published by John Wiley & Sons Australia, Ltd on behalf of the Japanese Heart Rhythm Society.

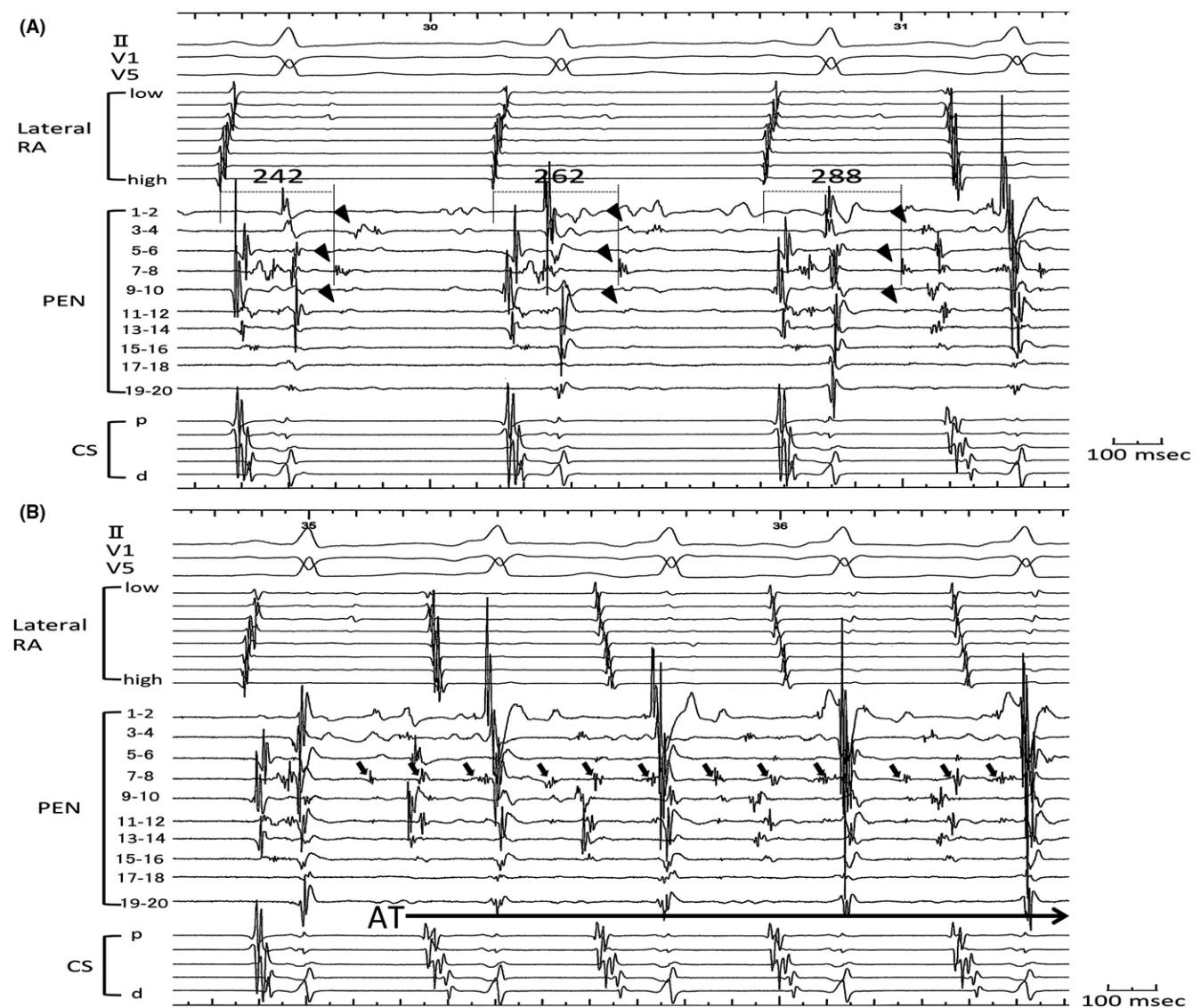


FIGURE 1 A, The intracardiac electrograms during sinus rhythm. LAATA (arrowheads) was recorded from PEN 3–4, 7–8, and 11–12. The interval between the local systolic electrogram and LAATA increased. The delay was associated with the induction of rapid atrial activity. B, The AT was initiated by rapid atrial activity (arrows) at PEN 7–8. AT, atrial tachycardia; RA, right atrium; CS, coronary sinus; LAATAs, local abnormal atrial activities; PEN, PentaRay®

3 | DISCUSSION

LAVA has been described as exhibiting sharp high-frequency ventricular potentials, and the elimination of that LAVA is associated with a superior ventricular tachycardia (VT)-free survival.¹ The interval between the local systolic electrogram and LAATA increased (Figure 1A), and the delay was associated with the induction of the AT. This phenomenon has been described with the LAVA during right ventricular pacing.¹ The cycle length of the rapid atrial activity and AT varied from 100 to 190 and 360 to 500 ms, respectively. The decremental conduction of the pathway between the LAATA and surrounding atrial muscle resulted in three to one conduction of the rapid atrial activity of this AT.

The rapid atrial activity, recorded by the PentaRay® NAV catheter, was not recorded by the 3.5 mm tip ablation catheter. Mapping using the PentaRay® NAV catheter, with a 1 mm tip and 2 mm spaced electrodes, has been described to improve the mapping resolution within areas of low voltage.³ The small and narrow spaced electrode catheters allowed for recording the fine potentials that were missed with the larger electrodes.

There were some limitations to utilizing the LAATA and rapid atrial activity. We could not perform burst or extra pacing to assess the properties of the LAATA. The AT induced by isoproterenol was not continuous, but was of an incessant form. Sinus rhythm activation, when the LAATA was recorded, continued for only several beats. It was not possible to perform pacing maneuvers to assess the properties of the LAATA. Also, the cycle length of the rapid atrial

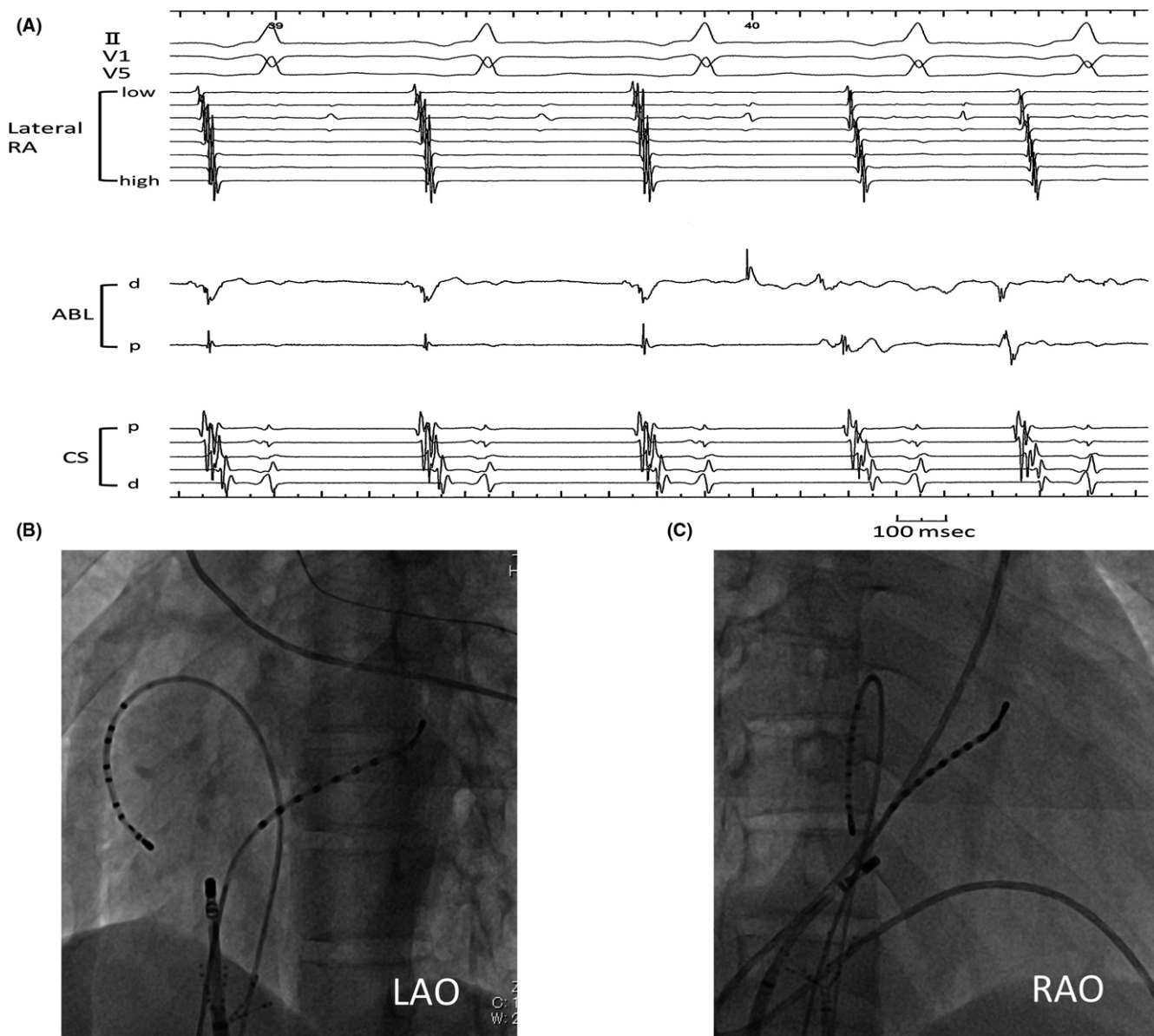


FIGURE 2 A, The intracardiac electrograms during the AT. No rapid atrial activity was recorded by the ablation catheter. B-C, The fluoroscopic view of the catheter ablation site. AT, atrial tachycardia; RA, right atrium; CS, coronary sinus; RAO, right anterior oblique view; LAO, left anterior oblique view; ABL, ablation catheter; PEN, PentaRay®

activity and AT varied from 100 to 190 and 360 to 500 ms, respectively. It was not possible to assess the properties of the rapid atrial activity.

To the best of our knowledge, this report is the first report to document an AT related to LAATA. The AT was initiated when rapid atrial activity was recorded at the site where the LAATA was recorded during sinus rhythm. Radiofrequency applications were delivered to cover the entire area where the LAATA was recorded during sinus rhythm. This strategy has been reported as homogenization in the field of VT ablation.² Further studies are needed to determine the true prevalence of LAATA as well as the relationship between the LAATA and AT.

CONFLICT OF INTEREST

The authors declare no conflict of interest for this article.

ORCID

Yasuharu Matsunaga-Lee  <http://orcid.org/0000-0002-4775-8914>

REFERENCES

1. Jais P, Maury P, Khairy P, et al. Elimination of local abnormal ventricular activities. A new end point for substrate modification in patients

- with scar-related ventricular tachycardia. *Circulation*. 2012;125:2184–96.
2. Briceno DF, Romero J, Gianni C, et al. Substrate ablation of ventricular tachycardia: late potentials, scar dechanneling, local abnormal ventricular activities, core isolation, and homogenization. *Card Electrophysiol Clin*. 2017;9:81–91.
 3. Tschabrunn CM, Roujol S, Dorman NC, et al. High-resolution mapping of ventricular scar: comparison between single and multielectrode catheters. *Circ Arrhythm Electrophysiol*. 2016;9:e003841.

How to cite this article: Matsunaga-Lee Y, Matsumoto S, Masunaga N, Takano Y. Atrial tachycardia related to local abnormal atrial activity. *J Arrhythmia*. 2018;34:294–297. <https://doi.org/10.1002/joa3.12058>