

RESEARCH ARTICLE

Editorial Process: Submission:12/11/2017 Acceptance:06/19/2018

Frequency of ALK Rearrangement by FISH Testing and its Correlation with ALK-IHC in Adenocarcinoma of Primary Lung Origin

Samar Moatter¹, Namrah Anwar¹, Tariq Moatter², Shahid Pervez^{1*}

Abstract

Anaplastic lymphoma kinase (ALK) gene can be oncogenic either by forming fusion with other genes, amplification of the gene or by having mutations. ALK rearrangement can either be detected by standard “fluorescence in situ hybridization (FISH)” or “immunohistochemistry (IHC)”. Objective of this study was to record the prevalence of ALK rearrangement in adenocarcinoma of Primary Lung origin and compare it with ALK-IHC staining. Data of 64 patients of lung adenocarcinoma from 2015-2017 was analyzed. All of the FFPE biopsies were tested for EGFR (qPCR) followed by ALK rearrangement (by FISH and IHC) on EGFR negative samples. Out of 64 samples, 21.8% (14) showed EGFR mutations and 14% (7/50) were positive for ALK rearrangement when checked by FISH. In IHC testing for ALK (FISH positive) 8% (4/50) showed positivity. In conclusion ALK-FISH positive cases are higher than other studies likely due to the relatively small sample size. FISH testing was found to be more sensitive than IHC; one reason may be the low level of ALK. Our study warrants that currently FISH remains the gold standard for screening of ALK gene rearrangements.

Keywords: Lung adenocarcinoma- ALK- FISH- IHC

Asian Pac J Cancer Prev, **19** (6), 1735-1738

Introduction

Detection of EGFR activating mutations and Anaplastic Lymphoma Kinase (ALK) rearrangements has become a standard of care for patients with adenocarcinoma of primary lung origin. ALK protein is a member of the Insulin receptor family of tyrosine kinases; ALK gene was discovered in 1994 in a subset of Anaplastic Large-Cell Lymphomas (ALCL) carrying t(2; 5) (p23;q35) translocation (Soda et al., 2007). ALK receptor protein is not expressed in the normal lung but gets activated by the echinoderm microtubule-associated protein like 4 (EML4)-Anaplastic Lymphoma Kinase gene fusion which occurs in approximately 3-5% of the patients with lung adenocarcinoma (Soda et al., 2007; Chiarle et al., 2008; Rodig et al., 2009). Rearrangements of the ALK gene are associated with patients of younger age, non-smokers, and adenocarcinoma with signet cells (Rodig et al., 2009).

Two main diagnostic tests being carried out to assess ALK gene status are Fluorescent in situ hybridization (FISH) analysis and the immunohistochemical technique (IHC). FISH works with a breakapart probe for ALK receptor gene analysis to determine its status in lung adenocarcinoma (Camidge et al., 2012; Shaw et al., 2013; Solomon et al., 2014). However FISH is technically

challenging, expensive and the required apparatus is not readily available in routine diagnostic laboratories along with specialized expertise (Rodig et al., 2009; Camidge et al., 2010; Mino-Kenudson et al., 2010). Immunohistochemical methods, on the other hand, readily available in most Pathology labs are much cheaper and easy to interpret. Although ALK-FISH is a Food and Drug Administration (FDA) approved method to detect fusion gene, a proportion of ALK-positive tumors show no detectable rearrangements, whereas on subsequent they were ALK IHC positive tumors and showed a remarkable response to receiving Crizotinib treatment (Peled et al., 2012; Sun et al., 2012; Ren et al., 2014; Shan et al., 2015). However the lack of standardization of the IHC technique as the primary diagnostic test has made it challenging to make an early diagnosis of the disease and evaluate a broader range of available treatment options. Crizotinib has been approved by the FDA for treatment for patients with advanced or metastatic non-small cell lung carcinoma (Malik et al., 2014). ALK rearrangement identification is an important procedure for lung cancers as they have a 50-60% response rate to Crizotinib and similar treatment options such as other ALK tyrosine kinase inhibitors leading to a better survival rate. The therapeutic options are chosen on the basis of genetic signature EML-ALK

¹Section of Histopathology, ²Section of Molecular Pathology, Department of Pathology and Laboratory Medicine, Aga Khan University Hospital, Karachi, Pakistan. *For Correspondence: shahid.pervez@aku.edu

translocation. Although, FISH technique is the preferred diagnostic method, however, for a broad implementation it is not optimal due to its technical and financial reasons, whereas IHC techniques would be a promising diagnostic method applicable for routine clinical practice in the near future due to its several advantages from being easily accessible to being more affordable and practicable.

Hence the purpose of this study was to reevaluate previously diagnosed cases of lung adenocarcinoma tested for ALK by FISH method using IHC testing and to further establish the role of IHC reliable substitute for primary screening of ALK rearrangements.

Materials and Methods

Sampling

The data of 64 patients was included who were diagnosed as adenocarcinoma of primary lung origin both in lung as well as in metastatic setting and tested for EGFR mutations and ALK rearrangements in our lab between 2015-2017. These patients were first analyzed for EGFR mutation by a commercial Real-time PCR kit. Then the EGFR negative samples were subjected to ALK mutation analysis by FISH technique followed by immunohistochemistry for ALK protein. In the case of metastasis, only those cases were recruited where confirmation of lung as the primary site of cancer was established.

EGFR mutation analysis

Depending upon the size of the tissue, 2-5 sections of 5 μ m thickness of FFPE specimen were cut and placed in 1.5 ml microfuge tubes. DNA extraction and multiplex PCR was performed using Cobas EGFR mutation detection kit and the Cobas z480 Real-time PCR instrument (Roche Molecular Systems, Branchburg, NJ, USA); following the standard package insert protocol. Cobas EGFR Mutation Test uses allele-specific polymerase chain reaction (AS-PCR) and can detect 43 different mutations in four exons (18-21) of EGFR gene, including several point mutations, deletions, and insertions.

FISH for ALK rearrangement

Paraffin sections from patients' tumor block ranging 4-6 μ m in thickness were deparaffinized in xylene before being dehydrated with graded ethanol. The sections were incubated in 0.2N HCl for 20min, washed and immersed

in protease solution for 30min and finally fixed in 10% buffered formalin. ALK probe cocktail (5' 442 kb and 3' 300 kb) purchased from Abbott Diagnostics (Chicago, IL, USA) were co-denatured at 73°C for 7 min in Thermobrite (Abbott Molecular, Chicago, IL, USA) and further incubated overnight at 37°C. Next day slides were washed in 2X SSC/0.3% NP-40 solution twice and counterstained with DAPI. Fluorescent signals were observed and scored under a Nikon Eclipse 90i (Nikon Inc., Melville, NY, USA) upright fluorescent microscope and 100 nuclei were observed.

Immunohistochemistry for ALK

IHC was performed in automated DAKO system. Briefly, 5 μ m tumor tissue sections were deparaffinized at 60°C for 30-60 min followed by incubations in xylene and graded ethanol. Antigens were unmasked as recommended by the manufacturer. Primary antibody against ALK (monoclonal mouse anti-human, CD246 from DAKO) was incubated at room temperature for 30 mins. Subsequent to multiple washes, tissues were blocked, and slides were incubated with a secondary antibody linked with HRP (DAKO, Denmark). Incubation in DAB, HRP substrate, revealed antigenic localization. After counterstaining with Mayer's Haematoxylin, tissues were dehydrated and cover-slipped. Appropriate positive and negative controls were included in each run. The slides were assessed independently by two histopathologists, and scoring was done according to the reported method (To et al., 2013).

Results

EGFR mutation analysis

Out of 64 patients 14 (21.8%) came out to be positive for EGFR mutations. The mutation test covers exon-18 to 24 of the EGFR gene. The results showed that six patients had a deletion in exon-19. Furthermore, two patients carried compound mutations in the following combination S768I (Serine is replaced by Isoleucine, exon-20) and L858R (Leucine is replaced by Arginine, exon-21) and other showed combination T790M (change from Threonine to Methionine, exon- 20) and G719X (exon-18). Six patients were positive for point mutation L858R in exon-21.

ALK analysis by FISH

Breakapart probes labeled with red and green

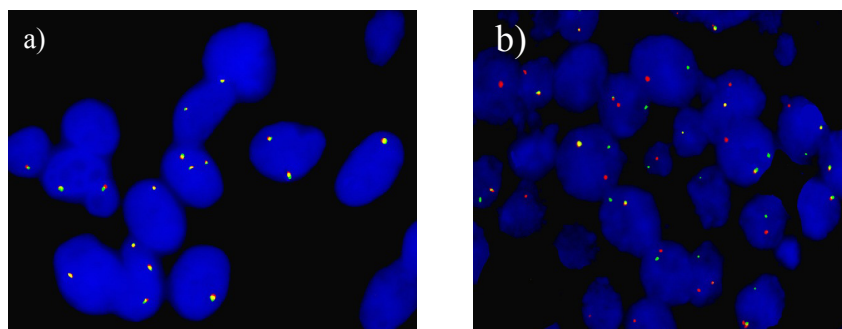


Figure 1. A Representative Image of ALK Negative (a) and Positive (b) Lung Adenocarcinoma. Separated Red and Green signals indicate ALK gene rearrangement

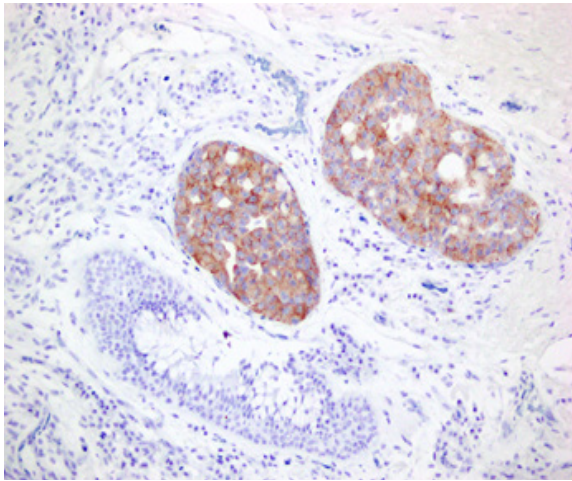


Figure 2. Bronchial Biopsy Showing Foci of Moderately Differentiated Adenocarcinoma of Primary Lung Origin. Note diffuse cytoplasmic staining with ALK Protein

fluorochromes were used to analyze ALK rearrangement at 2p23. The red probe was telomeric probe (3') and the green probe was centromeric probe (5'). Intact gene would exhibit fused signal of yellow color (Figure 1a), else the signal would split in to green and red in case of inversion of the region (Figure 1b), and either of the signals would be lost if a deletion occurs. A total of 100 nuclei were observed and a rearrangement was considered positive if observed in more than 15% of the nuclei and signals were at least two diameters apart. Out of 50 patients, 7 (14%) patients were found to have ALK gene rearrangements.

ALK by IHC

ALK was checked on all the samples which were FISH positive along with a subset of negative samples. According to the published criteria, IHC scores of 0 and 1+ were chosen as negative and scores of 2+ or 3+ as positive. Out of seven samples 4 showed diffused cytoplasmic staining and one sample came out to be weak positive (+1) which was considered as negative and other two samples were negative for ALK rearrangement staining (Figure 2).

Discussion

This study was done to determine the presence of EGFR mutations with ALK mutations and association of FISH and IHC for ALK testing diagnostically in Pakistani population of Lung Adenocarcinoma which is a common type of lung cancer and first line of treatment includes the platinum based therapy chemotherapy (Ellison et al., 2013). However, some patients harboring mutations are eligible for the TKIs which provide an advance treatment. EGFR is the most commonly mutated gene in such cases which accounts for like 60% of the overall cases. Almost 90% of these mutations are either in-frame deletions of exon-19 which removes the amino acids from 747-750 (LREA) or single nucleotide substitution of thymine to guanine resulting in change of arginine from leucine at 858 position of exon-21 (Shigematsu et al., 2005; Ellison et al., 2013). However, according to different published data,

half of the cases tend to progress towards a second-site mutation in EGFR kinase domain and more than 90% is the change of thymine to cytosine at 2639 position in exon 20. (Kwak et al., 2005; Balak et al., 2006; Kosaka et al., 2006). Our study showed the similar results to these studies in EGFR mutational analysis which provided the insight into the eligibility of patients for TKIs. Compound mutations were also observed which showed the increased resistance towards the TKIs.

In 2007, Soda et al., (2007) reported a fusion gene consisted of portions of EML4 (N terminal segment) and ALK(kinase domain) as a result of small inversion within chromosome 2p. The EML4-ALK translocation represents a new subgroup of lung adenocarcinoma patients who respond positively to ALK inhibitors. Recent studies suggest that presence of EML4-ALK fusion varies from 3-6% depending on the factors like ethnicity and detection methods (Takeuchi et al., 2008; Takeuchi et al., 2009). According to different studies genetic alterations in EGFR, KRAS, and ALK do not co-exist (Gainor et al., 2013). The results of this study concord with the published reports showing that the mutations of EGFR and ALK are mutually exclusive. Moreover, in our study, the overall ALK positivity was 14% which is higher than the reported data where, limited sample size remained a constraint. As ALK mutations mostly consists of intrachromosomal deletion and inversion so the diagnosis for ALK rearrangement requires FISH, RT-qPCR and ISH where FISH being the gold standard in diagnostics (Gainor et al., 2013).

Both techniques have pros and cons and recent publications in order to find the association of both the techniques in ALK detection have discussed the discordances (Boland et al., 2009). FISH has been approved by FDA as the method of choice for patient selection in clinical trials. The breakapart probe allows detection of rearrangements without the specificity of breakpoint. In addition, nonspecific signal separation could not be attributed to cells without rearrangement which increases the possibility of false results and intraobserver variability. Moreover, FISH requires specialized laboratory equipment and techniques, expert interpretation, relatively high costs, and a longer turnaround time and fluorescent signals rapidly fades away with time (Camidge et al., 2010). An alternative diagnostic method to FISH is IHC, which recently has been studied extensively for its usability in routine testing. The efficacy of IHC detection depends on various factors like tissue preparation, scoring system (H-score), type and affinity of antibody and the sensitivity of detection system. IHC was shown to be specific but not sensitive in earlier studies which could be attributed to the low transcriptional activity or instability of EML4 in cells (Martelli et al., 2009; Murakami et al., 2012). In a study conducted by Sholl et al. found one out of 15 ALK-positive specimens tested by FISH method was falsely negative and two were false positives after being reanalyzed using IHC, further highlighting the importance of this testing technique (Sholl et al., 2013). In our study four of the FISH positive ALK samples showed strong cytoplasmic staining in IHC and

three positive samples in FISH came out to be negative in IHC. These results were in agreement with some of the studies reported (Eunhee et al., 2011; Paik et al., 2011; McLeer-Florin et al., 2012).

To the list of our knowledge this is the first study from Pakistan reporting frequency of ALK rearrangement in adenocarcinoma of Primary Lung origin as well as correlation of FISH results with ALK IHC. Currently, the false negative results and less sensitivity do not make IHC plausible as primary screening technique. This study however, had some limitations which include small sample size and IHC testing with only one clone of ALK protein.

References

- Balak MN, Gong Y, Riely GJ, et al (2006). Novel D761Y and common secondary T790M mutations in epidermal growth factor receptor–mutant lung adenocarcinomas with acquired resistance to kinase inhibitors. *Clin Cancer Res*, **12**, 6494-6501.
- Boland JM, Erdogan S, Vasmatzis G, et al (2009). Anaplastic lymphoma kinase immunoreactivity correlates with ALK gene rearrangement and transcriptional up-regulation in non–small cell lung carcinomas. *Hum Pathol*, **40**, 1152-8.
- Camidge DR, Kono SA, Flacco A, et al (2010). Optimizing the detection of lung cancer patients harboring anaplastic lymphoma kinase (ALK) gene rearrangements potentially suitable for ALK inhibitor treatment. *Clin Cancer Res*, **16**, 5581-90.
- Camidge DR, Bang YJ, Kwak EL, et al (2012). Activity and safety of crizotinib in patients with ALK-positive non-small-cell lung cancer: updated results from a phase 1 study. *Lancet Oncol*, **10**, 1011-9.
- Chiarle R, Voena C, Ambrogio C, Piva R, Inghirami G (2008). The anaplastic lymphoma kinase in the pathogenesis of cancer. *Nat Rev Cancer*, **8**, 11-2.
- Ellison G, Zhu G, Moulis A, et al (2013). EGFR mutation testing in lung cancer: a review of available methods and their use for analysis of tumour tissue and cytology samples. *J Clin Pathol*, **66**, 79-89.
- Eunhee SY, Boland JM, Maleszewski JJ, et al (2011). Correlation of IHC and FISH for ALK gene rearrangement in non-small cell lung carcinoma: IHC score algorithm for FISH. *J Thorac Oncol*, **6**, 459-65.
- Gainor JF, Varghese AM, Ou SH, et al (2013). ALK rearrangements are mutually exclusive with mutations in EGFR or KRAS: an analysis of 1,683 patients with non–small cell lung cancer. *Clin Cancer Res*, **19**, 4273-81.
- Kosaka T, Yatabe Y, Endoh H, et al (2006). Analysis of epidermal growth factor receptor gene mutation in patients with non–small cell lung cancer and acquired resistance to gefitinib. *Clin Cancer Res*, **12**, 5764-9.
- Kwak EL, Sordella R, Bell DW, et al (2005). Irreversible inhibitors of the EGF receptor may circumvent acquired resistance to gefitinib. *PNAS*, **102**, 7665-70.
- Malik SM, Maher VE, Bijwaard KE, et al (2014). US food and drug administration approval: crizotinib for treatment of advanced or metastatic non–small cell lung cancer that is anaplastic lymphoma kinase positive. *Clin Cancer Res*, **20**, 2029-34.
- Martelli MP, Sozzi G, Hernandez L, et al (2009). EML4-ALK rearrangement in non-small cell lung cancer and non-tumor lung tissues. *Am J Pathol*, **174**, 661-70.
- McLeer-Florin A, Moro-Sibilot D, Melis A, et al (2012). Dual IHC and FISH testing for ALK gene rearrangement in lung adenocarcinomas in a routine practice: a French study. *J Thorac Oncol*, **7**, 348-54.
- Mino-Kenudson M, Chirieac LR, Law K, et al (2010). A novel, highly sensitive antibody allows for the routine detection of ALK-rearranged lung adenocarcinomas by standard immunohistochemistry. *Clin Cancer Res*, **16**, 1561-71.
- Murakami Y, Mitsudomi T, Yatabe Y (2012). A screening method for the ALK fusion gene in NSCLC. *Front Oncol*, **2**, 24.
- Paik JH, Choe G, Kim H, et al (2011). Screening of anaplastic lymphoma kinase rearrangement by immunohistochemistry in non-small cell lung cancer: correlation with fluorescence in situ hybridization. *J Thorac Oncol*, **6**, 466-72.
- Peled N, Palmer G, Hirsch FR, et al (2012). Next-generation sequencing identifies and immunohistochemistry confirms a novel crizotinib-sensitive ALK rearrangement in a patient with metastatic non–small-cell lung cancer. *J Thorac Oncol*, **7**, 14-6.
- Ren S, Hirsch FR, Varela-Garcia M, et al (2014). Atypical negative ALK break-apart FISH harboring a crizotinib-responsive ALK rearrangement in non–small-cell lung cancer. *J Thorac Oncol*, **9**, 21-3.
- Rodig SJ, Mino-Kenudson M, Dacic S, et al (2009). Unique clinicopathologic features characterize ALK-rearranged lung adenocarcinoma in the western population. *Clin Cancer Res*, **15**, 5216-23.
- Shan L, Jiang P, Xu F, et al (2015). BIRC6-ALK, a novel fusion gene in ALK break-apart FISH-negative lung adenocarcinoma, responds to crizotinib. *J Thorac Oncol*, **10**, 37-9.
- Shaw AT, Kim DW, Nakagawa K, et al (2013). Crizotinib versus chemotherapy in advanced ALK-positive lung cancer. *N Engl J Med*, **368**, 2385-94.
- Shigematsu H, Lin L, Takahashi T, et al (2005). Clinical and biological features associated with epidermal growth factor receptor gene mutations in lung cancers. *J Natl Cancer Inst*, **97**, 339-46.
- Sholl LM, Weremowicz S, Gray SW, et al (2013). Combined use of ALK immunohistochemistry and FISH for optimal detection of ALK-rearranged lung adenocarcinomas. *J Thorac Oncol*, **8**, 322-8.
- Soda M, Choi YL, Enomoto M, et al (2007). Identification of the transforming EML4–ALK fusion gene in non-small-cell lung cancer. *Nature*, **448**, 561-6.
- Solomon BJ, Mok T, Kim DW, et al (2014). First-line crizotinib versus chemotherapy in ALK-positive lung cancer. *N Engl J Med*, **371**, 2167-7.
- Sun JM, Choi YL, Won JK, et al (2012). A dramatic response to crizotinib in a non–small-cell lung cancer patient with IHC-positive and FISH-negative ALK. *J Thorac Oncol*, **7**, 36-8.
- Takeuchi K, Choi YL, Soda M, et al (2008). Multiplex reverse transcription-PCR screening for EML4-ALK fusion transcripts. *Clin Cancer Res*, **14**, 6618-24.
- Takeuchi K, Choi YL, Togashi Y, et al (2009). KIF5B-ALK, a novel fusion oncokine identified by an immunohistochemistry-based diagnostic system for ALK-positive lung cancer. *Clin Cancer Res*, **15**, 3143-9.
- To KF, Tong JH, Yeung KS, et al (2013). Detection of ALK rearrangement by immunohistochemistry in lung adenocarcinoma and the identification of a novel EML4-ALK variant. *J Thorac Oncol*, **8**, 883-91.



This work is licensed under a Creative Commons Attribution-Non Commercial 4.0 International License.