

Case Studies

A 65-Year-Old Female from Connecticut with Orf Infection

Jose Ramón Estela Cubells^a Irwin Braverman^b Michael Kashgarian^c
Rossitza Lazova^{b, c}

^aDepartment of Dermatology, Valencia University General Hospital, Valencia, Spain;
Departments of ^bDermatology and ^cPathology, Yale University School of Medicine,
New Haven, Conn., USA

Key Words

Orf · Parapoxvirus · Ecthyma contagiosum · Poxvirus · Orf virus

Abstract

The virus, which causes orf and induces acute pustular skin lesions in sheep and goats, is transmissible to humans yet is rarely observed in North America. We present a case of a 65-year-old female farmer from Connecticut who contracted orf from her sheep. The clinical and histopathologic features, important to arrive at the correct diagnosis of this uncommon yet important infection, are described. We also discuss the benign nature of this condition and emphasize that treatment is not required.

© 2016 The Author(s)
Published by S. Karger AG, Basel

Introduction

The orf virus of the Parapoxvirus genus of the family Poxviridae induces acute pustular skin lesions in sheep and goats and is transmissible to humans. This double-stranded DNA poxvirus is a member of the Paravaccinia subgroup [1]. The first case of human orf was documented in 1934 by Newson and colleagues [2]. The histopathologic features of the infected skin include vacuolar changes and keratinocyte swelling in the stratum spinosum, reticular degeneration, and striking proliferation of the epidermis [3]. Orf is rarely diagnosed in North America, although large series from Norway and New Zealand have been described [4–6]. Primarily, infected young sheep or goats develop contagious ecthyma, which is also known as contagious pustular dermatitis or scabby mouth, involving the lip and mouth [7]. In most

Jose Ramón Estela Cubells
Department of Dermatology, Valencia University General Hospital
Avenida Tres Cruces 2
ES–46014 Valencia (Spain)
E-Mail joseramonestelacubells@gmail.com

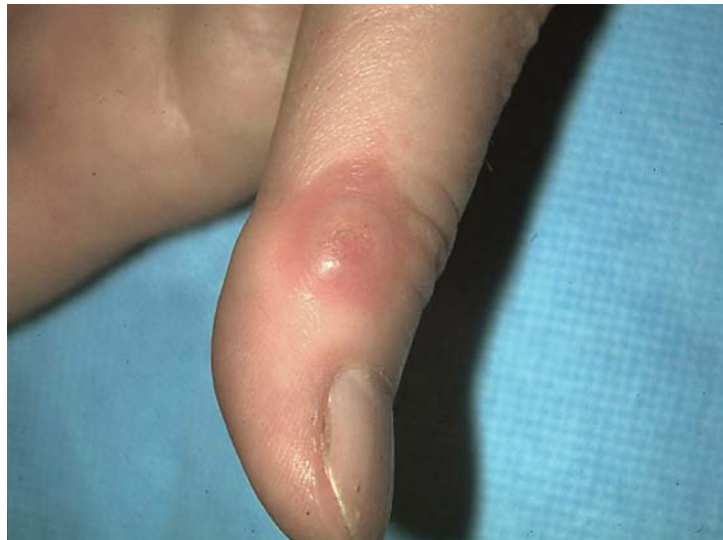

Fig. 1. One-centimeter, firm, erythematous papule involving the dorsal aspect of the right thumb of the 65-year-old female patient.

instances, the human disease occurs among sheep handlers and is transmitted by direct contact with the papulovesicular lesions or the crusts from an infected animal and only rarely through contact with meat or objects [8–10]. Although human-to-human transmission is extremely rare, some cases have been reported [11, 12].

Case Report

A 65-year-old female presented with a 1-cm firm erythematous cutaneous papule involving the dorsal aspect of her right thumb. The lesion had a targetoid appearance with a red center, a white ring measuring 0.2 cm around it and peripheral erythematous halo (fig. 1). She had no fever, malaise, or lymphadenopathy. The patient was a sheep farmer who had been working with newborn lambs. Initially, a red papule appeared on the dorsum of her right thumb, which became increasingly firm and painful.

Histologic examination of a punch biopsy revealed hyperplastic epidermis with elongation of the rete ridges and enlarged, vacuolated keratinocytes in the spinous layer (fig. 2a). Rare necrotic keratinocytes were noted. The papillary dermis appeared focally edematous, and there was a dense mixed inflammatory infiltrate of mainly lymphocytes (fig. 2b). The pathologic findings, in conjunction with the clinical history and physical appearance, suggested the target stage of orf infection.

Electron microscopic examination revealed multiple intracytoplasmic oval-shaped viral particles with electron-dense central core surrounded by a laminated capsule, consistent with Poxvirus (fig. 3). No treatment was given to the patient, and a follow-up visit after 2 months showed complete resolution of the lesion.

Discussion

A diagnosis of orf can be suspected when there is a history of contact with infected lambs, characteristic appearance and location of the lesion, and benign clinical course.

Following exposure, fingers, hands, forearms, and face are the most common sites of infection. After an incubation period of 3–7 days, the lesions (solitary or clustered) evolve through six clinical stages, with each stage lasting about a week: (1) maculopapular stage, in which an erythematous papule develops from the primary macule; (2) target stage, in which the lesion has a red center, a white ring around it and a surrounding red halo; (3) acute

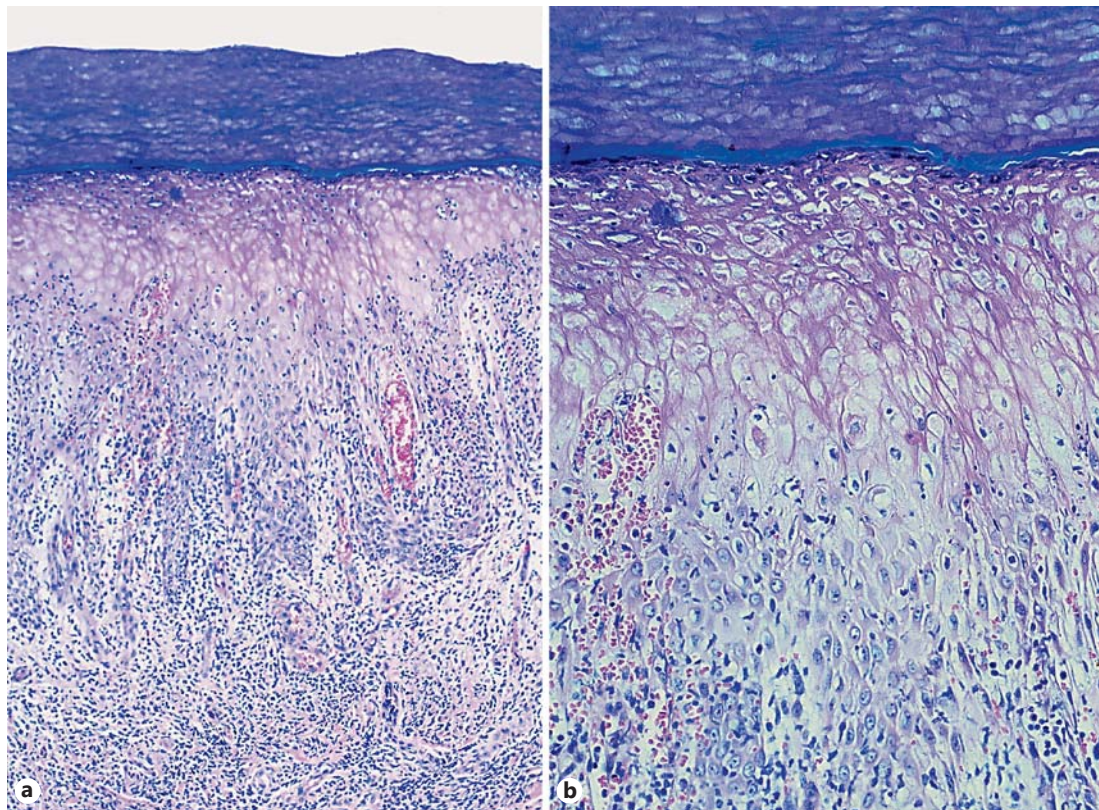


Fig. 2. **a** The epidermis is hyperplastic with elongation of the rete ridges, edematous papillary dermis, and dense, predominantly lymphocytic inflammatory infiltrate focally obscuring the dermal epidermal junction. **b** The keratinocytes in the stratum spinosum are enlarged, vacuolated, and with abundant pale cytoplasm. Rare necrotic keratinocytes are spotted.

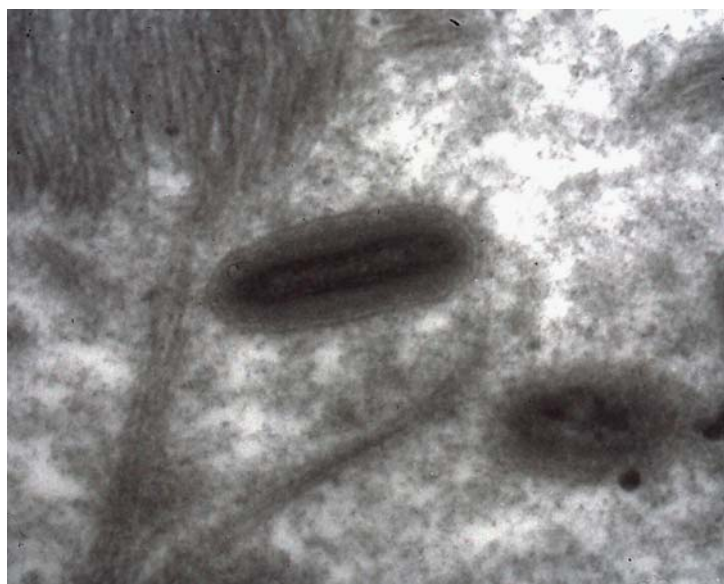

Fig. 3. Electron microscopy reveals intracytoplasmic viral particles with electron-dense cores.

weeping stage; (4) nodular stage; (5) papillomatous stage, which represents the regenerative drying stage, and (6) regressive stage, which is characterized by dry crust [8, 13]. The disease resolves spontaneously within approximately 7 weeks [14]. Human orf infections in North America are considered rare or are often underrecognized due in part to the failure of patients to seek care and/or the physicians' unfamiliarity with the disease [15]. In addition, skin lesions that result from orf infection, which is self-limiting in hosts with a competent immune system, may resemble and be clinically confused with other entities, such as anthrax [16], herpes, or tularemia, which are caused by the intracellular bacterium *Francisella tularensis* and papilloma.

Common complications include regional lymphadenitis, lymphangitis, superimposed infection, erythema multiforme, and toxic erythema. Large fungating lesions are occasionally reported and may resemble pyogenic granuloma or keratoacanthoma. When the disease affects the eye, permanent blindness can result. Rarely, widespread papulovesicular or bullous lesions, which resolve after a few weeks, suggest the possibility of viremic dissemination. Metastatic lesions have also been reported in humans. Reinfection in humans is not uncommon and may occur in an immunocompromised host, although this reinfection is usually less severe [17]. Differential clinical diagnosis of orf virus commands consideration of possible acute febrile neutrophilic dermatosis, erysipeloid, which is caused by infection by *Erysipelothrix rhusiopathiae*, and Milkers' nodules, which is caused by paravaccinia virus and transmitted via cows.

Because of these potentially confusing presentations, histologic examination is particularly useful for rendering the correct diagnosis. Depending upon the stage of the disease, the main histopathologic features of orf infection include vacuolar degeneration of the keratinocytes with eosinophilic intracytoplasmic and/or intranuclear inclusions in some of the vacuolated cells, intraepidermal vesicles, elongation of the rete ridges, varying amounts of perivascular inflammation in the dermis, and hyperkeratosis with papillomatosis of the epidermis. Differential histopathological diagnosis includes cowpox and smallpox virus infection that may also yield multilocular vesicles and prominent ballooning of keratinocytes with cytoplasmic eosinophilic inclusion bodies; however, these diseases can be differentiated from parapoxvirus infection by electron microscopy, virology, or PCR-based approaches. Herpes simplex, varicella, and zoster may also closely resemble orf infection, but multinucleated epithelial giant cells and keratinocytes with distinct chromatin margination and intranuclear eosinophilic inclusions are commonly observed only in the former lesions. Molluscum contagiosum can easily be differentiated histologically from orf infection by the presence of cytoplasmic amphophilic bodies in the affected keratinocytes. Other viruses of the parapoxvirus group, such as pseudocowpox (causing Milkers' nodules) and bovine pustular dermatosis viruses, are ultrastructurally identical to the orf virus. Histologic findings in lesions of orf and Milkers' nodules are also identical. Therefore, it is crucial to correlate the ultrastructural and microscopic findings to clinical observations as well as to the type of animal contact that has occurred. Furthermore pyogenic granuloma diagnosis can be differentiated by the presence of a collarette of epidermis with pale edematous stroma. In addition, pyoderma gangrenosum shows a mixed cellular infiltrate mainly composed of neutrophils, commonly finding erythrocyte extravasation without mural necrosis or luminal fibrin deposition. Other infections as *Mycobacterium marinum* of the skin can be differentiated by the presence of acid-fast bacilli and hyperkeratosis of epidermis, which are characteristic. Cutaneous anthrax should also be considered in the histopathological differential diagnosis, gram stain reveals gram-positive rod-shaped bacilli.

Orf-specific monoclonal antibody can also be used to confirm the diagnosis if necessary by means of ELISA or Western blot (KSHV ORF; Santa Cruz Biotechnology, Santa Cruz, Calif., USA). In vitro growth of the virus is unfortunately slow and inconsistent, and thus, use of this

technique does not represent an adequate diagnostic approach. Although serum analysis for antibodies against the orf virus is available as a diagnostic method, it is rarely used. Finally, a PCR-based diagnostic test specifically for the orf virus in humans has also been developed, and a more recent real-time PCR assay for parapoxvirus DNA has been used [18].

The treatment for orf is often focused on secondary infection since the orf infection typically resolves spontaneously. Secondary bacterial infection in patients infected with the orf virus should be aggressively treated. Previous reports have described successful treatment of complicated orf cases with topical imiquimod, resulting in rapid regression of the lesions [19]. In addition, others have described promising results following treatment of orf lesions with the antiviral cidofovir cream [20]. Cryotherapy has also been used successfully to speed up the healing process, especially in immunocompromised patients [21]. Importantly, physicians should be aware that orf infection occurs, albeit rarely, in North America and should therefore be considered in the differential diagnosis of cases with relevant animal exposure. Therefore, rapid and definitive diagnosis of orf is critical, and recognition of the benign nature of this virus infection is key because unnecessary overtreatment may be accompanied by complications.

Statement of Ethics

The patient gave written informed consent for the publication of this work.

Disclosure Statement

The authors have no conflicts of interest to disclose.

References

- 1 Lennette EH, Halonen P, Murphy FA (eds): Laboratory Diagnosis of Infectious Diseases: Principle and Practice. New York, Springer Verlag, 1988, pp 178–210.
- 2 Newson I, Cross F: Sore mouth transmissible to man. J Am Vet Med Assoc 1934;85:150–178.
- 3 Fleming SB, Wise LM, Mercer AA: Molecular genetic analysis of orf virus: a poxvirus that has adapted to skin. Viruses 2015;7:1505–1539.
- 4 Gill MJ, Arlette J, Buchan KA, Barber K: Human orf. A diagnostic consideration? Arch Dermatol 1990;126:356–358.
- 5 Johannessen JV, et al: Human orf. J Cutan Pathol 1975;2:265–283.
- 6 Robinson AJ, Petersen GV: Orf virus infection of workers in the meat industry. N Z Med J 1983;96:81–85.
- 7 Kluge JP, Chevillat NF, Peery TM: Ultrastructural studies of contagious ecthyma in sheep. Am J Vet Res 1972;33:1191–1200.
- 8 Georgiades G, Katsarou A, Dimitroglou K: Human orf (ecthyma contagiosum). J Hand Surg Br 2005;30:409–411.
- 9 Chahidi N, de Fontaine S, Lacotte B: Human orf. Br J Plast Surg 1993;46:532–534.
- 10 Centers for Disease Control and Prevention (CDC). Human orf virus infection from household exposures – United States, 2009–2011. MMWR Morb Mortal Wkly Rep 2012;61:245–248.
- 11 Rajkomar V, Hannah M, Coulson IH, Owen CM: A case of human to human transmission of orf between mother and child. Clin Exp Dermatol 2016;41:60–63.
- 12 Turk BG, Senturk B, Dereli T, Yaman B: A rare human-to-human transmission of orf. Int J Dermatol 2014;53:e63–e65.
- 13 Meier R, Sommacal A, Stahel A, et al: Orf – an orphan disease? JRSM Open 2015;6:2054270415593718.
- 14 Leavell UW, McNamera MJ, Muelling R, et al: Orf. Report of 19 human cases with clinical and pathological observations. JAMA 1968;204:657–664.
- 15 Joseph RH, Haddad FA, Matthews AL, et al: Erythema multiforme after orf virus infection: a report of two cases and literature review. Epidemiol Infect 2015;143:385–390.

- 16 Centers for Disease Control and Prevention (CDC). Human orf mimicking cutaneous anthrax – California. MMWR Morb Mortal Wkly Rep 1973;22:108.
- 17 Tan ST, Blake GB, Chambers S: Recurrent orf in an immunocompromised host. J Plast Surg 1991;44:465–467.
- 18 Gallina L, Dai Pozzo F, McInnes CJ, et al: A real-time PCR assay for the detection and quantification of orf virus. J Virol Methods 2006;134:140–145.
- 19 Erbagci Z, Erbagci I, Almila Tuncel A: Rapid improvement of human orf (ecthyma contagiosum) with topical imiquimod cream: report of four complicated cases. J Dermatolog Treat 2005;16:353–356.
- 20 De Clercq E: Clinical potential of the acyclic nucleoside phosphonates cidofovir, adefovir, and tenofovir in treatment of DNA virus and retrovirus infections. Clin Microbiol Rev 2003;16:569–596.
- 21 Degraeve C, De Coninck A, Senneseael J, Roseeuw D: Recurrent contagious ecthyma (Orf) in an immunocompromised host successfully treated with cryotherapy. Dermatology 1999;198:162–163.