



Proptosis in Otorhinolaryngology: An Overview

Novshaba Nazeer¹ Phani Bhushan Ivaturi²

¹ Department of ENT, Shadan Institute of Medical Sciences, Hyderabad, Telangana, India

² Department of ENT, Government Medical College, Nalgonda, India

Address for correspondence Phani Bhushan Ivaturi, MS ENT, Assistant Professor, Department of ENT, Government Medical College, Nalgonda, India (e-mail: novshani@gmail.com).

Int Arch Otorhinolaryngol 2021;25(2):e267–e272.

Abstract

Introduction Ear, nose and throat (ENT) pathologies can present with proptosis as the early manifestation. The majority of ENT pathologies present with ocular manifestations, due to close anatomical relationship.

Objective To study proptosis in ENT disorders in terms of etiology, pathogenesis, and management.

Methods The present article is a prospective study conducted at a tertiary care center, in Telangana, India. Patients presenting with proptosis secondary to ENT disorders were thoroughly evaluated and subjected to surgical exploration after providing a signed informed consent.

Results Sixty cases of proptosis secondary to ENT disorders have been reported. The most common cause was sinonasal squamous cell carcinoma followed by juvenile nasopharyngeal angiofibroma and allergic fungal rhinosinusitis.

Conclusion Many ENT disorders can present with proptosis. Proptosis needs to be evaluated completely for proper management and to limit the morbidity associated with it.

Keywords

- ▶ proptosis
- ▶ orbit
- ▶ Graves' disease
- ▶ ethmoid

Introduction

Proptosis is defined as the axial displacement of one or both eyeballs relative to the skull.¹ An otorhinolaryngologist should do a thorough evaluation of proptosis. Proptosis can be an early and, at times, the only manifestation of an ENT pathology. As there is close anatomical proximity of the orbit to the nose, sinuses, and the nasopharynx, the majority of ENT pathologies present with ocular manifestations.² The various routes attributed to the spread of this pathology are the foramen, fissures, vascular, erosion, and compression of the anatomical barriers.³ Radiological investigations play a major role in the diagnosis.⁴ Early diagnosis and treatment can revert proptosis in the majority of cases.⁵

Objectives

To determine the demographic characteristics, etiological factors, pathogenesis, and the various management strategies for proptosis in otorhinolaryngology

Materials and Methods

The present prospective study was conducted at the department of ENT of a tertiary care center in Telangana, India, for the duration of 2 years (June 2017–June 2019). Sixty cases of proptosis secondary to ENT disorders have been reported. Patients of all age groups presenting with proptosis due to ENT disorders who have given informed consent were included

received
September 25, 2019
accepted
March 4, 2020
published online
June 30, 2020

DOI <https://doi.org/10.1055/s-0040-1709986>.
ISSN 1809-9777.

© 2020. Fundação Otorrinolaringologia. All rights reserved.
This is an open access article published by Thieme under the terms of the Creative Commons Attribution-NonDerivative-NonCommercial-License, permitting copying and reproduction so long as the original work is given appropriate credit. Contents may not be used for commercial purposes, or adapted, remixed, transformed or built upon. (<https://creativecommons.org/licenses/by-nc-nd/4.0/>)
Thieme Revinter Publicações Ltda., Rua do Matoso 170, Rio de Janeiro, RJ, CEP 20270-135, Brazil

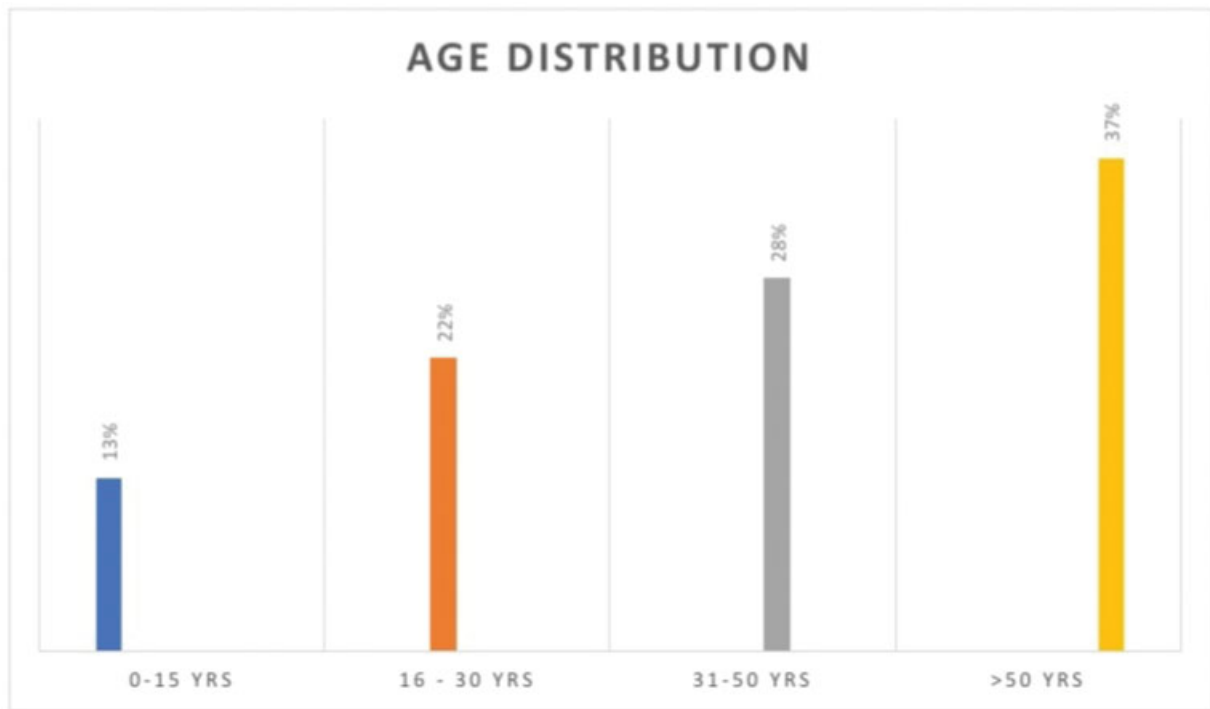


Fig. 1 Graph depicting age distribution of study population.

in present study. Patients with proptosis due to primary ocular pathology as well as those who have not given informed consent were excluded from present study. All patients were subjected to detailed history taking, clinical examination, diagnostic procedures and were subjected to treatment after signing the informed consent. Data regarding age, gender, etiology, ocular manifestations and treatment were recorded, and a statistical analysis was performed.

Ethical Approval

All procedures performed in studies involving human participants were in accordance with the ethical standards of the institution and with the 1964 Helsinki declaration and its later amendments or comparable ethical standards.

Results

(► **Figs. 1-3** and ► **Tables 1-4**).

Discussion

Sixty cases of ENT disorders leading to proptosis as one of the manifestations are reported in the present study.

Demographics

In the present study, the highest incidence of proptosis was noted in elderly patients (> 50 years old group), accounting for 22 cases (37%); this was followed by middle-aged patients

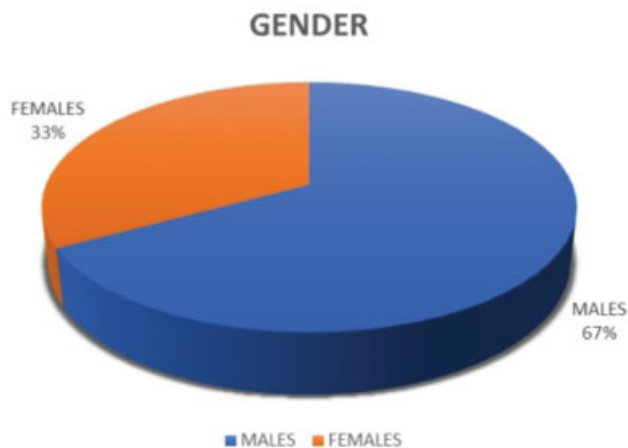


Fig. 2 Gender distribution of study population.

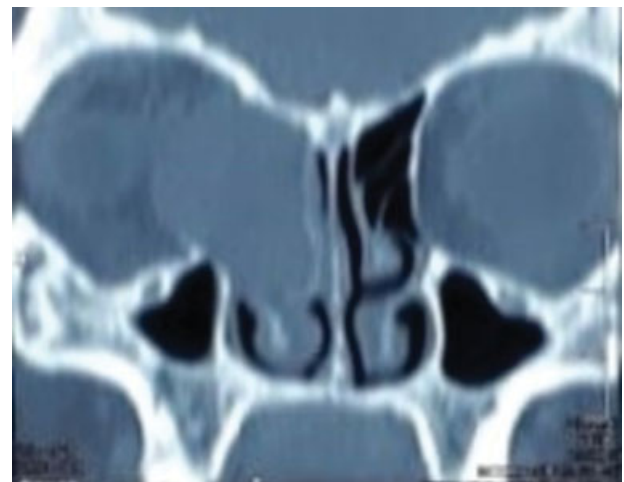

Fig. 3 Paranasal sinuses computed tomography coronal section depicting proptosis of the right eye resulting due to right ethmoid mucocele causing erosion of the right lamina papyracea.

Table 1 Etiology distribution of study population

Etiology	N; %
Nose and sinuses	
Nasal vestibulitis	1; 2%
Acute bacterial rhinosinusitis	3; 5%
Allergic fungal rhinosinusitis	6; 10%
Acute invasive fungal sinusitis	1; 2%
Fungal granuloma	3; 5%
Wegener granulomatosis	1; 2%
Ethmoid mucocele	2; 3%
Sinonasalschwannoma	2; 3%
Inverted papilloma	1; 2%
Frontal sinus osteoma	1; 2%
Fibrous dysplasia of maxilla	3; 5%
Fibrous dysplasia of ethmoid	1; 2%
Sinonasalsquamous cell carcinoma	12; 20%
Sinonasaladenocarcinoma	2; 3%
Sinonasaladenoid cystic carcinoma	2; 3%
Sinonasalembryonal rhabdomyosarcoma	1; 2%
Olfactory neuroblastoma	1; 2%
Nasopharynx	
Juvenile nasopharyngeal angiofibroma	7; 11%
Nasopharyngeal carcinoma	4; 6%
Thyroid	
Graves' disease	6; 10%

(31–50 years old group), accounting for 17 cases (28%), followed by the young patients group (16–30 years old), accounting for 13 cases (22%). The lowest incidence was noted in the group of patients aged 0–15 years old, accounting for 8 cases (13%). These data are similar to the ones presented in the study by Venugopal et al,⁶ in which the incidence of proptosis secondary to ENT disorders increased with advancing age.

The highest incidence of proptosis secondary to ENT disorders was noted in male patients, accounting for 40 cases (67%). In female patients, it accounted for 20 cases (33%). This is similar to the data presented in the study by Sinha et al.³ The male to female ratio was 2:1.

Etiology

In the present study, the anatomical categorization was nose, sinuses, nasopharynx, and thyroid, the pathology of which lead to one of the clinical manifestations of proptosis. In the nose and sinuses, the infective causes for proptosis were nasal vestibulitis (1; 2%), acute bacterial rhinosinusitis (3;5%), allergic fungal rhinosinusitis (6; 10%), and acute invasive fungal sinusitis (1; 2%). The granulomatous causes were fungal granuloma (3; 5%), and Wegener granulomatosis (1; 2%). The most common infectious etiology was Allergic fungal rhinosinusitis, and the most common granulomatous etiology was fungal granuloma. Sinonasal infections

Table 2 Etiopathogenesis of study population

Etiology	Pathogenesis
Nose and sinuses	
Nasal vestibulitis	Vascular (1; 2%)
Acute bacterial rhinosinusitis	Vascular (2; 3%) Compression (1; 2%)
Allergic fungal rhinosinusitis	Compression (6; 10%)
Acute invasive fungal sinusitis	Erosion (1; 2%)
Fungal granuloma	Compression (1; 2%) Erosion (2; 3%)
Wegener granulomatosis	Erosion (1; 2%)
Ethmoid mucocele	Compression (1; 2%) Erosion (1; 2%)
Sinonasalschwannoma	Compression (1; 2%) Erosion (1; 2%)
Inverted papilloma	Erosion (1; 2%)
Frontal sinus osteoma	Compression (1; 2%)
Fibrous dysplasia of maxilla	Compression (3; 5%)
Fibrous dysplasia of ethmoid	Compression (1; 2%)
Sinonasalsquamous cell carcinoma	Erosion (12; 20%)
Sinonasaladenocarcinoma	Erosion (2; 3%)
Sinonasaladenoid cystic carcinoma	Erosion (2; 3%)
Sinonasalembryonal rhabdomyosarcoma	Erosion (1; 2%)
Olfactory neuroblastoma	Erosion (1; 2%)
Nasopharynx	
Juvenile nasopharyngeal angiofibroma	Erosion (1; 2%) Compression (3; 5%) Spread via fissures (3; 5%)
Nasopharyngeal carcinoma	Erosion (2; 3%) Spread via fissures (2; 3%)
Thyroid	
Graves' disease	Increased intraconal fat (6; 10%)
TOTAL: Erosion: 28; 47% Compression: 18; 30% Vascular causing cavernous sinus involvement: 3; 5% Spread via fissures: 5; 8% Increased intraconal Fat: 6; 10%	

accounted for 15 cases (25%). In the nose and sinuses, the benign causes for proptosis were frontal sinus osteoma (1; 2%); fibrous dysplasia of the ethmoid sinus (1; 2%); fibrous dysplasia of the maxilla (3; 5%); sinonasal inverted papilloma (1; 2%); and sinonasal schwannoma (2; 3%). In the nasopharynx, the benign cause for proptosis was juvenile nasopharyngeal angiofibroma (7; 11%). In the present study, there were 4 fibrous dysplasia cases presenting as proptosis. Moore et al⁷ have reported 16 cases of fibrous dysplasia presenting as proptosis. The most common of benign tumor

Table 3 Non-surgical treatment distribution of study population

Etiology	Non-surgical management
Nose & sinuses	
Nasal vestibulitis	IV antibiotics (1; 2%) IV steroids (1; 2%)
Acute bacterial rhinosinusitis	IV antibiotics (3; 5%) IV steroids (2; 3%)
Allergic fungal rhinosinusitis	Intranasal steroids (6, 10%)
Acute invasive fungal sinusitis	IV amphotericin B (1; 2%) Oral itraconazole (1, 2%)
Fungal granuloma	IV amphotericin B (3; 5%) Oral itraconazole (3; 5%)
Wegener granulomatosis	Oral steroids (1, 2%) Oral cyclosporin (1; 2%)
Ethmoid mucocele	–
Sinonasal schwannoma	–
Inverted papilloma	–
Frontal sinus osteoma	–
Fibrous dysplasia of maxilla	–
Fibrous dysplasia of ethmoid	–
Sinonasal squamous cell carcinoma	Radiotherapy (10; 17%) Postoperative radiotherapy (2; 3%)
Sinonasal adenocarcinoma	–
Sinonasal adenoid cystic carcinoma	Postoperative radiotherapy (2; 3%)
Sinonasal embryonal rhabdomyosarcoma	Chemotherapy (1; 2%)
Olfactory neuroblastoma	Postoperative radiotherapy (1; 2%)
NASOPHARYNX	
Juvenile nasopharyngeal angiofibroma	–
Nasopharyngeal carcinoma	Radiotherapy (4; 6%)
Thyroid	
Graves' disease	Antithyroid drugs (6; 10%)
TOTAL: Antibiotics: IV (4; 6%) Steroids: Oral (1; 2%), IV (3; 5%), intranasal (6; 10%) = 10, 17% Immunosuppressive: Oral cyclosporin (1; 2%) Antifungals: IV amphotericin B (4; 6%), Oral itraconazole (4; 6%) Antithyroid drugs: 6; 10% Radiotherapy: 19; 32% of which 5; 8% were postoperative radiotherapy Chemotherapy: 1; 2%	

Abbreviation: IV, intravenous.

was juvenile nasopharyngeal angiofibroma. This is in accordance with the study by Sinha et al.³ Sinonasal and nasopharyngeal benign tumors accounted for 15 cases (25%). In the nose and sinuses, the malignant causes for proptosis were sinonasal squamous cell carcinoma (12; 20%); sinonasal adenocarcinoma (2; 3%); sinonasal adenoid cystic carcinoma (2; 3%); sinonasal embryonal rhabdomyosarcoma (1; 2%);

Table 4 Surgical treatment of study population

Etiology	Surgery
Nose & sinuses	
Nasal vestibulitis	Incision & drainage (1; 2%)
Acute bacterial rhinosinusitis	Functional endoscopic sinus surgery (3; 5%)
Allergic fungal rhinosinusitis	Functional endoscopic sinus surgery (6; 10%)
Acute invasive fungal sinusitis	Endoscopic sinus surgery and debridement (1; 2%)
Fungal granuloma	Endoscopic sinus surgery (3; 5%)
Wegener granulomatosis	Endoscopic sinus surgery (1; 2%)
Ethmoid mucocele	Functional endoscopic sinus surgery (2; 3%)
Sinonasalschwannoma	Endoscopic resection (2; 3%)
Inverted papilloma	Endoscopic resection (1; 2%)
Frontal sinus osteoma	Bicoronal incision and excision (1; 2%)
Fibrous dysplasia of maxilla	Lateral rhinotomy & paring (3; 5%)
Fibrous dysplasia of ethmoid	Lynch-Howarth external approach and removal (1; 2%)
Sinonasalsquamous cell carcinoma	Total maxillectomy (2; 3%)
Sinonasaladenocarcinoma	Total maxillectomy (2; 3%)
Sinonasaladenoid cystic carcinoma	Total maxillectomy (2; 3%)
Sinonasalembrional rhabdomyosarcoma	–
Olfactory neuroblastoma	Endoscopic resection (1; 2%)
Nasopharynx	
Juvenile nasopharyngeal angiofibroma	Endoscopic surgery with coblation (2; 3%) Lateral rhinotomy (5, 8%)
Nasopharyngeal carcinoma	–
Thyroid	
Graves' disease	Orbital decompression (2; 3%) Subtotal thyroidectomy (6; 10%)
TOTAL: Incision and drainage: 1; 2% Functional endoscopic sinus surgery: 11; 18% Endoscopic sinus surgery: 5; 8% Endoscopic resection: 4; 6% Bicoronal incision & excision: 1; 2% Lynch-Howarth external approach & removal: 1; 2% Lateral rhinotomy: 8; 13% Total maxillectomy: 6; 10% Endoscopic coblation surgery: 2; 3% Orbital decompression: 2; 3% Subtotal thyroidectomy: 6; 10%	

and olfactory neuroblastoma (1; 2%). In the nasopharynx, the malignant cause for proptosis was nasopharyngeal carcinoma (4; 6%). The most common of malignant tumor was sinonasal squamous cell carcinoma. This is in accordance with the studies by Conley et al,⁵ Sabharwal et al,⁸ Sayed

et al,⁹ and Johnson et al.¹⁰ Sinonasal and nasopharyngeal malignant tumors accounted for 22 cases (37%). The miscellaneous causes for proptosis were ethmoid mucocele (2; 3%) and Graves' disease (6; 10%). It was evident that malignant tumors, especially sinonasal squamous cell carcinoma, presented most commonly with proptosis manifestation, followed by juvenile nasopharyngeal angiofibroma and allergic fungal rhinosinusitis.

Pathogenesis

In the present study, the various pathogeneses for proptosis were erosion of anatomical barriers (28; 47%), compression of anatomical barriers (18; 30%); vascular spread leading to cavernous sinus involvement (3; 5%); spread via fissures (5; 8%); and increased intraconal fat (6; 10%). The computed tomography (CT), magnetic resonance imaging (MRI), and surgical exploration have played a role in identifying the various routes of involvement of the orbit that led to proptosis as one of the manifestations. The most common route was erosion of the anatomical barriers followed by compression of the anatomical barriers. The majority of malignant tumors were responsible for erosion of the anatomical barriers, whereas the majority of benign tumors and infective causes were responsible for compression of the anatomical barriers. One case of nasal vestibulitis and 2 cases of acute bacterial rhinosinusitis presented as cavernous sinus involvement, suggesting the valveless nature of communicating veins. This finding is similar to that reported in the study by Canon et al,¹¹ according to which sinusitis and untreated nasal vestibulitis can complicate to cavernous sinus thrombosis.

Management

Five cases (8%) were treated with non-surgical modalities alone, of which 1 case was of sinonasal embryonal rhabdomyosarcoma, and 4 cases were of nasopharyngeal carcinoma. Nineteen cases (32%) were treated with surgical modality alone, 7 of which were cases of juvenile nasopharyngeal angiofibroma, 2 cases were of sinonasal adenocarcinoma, 3 cases were of fibrous dysplasia of maxilla, 1 case was of fibrous dysplasia of ethmoid, 1 case was of frontal sinus osteoma, 1 case was of inverted papilloma, 2 cases were of sinonasal schwannoma, and 2 cases were of ethmoid mucocele. Thirty-six cases (60%) required a combined modality of both non-surgical and surgical treatments.

Non-surgical Measures

Nineteen cases (32%) were treated with radiotherapy, of which 10 cases were of sinonasal squamous cell carcinoma, 4 cases were of nasopharyngeal carcinoma, and 5 cases were given postoperative radiotherapy (1 case of olfactory neuroblastoma, 2 cases of sinonasal squamous cell carcinoma, 2 cases of sinonasal adenoid cystic carcinoma). Ten cases (17%) were treated with steroids, of which 1 case was of nasal vestibulitis, 2 cases of acute bacterial rhinosinusitis were treated with intravenous steroids, 6 cases of allergic fungal rhinosinusitis were treated with intranasal steroids, and 1 case of Wegener granulomatosis was treated

with oral steroids. Four cases (6%) were treated with antifungals, of which 1 case was of acute invasive fungal sinusitis, and 3 cases of fungal granuloma were treated with both IV amphotericin B and oral itraconazole. Four cases (6%) were treated with intravenous antibiotics, of which 1 case was of nasal vestibulitis and 3 cases were of acute bacterial rhinosinusitis. Cavernous sinus involvement cases (3) were treated with intravenous antibiotics and intravenous steroids. This is similar to that reported in the study by Abhay et al.¹² One case of Wegener granulomatosis was also given oral cyclosporin. One case of sinonasal embryonal rhabdomyosarcoma was treated with chemotherapy. All 6 cases of Graves' disease (10%) were treated with antithyroid drugs.

Surgical Measures

Eleven cases (18%) were treated with functional endoscopic sinus surgery, of which 3 cases were of acute bacterial rhinosinusitis, 6 cases were of allergic fungal rhinosinusitis, and 2 cases were of ethmoid mucocele. Six cases (10%) were treated with total maxillectomy, of which 2 cases were of sinonasal squamous cell carcinoma, 2 cases were of sinonasal adenoid cystic carcinoma, and 2 cases were of sinonasal adenocarcinoma. Three cases required orbital exenteration (2 cases of sinonasal squamous cell carcinoma and 1 case of sinonasal adenoid cystic carcinoma). Eight cases (13%) were treated with a lateral rhinotomy approach, of which 5 cases were of juvenile nasopharyngeal carcinoma, and 3 cases were of fibrous dysplasia of maxilla, in which paring was done. Five cases (8%) were treated with endoscopic sinus surgery, of which 1 case was of acute invasive fungal sinusitis, in which debridement was done, 3 cases were of fungal granuloma, and 1 case was of Wegener granulomatosis. In 4 cases (6%), endoscopic resection was done; out of these, 1 case was of inverted papilloma, 1 case was of olfactory neuroblastoma, and 2 cases were of sinonasal schwannoma. All 6 cases of Graves' disease were treated with subtotal thyroidectomy, of which 2 cases also required orbital decompression as an emergency treatment to prevent loss of vision due to increasing intraorbital pressure. Nasal vestibulitis (1 case) required incision and drainage. Frontal sinus osteoma (1 case) managed by bicoronal incision and excision. Fibrous dysplasia of ethmoid sinus (1 case) was managed by Lynch-Howarth external approach and removal. Two cases of nasopharyngeal angiofibroma were treated with endoscopic coblation method.

Conclusion

The majority of nose, sinuses, nasopharyngeal and thyroid pathologies can present proptosis as one of the clinical manifestations. The resultant compression of the orbit can raise the intraorbital pressure, thus leading to increased mortality and morbidity (blindness). Hence, it is essential for an otorhinolaryngologist and ophthalmologist to thoroughly evaluate the proptosis and work as a team to diagnose and manage this disorder at the earliest to prevent blindness as well as to address the cosmetic defect.

Conflict of Interest

The authors declare that there are no conflict of interests.

References

- 1 Wright JE. Proptosis. *Ann R Coll Surg Engl* 1970;47(06):323–334
- 2 Williamson-Noble FA, Williamson-Noble FA. Diseases of the orbit and its contents, secondary to pathological conditions of the nose and paranasal sinuses. *Ann R Coll Surg Engl* 1954;15(01):46–64
- 3 Sinha V, Bhardwaj D, George A, Memon RA. Proptosis through eyes of E.N.T. surgeon. *Indian J Otolaryngol Head Neck Surg* 2005; 57(03):207–209
- 4 Mahsud ZS, Bano S. Diagnostic role of CT scan in proptosis in paediatric age group. *J Postgrad Med Inst* 2004;18(03):439–442
- 5 Conley J, Baker DC. Management of the eye socket in cancer of the paranasal sinuses. *Arch Otolaryngol* 1979;105(12):702–705
- 6 Venugopal M, Sagesh M. Proptosis: The ENT Surgeon's Perspective. *Indian J Otolaryngol Head Neck Surg* 2013;65(02, Suppl 2):247–250
- 7 Moore AT, Buncic JR, Munro IR. Fibrous dysplasia of the orbit in childhood. Clinical features and management. *Ophthalmology* 1985;92(01):12–20
- 8 Sabharwal KK, Chouhal AL, Jain S. Evaluation of proptosis. *Indian J Radiol Imaging* 2006;16(04):683–688
- 9 Sayed YEL. Orbital involvement in sinonasal disease. *Saudi J Ophthalmol* 1995;9(01):29–37
- 10 Johnson LN, Krohel GB, Yeon EB, Parnes SM. Sinus tumors invading the orbit. *Ophthalmology* 1984;91(03):209–217
- 11 Cannon ML, Antonio BL, McCloskey JJ, Hines MH, Tobin JR, Shetty AK. Cavernous sinus thrombosis complicating sinusitis. *Pediatr Crit Care Med* 2004;5(01):86–88
- 12 Kumar A, Chauhan JPS, Bhadouriya SKS, Bharti B, Narain P, Singh J. Orbital complications of ENT diseases. *International Journal Of Otorhinolaryngology and Head and Neck Surgery*. 2018;4(01):210–216