

A neonate with late-onset hypocalcemia due to unrecognized maternal hyperparathyroidism and a systematic overview of similar cases

Ein Neugeborenes mit spät einsetzender Hypokalzämie aufgrund eines nicht erkannten mütterlichen Hyperparathyreoidismus und eine systematische Übersicht über ähnliche Fälle

Abstract

Objective: Neonatal seizures are alarming manifestations of an underlying significant disorder demanding immediate attention and intervention. Hypocalcemia, although rare, must be considered in the differential diagnosis of neonatal seizures.

Method: We present an unusual case of a 10-day-old infant with unexplained symptomatic hypocalcemia, experiencing multiple episodes of focal tonic-clonic seizures, born by an entirely asymptomatic mother. Moreover, we conducted a systematic search in PubMed and Scopus databases to present a clinical overview of all similar cases.

Result: Maternal laboratory investigation revealed markedly increased calcium levels with concomitant high parathyroid hormone levels due to a parathyroid adenoma, undiagnosed during antenatal checkup.

Conclusion: This is one of the few cases in the literature where neonatal symptomatology led to the diagnosis of undiagnosed maternal hyperparathyroidism. Early detection and appropriate management of neonatal hypocalcemia could eliminate serious maternal and fetal morbidity.

Keywords: neonates, hypocalcemia, hyperparathyroidism, seizures

Zusammenfassung

Zielsetzung: Krampfanfälle bei Neugeborenen sind alarmierende Manifestationen einer zugrunde liegenden signifikanten Störung, die sofortige Aufmerksamkeit und Intervention erfordert. Obwohl Hypokalzämien selten sind, müssen sie bei der Differentialdiagnose von Krampfanfällen bei Neugeborenen berücksichtigt werden.

Methode: Wir präsentieren einen ungewöhnlichen Fall eines 10 Tage alten Kindes mit ungeklärter symptomatischer Hypokalzämie, bei dem mehrere Episoden fokaler tonisch-klonischer Anfälle auftraten. Das Kind wurde von einer völlig asymptomatischen Mutter geboren. Darüber hinaus haben wir eine systematische Suche in den PubMed- und Scopus-Datenbanken durchgeführt, um einen klinischen Überblick über alle ähnlichen Fälle zu erhalten.

Ergebnis: Laboruntersuchungen bei der Mutter ergaben einen deutlich erhöhten Kalziumspiegel bei gleichzeitig hohen Nebenschilddrüsenhormonspiegeln aufgrund eines Nebenschilddrüsenadenoms, das während der vorgeburtlichen Untersuchungen nicht diagnostiziert wurde.

Schlussfolgerung: Dies ist einer der wenigen Fälle in der Literatur, in denen die Neugeborenen-Symptomatik zur Diagnose eines nicht diagnostizierten mütterlichen Hyperparathyreoidismus führte. Eine frühzeitige Erkennung und angemessene Behandlung der neonatalen Hypokalzämie könnte eine schwerwiegende Morbidität bei Mutter und Kind verhindern.

Georgios Mitsiakos¹
Georgios N. Katsaras¹
Ilias Chatziioannidis¹
Anastasia Gkampeta¹
Christina Mitsiakou¹
Nikolaos Nikolaidis¹

1. 2nd Neonatal Department and Neonatal Intensive Care Unit, Aristotle University of Thessaloniki, "Papageorgiou" General Hospital of Thessaloniki, Greece

Schlüsselwörter: Neugeborene, Hypokalzämie, Hyperparathyroidismus, Krampfanfälle

Introduction

Neonatal hypocalcemia, although rare, must be considered in the differential diagnosis of neonatal seizures which are alarming manifestations of an underlying disorder demanding immediate evaluation and intervention [1]. Neonatal hypocalcemia occurring in the first three days of life is defined as early-onset, whereas occurring after the first three days of life it is defined as late-onset hypocalcemia [2].

Primary hyperparathyroidism (PHP) during pregnancy is a very rare condition increasing both maternal and perinatal morbidity and mortality. Thus, early detection and intervention is mandatory, the optimal time being during the second trimester [3], [4], [5], [6]. Maternal hyperparathyroidism can lead to profound neonatal hypocalcemia and hypocalcemic tetany, occurring approximately in 50% of infants born from mothers with untreated disease. Neonatal hypocalcemia is attributed to prolonged parathyroid suppression from the chronic hypercalcemic maternal state and the abrupt halt of maternal calcium following delivery [7].

The investigation of a newborn's hypocalcemia should not focus on the patient alone. Detailed examination and laboratory investigation of an apparently healthy mother could be beneficial for both neonate and mother.

In this article, we present a case of neonatal seizures due to undiagnosed maternal hyperparathyroidism. What is more, we conducted a systematic search in PubMed and Scopus databases using the terms "maternal hyperparathyroidism", "hyp?parathyroidism", "neonat*" and "newborn" in order to meta-analyze the published case reports of neonatal events that led to the diagnosis of unrecognized maternal hyperparathyroidism.

Case description

A 10-day-old male neonate was admitted to our Neonatal Intensive Care Unit (NICU) due to multiple episodes of focal tonic-clonic seizures. He was born at 40 weeks gestational age and 3060 g birth weight after an uneventful pregnancy and an uncomplicated vaginal delivery. The last 24 hours, he started having several episodes of left upper extremity's jerking combined with rapid eye blinking on the same side. There was no history of trauma or clinical signs of infection.

On admission, a detailed clinical examination and a full sepsis screen, including lumbar puncture, revealed no signs of infection. Detailed laboratory investigation exhibited hypocalcemia with hyperphosphatemia [$\text{Ca}=5.4\text{mg/dl}$ (normal reference range: 9.0–10.9 mg/dl), $\text{P}=11.8\text{mg/dl}$ (normal reference range: 4.8–8.2 mg/dl)]. Immediately, Ca gluconate 10% (8 ml/H) was administered to the in-

fant, but seizures did not resolve, hypocalcemia persisted while the neonate experienced an episode of bradycardia. A subsequent brain ultrasound and cerebral function monitoring (CFM) were negative for cerebral pathology. Serum electrolytes, plasma glucose and arterial gases were all within normal ranges. However, total serum and ionized calcium levels were low [7.4 mg/dl and 3.8 mg/dl (normal reference range: 4.52–5.2 mg/dl), respectively], with normal magnesium and high phosphate levels (1.6 mg/dl and 10.2 mg/dl, respectively). Parathyroid hormone (PTH) levels were low (14.5 pg/ml, normal reference range: 10–65 pg/ml).

The neonate started calcium gluconate 10% (8ml/H) as well as vitamin D (1 α -OH D₃, 0.25 $\mu\text{g/day}$), and monitoring of PTH and serum electrolytes was established. The seizures resolved after 24 hours and the neonate was discharged 20 days later with normal electrolyte levels. Vitamin D and calcium supplement were stopped after 3 months. During follow-up, the patient remained seizure-free, with normal serum calcium and PTH levels (9.66 mg/dl and 22.3 pg/ml).

Because of the unexplained neonatal hypocalcemia secondary to hypoparathyroidism, a maternal blood sample was taken for further evaluation. The mother was clinically asymptomatic. She had a positive history of nephrolithiasis from a few years ago. The mother's evaluation revealed high total calcium and ionized calcium levels (12.48 mg/dl and 7 mg/dl, respectively) with concomitant high PTH (201 pg/ml) levels. Based on these findings, maternal hyperparathyroidism was suspected. Further investigation with ultrasonography revealed a hypoechogenic nodule in the thyroid gland, and Tc-99m sestamibi scintigraphy demonstrated focally increased uptake in the corresponding site, suggestive of parathyroid adenoma. After 6 months, a macroscopically nodule of 0.5 g weight and 2 cm maximum diameter was removed surgically, while the histopathologic examination confirmed the diagnosis of parathyroid adenoma.

Discussion

We describe a rare case of neonatal symptomatology leading to the diagnosis of maternal hyperparathyroidism. The case underlines the necessity of maternal investigation whenever neonatal hypocalcemia is detected.

Maternal hypercalcemic hyperparathyroidism causes suppression of fetal parathyroid glands secondary to an increased calcium flux across the placenta to the fetus. This leads to neonatal hypoparathyroidism and subsequent hypocalcemia. This could be attributed to the unknown interaction of parathyroid hormone-related peptide (PTHrP) that could activate the PTH receptor resulting in hypercalcemic and hyperphosphaturic PTH-like activity during the early neonatal period. Although its detailed physiological function remains unknown, PTHrP

Table 1: Published cases of neonatal hypoparathyroidism due to maternal unrecognized hyperparathyroidism from 1938 until today

Case report	N	Age at diagnosis	Symptoms
Pragathi et al. (2019) [47]	1	4 th day of life	Seizures
Tseng et al. (2016) [16]	1	14 th postnatal day	Seizures and tetany
Long et al. (2015) [17]	1	7 th postnatal day	Tonic-clonic seizures
Razavi et al. (2014) [18]	1	10 th postnatal day	Tetany
Çakır et al. (2013) [20]	1	21 st postnatal day	Seizures and tetany
Korkmaz et al. (2013) [19]	1	14 th postnatal day	Tonic seizures
Nilsson et al. (2010) [40]	1	5 th postnatal day	Circulatory collapse
Dinçer et al. (2008) [41]	1	1 st month of life	Seizures
Poomthavom et al. (2008) [21]	2	First 2 weeks of life	Seizures
Haynes (2007) [42]	1	1 st week of life	Seizures and choking episodes during feedings
Alikasifoglu et al. (2005) [23]	1	1 st month of life	Multiple bone fractures
Ip (2003) [24]	1	2 nd month of life	Seizures
Pieringer et al. (2007) [22]	1	15 th postnatal day	Tetany
Tseng et al. (2001) [25]	4	6 th –17 th postnatal day	Seizures (in 3 cases), pitch crying, irritability, opisthotonus (in 1 case)
Beattie et al. (2000) [44]	2	10 th and 11 th postnatal day, respectively	Seizures
Karowski et al. (2000) [46]	1	2 nd postnatal day	Asymptomatic hypocalcemia
Thomas et al. (1999) [45]	2	1 st month and 6 th week of life, respectively	Severe metabolic disease and seizures, respectively
Hsieh et al. (1998) [37]	1	2 nd postnatal day	Seizures
Thomas et al. (1995) [26]	2	2 nd week and 5 th postnatal day, respectively	Seizures
Brisse et al. (1994) [27]	1	7 th postnatal day	Dyspnea and repeated seizures
Furioli et al. (1990) [39]	1	6 th postnatal day	Seizures
Ozeki et al. (1977) [28]	1	1 st month of life	Seizures
Zeisner et al. (1977) [38]	1	N/A	Seizures
Monteleone et al. (1975) [29]	1	1 st month of life	Tetany
Rosenthal et al. (1975) [30]	1	3 rd week of life	Tetany
Better et al. (1973) [32]	1	19 th postnatal day	Seizures
Bonquentin et al. (1973) [31]	2	3 rd and 13 th postnatal day, respectively	Seizures
Ertel et al. (1969) [33]	1	14 th postnatal day	Twitching
Willi et al. (1966) [34]	1	1 st month of life	Seizures
VanArsdel (1955) [35]	1	10 th postnatal day	Seizures
Walton (1954) [36]	2	8 th and 5 th postnatal day, respectively	Tetany
Friderichsen (1938) [43]	1	N/A	Seizures

N/A: not available

could play a role during pregnancy and the perinatal period as it is produced by the placenta and fetal parathyroid glands and is found in the mother's milk as well [7], [8].

Primary maternal hyperparathyroidism is a rare but severe complication of pregnancy. The early diagnosis during pregnancy remains difficult, as the symptoms are usually subtle and are easily confused with other minor complications of pregnancy. Maternal symptomatology may be nonspecific with fatigue, subtle mental changes, weakness, and hyperemesis; or more specific with nephrolithiasis, pancreatitis, gastrointestinal ulcers, and life-threatening hypercalcemic crisis. Rarely, signs of complicated gestation are present (intrauterine growth retardation, spontaneous abortion, preterm delivery, low birth

weight) [8], [9], [10], [11], [12], [13], [14], [15]. In our case, the mother had a renal colic due to nephrolithiasis 2 years ago, treated with medications without recurrences.

Worldwide, few cases of neonatal hypoparathyroidism due to maternal unrecognized hyperparathyroidism have been described (Table 1). Since 1938, 41 cases have been described [16], [17], [18], [19], [20], [21], [22], [23], [24], [25], [26], [27], [28], [29], [30], [31], [32], [33], [34], [35], [36], [37], [38], [39], [40], [41], [42], [43], [44], [45], [46], [47]. A qualitative analysis of these cases showed that the median day of neonatal hypoparathyroidism is the 11th postnatal day with IQR: 7th–21st postnatal days (Figure 1). The majority of cases presented with seizures (63.4%), followed by tetanus (19.5%). Other

symptoms, such as twitching, choking, pitch crying, irritability, dyspnea, severe metabolic disease and circulatory collapse were rarely reported (2.4% each of them).

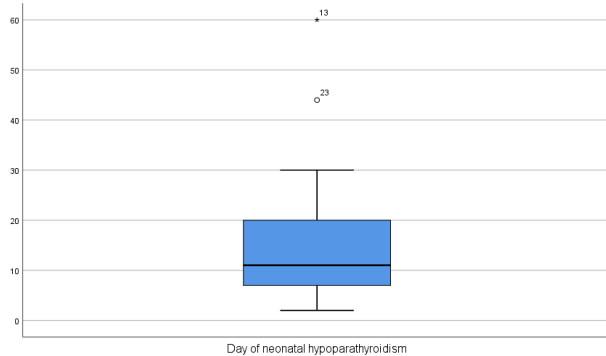


Figure 1: Box-Plot: Day of neonatal clinical findings of hypoparathyroidism

Conclusions

Our case enhances the findings of the current literature. As neonatal hypocalcemia usually occurs soon after birth in high-risk infants, any unexplained late-onset hypocalcemia, especially if neonatal seizures are present, warrants further investigation including maternal calcium and phosphate levels. High obstetricians' and pediatricians' alertness are required for early detection of maternal hyperparathyroidism and its underlying cause.

Notes

Informed consent

Informed consent has been obtained from the patient's mother for the publication of this case report.

Authors' contributions

Georgios Mitsiakos participated in supervision, conceptualization, investigation, methodology, writing, original drafting of the manuscript and validating the final form. Georgios N. Katsaras, Anastasia Gkampeta and Christina Mitsiakou participated in conceptualization, investigation, methodology, writing and original drafting the manuscript. Ilias Chatziioannidis, Paraskevi Karagianni and Nikolaos Nikolaidis were responsible for investigation, methodology, validation, editing and reviewing the paper.

Competing interests

The authors declare that they have no competing interests.

References

- Painter MJ, Bergman I, Crumrine P. Neonatal seizures. *Pediatr Clin North Am.* 1986 Feb;33(1):91-109. DOI: 10.1016/S0031-3955(16)34971-9
- Jain A, Agarwal R, Sankar MJ, Deorari A, Paul VK. Hypocalcemia in the newborn. *Indian J Pediatr.* 2010 Oct;77(10):1123-8. DOI: 10.1007/s12098-010-0176-0
- Graham EM, Freedman LJ, Forouzan I. Intrauterine growth retardation in a woman with primary hyperparathyroidism. A case report. *J Reprod Med.* 1998 May;43(5):451-4.
- Inabnet WB, Baldwin D, Daniel RO, Staren ED. Hyperparathyroidism and pancreatitis during pregnancy. *Surgery.* 1996 Jun;119(6):710-3. DOI: 10.1016/S0039-6060(96)80198-X
- Kaplan EL, Burrington JD, Klementsichs P, Taylor J, Deftos L. Primary hyperparathyroidism, pregnancy, and neonatal hypocalcemia. *Surgery.* 1984 Oct;96(4):717-22.
- Murray JA, Newman WA 3rd, Dacus JV. Hyperparathyroidism in pregnancy: diagnostic dilemma? *Obstet Gynecol Surv.* 1997 Mar;52(3):202-5. DOI: 10.1097/00006254-199703000-00024
- Kovacs CS, Kronenberg HM. Maternal-fetal calcium and bone metabolism during pregnancy, puerperium, and lactation. *Endocr Rev.* 1997 Dec;18(6):832-72. DOI: 10.1210/edrv.18.6.0319
- Strewler GJ. The physiology of parathyroid hormone-related protein. *N Engl J Med.* 2000 Jan;342(3):177-85. DOI: 10.1056/NEJM200001203420306
- Kelly TR. Primary hyperparathyroidism during pregnancy. *Surgery.* 1991 Dec;110(6):1028-33; discussion 1033-4.
- Peschgens T, Stollbrink-Peschgens C, Merz U, Schneider B, Maurin N, Kutta T, Hörnchen H. Primärer Hyperparathyroidismus und Schwangerschaft. Aspekte der Neugeborenen-Morbidität [Primary hyperparathyroidism and pregnancy. Aspects of neonatal morbidity]. *Z Geburtshilfe Perinatol.* 1994 May-Jun;198(3):96-9.
- Rooney DP, Traub AI, Russell CF, Hadden DR. Cure of hyperparathyroidism in pregnancy by sternotomy and removal of a mediastinal parathyroid adenoma. *Postgrad Med J.* 1998 Apr;74(870):233-4. DOI: 10.1136/pgmj.74.870.233
- Iqbal N, Steinberg H, Aldasouqi S, Edmondson JW. Nephrolithiasis during pregnancy secondary to primary hyperparathyroidism. *Urology.* 2001 Mar;57(3):554. DOI: 10.1016/S0090-4295(00)01061-x
- Hong MK, Hsieh CT, Chen BH, Tu ST, Chou PH. Primary hyperparathyroidism and acute pancreatitis during the third trimester of pregnancy. *J Matern Fetal Med.* 2001 Jun;10(3):214-8. DOI: 10.1080/714904315
- Schnatz PF, Curry SL. Primary hyperparathyroidism in pregnancy: evidence-based management. *Obstet Gynecol Surv.* 2002 Jun;57(6):365-76. DOI: 10.1097/00006254-200206000-00022
- Cherry TA, Kauffman RP, Myles TD. Primary hyperparathyroidism, hypercalcemic crisis and subsequent seizures occurring during pregnancy: a case report. *J Matern Fetal Neonatal Med.* 2002 Nov;12(5):349-52. DOI: 10.1080/jmf.12.5.349.352
- Tseng MH, Chu SM, Lo FS, Lien RI, Cheng CJ, Lin SH. A neonate with recurrent tetany: questions and answers. *Pediatr Nephrol.* 2016 May;31(5):753, 755-7. DOI: 10.1007/s00467-015-3107-5
- Long K, Cartwright T, Sloan D, Lee C. Cystic multiglandular maternal hyperparathyroidism diagnosed by neonatal hypocalcemic seizures. *J Surg Case Rep.* 2015 Mar;2015(3):rvj031. DOI: 10.1093/jscr/rvj031

18. Razavi CR, Charitou M, Marzouk M. Maternal atypical parathyroid adenoma as a cause of newborn hypocalcemic tetany. *Otolaryngol Head Neck Surg*. 2014 Dec;151(6):1084-5. DOI: 10.1177/0194599814555850
19. Korkmaz HA, Ozkan B, Terek D, Dizdärer C, Arslanoğlu S. Neonatal seizure as a manifestation of unrecognized maternal hyperparathyroidism. *J Clin Res Pediatr Endocrinol*. 2013 Sep;5(3):206-8. DOI: 10.4274/Jcrpe.1037
20. Çakır U, Alan S, Erdeve Ö, Atasay B, Şıklar Z, Berberoğlu M, Arslan S. Late neonatal hypocalcemic tetany as a manifestation of unrecognized maternal primary hyperparathyroidism. *Turk J Pediatr*. 2013 Jul-Aug;55(4):438-40.
21. Poomthavorn P, Ongphiphadhanakul B, Mahachoklertwattana P. Transient neonatal hypoparathyroidism in two siblings unmasking maternal normocalcemic hyperparathyroidism. *Eur J Pediatr*. 2008 Apr;167(4):431-4. DOI: 10.1007/s00431-007-0528-6
22. Pieringer H, Hatzl-Griesenhofer M, Shebl O, Wiesinger-Eidenberger G, Maschek W, Biesenbach G. Hypocalcemic tetany in the newborn as a manifestation of unrecognized maternal primary hyperparathyroidism. *Wien Klin Wochenschr*. 2007;119(3-4):129-31. DOI: 10.1007/s00508-006-0748-1
23. Alikasifoglu A, Gonc EN, Yalcin E, Dogru D, Yordam N. Neonatal hyperparathyroidism due to maternal hypoparathyroidism and vitamin D deficiency: a cause of multiple bone fractures. *Clin Pediatr (Phila)*. 2005 Apr;44(3):267-9. DOI: 10.1177/000992280504400312
24. Ip P. Neonatal convulsion revealing maternal hyperparathyroidism: an unusual case of late neonatal hypoparathyroidism. *Arch Gynecol Obstet*. 2003 Aug;268(3):227-9. DOI: 10.1007/s00404-002-0316-5
25. Tseng UF, Shu SG, Chen CH, Chi CS. Transient neonatal hypoparathyroidism: report of four cases. *Acta Paediatr Taiwan*. 2001 Nov-Dec;42(6):359-62.
26. Thomas BR, Bennett JD. Symptomatic hypocalcemia and hypoparathyroidism in two infants of mothers with hyperparathyroidism and familial benign hypercalcemia. *J Perinatol*. 1995 Jan-Feb;15(1):23-6.
27. Brisse F, Breton D, Gagey V, Chéron G. Convulsions et hypoparathyroïdie néonatales révélant une hyperparathyroïdie maternelle [Convulsions and neonatal hypoparathyroidism revealing maternal hyperparathyroidism]. *Arch Pediatr*. 1994 Mar;1(3):255-9.
28. Ozeki T, Egi S, Takehiro A, Otsuka S, Egawa M. Neonatal tetany due to maternal calcium metabolism disorder – maternal hyperparathyroidism (parathyroid cancer) and familial idiopathic hypoparathyroidism. *Horumon To Rinsho*. 1977 Aug;25(8):825-9.
29. Monteleone JA, Lee JB, Tashjian AH Jr, Cantor HE. Transient neonatal hypocalcemia, hypomagnesemia, and high serum parathyroid hormone with maternal hyperparathyroidism. *Ann Intern Med*. 1975 May;82(5):670-2. DOI: 10.7326/0003-4819-82-5-670
30. Rosenthal T, Yahav J, Teicher A, Frand M, Rotem Y. A case of maternal hyperparathyroidism presenting as neonatal tetany. *Isr J Med Sci*. 1975 Jan;11(1):30-2.
31. Bocquentin F, Safar A, Aicardi J, Job JC. Tétanie hypocalcémique néonatale chez deux enfants d'une mère hyperparathyroïdienne [Neonatal hypocalcemic tetany in 2 children of a mother with hyperparathyroidism]. *Arch Fr Pediatr*. 1973 Nov;30(9):989-98.
32. Better OS, Levi J, Grief E, Tuma S, Gellei B, Erlik D. Prolonged neonatal parathyroid suppression. A sequel to asymptomatic maternal hyperparathyroidism. *Arch Surg*. 1973 May;106(5):722-4. DOI: 10.1001/archsurg.1973.01350170082022
33. Ertel NH, Reiss JS, Spergel G. Hypomagnesemia in neonatal tetany associated with maternal hyperparathyroidism. *N Engl J Med*. 1969 Jan 30;280(5):260-3. DOI: 10.1056/NEJM196901302800508
34. Willi H, Baumann U. Hypoparathyreoidismus beim Kind einer Mutter mit Hyperparathyreoidismus [Hypoparathyroidism in the child of a mother with hyperparathyroidism]. *Arch Kinderheilkd*. 1966 May;174(2):263-73.
35. VanArsdel PP Jr. Maternal hyperparathyroidism as a cause of neonatal tetany: case report and review of 29 cases of parathyroid adenoma. *J Clin Endocrinol Metab*. 1955 Jun;15(6):680-4. DOI: 10.1210/jcem-15-6-680
36. Walton RL. Neonatal tetany in two siblings: effects of maternal hyperparathyroidism. *Pediatrics*. 1954 Mar;13(3):227-34.
37. Hsieh YY, Chang CC, Tsai HD, Yang TC, Chiu TH, Tsai CH. Primary hyperparathyroidism in pregnancy – report of 3 cases. *Arch Gynecol Obstet*. 1998;261(4):209-14. DOI: 10.1007/s004040050223
38. Zeisner W, Stober B, Schmidt-Gayk H. Neonatale Hypocalcämie bei mütterlichem Hyperparathyreoidismus [Neonatal hypocalcemia in hyperparathyroidism of the mother]. *Klin Padiatr*. 1977 Mar;189(2):185-91.
39. Furioli J, Wipff P. Convulsions hypocalcémiques chez deux nouveau-nés d'une même fratrie, révélatrices d'une hyperparathyroïdie maternelle [Hypocalcemic seizures in two newborn siblings revealing hyperparathyroidism in the mother]. *Ann Pediatr (Paris)*. 1990 Sep;37(7):451-3.
40. Nilsson IL, Adner N, Reihné E, Palme-Kilander C, Edstrom G, Degerblad M. Primary hyperparathyroidism in pregnancy: a diagnostic and therapeutic challenge. *J Womens Health (Larchmt)*. 2010 Jun;19(6):1117-21. DOI: 10.1089/jwh.2009.1777
41. Dinçer SI, Demir A, Kara HV, Günlüoğlu MZ. Thoracoscopic removal of a maternal mediastinal ectopic parathyroid adenoma causing neonatal hypocalcemia: a case report. *Ann Thorac Cardiovasc Surg*. 2008 Oct;14(5):325-8.
42. Haynes S. A neonate with persistent twitching. Patient report. *Clin Pediatr (Phila)*. 2007 Jun;46(5):458-9. DOI: 10.1177/0009922806290103
43. Friderichsen C. Hypocalcämie bei einem Brustkind und Hypercalcämie bei der Mutter. *M Schr Kinderheilk*. 1938;75:147-51.
44. Beattie GC, Ravi NR, Lewis M, Williams H, Blair AW, Campbell IW, Browning GG. Rare presentation of maternal primary hyperparathyroidism. *BMJ*. 2000 Jul;321(7255):223-4. DOI: 10.1136/bmj.321.7255.223
45. Thomas AK, McVie R, Levine SN. Disorders of maternal calcium metabolism implicated by abnormal calcium metabolism in the neonate. *Am J Perinatol*. 1999;16(10):515-20. DOI: 10.1055/s-1999-7280
46. Karbowski B, Bock-Steinweg U. Primärer Hyperparathyreoidismus in der Schwangerschaft – ein Fallbericht [Primary hyperparathyroidism in pregnancy – a case report]. *Z Geburtshilfe Neonatol*. 2000 Nov-Dec;204(6):232-5. DOI: 10.1055/s-2000-95840
47. Pragathi LK, Kannan PR, Shanbhag M. An unusual case of neonatal seizures as manifestation of asymptomatic maternal hypoparathyroidism. *BMJ Case Rep*. 2019 Aug 15;12(8):e229160. DOI: 10.1136/bcr-2018-229160

Corresponding author:

Georgios Mitsiakos
2nd Neonatal Department and Neonatal Intensive Care
Unit, Aristotle University of Thessaloniki, "Papageorgiou"
General Hospital of Thessaloniki, Nea Efkarpia Ring Road,
56403 Thessaloniki, Greece
mitsiakos@auth.gr

Please cite as

Mitsiakos G, Katsaras GN, Chatziioannidis I, Gkampeta A, Mitsiakou C, Nikolaidis N. A neonate with late-onset hypocalcemia due to unrecognized maternal hyperparathyroidism and a systematic overview of similar cases. *GMS Ger Med Sci.* 2021;19:Doc09.
DOI: 10.3205/000296, URN: urn:nbn:de:0183-0002964

This article is freely available from

<https://www.egms.de/en/journals/gms/2021-19/000296.shtml>

Received: 2021-03-22

Revised: 2021-06-03

Published: 2021-07-28

Copyright

©2021 Mitsiakos et al. This is an Open Access article distributed under the terms of the Creative Commons Attribution 4.0 License. See license information at <http://creativecommons.org/licenses/by/4.0/>.