



ELSEVIER

Contents lists available at [ScienceDirect](https://www.sciencedirect.com)

Trauma Case Reports

journal homepage: www.elsevier.com/locate/tcr

Case Report

Traumatic obturator foramen hernia. A rare aetiology of a rare condition: A case report

Megan Alderuccio^{a,b,*}, Maria Kristina Vanguardia^{a,b},
Junius Andrew Packiyathan^a, Mark Fitzgerald^b^a Alfred Health Department of General Surgery, Australia^b Alfred Health Department of Trauma, Australia

ARTICLE INFO

Keywords:

Trauma
Trauma laparotomy
Obturator hernia
Abdominal hernia
Hernia

ABSTRACT

Obturator hernias (OH) are rare, accounting for less than 0.05% of all hernias. The aetiology is usually attributed to chronically raised intra-abdominal pressure or cachexia with poor muscle mass. This case report describes a traumatic obturator hernia, an exceptionally rare aetiology of an already rare surgical condition. There are no previous reports of a traumatic obturator hernia in the current literature.

This case reports upon the presentation, operative findings and management of a 48 year old male with abdominal and pelvic trauma following a motor bike collision. Laparotomy findings included a right sided traumatic incarcerated obturator foramen hernia with the comminuted pubic rami fracture trapping and piercing ileum within the hernia. In retrospect, the hernia was visible on CT scan. The hernia was repaired using biological mesh which was covered with adjacent peritoneum.

As with much of trauma surgery, the management of this case required reliance on general principles and real time problem solving to address an issue not previously experienced by the operator, and not previously reported on in the current literature.

Case report

A 48-year-old male was emergently transferred to our trauma centre following a single vehicle motorbike collision at 80 km/h. The patient complained immediately of abdominal and pelvic pain. He was haemodynamically stable and was transferred by air in full spinal precautions and with a pelvic binder in situ. Past medical history included invasive transitional cell carcinoma of the bladder treated two years prior with cystoprostatectomy and ileal conduit. The patient was an active smoker and drinker.

On arrival to our institution, eFAST revealed pelvic free fluid and surgical absence of a bladder. Heart rate and blood pressure remained stable upon removal of the pelvic binder (HR 95, BP 115/85). The abdomen was soft but tender in the lower quadrants, and the pelvis was significantly tender anteriorly and mildly tender posteriorly. Howship-Romberg sign (compression of obturator nerve) was not elicited, however examination of this sign was limited due to distracting injuries.

X-rays and CT scans demonstrated mildly displaced sacral fracture at S5 and comminuted bilateral superior and inferior pubic rami fractures with fracture fragments of the right hemipelvis contacting adjacent small bowel (Fig. 1a). Also evident was moderate volume pelvic free fluid and a single dilated loop of small bowel in the left iliac fossa (Fig. 1b). The previous cystoprostatectomy and ileal

* Corresponding author at: Alfred Hospital, 55 Commercial Road, Melbourne, VIC 3004, Australia.

E-mail address: m.alderuccio@alfred.org.au (M. Alderuccio).

conduit displayed normal contrast opacification with no evidence of injury or perforation. There was no pneumoperitoneum or intramural gas, no active contrast extravasation and no solid organ injury.

Initial pathology revealed a haemoglobin of 141 g/L with haematocrit of 0.41 L/L, neutrophilia of $13.95 \times 10^9/L$, and respiratory acidosis with pH 7.28 and lactate of 1.8 mmol/L.

The pelvic injuries were reviewed by a pelvic orthopaedic surgeon and deemed appropriate for non-operative management with bilateral non-weight bearing restrictions for a six week period.

During the ongoing assessment of the patient during the initial 2 h of admission, serial abdominal examinations by the Trauma and General Surgical teams saw the development of peritonitis.

On the index day of admission, the patient was taken to theatre for an emergency laparoscopy \pm laparotomy by the General Surgical team with involvement from both Urology and Orthopaedic surgeons. Upon laparoscopic entry into the abdomen it was evident that there was enteric soiling and haemoperitoneum and therefore the procedure was converted to laparotomy. Operative findings included a right sided traumatic incarcerated obturator foramen hernia with the comminuted pubic rami fracture trapping and piercing ileum within the hernia (Fig. 2). The right obturator neurovascular bundle was not formally identified. A 15 cm portion of non-viable small bowel containing the perforation was resected and primarily anastomosed with side-to-side stapled anastomosis. A second ileal perforation was identified away from the site of the hernia and this was primarily repaired. With orthopaedic involvement, sharp fracture fragments of the right hemi-pelvis were resected with a bone nibbler to achieve a smooth surface. The hernial defect was plugged with a cylindrical rolled 9 cm \times 15 cm BioA biosynthetic mesh [W.L. Gore & Associates Pty Ltd., Australia] which was then covered with adjacent peritoneum. The patient was commenced on intravenous ceftriaxone and metronidazole and was transferred to the ward for ongoing care.

The patient recovered well with bowels opening on the fifth post-operative day. Haemoglobin down trended to 82 g/L with haematocrit of 0.24 L/L with no associated instability of haemodynamics. It was felt that this was due to a combination of blood loss secondary to initial trauma, minor intra-operative losses and a dilutional effect secondary to administration of intravenous crystalloids. Haemoglobin incremented over the following days back to 95 g/L without the administration of blood products. The initial neutrophilia resolved within 36 h of admission, as did the respiratory acidosis.

On the fifth post-operative day the patient discharged against medical advice. He maintained adherence to bilateral non-weight bearing restrictions, and has planned follow up with all involved surgical teams.

Discussion

Traumatic abdominal wall hernias (TAWH) are a rare but serious complication of blunt abdominal trauma. Although abdominal wall injuries are present in up to 9% of patients following high energy blunt trauma, fascial disruptions with associated hernia are detected in <1% of patients [1]. TAWH are associated with a high incidence of intra-abdominal injury. Almost half of patients (46.8%) with TAWH require urgent laparotomy for management of the hernia, while the remainder of the patients require close clinical and biochemical monitoring to confirm the appropriateness of conservative management [2]. Common locations of TAWH include anteriorly through rectus abdominus, laterally through the oblique muscles or posteriorly through the lumbar triangle [3]. On review of the current literature, there were no reports of traumatic obturator hernias, confirming the exceedingly rare nature of the injuries our patient sustained.

Obturator hernias (OH) are rare, accounting for less than 1% of all hernias [6]. They are caused by herniation of abdominal contents through the fibro-osseous obturator foramen, through which the obturator nerve and vessels traverse from the pelvis to the medial compartment of the thigh [4]. Obturator hernias most commonly occur in elderly females who are emaciated or cachectic, or those with a history of chronically raised intra-abdominal pressure [5]. They are more common on the right, thought to be due to presence of the sigmoid colon obscuring the left obturator foramen [5]. Obturator hernias may present with non-specific abdominal

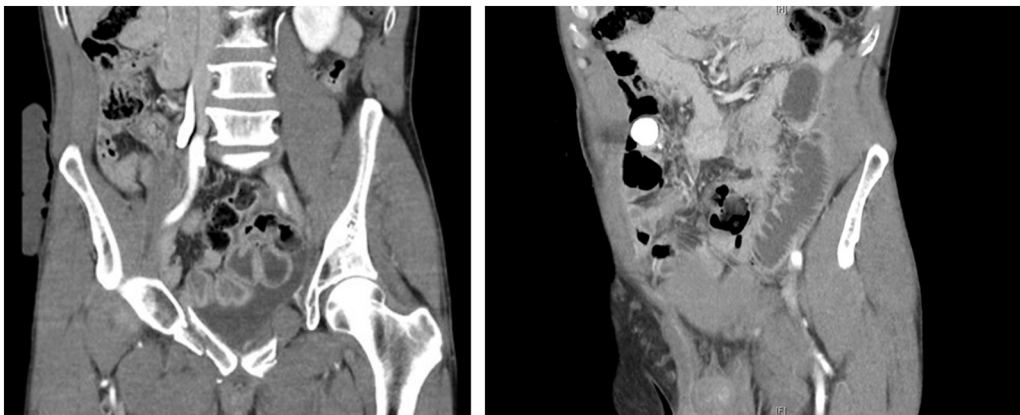


Fig. 1. Coronal slices of CT A/P. A) right hemipelvis fracture fragments contacting adjacent small bowel, moderate volume pelvic free fluid. B) Single dilated loop of small bowel in the left iliac fossa, measuring up to 34 mm.

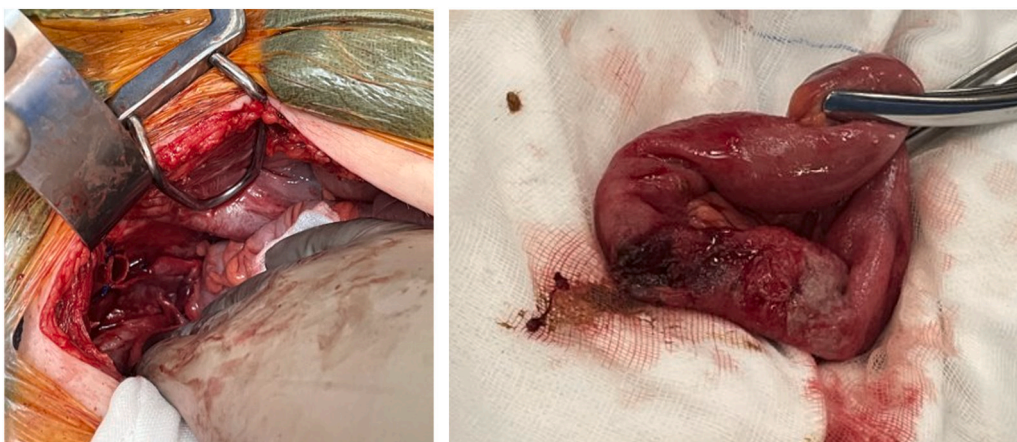


Fig. 2. A) Intra-operative image of the right hemipelvis fracture fragments trapping a loop of ileum within the right obturator foramen. B) Resected portion of ileum containing perforation secondary to pelvic fracture fragments.

pain, symptoms of bowel obstruction, or compression of the obturator nerve (Howship-Romberg sign) [6]. The mortality associated with OH is high, with reports ranging from 12 to 70% for strangulated OH [7]. This high mortality rate has been attributed to the advanced age and medical comorbidities of the patients it most commonly affects [6]. Obturator hernias repaired in the elective setting are repaired with the use of mesh, whilst those repaired in the emergent setting are most commonly repaired without mesh to reduce the risk of mesh infection [5].

This was a challenging case, requiring innovative methods of repair. The two competing factors of a large hernial defect and presence of enteric soiling made for complex surgical decision making. The comminuted pelvic fractures saw a large defect formed in the obturator membrane and altered adjacent bony anatomy. This alteration of anatomy eliminated primary repair as a viable surgical option, as this posed an unacceptably high risk of hernia recurrence. In an effort to avoid the use of surgical mesh in a contaminated surgical field, an attempt was made to cover the defect using peritoneum, however due to the patients past history of cystoprostatectomy, complete mobilisation of the peritoneum for use as a flap or plug was not possible. As mentioned previously, the hernial defect was plugged with a rolled BioA mesh, which was subsequently covered with adjacent peritoneum. Biological mesh, along with a course of antibiotics, was used in order to mitigate the risk of mesh infection.

This case describes an exceptionally rare aetiology of an already rare surgical condition. As with much of trauma surgery, the management of this case required reliance on general principles and real time problem solving to address an issue not previously experienced by the operator, and not previously reported on in the current literature. The methodical consideration of closure options and the involvement of Orthopaedic surgical colleagues resulted in the best possible outcome for our patient. When the patient was contacted five months post injury for consent for this report, he remained asymptomatic from an obturator hernia point of view.

Consent

Informed consent was provided by the subject for the release of this de-identified written information and photographs.

Declaration of competing interest

The views expressed and submitted are those of the authors and not an official position of the institution in which they are employed.

The authors declare that there is no conflict of interest.

References

- [1] K.L. Chow, E.C. Omi, J. Santaniello, et al., Traumatic abdominal wall hernias: a single-center case series of surgical management, *Trauma Surg. Acute Care Open* 5 (1) (2020), e000495, <https://doi.org/10.1136/tsaco-2020-000495>. Published 2020 Dec 1.
- [2] A. Omar, G. Laurent, L. Antoinette, M. Olivier, Traumatic abdominal wall hernia-a series of 12 patients and a review of the literature, *World J. Surg.* 45 (9) (2021) 2742–2746, <https://doi.org/10.1007/s00268-021-06177-2>.
- [3] J.J. Coleman, E.K. Fitz, B.L. Zarzaur, et al., Traumatic abdominal wall hernias: location matters, *J. Trauma Acute Care Surg.* 80 (3) (2016) 390–397, <https://doi.org/10.1097/TA.0000000000000946>.
- [4] C.D. Strange, K.L. Birkemeier, S.T. Sinclair, et al., Atypical abdominal hernias in the emergency department: acute and non-acute, *Emerg. Radiol.* 16 (2009) 121–128, <https://doi.org/10.1007/s10140-008-0753-y>.

- [5] Z. Li, C. Gu, M. Wei, X. Yuan, Z. Wang, Diagnosis and treatment of obturator hernia: retrospective analysis of 86 clinical cases at a single institution, *BMC Surg.* 21 (1) (2021 Mar 9) 124, <https://doi.org/10.1186/s12893-021-01125-2>.
- [6] J. Park, Obturator hernia: clinical analysis of 11 patients and review of the literature, *Medicine (Baltimore)* 99 (34) (2020 Aug 21), e21701, <https://doi.org/10.1097/MD.00000000000021701>.
- [7] K.V. Chan, C.K. Chan, K.W. Yau, M.T. Cheung, Surgical morbidity and mortality in obturator hernia: a 10-year retrospective risk factor evaluation, *Hernia* 18 (3) (2014) 387–392.