

Infrared thermography in the diagnosis and management of vasculitis

Peter H. Lin, MD,^{a,b} Angela Echeverria, MD,^a and Mun J. Poi, MD,^a *Houston, Tex; and Los Angeles, Calif*

ABSTRACT

Vasculitis is a clinical condition with associated diagnostic challenges due to nonspecific symptoms and lack of a confirmatory imaging modality. We report a case of a 39-year-old female patient who developed generalized malaise, lethargy, and headache. Laboratory evaluation showed elevated inflammatory markers. Conventional imaging studies including computed tomography and carotid duplex ultrasound were unremarkable. Infrared thermography revealed enhanced thermographic signals in the left carotid artery and aortic arch. Corticosteroid therapy was commenced, and the patient responded well. Follow-up infrared thermography at 6 months showed complete resolution of the thermographic pattern, and the patient remained symptom free. (*J Vasc Surg Cases and Innovative Techniques* 2017;3:112-4.)

Takayasu arteritis is a vasculitis primarily affecting the aorta and its branches. The thoracic aorta and its branches, including the carotid artery and subclavian arteries, are often affected. Diagnosis of this condition can be difficult and is frequently delayed in part because of the nonspecific symptoms associated with the disease, such as malaise, fever, and weight loss. We herein report the case of a patient with Takayasu arteritis whose diagnosis was facilitated by an infrared thermographic evaluation. This imaging modality was useful in follow-up surveillance evaluation on the completion of medical treatment. Informed consent was obtained for the publication of this report.

CASE REPORT

A 38-year-old female patient reported a 6-month history of lethargy, headache, left-sided neck pain, left shoulder pain, and intermittent fever. She was a current smoker with a 10 pack-year history. She had no significant past medical history, and her physical examination was unremarkable. Initial laboratory investigations were unremarkable, except for an elevated erythrocyte sedimentation rate of 120 mm/h (normal range, <40), C-reactive protein level of 78 mg/L (normal range, 0-10), and serum amyloid A level of 706 mg/L (normal range, 0-6). Her urinalysis was unremarkable, and results of relevant infection and immunology screens were negative. Serum immunoglobulins including immunoglobulin G4 were all within normal limits. A temporal artery biopsy revealed no evidence of giant cell arteritis. Her carotid

duplex ultrasound showed no hemodynamically significant stenosis. A computed tomography (CT) scan of the chest with contrast enhancement similarly revealed no gross abnormalities. With no radiographic evidence of vascular disease, dynamic infrared thermography (FLIR E8 with 320 × 240 infrared resolution; FLIR Systems, Inc, Wilsonville, Ore) was performed, which showed increased thermal retention in her left carotid artery and thoracic aorta (Fig 1). To standardize the imaging technique, we maintained the room temperature at 71°F to 73°F when thermal images were taken. Efforts were made to avoid taking thermal images adjacent to a source that emits heat energy, such as a window, heating vent, lamp, or computer. A distance of 2 feet between the thermal camera and the patient's neck was maintained in all thermal imaging evaluations.

On the basis of her serologic and thermographic findings, she was diagnosed with Takayasu arteritis. Prednisone was commenced at a dose of 60 mg daily (or 1 mg/kg), gradually, reduced to 10 mg daily during a period of 12 weeks and then to a maintenance dose of 5 mg daily after an additional period of 12 weeks. Her erythrocyte sedimentation rate decreased to the level of 5 mm/h within 4 weeks after the steroid therapy. She showed rapid improvement in her symptoms 1 week after the initiation of the steroid regimen. The patient has been stable for 1 year. At that point, she was considered to be in established clinical disease remission. Follow-up infrared thermography was performed, which showed complete resolution of vascular changes seen previously (Fig 2). She remains well and free of symptoms at follow-up 18 months after the initial symptoms.

DISCUSSION

Takayasu arteritis, along with myriad other vasculitis conditions, often poses a diagnostic challenge to clinicians because the patient frequently presents with nonspecific symptoms, such as malaise, fever, lethargy, and weight loss. Furthermore, the lack of a definitive imaging modality or confirmatory serologic test often leads to misdiagnosis and treatment delay in these patients. This report represents the first case of use of infrared thermography technology in assessing body regions potentially affected by vasculitis by detecting elevated thermal signals. Furthermore, this imaging

From the Division of Vascular Surgery and Endovascular Therapy, Michael E. DeBakey Department of Surgery, Baylor College of Medicine, Houston^a; and the University Vascular Associates, Los Angeles.^b

Author conflict of interest: none.

Correspondence: Peter H. Lin, MD, Professor Emeritus of Surgery, Michael E. DeBakey Department of Surgery, Baylor College of Medicine, One Baylor Plaza, Houston, TX 77030 (e-mail: plin@bcm.edu).

The editors and reviewers of this article have no relevant financial relationships to disclose per the Journal policy that requires reviewers to decline review of any manuscript for which they may have a conflict of interest.

2468-4287

© 2017 The Authors. Published by Elsevier Inc. on behalf of Society for Vascular Surgery. This is an open access article under the CC BY-NC-ND license (<http://creativecommons.org/licenses/by-nc-nd/4.0/>).

<http://dx.doi.org/10.1016/j.jvscit.2016.12.002>

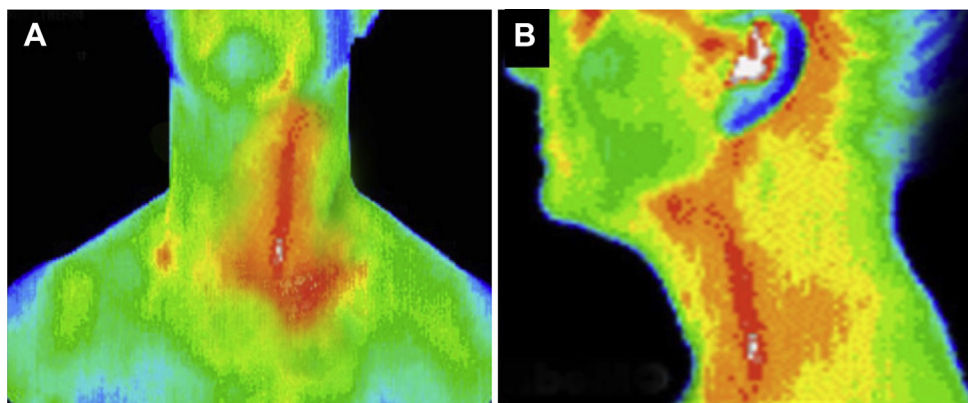


Fig 1. Infrared thermography demonstrated enhanced thermal signals in the aortic arch and left carotid artery in anteroposterior (A) and lateral (B) views of our patient with Takayasu arteritis.

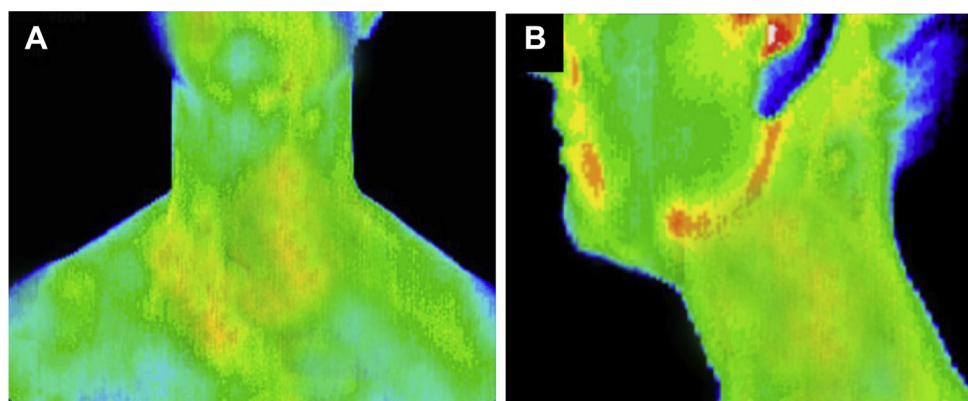


Fig 2. Surveillance infrared thermography after corticosteroid treatment at 6 months demonstrated resolution of thermal pattern in anteroposterior (A) and lateral (B) views.

modality can provide follow-up surveillance information to determine the treatment response.

First developed in 1929 by a Hungarian physicist, Kálmán Tihanyi, an infrared thermographic camera was used to detect heat signals in the form of infrared radiation.¹ The application of this technology in medicine has expanded greatly in recent years. Researchers have applied this imaging modality to facilitate the diagnosis of conditions associated with increased infrared thermal characteristics due to an inflammatory process or enhanced vascularity, such as neoplasm or infection.^{1,2} Clinical reports have highlighted the clinical utility of infrared thermography as a breast cancer screening tool.^{2,3} Zadeh et al recently examined 60 patients thought to have breast disease using an infrared thermographic camera. These authors found that this imaging modality was not only effective in determining breast mass location but also highly accurate in identifying hypoechoic lesions, cystic masses, and heterogeneous lesions including fibroadenomas and intraductal masses.³ Researchers have recently lauded the diagnostic benefit of infrared thermography in differentiating melanomas from benign cutaneous pigmented lesions

on the basis of their particular infrared thermographic signals.⁴ The application of this technology in detecting vascular tumors, including cutaneous hemangiomas and other vascular malformations, before and after treatment with cryotherapy or laser therapy has been reported.⁵ Similarly, this technology has been found to be useful in mapping and characterizing perforators for preoperative assessment as well as for postoperative monitoring of muscle flap reconstruction.² In patients with burn injuries, differentiating between superficial dermal and deep dermal burns can be challenging because of the inability to visualize depth of thermal injury. This differentiation is critical because superficial dermal burns can be treated conservatively, whereas deep dermal burns frequently require excision and skin grafting. Singer et al highlighted the diagnostic accuracy using infrared thermal imaging in 30 burn patients in predicting burn depth as this imaging modality facilitated the treatment decision and potentially reduced unnecessary skin grafting in burn patients.⁶

Blackmur et al recently reported the use of an ¹⁸F-fluorodeoxyglucose positron emission tomography (¹⁸F-FDG-PET) CT scan in the diagnosis and

treatment of a patient with aortitis.⁷ Neumann and associates similarly reported the utility of this imaging technique to diagnose large-vessel aortitis for which conventional CT scan and magnetic imaging had proved inconclusive.⁸ Whereas the ¹⁸F-FDG-PET CT scan may prove to be sensitive in demonstrating ¹⁸F-FDG uptake in the wall of the thoracic and abdominal aorta where chronic inflammation is present, this technology requires highly sophisticated imaging equipment with radioactive tracer administration as well as trained personnel to perform the imaging evaluation. The adaptation of this imaging modality by clinicians or hospitals in general may prove to be challenging because of cost considerations. In contrast, the ubiquitous proliferation of smartphones has led to the development of a cell phone-mounted infrared thermographic camera. Hardwicke et al recently reported their experiences of using a smartphone-mounted thermographic camera in evaluating perforators for cutaneous blood flow in patients undergoing free flap reconstruction.⁹ A recent report by Kanazawa et al demonstrated the clinical benefit of using smartphone-attached mobile thermography at the bedside in assessing subclinical inflammation in patients with diabetic foot ulcers.¹⁰ We have recently reported our clinical experience of using a smartphone-mounted infrared thermographic camera in assessing tissue perfusion after either surgical or endovascular lower extremity revascularization in eight patients.¹¹ We found that this technology is easy to use and highly cost-effective as an adjunctive imaging tool in the care of vascular patients.

CONCLUSIONS

Our case highlights the potential clinical utility of using infrared thermography in patients with vasculitis. The enhanced thermal signals in the aortic arch and carotid artery provided valuable information in the diagnosis and treatment of arteritis in our patient. This technology was similarly beneficial in subsequent surveillance

evaluation once the patient completed the prescribed treatment. Further studies are warranted to determine the clinical sensitivity and diagnostic accuracy of this imaging modality in vasculitis.

REFERENCES

1. Ring EF, Ammer K. Infrared thermal imaging in medicine. *Physiol Meas* 2012;33:R33-46.
2. John HE, Niumsawatt V, Rozen WM, Whitaker IS. Clinical applications of dynamic infrared thermography in plastic surgery: a systematic review. *Gland Surg* 2016;5:122-32.
3. Zadeh HG, Haddadnia J, Ahmadinejad N, Baghdadi MR. Assessing the potential of thermal imaging in recognition of breast cancer. *Asian Pac J Cancer Prev* 2015;16:8619-23.
4. Herman C. Emerging technologies for the detection of melanoma: achieving better outcomes. *Clin Cosmet Investig Dermatol* 2012;5:195-212.
5. Saxena AK, Willital GH. Infrared thermography: experience from a decade of pediatric imaging. *Eur J Pediatr* 2008;167:757-64.
6. Singer AJ, Relan P, Beto L, Jones-Koliski L, Sandoval S, Clark RA. Infrared thermal imaging has the potential to reduce unnecessary surgery and delays to necessary surgery in burn patients. *J Burn Care Res* 2015;37:350-5.
7. Blackmur JP, Patel D, Kluth DC, Dhaun N. Utility of ¹⁸F-fluorodeoxyglucose positron emission tomography computed tomography in the diagnosis and management of aortitis. *Circulation* 2015;132:1937-8.
8. Neumann T, Oelzner P, Freesmeyer M, Hansch A, Opfermann T, Hein G, et al. Images in cardiovascular medicine. Diagnosis of large-vessel vasculitis by [¹⁸F] fluorodeoxyglucose-positron emission tomography. *Circulation* 2009;119:338-9.
9. Hardwicke JT, Osmani O, Skillman JM. Detection of perforators using smartphone thermal imaging. *Plast Reconstr Surg* 2016;137:39-41.
10. Kanazawa T, Nakagami G, Goto T, Noguchi H, Oe M, Miyagaki T, et al. Use of smartphone attached mobile thermography assessing subclinical inflammation: a pilot study. *J Wound Care* 2016;25:177-82.
11. Lin PH, Saines M. Assessment of lower extremity ischemia using smartphone thermographic imaging. *J Vasc Surg Cases and Innovative Techniques* 2017; in press.

Submitted Jun 5, 2016; accepted Dec 13, 2016.