

Case Report

Botryomycosis in a lung cavity

D Vinay, V Ramasubramanian, Ram Gopalakrishnan, Laxman G Jessani

Institute of Infectious Diseases, Apollo Main Hospital, Chennai, Tamil Nadu, India

ABSTRACT

Botryomycosis is a rare pyogranulomatous disease characterized by suppurative and often granulomatous bacterial infection of the skin, soft tissues and viscera. Only about 90 cases have been reported in world literature till date: 75% of them are cases of cutaneous botryomycosis. Of the 18 reported cases of primary pulmonary botryomycosis, only one had histologically proven botryomycosis in a lung cavity. We report here a case of primary pulmonary botryomycosis occurring in a lung cavity, which is to the best of our knowledge first such case from India. The index case was a 62 year old female who presented to us with recurrent episodes of non-massive streaky hemoptysis with CT chest revealing 'Air Crescent' sign with a probable fungal ball in a left upper lobe cavity. Left upper pulmonary lobectomy was done and histopathology of the cavitary tissue revealed Splendore-Hoeppli phenomenon and features suggestive of Botryomycosis. Tissue culture from the cavitary specimen grew *Pseudomonas aeruginosa*. Botryomycosis can mimic Aspergilloma radiologically as was seen in our case, but therapy is often a combination of both medical and surgical measures unlike Aspergilloma.

KEY WORDS: Botryomycosis, hemoptysis, lung cavity, *Pseudomonas aeruginosa*, pyogranulomatous, Splendore-Hoeppli phenomenon

Address for correspondence: Dr. D Vinay, Apollo Institute of Infectious Diseases, Apollo Main Hospital, Chennai - 600 006, Tamil Nadu, India.
E-mail: vinaydevraj36@gmail.com

INTRODUCTION

Botryomycosis is a rare chronic, pyogranulomatous disorder primarily involving the skin. It less commonly involves the soft tissues and viscera.^[1] It is a disease characterized by suppurative and often granulomatous bacterial infection of the skin, soft tissues, and viscera with aggregates of nonbranching Gram-positive organisms or Gram-negative *Bacilli* surrounded by eosinophilic material.^[1,2] Botryomycosis as a disease entity was recognized as early as 1870.^[3] The first reported human case was in 1913, after which about 90 cases have been reported till date: 75% of them are cases of cutaneous botryomycosis.^[4] Of the 18 reported cases of primary pulmonary botryomycosis, only one had histologically proven botryomycosis in a lung cavity.^[4] We report here a case of primary pulmonary botryomycosis occurring in a lung cavity, which is to the best of our knowledge first such case from India.

CASE REPORT

The index case was a 62-year-old female from Indore, Madhya Pradesh, India, with no significant comorbid illness except for well-controlled bronchial asthma of 25 years. She presented to us in May 2014 with history of recurrent episodes of nonmassive streaky hemoptysis since 2010. She had such episodes of hemoptysis manifesting every 6–8 months, lasting for 10–14 days and subsiding each time with a week to 10 day course of ciprofloxacin prescribed by her physician. She had no fever or respiratory distress. There was no history of loss of weight or appetite.

She was evaluated for these complaints in 2011 at AIIMS, New Delhi. Chest radiograph done at AIIMS revealed presence of "Air Crescent" sign suggestive of a fungal ball inside a lung cavity in the left upper lobe. Serum and bronchoalveolar lavage (BAL) galactomannan were not in

This is an open access article distributed under the terms of the Creative Commons Attribution-NonCommercial-ShareAlike 3.0 License, which allows others to remix, tweak, and build upon the work non-commercially, as long as the author is credited and the new creations are licensed under the identical terms.

For reprints contact: reprints@medknow.com

How to cite this article: Vinay D, Ramasubramanian V, Gopalakrishnan R, Jessani LG. Botryomycosis in a lung cavity. *Lung India* 2016;33:540-2.

| Access this article online | |
|--|---|
| Quick Response Code:  | Website: www.lungindia.com |
| | DOI: 10.4103/0970-2113.188977 |

detectable range. Sputum and BAL analysis did not yield any acid-fast *Bacilli*. Her serum immunoglobulin E (IgE) titer was 100, and *Aspergillus*-specific IgE was not detectable. Left upper lobectomy was planned, but the patient was not willing for any procedure and was discharged on request. She continued to have such symptoms every 6–8 months and was treated by her physician with ciprofloxacin.

She approached our cardiovascular surgery unit in May 2014 with persistent but increasing frequency of symptoms. Computed tomography scan of the chest confirmed the presence of a lung cavity in the left upper lobe with an organized mass within the cavity suspicious of a fungal ball [Figure 1].

Her renal and liver functions were within normal range, erythrocyte sedimentation rate (ESR) was 64, and HIV ELISA was nonreactive. With the working diagnosis of aspergilloma with manifest troublesome hemoptysis, left upper pulmonary lobectomy was done, and the excised tissue and lung cavity was sent for histopathological analysis. Histopathology of the cavitory tissue revealed lung parenchyma with cavity lined by necrotic material surrounded by neutrophils, lymphocytes, plasma cells, and histiocytes with presence of sulfur granules with Splendore-Hoeppli phenomenon in the cavitory lining [Figure 2]. No breach or invasion of respiratory lining was noted, ruling out invasive aspergillosis. Gram-stain was equivocal, but silver stain for fungi was negative. No acid-fast *Bacilli* were detectable. Charcot-Leyden crystals were seen in abundance and a final impression of botryomycosis was made.

Tissue culture from the cavitory specimen revealed heavy growth of pan-sensitive *Pseudomonas aeruginosa* [Figure 3]. During postsurgery, she was asymptomatic and hence was not started on any specific antibiotic therapy. She had a week-long asymptomatic postoperative stay in the hospital and was discharged.

DISCUSSION

Botryomycosis is a rare chronic, suppurative granulomatous disorder involving the skin, soft tissues, and viscera.^[1] Bollinger reported this case initially in castrated horses in 1870 and in 1884, Rivolta gave the term “Botryomycosis.”^[3,5] The prefix “botrys” is a Greek word that means bunch of grapes, and the suffix “mycosis” means fungus, originally implying a fungal source. The first reported human case was in 1913.^[6] Botryomycosis in humans manifests in two forms: Cutaneous and visceral. The cutaneous disease accounts for 75% of cases, and visceral disease is seen mainly in patients with some underlying disease. Involved organs include liver, kidneys, brain, prostate, lungs, orbit, tongue, ears, intestines, and trachea.^[7,8]

Eighteen cases of primary pulmonary botryomycosis have been reported in literature till date.^[4,7-13] The age range was 9 months to 68 years, with 10 males and 8 females. Three of 8 adult patients were long-term smokers.

Fifteen of 18 patients had an underlying disease: Cystic fibrosis in 8 patients, diabetes mellitus in 3 patients, and 1 patient each had AIDS, chronic granulomatous disease, asthma (receiving inhaled corticosteroids) and pulmonary sequestration.^[4,7-13] Four of 8 adult patients presented with hemoptysis, and 3 of 8 adult patients presented with weight loss. Young patients with cystic fibrosis presented with varied symptoms that generally were not distinguishable from those of the underlying disease. Diagnosis of infection in 4 of 8 adult patients

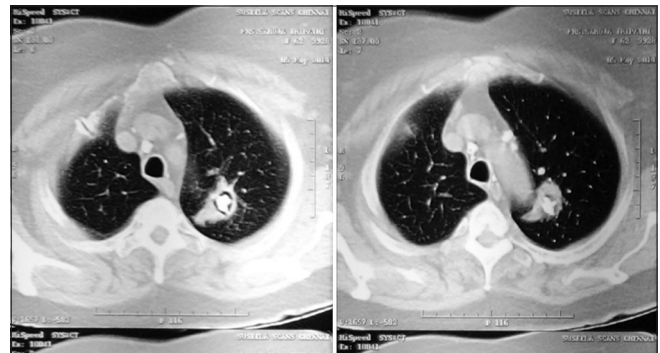


Figure 1: Left upper zone cavity with air crescent sign

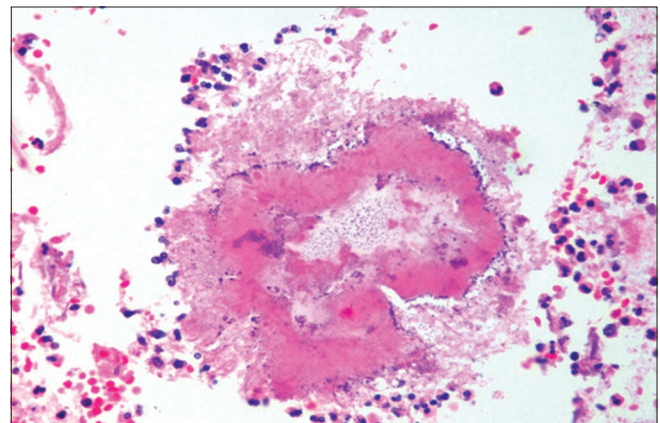


Figure 2: Splendore-Hoeppli phenomenon

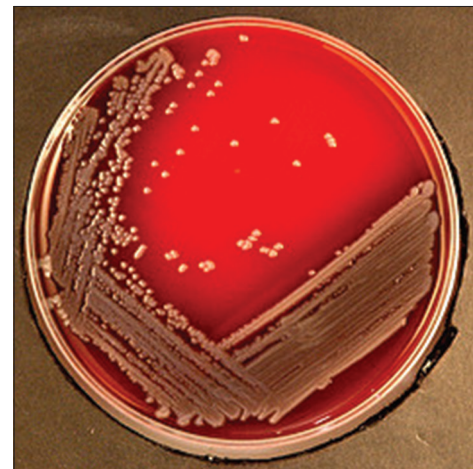


Figure 3: *Pseudomonas* growth on blood agar

was achieved by review of a Gram-stained specimen, and cultured specimens from four patients grew specific bacteria. Most patients responded favorably to antibiotic treatment that was given for a minimum of 2 weeks and a maximum of 6 months. Six of 8 adult patients had surgical treatment in addition to antibiotic therapy.^[4,7-13]

The pathogenesis of botryomycosis is unclear as of yet. Local trauma, impacted foreign body, greater size of bacterial inoculum and organisms of low virulence may influence the onset of disease.^[7,14] These factors coupled with host factors such as alcoholism, diabetes mellitus, cystic fibrosis, malnutrition, immunosuppressive therapy, and HIV-AIDS may contribute to and promote the development of this disease in a susceptible host.^[7,14] These factors appear to lead to a state of equilibrium between the host and the infecting agent. Histologically, this leads to granulation tissue formation, newly formed capillaries, epithelial cells, giant cells, and micro-abscesses composed of neutrophils as well as the typical granules. The most characteristic feature of the disease is that the bacteria, instead of spreading throughout the infected tissue, group together to form conglomerates resembling the sulfuric granules of *Actinomyces*.^[2]

Though *Staphylococcus aureus* is the most common causative agent, numerous other organisms have been isolated in conjunction with histological findings of botryomycosis. These include *Pseudomonas aeruginosa*, *Escherichia coli*, α -hemolytic *Streptococcus*, *Actinobacillus lignieresii*, *Moraxella nonliquefaciens*, *Serratia marcescens*, *Peptostreptococcus*, *Fusobacterium*, and *Burkholderia cepacia*.^[13-15]

Although the Splendore-Hoeppli phenomenon is a characteristic histologic finding in actinomycosis, it is also seen in fungal infections including sporotrichosis, pityriasis, zygomycosis, candidiasis, aspergillosis, and blastomycosis, bacterial infections including nocardiosis and parasitic conditions including orbital pythiosis, strongyloidiasis, schistosomiasis, and cutaneous larva migrans. In addition, Splendore-Hoeppli reaction may be seen with noninfective pathologies such as hypereosinophilic syndrome and allergic conjunctival granulomas.^[2]

No specific guidelines exist as to what is the definitive therapy for pulmonary botryomycosis. Most of the cases in literature benefited from combined surgical and medical management and antibiotics in most cases were guided by specific culture and sensitivities.^[7-13,15-17]

Our index case had none of the classic predisposing factors for botryomycosis. Lung cavity in her presumably may have been an asymptomatic mycobacterial infection due to previous exposure. Botryomycosis in a lung cavity, as mentioned earlier is a rare occurrence, and our case is

second only to be reported to the best of our knowledge. Clinical responsiveness to ciprofloxacin each time may be a reflection of drug sensitive nature of *Pseudomonas* isolated from tissue culture.

Since uniform guidelines are lacking as to when to initiate and how long to continue antibiotics, we did not start antibiotics as source reduction was done already in the form of lobectomy and patient had improved clinically.

We present this case to create more awareness among physicians about this uncommon but important and treatable disease entity which histologically and sometimes radiologically may mimic more morbid illnesses such as actinomycosis and malignancy. Stress is to be laid on isolation of organisms on culture to have an unbiased diagnosis of botryomycosis.

Financial support and sponsorship

Nil.

Conflicts of interest

There are no conflicts of interest.

REFERENCES

- Winslow DJ. Botryomycosis. Am J Pathol 1959;35:153-67.
- Johnson FB. Splendore-Hoeppli phenomenon. In: Bindford CH, Connor DH, editors. Pathology of Tropical and Extraordinary Diseases. Washington, DC: Armed Forces Institute of Pathology; 1976. p. 681-3.
- Bollinger O, Modlich F. Mycosis of Lung in Horses. Virchows Arch Pathol Anat 1870;49:583-6.
- Heyndrickx M, Galateau-Salle F, Herry I, Icard P. Pulmonary botryomycosis on a lung cavity: A rare pulmonary infection mimicking cancer. Gen Thorac Cardiovasc Surg 2012;60:607-9.
- Rivolta S. Mycelium and ascomycetes of varieties of species of pathogenic fungi. J Anat Physiol Pathol Animals 1884;16:181-98.
- Opie EL. Human botryomycosis of the liver. Arch Intern Med 1913;2:425-39.
- Katapadi K, Pujol F, Vuletin JC, Katapadi M, Pachter BR. Pulmonary botryomycosis in a patient with AIDS. Chest 1996;109:276-8.
- Shih JY, Hsueh PR, Chang YL, Lee LN, Chen YC, Chen MF, et al. Tracheal botryomycosis in a patient with tracheopathia osteochondroplastica. Thorax 1998;53:73-5.
- Multz AS, Cohen R, Azeuta V. Bacterial pseudomycosis: A rare cause of haemoptysis. Eur Respir J 1994;7:1712-3.
- Katznellen D, Vawter GF, Foley GE, Shwachman H. Botryomycosis, a complication cystic fibrosis. Report of 7 cases. J Pediatr 1964;65:525-39.
- Speir WA Jr., Mitchener JW, Galloway RF. Primary pulmonary botryomycosis. Chest 1971;60:92-3.
- Paz HL, Little BJ, Ball WC Jr., Winkelstein JA. Primary pulmonary botryomycosis: A manifestation of chronic granulomatous disease. Chest 1992;101:1160-2.
- Bersoff-Matcha SJ, Roper CC, Liapis H, Little JR. Primary pulmonary botryomycosis: Case report and review. Clin Infect Dis 1998;26:620-4.
- McGinnis MR, Fader RC. Mycetoma: A contemporary concept. Infect Dis Clin North Am 1988;2:939-54.
- Murray PR, Baron EJ, Pfaller MA, Tenoer FC, Tenover RH, editors. Manual of clinical microbiology. 7th ed. Washington DC; 1999. p. 283-96.
- Saadat P, Ram R, Sohrabian S, Vadmal MS. Botryomycosis caused by *Staphylococcus aureus* and *Pneumocystis carinii* in a patient with acquired immunodeficiency disease. Clin Exp Dermatol 2008;33:266-9.
- Tuggey JM, Hosker HS, Da Costa P. Primary pulmonary botryomycosis: A late complication of foreign body aspiration. Thorax 2000;55:1068-9.