








Diffuse Sclerosing Variant of Papillary Thyroid Carcinoma in a Child: A Case Report

소아의 미만성 경화 변종 갑상선 유두암: 증례 보고

Seung Hee Byun, MD¹ , Sun Kyoung You, MD^{1,2*} , Seong Su Kang, MD¹ ,
 Kyung Sook Shin, MD^{1,2} , Jeong Eun Lee, MD^{1,2} 

¹Department of Radiology, Chungnam National University Hospital, Daejeon, Korea

²Department of Radiology, Chungnam National University College of Medicine, Daejeon, Korea

The diffuse sclerosing variant of papillary thyroid carcinoma (DSPTC) is uncommon. Herein, we report a rare case of DSPTC in a 9-year-old girl who initially presented with a painless diffuse goiter. Thyroid peroxidase antibody testing yielded positive results, and the initial clinical diagnosis was Hashimoto's thyroiditis. However, thyroid ultrasonography revealed characteristic findings of DSPTC, which was confirmed through the postoperative histopathological diagnosis. Although thyroid cancers are rare in the pediatric population, DSPTC should be included in the differential diagnosis of goiter in these patients. Moreover, ultrasonography may prevent a diagnostic delay and facilitate the detection of a concomitant malignancy.

Index terms Papillary Thyroid Carcinoma; Children; Ultrasonography; Hashimoto Thyroiditis

INTRODUCTION

The diffuse sclerosing variant of papillary thyroid carcinoma (DSPTC), which was initially described by Crile and Fisher in 1953 (1), is an uncommon variant with an unfavorable prognosis. DSPTC is characterized by diffuse involvement of one or both thyroid lobes and is diagnostically similar to Hashimoto's thyroiditis (HT). Also, it is important in that of clinical diagnostic similarity with HT. Several reports have suggested a positive correlation between papillary thyroid carcinoma and HT in adults (2). However, only a few studies have explored this topic in children and adolescents, and none have suggested definitive evidence of a positive association between these disease entities (3). Notably, although DSPTC was the most prevalent subtype in retrospective studies of patients aged < 20 years who were diagnosed with papillary thyroid carcinoma,

Received April 4, 2019
 Revised September 7, 2019
 Accepted January 1, 2020

*Corresponding author
 Sun Kyoung You, MD
 Department of Radiology,
 Chungnam National University
 Hospital, 282 Munhwa-ro,
 Jung-gu, Daejeon 35015, Korea.
 Tel 82-42-220-8108
 Fax 82-42-253-0061
 E-mail sunkyou@cnuh.co.kr

This is an Open Access article distributed under the terms of the Creative Commons Attribution Non-Commercial License (<https://creativecommons.org/licenses/by-nc/4.0>) which permits unrestricted non-commercial use, distribution, and reproduction in any medium, provided the original work is properly cited.

ORCID iDs

Seung Hee Byun 
<https://orcid.org/0000-0002-8140-9400>
 Sun Kyoung You 
<https://orcid.org/0000-0002-1026-5809>
 Seong Su Kang 
<https://orcid.org/0000-0003-0278-7372>
 Kyung Sook Shin 
<https://orcid.org/0000-0002-5872-0831>
 Jeong Eun Lee 
<https://orcid.org/0000-0001-9566-7489>

except classical papillary carcinoma (4), it is rare in children aged younger than 10 years, and increase in frequency with age, with 70% of cases presenting between the ages of 11 and 17 years (5).

Here, we report a case of DSPTC in a 9-year-old girl who initially presented with a painless diffuse goiter and exhibited positivity for thyroid peroxidase antibodies. Although the patient was initially suspected to have HT, the final histopathological diagnosis was DSPTC with HT.

This aim of study is to describe the imaging finding of DSPTC mimicking HT that may potentially aid in the differentiation of DSPTC from HT and discuss clinical evaluation and diagnosis.

CASE REPORT

A 9-year-old girl visited our hospital with painless but progressively increasing swelling of the anterior neck over a period of 10 months. A physical examination revealed a firm diffuse goiter. She did not present with palpitations or tremors, and had not experienced any change in body weight or appetite. Thyroid function tests yielded values within the normal ranges for free thyroxine (1.43 ng/dL; normal: 0.7–1.9 ng/dL), triiodothyronine (1.32 ng/mL; normal: 0.6–1.9 ng/mL), and thyroid stimulating hormone (2.65 uIU/mL; normal: 0.25–4.0 uIU/mL). However, the patient was positive for anti-thyroglobulin antibody (8196 U/mL; normal: 0–30.0 U/mL) and thyroid peroxidase antibodies (29067 U/mL; normal: 0–8 U/mL). Tc-99m pertechnetate thyroid scintigraphy thyroiditis revealed uneven tracer uptake in both thyroid lobes, suggesting chronic thyroiditis. Hence, she received an initial clinical diagnosis of suspected HT. subsequent ultrasonography (iU 22 Unit, Philips Healthcare, Bothell, WA, USA) revealed a hypoechoic enlarged thyroid gland with diffusely heterogeneous parenchyma, particularly in the right lobe, with no dominant mass (Fig. 1A, B). Color Doppler ultrasound showed diffusely increased vascularity throughout the parenchyma (Fig. 1C). Initially, the thyroid parenchyma appeared to be consistent with a diffuse thyroid disease, such as HT. However, multiple scattered microcalcifications with no associated mass were observed in both lobes (Fig. 1A, B). Furthermore, enlarged lymph nodes at level II in the right neck contained multiple microcalcifications that were suspicious for metastatic disease (Fig. 1D). Consequently, the patient underwent fine needle aspiration biopsy of mid-portion of the right thyroid lobe and an adjacent level II lymph node in the right neck, which indicated papillary thyroid carcinoma and a metastatic lymph node. Consequently, the patient underwent a total thyroidectomy with bilateral modified radical neck dissection. A postoperative histological analysis revealed numerous scattered small papillary carcinomas within the dilated lymphovascular channel in both lobes of the thyroid gland, along with squamous metaplasia and innumerable psammoma bodies. The final histopathological diagnosis was bilateral DSPTC with multiple lymph node metastases at level II in the right neck and level VI bilaterally.

The patient underwent I-131 radioablation at dose of 30 mCi. One week later, I-131 whole body scintigraphy revealed no abnormal I-131 uptake in the whole body. During a 1-year follow-up ultrasonography and serum thyroglobulin evaluation, we observed no evidence of recurrence or distant metastasis.

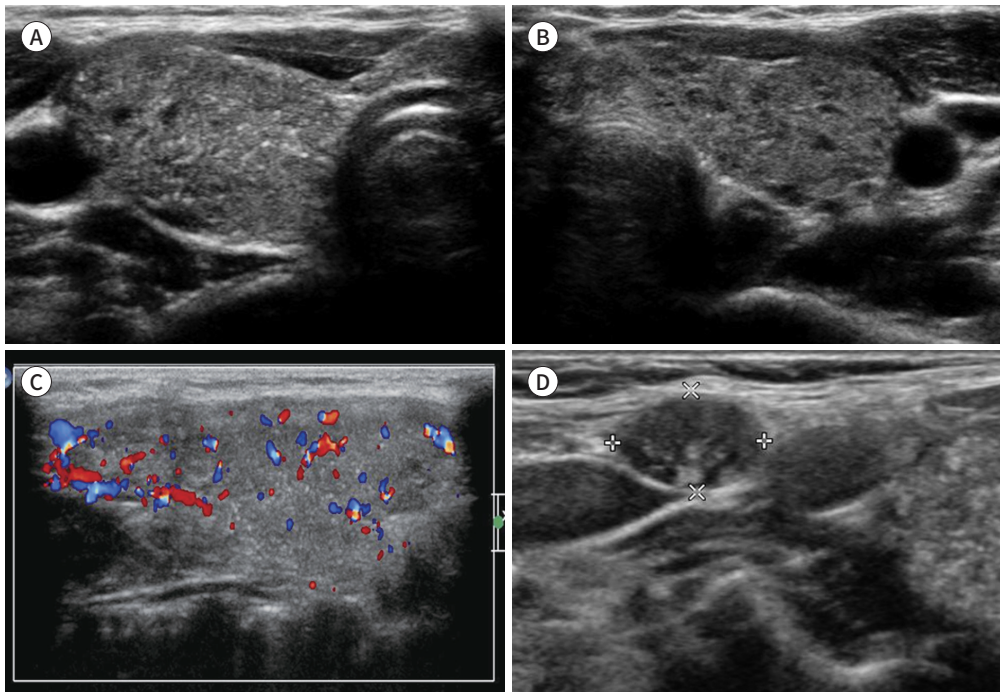
Fig. 1. A 9-year-old girl with diffuse sclerosing variant of papillary thyroid carcinoma presented with a painless diffuse goiter.

A, B. Transverse US of the thyroid revealed heterogeneous hypoechoogenicity with diffuse scattered microcalcifications.

C. Color Doppler US demonstrated increased vascularity in the thyroid gland.

D. Transverse US revealed enlarged level II lymph nodes on the right side of the neck, with increased internal echogenicity and microcalcifications, suspected to be metastases.

US = ultrasonography



DISCUSSION

The incidence of differentiated thyroid cancer, which almost exclusively manifests in the form of papillary thyroid cancer, is known as 0.54 cases per 100000 persons, but it is rare disease in children and adolescents, accounting for only 1.4 % of all pediatric malignancies (6). Among them, DSPTC is a rare variant, and there are studies reporting the prevalence of this variant among children < 10 years ranges from 2.94% to 4.65% (4).

DSPTC usually presents as painless thyroid nodules or diffuse goiter (7), and the latter presentation may lead to a diagnostic delay, as seen in our case. Moreover, DSPTC is associated with a higher incidence of regional lymph node and pulmonary metastases relative to classic papillary thyroid carcinoma (8). Consistent with that observation, our patient was found to have bilateral cervical lymph node metastases.

HT, or lymphocytic thyroiditis, is the most common type of inflammatory thyroid disease in children and adolescents, with a prevalence of 1.3% to 9.6%. HT is characterized by diffuse lymphocyte and plasma cell infiltration; high serum concentrations of thyroid antibodies, particularly antithyroid peroxidase and anti-thyroglobulin antibodies; and goiter (3). Patients with DSPTC are more likely to receive positive anti-thyroglobulin antibody test results, compared to those with classical papillary thyroid carcinoma (4). Few reports have explored the

potential correlation between papillary thyroid carcinoma and HT in children and adolescents. In this regard, Won et al. (3) reported that malignancy rate of 7.9% in children and adolescents with HT and only 1.1% in patients younger than 10 years. DSPTC is clinically similar to HT and permeates the entire gland causing diffuse thyroid enlargement without a dominant nodule. Moreover, the presence of anti-thyroglobulin antibodies may mimic HT (9). Therefore, clinical and radiologic evaluations are important in the avoidance of misdiagnosis.

Previous studies have reported on the characteristic ultrasonographic features of DSPTC, including diffuse enlargement of the thyroid gland with heterogeneous hypoechogenicity and diffuse scattered microcalcifications with or without an associated suspicious mass (10). The ultrasonographic features of HT include a hypoechoic and enlarged thyroid gland with heterogeneous parenchyma containing echogenic septations and micronodules. On ultrasound images, the diffuse nature of DSPTC often mimics chronic thyroiditis, especially in the absence of a nodular mass. Consequently, the presence of diffuse scattered microcalcifications may be the most important ultrasonographic feature of DSPTC (9). In our case, microcalcifications were scattered in both thyroid lobes and some lymph nodes.

In summary, we here reported a case of DSPTC in a 9-year-old girl who presented with a painless diffuse goiter and positive autoantibody test results suggestive of HT. The ability of DSPTC to mimic the diffuse thyroid enlargement associated with thyroiditis presents a clinical diagnostic challenge. Although DSPTC has low prevalence in children younger than 10 years, it should be included in the differential diagnosis of diffuse goiter in children, and ultrasonography should be used as an initial diagnostic tool. In such cases, the presence of multiple scattered microcalcifications in the thyroid gland and lymph nodes should alert the radiologist to the possibility of concomitant malignancy.

Author Contributions

Conceptualization, Y.S.K.; data curation, Y.S.K.; formal analysis, B.S.H., Y.S.K., K.S.S.; investigation, B.S.H., K.S.S.; supervision, S.K.S.; validation, L.J.E.; writing—original draft, B.S.H., Y.S.K., K.S.S.; and writing—review & editing, B.S.H., Y.S.K., K.S.S.

Conflicts of Interest

The authors have no potential conflicts of interest to disclose.

REFERENCES

1. Crile G Jr, Fisher ER. Simultaneous occurrence of thyroiditis and papillary carcinoma; report of two cases. *Cancer* 1953;6:57-62
2. Kim KW, Park YJ, Kim EH, Park SY, Park DJ, Ahn SH, et al. Elevated risk of papillary thyroid cancer in Korean patients with Hashimoto's thyroiditis. *Head Neck* 2011;33:691-695
3. Won JH, Lee JY, Hong HS, Jeong SH. Thyroid nodules and cancer in children and adolescents affected by Hashimoto's thyroiditis. *Br J Radiol* 2018;91:20180014
4. Koo JS, Hong S, Park CS. Diffuse sclerosing variant is a major subtype of papillary thyroid carcinoma in the young. *Thyroid* 2009;19:1225-1231
5. Chung BM, Park SH, Kim SJ, Seo JS, Kim YS, Shim HJ, et al. Papillary thyroid carcinoma in children and adolescents. *Ultrasound Q* 2014;30:193-196
6. Verburg FA, Van Santen HM, Luster M. Pediatric papillary thyroid cancer: current management challenges. *Onco Targets Ther* 2017;10:165-175
7. Fukushima M, Ito Y, Hirokawa M, Akasu H, Shimizu K, Miyauchi A. Clinicopathologic characteristics and prognosis of diffuse sclerosing variant of papillary thyroid carcinoma in Japan: an 18-year experience at a

single institution. *World J Surg* 2009;33:958-962

8. Kwak JY, Kim EK, Hong SW, Oh KK, Kim MJ, Park CS, et al. Diffuse sclerosing variant of papillary carcinoma of the thyroid: ultrasound features with histopathological correlation. *Clin Radiol* 2007;62:382-386
9. Chen CC, Chen WC, Peng SL, Huang SM. Diffuse sclerosing variant of thyroid papillary carcinoma: diagnostic challenges occur with Hashimoto's thyroiditis. *J Formos Med Assoc* 2013;112:358-362
10. Zhang Y, Xia D, Lin P, Gao L, Li G, Zhang W. Sonographic findings of the diffuse sclerosing variant of papillary carcinoma of the thyroid. *J Ultrasound Med* 2010;29:1223-1226

소아의 미만성 경화 변종 갑상선 유두암: 증례 보고

변승희¹ · 유선경^{1,2*} · 강성수¹ · 신경숙^{1,2} · 이정은^{1,2}

미만성 경화 변종 갑상선 유두암은 갑상선 유두암의 드문 변종이다. 저자들은 통증을 동반하지 않은 미만성 갑상선 비대를 보였던 9세 여자 환자에서 발생한 미만성 경화 변종 갑상선 유두암의 드문 증례에 대해 보고하고자 한다. 환자는 갑상선 과산화효소 항체에 양성하였고, 처음에는 하시모토 갑상선염으로 진단받았다. 하지만 갑상선 초음파 상에서 미만성 경화 변종 갑상선 유두암의 특징적인 초음파 소견을 보였고, 수술 후 미만성 경화 변종 갑상선 유두암으로 확진되었다. 비록 소아에서 갑상선암은 드물지만 갑상선 비대를 보일 때 미만성 경화 변종 갑상선 유두암의 가능성을 고려해야 한다. 또한 초음파를 시행함으로써 갑상선암의 진단이 지연되는 것을 막을 수 있다.

¹충남대학교병원 영상의학과,

²충남대학교 의과대학 영상의학교실