

# Sporotrichosis in the nail—An unusual location and presentation



Krista N. Larson, MD,<sup>a</sup> Shaily Pandey, MD,<sup>b</sup> William Hoover III, MD,<sup>b</sup> and  
Natalie Z. Sun, MD<sup>b</sup>  
Morgantown, West Virginia, and Chapel Hill, North Carolina

**Key words:** fungus; nail disorders; sporotrichosis.

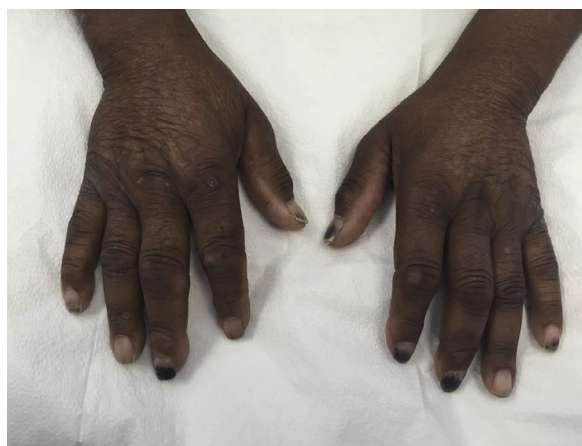## INTRODUCTION

Sporotrichosis, or rose gardener's disease, is caused by the dimorphic fungus *Sporothrix schenckii* and is the most common subcutaneous mycosis.<sup>1</sup> The disease typically occurs in one of 3 main forms: lymphocutaneous (most commonly), fixed cutaneous, or disseminated cutaneous.<sup>1</sup> We report an unusual case of *Sporothrix*, presenting in a 67-year-old man with painful, hyperpigmented fingernails.

## CASE REPORT

A 67-year-old man with a history of hypertension, hyperlipidemia, type II diabetes mellitus, end-stage renal disease on hemodialysis, gout, and coronary artery disease presented to the dermatology clinic with a 9-month history of multiple painful, hyperpigmented fingernails. He denied any systemic symptoms including fever, chills, night sweats, or unintentional weight loss during this period. He had attempted therapy with acetaminophen for the pain without relief. Two months before presenting in the dermatology clinic, the pain was so severe that he was admitted to the hospital. During the hospitalization, although afebrile, he underwent workup for endocarditis with a transesophageal echocardiogram that was negative. Additionally, he was screened for various forms of autoimmune disease and vasculopathy, but all laboratory results were unremarkable.

Further history revealed that he worked outdoors with his hands, but he denied any recent trauma. Our initial differential diagnosis at this time included hyperpigmented onychomycosis, trauma, bleeding diathesis, or endocarditis not visualized on transesophageal echocardiogram.



**Fig 1.** Hyperpigmentation of the distal nail plate with subungual debris involving multiple digits.

On examination, the patient exhibited hyperpigmentation of the distal half of the nail plate in the nails of the third digit bilaterally and the first and second digit of the left hand. Hyperpigmentation only involved the most distal half centimeter of the nail plate of the fifth digit bilaterally and the first and second digit of the right hand. There was subungual thickening of the distal nail plates of all 10 digits, with diminished involvement of the fourth digit bilaterally (Fig 1). A nail clipping was performed and sent for culture. The culture on Sabouraud dextrose agar grew *Sporothrix*-like species, which was confirmed with sequencing of the internal transcribed spacer region of the fungal ribosomal RNA (Fig 2). The patient was treated with 200 mg of itraconazole daily for 3 months. He returned to the clinic 1 month after treatment, and his nail findings had resolved (Fig 3).

From the Department of Dermatology, West Virginia University<sup>a</sup> and the Department of Dermatology, University of North Carolina.<sup>b</sup>

Funding sources: None.

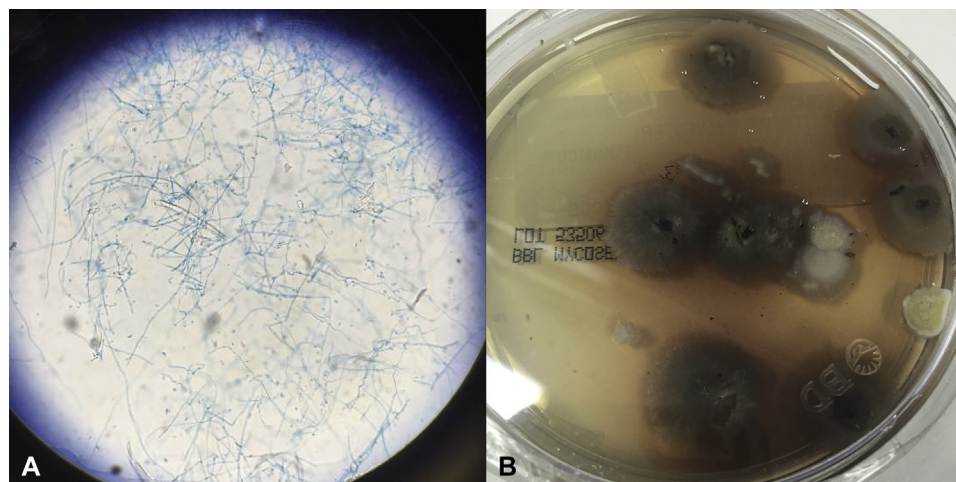
Conflicts of interest: None declared.

Correspondence to: Krista N. Larson, MD, Department of Medicine, Section of Dermatology, 4th Floor HSCH, Rm 4075A, PO Box 9158, Morgantown, WV 26506. E-mail: [knl4bm@virginia.edu](mailto:knl4bm@virginia.edu).

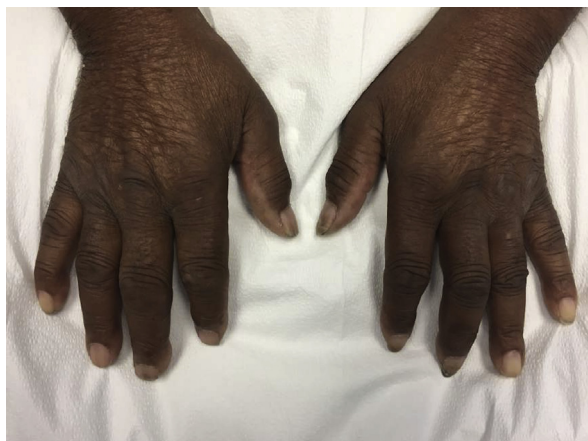JAAD Case Reports 2018;4:47-9.  
2352-5126

© 2017 by the American Academy of Dermatology, Inc. Published by Elsevier, Inc. This is an open access article under the CC BY-NC-ND license (<http://creativecommons.org/licenses/by-nc-nd/4.0/>).

<http://dx.doi.org/10.1016/j.jidcr.2017.08.003>



**Fig 2.** Microscopic view shows (A) *Sporothrix* species and (B) Sabouraud dextrose agar growing sporothrixlike species.



**Fig 3.** Follow-up visit with nail findings resolved.

## DISCUSSION

*Sporothrix* species causes subcutaneous mycosis, most commonly presenting in the lymphocutaneous form.<sup>1</sup> It was first described in 1898 by Benjamin Schenk at Johns Hopkins Hospital and in 1900 was named by Hektoen and Perkins.<sup>2</sup> Although *S schenckii* was previously thought to be the only cause of sporotrichosis, it recently became evident that *S schenckii* is actually a complex of many distinct species all resulting in the classically described clinical presentation of sporotrichosis.<sup>3</sup> *Sporothrix* species are typically found in tropical and subtropical humid climates, with the highest prevalence in Central and South America, Africa, and Japan.<sup>2,4</sup>

Sporotrichosis initially presents at sites of trauma, typically the face or extremities, and is thought to occur during gardening or some other form of activity resulting in direct contact with the soil. More recently, it has also been found to be transmitted via domestic cats in Brazil and Japan.<sup>5,6</sup> The

lymphocutaneous form typically occurs after first exposure to the fungus. It starts as an erythematous granulomatous nodule at the site of initial injury, and over the span of a week to month spreads proximally via the lymphatics.<sup>4</sup> The fixed cutaneous form typically occurs in patients previously exposed to the fungus, whereas the disseminated form is most common in immunocompromised hosts.<sup>1</sup>

Multiple atypical presentations of sporotrichosis have been documented in the literature; however, none resemble our patient's presentation. A case of sporotrichosis presenting as a periungual papule has been reported; however, this patient ultimately developed new nodules spreading in a lymphocutaneous manner within weeks.<sup>4</sup> Additionally, an immunocompromised patient presented with multiple irregularly shaped and randomly distributed ulcers with herpetiform morphology that was ultimately diagnosed as sporotrichosis.<sup>7</sup> A 26-year-old man with a hypoesthetic plaque thought to be leprosy was found to have sporotrichosis as well.<sup>8</sup> Finally, a case of sporotrichosis on the left ear of a female patient, where the source of infection was thought to be a wooden earring, was reported.<sup>9</sup>

We report the first case, to our knowledge, of *Sporothrix* species causing a pigmented infection of the nail. The infected nails, and the fungal growth on the Sabouraud dextrose agar, were dark in color secondary to melanin-like pigment production by *Sporothrix*. A prior study found that not only are these melanin-like pigments made by *Sporothrix* in vitro, but in infected humans, antibodies against the pigments are also produced.<sup>10</sup> Our patient did not exhibit any other cutaneous manifestations, and after 9 months of infection did not have any lymphocutaneous spread. Our case highlights a

novel location and progression of sporotrichosis. Sporotrichosis should be added to the current list of organisms causing fungal melanonychia.<sup>11</sup> Our patient was started on 200 mg of itraconazole daily, which was continued for 3 months based on other noted dosing regimens for cutaneous sporotrichosis. The patient's granddaughter kept his nails trimmed regularly, and on follow-up, his nail findings had resolved completely.

#### REFERENCES

1. Bolognia JL, Jorizzo JL, Schaffer JV. *Dermatology*. 3rd ed. Volume 1 Chapter 77. Philadelphia: Elsevier Limited; 2012:1251-1284.
2. Vasquez-del-Mercado E, Arenas R, Padilla-Desgarennes C. Sporotrichosis. *Clin Dermatol*. 2012;30:437-443.
3. Oliveria MM, Almeida-Paes R, Gutierrez-Galhardo MC, Zancope-Oliveira RM. Molecular identification of the *Sporothrix schenckii* complex. *Rev Iberoam Micol*. 2014;31(1):2-6.
4. Hattori M, Yoshiike T, Sonda T, Hiruma M. A case of lymphocutaneous sporotrichosis occurring at the nail bed. *Mycoses*. 2011;54(5):e663-e665.
5. de Lima Barros MB, de Oliveira Schubach A, Galhardo MC, et al. Sporotrichosis with widespread cutaneous lesions: report of 24 cases related to transmission by domestic cats in Rio de Janeiro, Brazil. *Int J Dermatol*. 2003;42:677-681.
6. Watanabe M, Hayama K, Fujita H, et al. A case of sporotrichosis caused by *sporothrix globosa* in Japan. *Ann Dermatol*. 2016;28(2):251-252.
7. Gandhi N, Chander R, Jain A, Sanke S, Garg T. Atypical cutaneous sporotrichosis in an immunocompetent adult: response to potassium iodide. *Indian J Dermatol*. 2016;61(2):236.
8. Vaishampayan S, Borde P. An unusual presentation of sporotrichosis. *Indian J Dermatol*. 2013;58(5):409.
9. Reis BD, Zacaron LH, Lima RB, Cobucci FO, D'Acri AM, Martins CJ. Sporotrichosis in an unusual location- a case report. *An Bras Dermatol*. 2015;90(3 Suppl 1):S84-S87.
10. Morris-Jones R, Youngchim S, Gomez BL, et al. Synthesis of melanin-like pigments by *sporothrix schenckii* in vitro and during mammalian infection. *Infect Immun*. 2003;71(7):4026-4033.
11. Finch J, Arenas R, Baran B. Fungal melanonychia. *J Am Acad Dermatol*. 2012;66(5):830-841.