

This is an Open Access article licensed under the terms of the Creative Commons Attribution-NonCommercial-NoDerivs 3.0 License (www.karger.com/OA-license), applicable to the online version of the article only. Distribution for non-commercial purposes only.

Late-Onset Anterior Dislocation of a Posterior Chamber Intraocular Lens in a Patient with Pseudoexfoliation Syndrome

Zisis Gatzoufas^a Konstantinos Kopsidas^b
Balasz Gyongyossy^a Marilita Moschos^b Berthold Seitz^a

^aDepartment of Ophthalmology, University of Saarland, Homburg/Saar, Germany;

^bDepartment of Ophthalmology, University of Athens, Athens, Greece

Key Words

Angle-closure glaucoma · Myopic shift · Anterior dislocation · Pseudoexfoliation syndrome · Cataract surgery

Abstract

Here, we report on a patient with pseudoexfoliation syndrome who developed acute angle-closure glaucoma with a marked myopic shift due to anterior dislocation of the posterior chamber intraocular lens almost 16 months after an uneventful phacoemulsification. Examination with a Scheimpflug camera was extremely useful in confirming the diagnosis. This is the first case of late-onset angle-closure glaucoma with a significant myopic shift due to anterior dislocation of the posterior chamber intraocular lens, which resulted in a permanent alteration of the postoperative target refraction.

Introduction

Pseudoexfoliation syndrome (PES) is characterized by the production and accumulation of fibrillar extracellular material within the ocular tissue. The presence of PES is of paramount clinical importance in patients undergoing cataract surgery, because it is associated with a high rate of complications such as zonular dialysis, rupture of the posterior lens capsule, vitreous loss and dislocation of the intraocular lens (IOL) [1]. PES has also been identified as a main factor predisposing to secondary open-angle glaucoma [1].

Spontaneous dislocation of a posterior chamber IOL (PC/IOL) represents an unusual, severe complication, which mostly occurs in the late postoperative period and requires

exchange surgery of the PC/IOL or PC/IOL repositioning with scleral fixation [2–4]. In all cases reported in the literature, an in-the-bag PC/IOL was subluxed posterior into the vitreous cavity.

Here, we report on a patient with PES who developed partial acute angle-closure glaucoma (ACG) with a marked myopic shift due to anterior dislocation of the PC/IOL almost 16 months after an uneventful phacoemulsification. To the best of our knowledge, this is the first case of late-onset anterior PC/IOL dislocation with partial ACG and a marked myopic shift, which resulted in a permanent alteration of the postoperative target refraction.

Case Report

A 70-year-old male underwent an uneventful clear-cornea phacoemulsification with PC/IOL implantation in the right eye (OD) in January 2006. Preoperative routine examination disclosed a bilateral corticonuclear cataract as well as features of PES OD (fig. 1a). Neither phacodonesis nor poor pupil dilatation was observed OD. Anterior segment examination in the left eye (OS) displayed normal findings. Fundoscopy revealed normal findings bilaterally. There was no other medical history, and the patient did not receive any medication.

Cataract surgery was performed under retrobulbar anaesthesia. During the operation, we implanted a capsular tension ring (CTR) in order to stabilize the posterior capsule and prevent zonular-capsular complications. A PMMA CTR (type 14, 10-mm closed diameter; Morcher GmbH, Stuttgart, Germany) was implanted, which, according to our personal experience, represents a simple and reliable solution for cases with moderate risk. Finally, a foldable PC/IOL (hydrophilic acryl) was inserted in the bag, without any complication occurring during the surgical procedure. After one week, the patient's best corrected visual acuity (BCVA) was 1.0 (refraction $-0.25/-0.5/110^\circ$). Six weeks later, the patient was subjected to an uncomplicated cataract surgery OS. Postoperative BCVA was 1.0 (refraction $-0.25/-0.75/175^\circ$).

In February 2007, the patient was referred to our department complaining of visual acuity deterioration OD. Slit-lamp examination demonstrated a marked shallowing of the anterior chamber, without any other visible pathological findings (fig. 1b). Distension of the posterior capsule indicative of capsular block syndrome was not observed. Intraocular pressure (IOP) was 29 mm Hg OD and 11 mm Hg OS. Evaluation of refraction unravelled a significant myopic shift OD; BCVA was 1.0 with $-3.75/-0.5/110^\circ$. The refractive status OS was $-0.25/-0.75/115^\circ$ and BCVA was 1.0. Scheimpflug examination documented a prominent axial anterior dislocation of the PC/IOL OD, without fluid accumulation between the posterior capsule and the PC/IOL (fig. 1d). Anterior chamber depth was 3.93 mm. The PC/IOL was sitting in the capsular bag OS, and the anterior chamber depth was 5.21 mm (fig. 1c, e). IOP elevation resisted to topical therapy with α -2 receptors agonists (brimonidine eye drops) and, therefore, one week later Nd:YAG iridotomy was performed. IOP was successfully regulated OD after Nd:YAG iridotomy (direct postoperative IOP: 14 mm Hg). Nevertheless, the shallowing of the anterior chamber did not significantly improve, and the anterior dislocation of the PC/IOL remained unaltered (refraction $-2.75/-0.75/110^\circ$, BCVA 1.0). Visual acuity OS was 1.0 (refraction $0.0/-0.75/175^\circ$). Although the myopic shift OD was not eliminated, the patient was satisfied with the monovision, which was achieved unintentionally and, therefore, we did not proceed to an exchange surgery of the PC/IOL.

Discussion

PES is associated with a high incidence of PC/IOL dislocation in cataract surgery, whether it is an in-the-bag PC/IOL or an out-of-the-bag PC/IOL [5]. This unusual complication may occur with any type of PC/IOL on average 8.5 years after its implantation [6]. Bilateral PC/IOL dislocation in PES has also been described [7]. It is

important to note that all cases reported up to date in the literature manifested a posterior PC/IOL dislocation in the vitreous cavity.

Our patient presented with a myopic shift and ACG due to delayed anterior PC/IOL dislocation OD. Slit-lamp examination did not reveal an anterior capsular opacification of elements of phimosis which could explain the anterior dislocation of the PC/IOL-CTR complex. During a thorough preoperative explanatory discussion, the patient was informed about the complication risk due to the underlying PES, and he strongly insisted that we should implement any necessary precautionary measures during the operation to minimize this risk. Therefore, we decided to implant a CTR during the operation in order to stabilize the posterior capsule and prevent zonular-capsular complications, although we did not observe phacodonesis or difficulties in pupil dilation preoperatively.

von der Lippe et al. [8] first postulated that zonular weakness in some patients with PES may lead to anterior subluxation of the lens with consecutive ciliary block ACG. Use of a CTR during the cataract surgery did not prevent this complication, since CTR implantation in PES-associated zonular weakening does not guarantee long-term zonular stability [9]. In our patient, Nd:YAG iridotomy resulted in a satisfactory IOP regulation, but the emmetropic refractive status was not restored. Our patient was satisfied with the monovision (OD refraction $-2.75/-0.50/110^\circ$, OD BCVA 1.0; OS refraction $-0.25/-0.75/115^\circ$, OS BCVA 1.0) and, therefore, we did not proceed to PC/IOL exchange or PC/IOL repositioning. To the best of our knowledge, this is the first report of late-onset anterior PC/IOL dislocation in PES, generating a permanent myopic shift. Ophthalmologists should be aware of this potential complication, which may occur in patients with PES within a considerable period of time after cataract surgery, and these patients should be warned accordingly.

Disclosure Statement

All authors have no conflict of interest to declare.

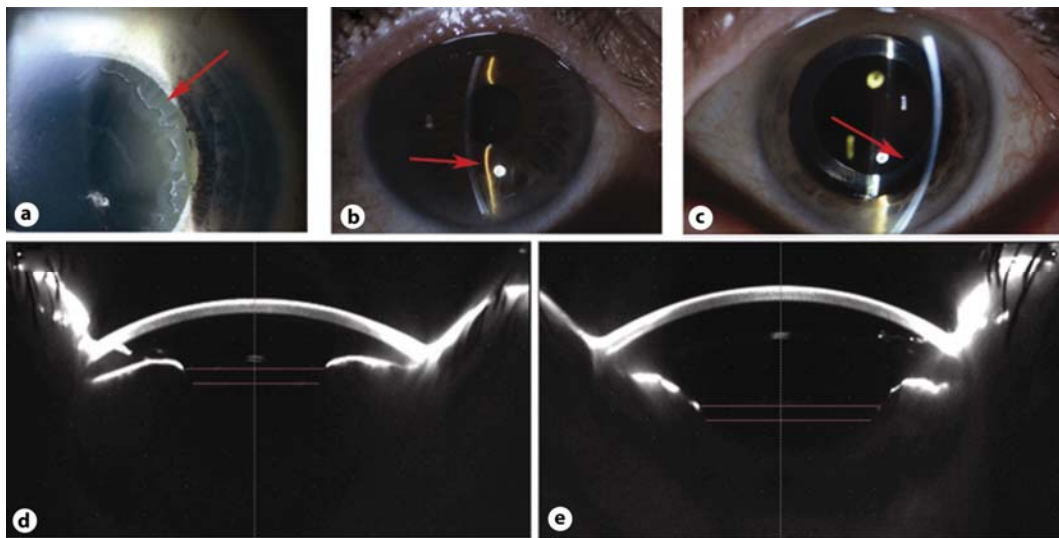


Fig. 1. Slit-lamp findings and Scheimpflug imaging after anterior dislocation of the posterior chamber intraocular lens (PC/IOL) in a patient with pseudoexfoliation syndrome. Prominent features of pseudoexfoliation on the right anterior lens capsule (red arrow, **a**). Narrowing of the anterior chamber after anterior dislocation of the PC/IOL in the right eye (red arrow, **b**). Normal anterior segment with wide anterior chamber after cataract surgery in the left eye (red arrow, **c**). Scheimpflug examination confirmed the anterior dislocation of the PC/IOL in the right eye (red line, **d**). Anterior chamber depth was 3.93 mm. Normal in-the-bag position of the PC/IOL in the left eye (red line, **e**). Anterior chamber depth was 5.21 mm.

References

- 1 Naumann GO, Schlötzer-Schrehardt U, Kühle M: Pseudoexfoliation syndrome for the comprehensive ophthalmologist. Intraocular and systemic manifestations. *Ophthalmology* 1998;105:951–968.
- 2 Gross JG, Kokame GT, Weinberg DV, Dislocated In-The-Bag Intraocular Lens Study Group: In-the-bag intraocular lens dislocation. *Am J Ophthalmol* 2004;137:630–635.
- 3 Jehan FS, Mamalis N, Crandall AS: Spontaneous late dislocation of intraocular lens within the capsular bag in pseudoexfoliation patients. *Ophthalmology* 2001;108:1727–1731.
- 4 Masket S, Osher RH: Late complications with intraocular lens dislocation after capsulorhexis in pseudoexfoliation syndrome. *J Cataract Refract Surg* 2002;28:1481–1484.
- 5 Hayashi K, Hirata A, Hayashi H: Possible predisposing factors for in-the-bag and out-of-the-bag intraocular lens dislocation and outcomes of intraocular lens exchange surgery. *Ophthalmology* 2007;114:969–975.
- 6 Davis D, Brubaker J, Espandar L, Stringham J, Crandall A, Werner L, Mamalis N: Late in-the-bag spontaneous intraocular lens dislocation: evaluation of 86 consecutive cases. *Ophthalmology* 2009;116:664–670.
- 7 Yopez J, Prall FR, Arevalo JF, de Yopez J, Contreras F, Matheus E: Management of two dislocated posterior chamber lenses in eyes with pseudoexfoliation. *Br J Ophthalmol* 2006;90:917–918.
- 8 von der Lippe I, Kühle M, Naumann GO: Pseudoexfoliation syndrome as a risk factor for acute ciliary block angle closure glaucoma. *Acta Ophthalmol (Copenh)* 1993;71:277–279.
- 9 Scherer M, Bertelmann E, Rieck P: Late spontaneous in-the-bag intraocular lens and capsular tension ring dislocation in pseudoexfoliation syndrome. *J Cataract Refract Surg* 2006;32:672–675.