

Phrenic nerve injury contemporaneous with acute decrease in compound motor action potential during laser balloon pulmonary vein isolation for atrial fibrillation



Takahiko Nagase, MD, So Asano, MD, Koji Goto, MD, Yoshifumi Ikeda, MD, Ritsushi Kato, MD, Kazuo Matsumoto, MD

From the Department of Cardiology, International Medical Center, Saitama Medical University, Saitama, Japan.

Introduction

Pulmonary vein isolation (PVI) leads to acceptable success rates in individuals with drug-refractory paroxysmal or persistent atrial fibrillation (AF).¹ In addition to conventional irrigated radiofrequency current ablation, the laser balloon (HeartLight, CardioFocus, Marlborough, MA) is currently available in clinical practice as technology specialized for PVI.

As with other ablation technologies, phrenic nerve injury is an important complication even in laser balloon PVI.²⁻⁴ For prevention of phrenic nerve injury in laser balloon PVI, attenuation of phrenic nerve capture under high-output pacing from the superior vena cava has been used as a criterion for cessation of laser energy titration.^{5,6} In cryoballoon ablation, monitoring of the compound motor action potential (CMAP) has already been reported with regard to prevention of phrenic nerve injury.⁷ Theoretically, CMAP is considered to decrease at the time of phrenic nerve injury also in laser balloon ablation. However, the actual clinical significance of CMAP in laser balloon PVI is unknown.

We report the case of a patient demonstrating a sudden drop in CMAP amplitude at the same time as the decrease in diaphragmatic capture during laser energy titration to the right superior pulmonary vein.

Case report

A 75-year-old woman was admitted to our hospital for laser balloon PVI for treatment of drug-refractory symptomatic paroxysmal AF (Figure 1A). The patient had a history of resection of a small part of her lung by video-assisted thoracic

KEY TEACHING POINTS

- The significance and reaction of the compound motor action potential (CMAP) remain unclear in laser balloon ablation.
- Diaphragmatic excursion was reduced on manual palpation almost simultaneously with the decline of CMAP during phrenic nerve pacing in laser energy titration to the right superior pulmonary vein. CMAP decreased suddenly at the time of phrenic nerve injury.
- Right phrenic nerve injury persisted 3 months after laser balloon ablation, regardless of CMAP monitoring.
- CMAP can be a marker of phrenic nerve injury in laser balloon ablation. However, whether CMAP can prevent phrenic nerve injury in laser balloon ablation remains unclear.

surgery because of lung cancer 18 years ago. The patient had neither respiratory symptoms nor any recurrence of her lung cancer. Preoperative computed tomography showed normal anatomic position of the pulmonary veins. No significant elevation of the diaphragms was observed on chest radiograph before ablation (Figure 1B). The procedure was performed with the patient under deep sedation using boluses of fentanyl with continuous infusions of dexmedetomidine and propofol. An esophageal temperature probe (Esophaster; Japan Lifeline, Tokyo, Japan) was inserted orally. After a 7F, 20-pole catheter (Livewire; Abbott, Saint Paul, MN) was placed in the coronary sinus, a single transseptal puncture was performed using the modified Brockenbrough technique and a transseptal 8F sheath (SL1, Abbott). Selective pulmonary vein angiograms were obtained before ablation to define

KEYWORDS Atrial fibrillation; Compound motor action potential; Laser balloon ablation; Phrenic nerve injury; Pulmonary vein isolation (Heart Rhythm Case Reports 2019;5:83-87)

Address reprint requests and correspondence: Dr Takahiko Nagase, Department of Cardiology, Saitama Medical University, International Medical Center, 1397-1 Yamane, Hidaka, Saitama 350-1298, Japan. E-mail address: tnagase@saitama-med.ac.jp.

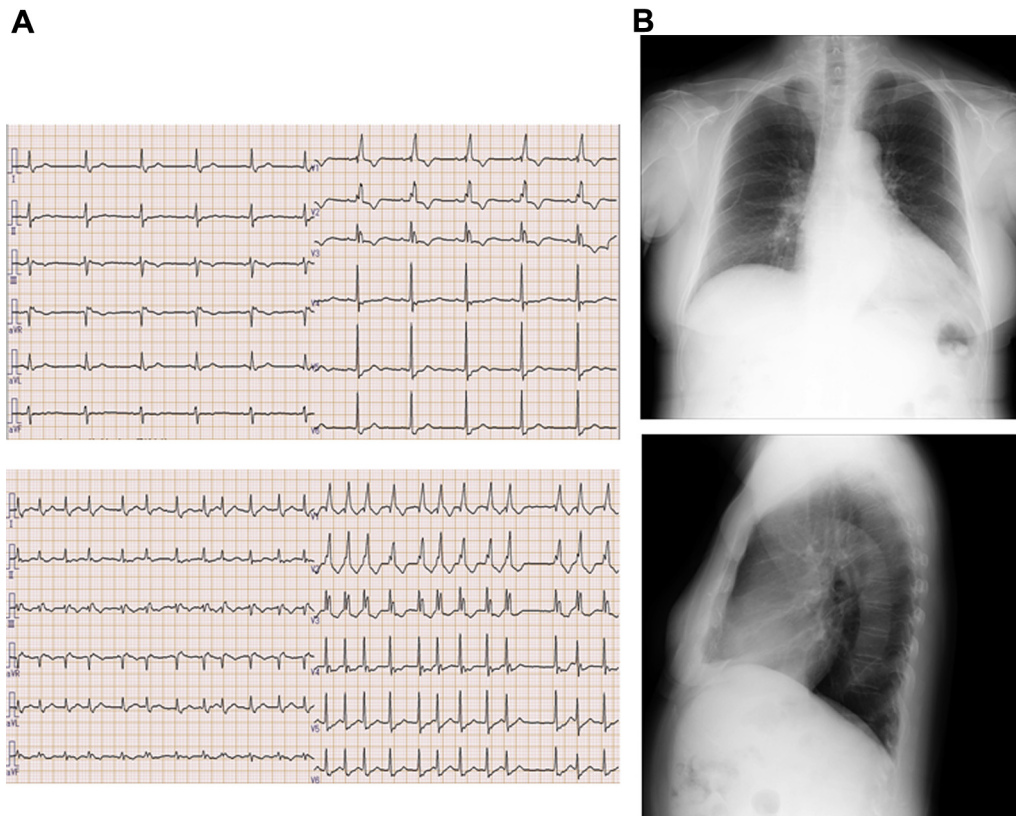


Figure 1 A: Baseline 12-lead electrocardiogram in sinus rhythm (*top*) and paroxysmal atrial fibrillation (*bottom*) before ablation. B: Chest radiographs of posterior-anterior view (*top*) and right-left view (*bottom*) before ablation.

the pulmonary vein anatomy using a 6F multipurpose catheter. The laser balloon was navigated to the target pulmonary vein using a steerable 12F sheath (CardioFocus) and inflated for optimal pulmonary vein occlusion at the antral balloon position. Laser energy was deployed in one-by-one fashion covering 30° of a circle, with each ablation lesion for 20 or 30 seconds according to the console's settings. The energy was titrated between 5.5 and 12 W depending on the degree of tissue exposure targeted to at least 8.5 W according to the high-dose energy concept.⁸ Ablation was performed individually in the following order: left superior pulmonary vein, left inferior pulmonary vein, right superior pulmonary vein, and right inferior pulmonary vein.

Because phrenic nerve injury has been rare in laser balloon ablation,² the right superior pulmonary vein ablation was treated earlier than the right inferior pulmonary vein. During ablation of the right-sided pulmonary veins, continuous and stable right phrenic nerve pacing (10 V, 2 ms) was performed using a 10-pole multielectrode circular mapping catheter (15/25 mm, Lasso; Biosense Webster, Diamond Bar, CA) at a pacing rate of 50/min in the superior vena cava for early detection of phrenic nerve injury. CMAP was recorded using the standard method as described previously.⁷ For ablation of the right-sided pulmonary vein, the laser balloon was carefully positioned at the left atrial antrum to prevent phrenic nerve injury (Figure 2A and B).

Laser energy was titrated from the posterior to the anterior wall during ablation of the right superior pulmonary vein.

Stable CMAP amplitude was confirmed before each titration (Figure 2C). However, we noted a sudden weakening in the palpation of the right diaphragm simultaneous with a decline in CMAP amplitude at the time of titration to 12 W to the anterior wall (Figure 2B and C). The titration was immediately terminated 10 seconds after the beginning of titration. In retrospective analysis for comparison with cryoballoon ablation according to a previous report,⁹ CMAP declined from 0.61–0.67 mV to 0.42 mV, which was <70% of the pre-ablation CMAP amplitude, in 2.4 seconds (Figure 2C).

After a waiting period, CMAP and right diaphragm movement improved somewhat but not to previous levels. Laser energy titration had already been completed for almost the entire circle of the right superior pulmonary vein. We avoided any additional energy titration to the rest of the right superior pulmonary vein. The right phrenic nerve is slightly away from the right inferior pulmonary vein.¹ Hence, we proceeded carefully with right inferior pulmonary vein ablation. CMAP did not decline during ablation of the right inferior pulmonary vein. After complete circular ablation of all pulmonary veins, the pulmonary veins were remapped using the circular mapping catheter. Entrance and exit block between the left atrium and pulmonary vein were confirmed for all of the pulmonary veins. The patient's respiratory status, including oxygen saturation, remained stable, and the procedure was completed.

Chest radiograph on the day after the procedure showed mild right diaphragm elevation compared with before the

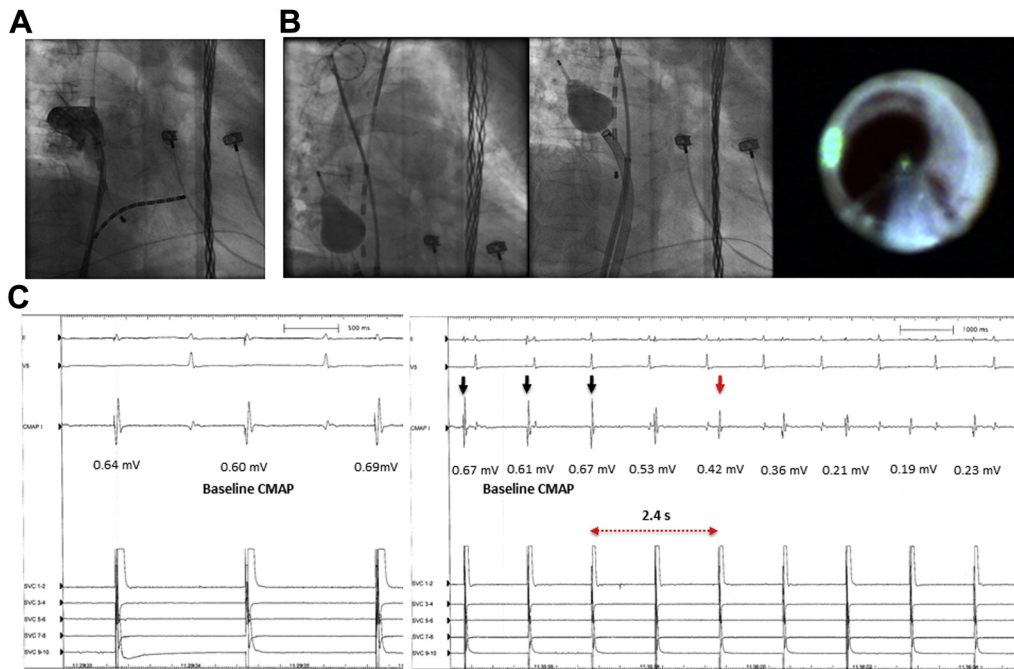


Figure 2 **A:** Selective angiogram of the right superior pulmonary vein. **B:** Balloon position and endoscopic view at the time of sudden decline in compound motor action potential (CMAP). Left: CMAP was obtained while pacing the circular mapping catheter positioned at the superior vena cava. Middle: Laser balloon was positioned at the left atrial antral position. Right: Endoscopic view. CMAP was suddenly reduced at the anterior part of the right superior pulmonary vein. **C:** Left: Intracardiac electrocardiogram. A stable CMAP amplitude was confirmed before laser energy titration to the right superior pulmonary vein. Right: CMAP showed a sudden reduction >30% of baseline amplitude (*black arrows*, 0.61–0.67 mV) in only 2.4 seconds (*red arrow*, 0.42 mV) during titration to the anterior wall of the right superior pulmonary vein.

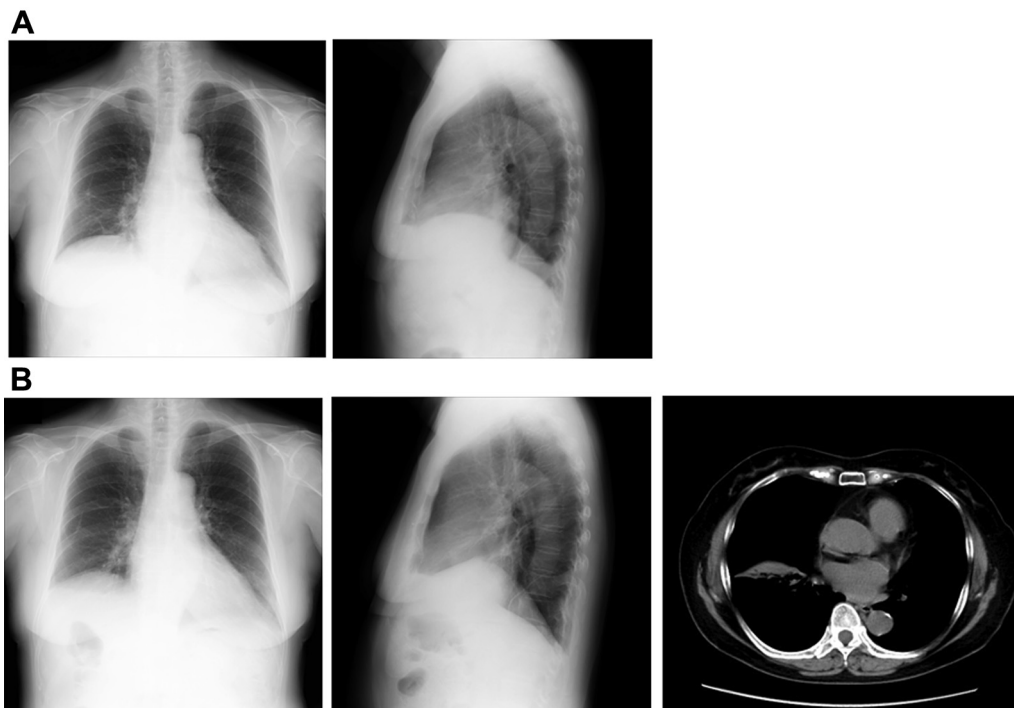


Figure 3 **A:** Chest radiographs of posterior-anterior view (*left*) and right-left view (*right*) on the day after ablation. The right diaphragm was mildly elevated. **B:** Chest radiographs of posterior-anterior view (*left*) and right-left view (*middle*) and computed tomography scan (*right*) 1 month after ablation. The right diaphragm was still elevated with a mild right atelectasis.

procedure (Figure 3A). Mild breathing difficulty at deep inspiration was noted. However, the patient had no symptoms at rest, and her oxygen saturation was normal without administration of oxygen. The patient was discharged 5 days postablation.

In the outpatient clinic 1 month after discharge, chest radiograph and computed tomography showed that the right diaphragm remained elevated, and residual mild right atelectasis was present (Figure 3B). However, the symptoms were not exacerbated, and the patient was able to be observed without the need for special treatment. Right phrenic nerve injury remained 3 months after the ablation. Follow-up every 3 months was scheduled.

Discussion

In this report, we showed CMAP response at the time of phrenic nerve injury during laser balloon PVI. CMAP declined suddenly during laser energy titration to the anterior wall of the right superior pulmonary vein. To our knowledge, use of CMAP for prevention of phrenic nerve injury in laser balloon PVI has not been reported.

Originally, CMAP proved to be useful for early detection of phrenic nerve injury during PVI using a cryoballoon.⁷ A reduction of CMAP amplitude has been reported to precede diaphragmatic dysfunction.⁹ Franceschi and colleagues⁷ demonstrated that CMAP declined over time during freezing in cryoballoon ablation in patients with phrenic nerve injury. This seems to result because cryoenergy gradually forms lesions on the left atrial intimal surface together with balloon surface cooling. However, in the present report we found that CMAP decreases suddenly and considerably during laser balloon PVI. The difference in the timing of the decline in CMAP between cryoballoon and laser balloon ablation may be due to energy conduction characteristics or lesion depth to the left atrial intimal surface and the method of energy delivery (ie, one-shot vs point-by-point). It has already been reported that energy conduction and the mode of lesion formation to the left atrial antrum–pulmonary vein junction may differ between different technologies.¹ Andrade and colleagues¹⁰ described in an animal study that phrenic nerve injury in cryoballoon ablation is axonal in nature and characterized by wallerian degeneration with the potential for recovery. With regard to the laser balloon, previous studies have demonstrated that laser energy can form deeper and more discrete lesions in the pulmonary vein–left atrial antrum than radiofrequency current can in the adenosine provocation test and on cardiac magnetic resonance imaging.^{11,12} Bordignon and colleagues¹³ reported that laser energy is absorbed by the water in cardiac tissues, and that maximal heat is reached some millimeters deep beyond the endocardial level at first and then propagates to deeper tissues. These are possible reasons why phrenic nerve injury occurred suddenly and persistently.

The incidence of phrenic injury as a complication is not high in laser balloon PVI compared with other technologies.² However, it is possible that phrenic nerve injury persists in

laser balloon PVI. Saitoh and colleagues¹⁴ reported that persistent phrenic nerve injury occurred in 4.5% of 199 patients during second-generation cryoballoon ablation. However, phrenic nerve injury remained in only 2 patients at final follow-up of 5 and 20 months, respectively. Dukkipati and colleagues² reported that phrenic nerve injury occurred in 6 of 170 AF patients (3.5%) during laser balloon PVI, and that persistent phrenic nerve injury was observed in 3 of the 6 patients (1.8%). According to that report, the usefulness of CMAP for prevention of persistent phrenic injury remains unclear.

The laser balloon system is designed so that PVI can be achieved by a single operator.¹³ However, it may be difficult to monitor diaphragm contraction during ablation directly by the operator's hand. From that standpoint, CMAP may be considered useful for a single operator during laser balloon PVI. However, because of the difficulty in detecting the acute decline in CMAP, whether CMAP can prevent the occurrence of phrenic nerve injury remains unclear.

Because the CMAP can decline quickly during laser energy titration, the faster pacing rate of the phrenic nerve and the antral balloon positioning by adjusting the balloon size as large as possible, as described previously for cryoballoon ablation,¹⁵ may be better for preventing phrenic nerve injury. In addition, the lesion sizes in laser balloon PVI for different energy settings and the proper energy dose, especially to right-sided pulmonary veins, for prevention of phrenic nerve injury remain unclear. Further studies are needed to better clarify these factors in relation to prevention of phrenic nerve injury.

Conclusion

CMAP declined quickly in laser balloon ablation of the right superior pulmonary vein. Whether CMAP can prevent phrenic nerve injury in laser balloon PVI remains unclear.

References

1. Calkins H, Hindricks G, Cappato R, et al. 2017 HRS/EHRA/ECAS/APHS/SOLAECE expert consensus statement on catheter and surgical ablation of atrial fibrillation. *Heart Rhythm* 2017;14:e275–e444.
2. Dukkipati SR, Cuoco F, Kutinsky I, Aryana A, Bahnson TD, Lakkireddy D, Woollett I, Issa ZF, Natale A, Reddy VY; HeartLight Study Investigators. Pulmonary vein isolation using the visually guided laser balloon: a prospective, multicenter, and randomized comparison to standard radiofrequency ablation. *J Am Coll Cardiol* 2015;66:1350–1360.
3. Chierchia GB, Mugnai G, Hunuk B, Ströker E, Velagić V, Saitoh Y, Irfan G, Hacıoglu E, Cicconte G, Brugada P, DE Asmundis C. Impact on clinical outcome of premature interruption of cryoenergy delivery due to phrenic nerve palsy during second generation cryoballoon ablation for paroxysmal atrial fibrillation. *J Cardiovasc Electrophysiol* 2015;26:950–955.
4. Sacher F, Monahan KH, Thomas SP, et al. Phrenic nerve injury after atrial fibrillation catheter ablation: characterization and outcome in a multicenter study. *J Am Coll Cardiol* 2006;47:2498–2503.
5. Schmidt B, Gunawardene M, Urban V, Kulikoglu M, Schulte-Hahn B, Nowak B, Bordignon S, Chun KJ. Visually guided sequential pulmonary vein isolation: insights into techniques and predictors of acute success. *J Cardiovasc Electrophysiol* 2012;23:576–582.
6. Metzner A, Wissner E, Schmidt B, Chun J, Hindricks G, Piorkowski C, Ouyang F, Kuck KH. Acute and long-term clinical outcome after endoscopic pulmonary vein isolation: results from the first prospective, multicenter study. *J Cardiovasc Electrophysiol* 2013;24:7–13.

7. Franceschi F, Dubuc M, Guerra PG, Khairy P. Phrenic nerve monitoring with diaphragmatic electromyography during cryoballoon ablation for atrial fibrillation: the first human application. *Heart Rhythm* 2011;8:1068–1071.
8. Bordignon S, Chun KR, Gunawardene M, Urban V, Kulikoglu M, Miehm K, Brzank B, Schulte-Hahn B, Nowak B, Schmidt B. Energy titration strategies with the endoscopic ablation system: lessons from the high-dose vs. low-dose laser ablation study. *Europace* 2013;15:685–689.
9. Franceschi F, Dubuc M, Guerra PG, et al. Diaphragmatic electromyography during cryoballoon ablation: a novel concept in the prevention of phrenic nerve palsy. *Heart Rhythm* 2011;8:885–891.
10. Andrade JG, Dubuc M, Ferreira J, Guerra PG, Landry E, Coulombe N, Rivard L, Macle L, Thibault B, Talajic M, Roy D, Khairy P. Histopathology of cryoballoon ablation-induced phrenic nerve injury. *J Cardiovasc Electrophysiol* 2014;25:187–194.
11. Ücer E, Janeczko Y, Seegers J, Fredersdorf S, Friemel S, Poschenrieder F, Maier LS, Jungbauer CG. A Randomized Trial to compare the acute reconnection after pulmonary vein ISolation with Laser-BalloON versus radiofrequency Ablation: RATISBONA trial. *J Cardiovasc Electrophysiol* 2018;29:733–739.
12. Figueras I, Ventura RM, Mărgulescu AD, Benito EM, et al. Post-procedural LGE-CMR comparison of laser and radiofrequency ablation lesions after pulmonary vein isolation. *J Cardiovasc Electrophysiol* 2018;29:1065–1072.
13. Bordignon S, Chun KR, Gunawardene M, Schulte-Hahn B, Nowak B, Fuernkranz A, Schmidt B. Endoscopic ablation systems. *Expert Rev Med Devices* 2013;10:177–183.
14. Saitoh Y, Irfan G, Ciconte G, et al. Persistence of phrenic nerve palsy following 28-mm cryoballoon ablation: a four-year single center experience. *Pacing Clin Electrophysiol* 2015;38:807–814.
15. Saitoh Y, Ströker E, Irfan G, Mugnai G, Ciconte G, Hünük B, Velagić V, Overeinder I, Tanaka K, Brugada P, de Asmundis C, Chierchia GB. Fluoroscopic position of the second-generation cryoballoon during ablation in the right superior pulmonary vein as a predictor of phrenic nerve injury. *Europace* 2016;18:1179–1186.