

Received: 2018.11.13  
Accepted: 2019.03.08  
Published: 2019.06.20

## Idiopathic Ileo-Ileo-Cecal Intussusception in a 25-Year-Old Female

Authors' Contribution:  
Study Design A  
Data Collection B  
Statistical Analysis C  
Data Interpretation D  
Manuscript Preparation E  
Literature Search F  
Funds Collection G

BCDE 1 **Elie Zaghrine**  
ABDE 2 **Roberto Algaba**  
ABDE 3 **Gregory Nicolas**  
ADEF 4 **Elliott Koury**  
CDEF 3 **Christian Saliba**  
CDE 3 **Dani Osman**  
CDE 5 **Jaafar Al-Shami**  
CDE 3 **Julien Sami Atef Al Sayegh**  
ACDF 1 **Tony Kfoury**

1 Department of Emergency, Joseph Bracops Hospital, Bruxelles, Belgium  
2 Department of Digestive Surgery, Joseph Bracops Hospital, Bruxelles, Belgium  
3 Department of Surgery, Lebanese American University Medical Center, Rizk Hospital, Beirut, Lebanon  
4 Department of Gastroenterology, Lebanese American University Medical Center, Rizk Hospital, Beirut, Lebanon  
5 Department of Surgery, Lebanese University, Beirut, Lebanon

**Corresponding Author:** Gregory Nicolas, e-mail: [gregory.nicolas@lau.edu](mailto:gregory.nicolas@lau.edu)  
**Conflict of interest:** None declared

**Patient:** Female, 25  
**Final Diagnosis:** Ileo-ileo-cecal intussusception  
**Symptoms:** Abdominal pain  
**Medication:** —  
**Clinical Procedure:** —  
**Specialty:** Surgery

**Objective:** Rare disease





**Background:** Intussusception is defined as the penetration or telescoping of a segment of bowel into a more distal segment. Intussusception is a common cause of small bowel obstruction, especially in children. However, this finding is much less common in adults. Furthermore, when present in adults, intussusception is often found in association with some sort of organic mass, such as a tumor or pancreatic divisum that acts as a lead point, dragging the proximal segment into the distal one. The presence of an intussusception in an adult patient with no obvious lead point is very uncommon.

**Case report:** Here we report a case of ileo-ileo-cecal double intussusception in an adult patient that yielded no lead point on surgical exploration. The patient was a 25-year-old female who presented with symptoms of obstruction and was diagnosed with the intussusception via computed tomography scan. Surgical resection of the bowel was necessary as reduction could not be accomplished.

**Conclusions:** The finding of intussusception in an adult patient is far less common than in children, and even more rare when a lead point is not established. When surgery is required, a thorough exploration should be performed to search any signs of a potential lead point. Laparoscopy is usually preferred to laparotomy; however, in this case the degree of distention determined the surgical approach. Thus, due to severe distention, laparotomy was preferred.

**MeSH Keywords:** Abdominal Pain • Ileum • Intussusception

**Full-text PDF:** <https://www.amjcaserep.com/abstract/index/idArt/914110>

 1648  1  4  24



## Background

Intussusception is defined as the penetration or telescoping of a segment of bowel into a more distal segment. Intussusception is a common cause of small bowel obstruction, especially in children. This finding is much less common in adults and when present is often found in association with some sort of organic mass, such as a tumor or pancreatic divisum that acts as a lead point, dragging the proximal segment into the distal one.

## Case Report

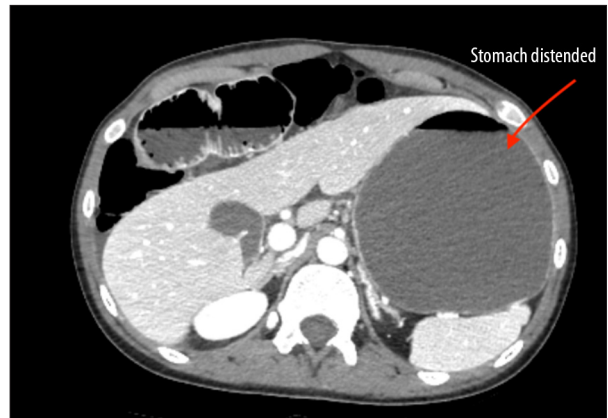A 25-year-old female presented with 24 hours of acute onset, diffuse, non-radiating, abdominal pain. In addition, she reported 3 episodes of yellowish vomiting since the pain began, as well as obstipation.

On physical examination, there was significant abdominal bloating, hypoactive bowel sound, as well as generalized tenderness to palpation. No masses were appreciated and Dance's sign was not observed. Digital rectal examination was negative with an empty rectum. Vital signs on arrival were as

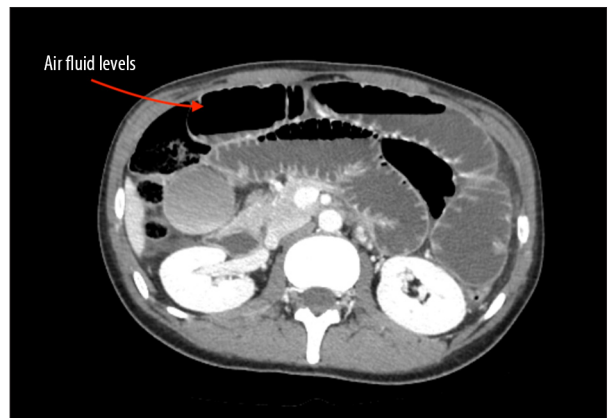
**Table 1.** Laboratory test values.

Laboratory test	Value	Normal range
Hemoglobin, g/dL	15.1	13–17
Hematocrit, %	41.8	40–50
White blood cells, 10 <sup>3</sup> /mCL	12.8	4–10
Neutrophils, %	85.1%	45–73
Platelets, 10 <sup>3</sup> /mCL	248	150–400
LDH, UI/L	229	100–190
Na, mmol/L	138	136–145
K, mmol/L	3.6	3.5–5.1
Cl, mmol/L	99	98–107
Ca, mmol/L	2.49	2.05–2.55
Creatinine, mg/dL	0.9	0.7–1.2
Urea, mg/dL	67	17–48
SGOT, UI/L	15	<40
SGPT, UI/L	10	<41
Alkaline phosphatase, UI/L	39	40–130
Total bilirubin, mg/dL	1	0.3–1
Direct bilirubin, mg/dL	0.4	<0.3

LDH – lactate dehydrogenase; NA – sodium; K – potassium; Cl – chloride; Ca – calcium; SGOT – serum glutamic-oxaloacetic transaminase; SGPT – serum glutamic-pyruvic transaminase.



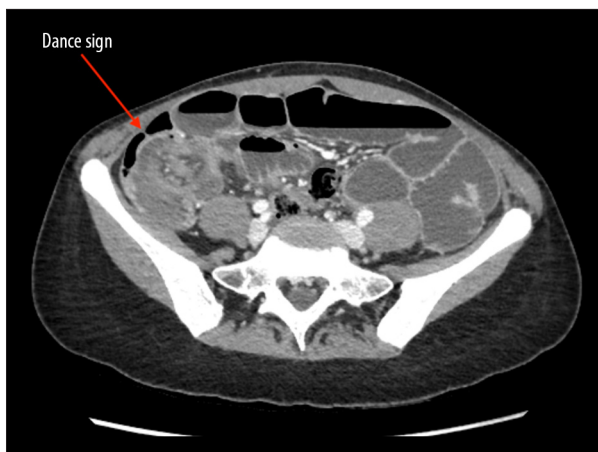**Figure 1.** Initial computed tomography scan. Severe gastric distention associated with a severe distention of the jejunum and ileum.



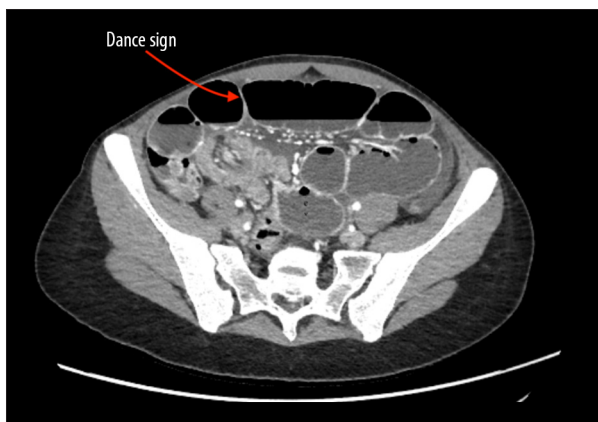
**Figure 2.** Initial computed tomography scan. Distention is noted up to the height of the right iliac fossa where a small bowel in small bowel invagination is visualized. The intestinal wall remains vascularized with a notable amount of pelvic ascites.

follows: pulse 88 beats per minute; saturation 100%; temperature 36.5°C; blood pressure 140/70 mm Hg. Laboratory samples drawn in the Emergency Department showed mildly elevated white blood cells (Table 1). An abdominal computed tomography (CT) scan was done and revealed severe gastric distention associated with a severe distention of the jejunum and ileum. Distention was noted up to the height of the right iliac fossa where a small bowel in small bowel invagination was visualized. The intestinal wall remained vascularized with a notable amount of pelvic ascites. Severe intestinal obstruction was noted in the area of intussusception (Figures 1, 2).

Following this imaging result, a nasogastric tube was introduced for decompression, which yielded 400 mL of yellowish secretions directly after insertion. The patient was then admitted to the ward for observation in hope that the obstruction



**Figure 3.** Repeat computed tomography scan following worsening of initial symptoms. Severe intestinal obstruction is noted in the area of intussusception.



**Figure 4.** Repeat computed tomography scan following worsening of initial symptoms. Severe intestinal obstruction is noted in the area of intussusception.

would resolve. She was kept NPO (nothing by mouth) and was given antibiotics and analgesics for pain control.

After 24 hours the symptoms persisted with 500 mL of secretions drawn from the nasogastric tube, as well as a notable increase in pain. A control scan was done and revealed a persistence of the small bowel obstruction. All of the bowel loops were dilated, filled with liquid, and showed air-fluid levels. The ileal intussusception was visible and 10 cm in length, with the distal part of the invagination entering the cecum. The walls of the invaginated loop were thickened and there was free liquid noted, but no pneumoperitoneum (Figures 3, 4).

The patient was then transferred to the operating room. Due to the extent of the dilation of small bowel, it was decided to begin the exploration by laparotomy instead of laparoscopy. An approximately 10 cm McBurney incision for the laparotomy was made at the level of the right iliac fossa.

Upon exploration, an ileo-ileo-cecal intussusception was found. Given the presence of this significant invagination, the mesentery was shortened which made mobilization of the ileo-cecal region outward difficult. Reduction of the intussusception was not possible so ileo-cecal resection was performed, and 10 cm of the ileum as well as half of the right colon were resected. It was decided to perform an isoperistaltic latero-lateral anastomosis. The anastomosis was ileo-ascending and was stapled. A thorough investigation of the small bowel was performed looking for additional lesions or a possible lead point as the cause of this intussusception, but the entirety of the small bowel was normal.

On the first postoperative day the patient was stable, reporting only mild pain; 100 cc of serous fluid was noted in the drain and the nasogastric tube produced 150 cc of fluid as well. On the third postoperative day the nasogastric tube was removed. The patient gave flatus on the fourth postoperative day and a soft diet was started. The drain was removed on the seventh postoperative day and the patient was discharged soon after.

Samples of the small intestine were sent to pathology which reported mucosa whose villi are long, thin, and coated with a non-atypical epithelium. The chorion was congestive, with hemorrhage noted in the submucosa. In terms of the intussusception, focal ischemic necrosis of the mucosa was observed with replacement by a fibrin-leucocyte exudate. The submucosa was noted to be highly edematous and associated with congestion and a polymorphic inflammatory infiltrate. This infiltrate extended to the muscular layers and no signs of peritonitis were noted.

## Discussion

Barbettein was the first to describe intestinal invagination in 1674 [1]. Intestinal intussusception is defined as the penetration or telescoping of a segment of gastrointestinal tract into a distally situated segment. This may result in emergency complications such as strangulation or bowel obstruction. The incidence of intussusception is by far the highest in children, and represents only a minority of intestinal obstruction cases in adults, about 1–5% [2]. Within the invagination, an organic lesion is noted in about 90% of the cases, which acts as a lead point, dragging the proximal segment into the distal one.

The majority of these intussusceptions, up to 90%, occur within the small or large bowel. The most frequent region where they occur is within the ileum, with ileoileal intussusceptions being the most common. Double ileoileal and ileocecal intussusceptions are less frequent [2]. The other 10% may be seen in the stomach or within a stroma that is surgically created [3].

A large study was performed in 1954 looking at a total of 745 cases of intussusception that were surgically diagnosed. This study noted the locations of the invaginations. These cases were reviewed and showed that invaginations were entero-enteric in 39% of cases, ileocecal in 21% of cases, colocolic in 17% of cases, and ileocolic in 13% of cases. The duodenum, stomach, or stomata was involved in about 10% of cases [4,5]. Furthermore, the approximate male to female ratio was found to be about 2: 1 [6–8].

The lesions that act as lead points to the intussusceptions may be related to benign, malignant, or idiopathic processes [3,9]. In children, these are often idiopathic and many times a lead point is not found. However, adults often show malignant processes. In adults, even though the annual incidence is only 3 cases per 1 million inhabitants, a lead point or underlying cause is identified in 90% of cases [1]. Examples include small bowel tumors and pancreatic divisum. About 8% of intussusception cases of the small bowel are idiopathic with no identifiable lead point [8,10]. This was the case with our patient. The entirety of the small bowel and the abdomen were searched without finding any evidence of an etiology, which is a rarity especially in an adult patient. Furthermore, other potentially contributing disease processes, such as abnormal peristalsis or thyroid abnormalities, were absent as well.

In a review by Felix et al., 63% of cases were noted as tumor related intussusceptions [11]. Intussusception has also been noted in patients with abdominal trauma and tropical sprue/ celiac disease. It has even been noted to occur in the postoperative period [11–13]. In addition, intussusception has a higher rate of occurrence in patients with acquired immunodeficiency syndrome (AIDS) related gut disease [14,15]. All were absent in our patient.

In terms of the presenting symptoms, they are usually non-specific in adult patients with intussusception. Pain is by far the most common symptom as it is present in 71% to 90% of patients. Following pain, other presenting symptoms include rectal bleeding and vomiting which are the next most common [9]. In our patient's case, symptoms were typical of those seen with obstruction. Furthermore, in about 10% of cases, an abdominal mass is noted on physical examination [8].

The diagnosis of intussusception can often be made prior to surgery, but often laparotomy is required. Thirty patient cases were reviewed by Morera-Ocón et al. in 2009. They reported making the diagnosis of intussusception in 83% of the cases

prior to surgery [4]. Laboratory studies are non-significant in this condition unless ischemia or perforation of the small bowel are present [16]. Diagnosis is often made by imaging. According to reported studies, diagnosis can be made by ultrasound in 33% of cases [17]; plain radiographs in 60% of cases [18]; barium enema in 36% of cases [8,17]; and CT scan in 72% of cases [7,8,17]. The classic donut or target sign may sometimes be demonstrated on ultrasound. This can sometimes be difficult to view due to excessive dilation of the bowels [6,18]. Three patterns are often demonstrated on CT scan. These include the target lesion (as was seen in our case), a sausage mass with layers, and a reniform mass that occurs due to edema, mural thickening, and ischemia [6,18].

The use of laparotomy is more exigent for adult cases of intussusception and is used more so than hydrostatic reduction because of the increased incidence of underlying abnormalities [8]. Some reports advocate for attempted reduction of the intussusception before resection is performed [5,19]. However, Azar et al. preferred to not reduce prior to resection [20]. Reduction was not possible for our patient. The management of intussusception by laparoscopy in adults is feasible, and can be done for both small bowel [21,22] and large bowel cases [23,24]. However, as in our case, when the small bowel was severely dilated, laparotomy was referred. A similar approach for ileocecal or colocolic intussusception with colon cancer resection by laparoscopy is founded regardless of the pathology [6].

## Conclusions

Intussusceptions, though rare in adults, are important to consider in cases of small bowel obstruction. Furthermore, even though an organic lead point, such as a small bowel tumor, is almost always found, here we report a case in which surgical exploration yielded no such finding. Other conditions, such as thyroid abnormalities and problems of peristalsis, may also be potential causes of intussusception and should be ruled out as well. In addition, it is important to notice the degree of distention caused by the obstruction as it can determine the surgical approach to exploration and decompression. Severe distention makes laparoscopy risky and laparotomy the recommended course of action.

## Conflict of interest

None.

## References:

1. Alonso V, Targarona EM, Bendahan GE et al: [Laparoscopic treatment of intestinal intussusception in adults]. *Cir Esp*, 2003; 74: 46–49 [in Spanish]
2. Vázquez R, Poletto DJ, Moreno MT et al: Ileoileal and ileocecal intussusception due to ileal lipoma: A rare cause of bowel obstruction in the adult. *Rev Gastroenterol Mex*, 2018; 83(4): 457–59
3. Stubenbord WT, Thorbjarnarson B: Intussusception in adults. *Ann Surg*, 1970; 172(2): 306–10
4. Morera-Ocón FJ, Hernández-Montes E, Bernal-Sprekelsen JC: [Intestinal invagination in adults: Presentation of a case and a review of the Spanish literature]. *Cir Esp*, 2009; 86: 358–62 [in Spanish]
5. Brayton D, Norris WJ: Intussusception in adults. *Am J Surg*, 1954; 88(1): 32–43
6. Donhauser JL, Kelly EC: Intussusception in the adult. *Am J Surg*, 1950; 79(5): 673–77
7. Toso C, Erne M, Lenzlinger PM et al: Intussusception as a cause of bowel obstruction in adults. *Swiss Med Weekly*, 2005; 135: 87–90
8. Azar T, Berger DL: Adult intussusception. *Ann Surg*, 1997; 226: 134–38
9. Reijnen HA, Joosten HJ, De Boer HH: Diagnosis and treatment of adult intussusception. *Am J Surg*, 1989; 158: 25–28
10. Felix EL, Cohen MH, Bernstein AD et al: Adult intussusception: Case report of recurrent intussusception and review of the literature. *Am J Surg*, 1976; 131: 758–61
11. Brooks A, Bebington BD, Lucas S et al: Intussusception caused by blunt abdominal trauma. *J Trauma*, 1999; 47: 156–57
12. Eke N, Adotey JM: Post-operative intussusception, causal or casual relationship? *Int Surg*, 2000; 85: 303–8
13. Dannin JC, McCarty M, Coker R: Case report: lymphoma causing small bowel intussusception in a patient with the acquired immune deficiency syndrome. *Clin Radiol*, 1992; 46: 350–51
14. Meyerson S, Desai TK, Polidori G et al: A case of intussusception and lymphoid hyperplasia in a patient with AIDS. *Am J Gastroenterol*, 1993; 88: 303–6
15. Nagorney DM, Sarr MG, McIlrath DC: Surgical management of intussusception in the adult. *Ann Surg*, 1981; 193: 230–36
16. Tan KY, Tan SM, Tan AG et al: Adult intussusception: experience in Singapore. *Aust NZJ Surg*, 2003; 73: 1044–47
17. Byrne AT, Goeghegan T, Govender P et al: The imaging of intussusception. *Clin Radiol*, 2005; 60: 39–46
18. Gayer G, Zissin R, Apter S et al: Adult intussusception – a CT diagnosis. *Br J Radiol*, 2002; 75: 185–90
19. Hutchinson J: A successful case of abdominal section for intussusception. *Proc R Med Chir Soc*, 1873; 7: 195–98
20. Alonso V, Targarona EM, Bendahan GE et al: Laparoscopic treatment for intussusception of the small intestine in the adult. *Surg Laparosc Endosc Percutan Tech*, 2003; 13: 394–96
21. Chiu CC, Wei PL, Huang MT et al: Laparoscopic treatment of ileocecal intussusception caused by primary ileal lymphoma. *Surg Laparosc Endosc Percutan Tech*, 2004; 14: 93–95
22. Park KT, Kim SH, Sony TJ, Moon HY: Laparoscopic-assisted resection of ileal lipoma causing ileo-ileo-colic intussusception. *J Korean Med Sci*, 2001; 16: 119–22
23. Hacham DJ, Saibil F, Wilson S, Litwin D: Laparoscopic management of intussusception caused by colonic lipomata: A case report and review of the literature. *Surg Laparosc Endosc*, 1996; 6: 155–59
24. Yamaguchi S, Fujii S, Ike H, Shimada H: Laparoscopic reduction of appendiceal intussusception due to mucinous cystadenoma in an adult. *JLS*, 2004; 8: 279–82