

Keratoacanthoma versus invasive squamous cell carcinoma: a comparison of dermatoscopic vascular features in 510 cases

John H. Pyne¹, Graham Windrum¹, Devendra Sapkota¹, Jian Cheng Wong²

¹ School of Medicine, University of Queensland, Brisbane, Australia

² School of Mathematics and Statistics, The University of New South Wales, Sydney Australia

Keywords: keratoacanthoma, invasive squamous cell carcinoma, vessels, vascular, dermatoscopy

Citation: Pyne JH, Windrum G, Sapkota D, Wong JC. Keratoacanthoma versus invasive squamous cell carcinoma: a comparison of dermatoscopic vascular features in 510 cases. *Dermatol Pract Concept*. 2014;4(3):6. <http://dx.doi.org/10.5826/dpc.0403a06>

Received: January 7, 2014; **Accepted:** May 17, 2014; **Published:** July 31, 2014

Copyright: ©2014 Pyne et al. This is an open-access article distributed under the terms of the Creative Commons Attribution License, which permits unrestricted use, distribution, and reproduction in any medium, provided the original author and source are credited.

Funding: None.

Competing interests: The authors have no conflicts of interest to disclose.

All authors have contributed significantly to this publication.

Corresponding author: John Pyne, MBBS, BOptom, MMed, PhD, 131 Ellesemere Rd, GyMEA Bay, NSW Australia. Tel. 61.414.750625; Fax. 61.2.95253193. Email: j.pyne@uq.edu.au

ABSTRACT Introduction: Keratoacanthoma (KA) and invasive squamous cell carcinoma (SCC) are keratinocytic tumors displaying vascular features, imaged using dermatoscopy.

Objective: Compare the dermatoscopy vascular features of KA to SCC.

Methods: This prospective study examined consecutive cases of 100 KA and 410 invasive SCC in a single private practice in Sydney, Australia. Vascular features were recorded *in vivo* direct from patients using a non-polarized Delta 20 Heine dermatoscope. These vascular features were: linear, branching, serpentine, hairpin, glomerular and dot vessels, the presence or absence of large diameter tumor vessels, vessel presence in central versus peripheral tumor areas and tumor pink areas in different proportions. Following full excision, all cases were submitted for histopathologic diagnosis.

Results: Branching vessels were the only vessel morphology that varied, with a significant incidence in KA (25.0%), compared to SCC (10.7%), $P < 0.01$. Large vessels were identified in 20.0% of KA, compared to 12.4% in SCC, $P = 0.05$. No vessels were observed in the central tumor areas in 43.4% of KA compared to 58.0% of SCC, $P = 0.01$. Other data comparing the central versus peripheral tumor areas for vessels present did not reveal any distinctive associations. There were no significant differences between KA and SCC when reviewing the selected proportions of pink within the tumor.

Limitations: The vascular features may be confounded by tumor depth in KA. Polarized dermatoscopy may not produce the same findings.

Conclusion: This study found branching vessels to have a higher incidence in KA compared to invasive SCC. Although not statistically significant, large diameter vessels were also more frequent in KA. Proportions of pink within the tumor or central versus peripheral tumor vessel distribution were not useful diagnostic features separating KA from SCC using dermatoscopy.

Introduction

KA and invasive SCC are both common keratinocytic tumors. KA can be thought of as a variant of well-differentiated SCC, capable of spontaneous regression [1]. However, other authors have challenged this concept [2]; some consider KA a benign entity [3]. Different histopathologic subtypes of KA have been proposed [4]. Keratoacanthoma rarely metastasizes to lymph nodes [5]; and rarely undergoes perineural [6,7] or venous invasion [8]. The characteristic rapid growth, maturation, and involution of KA are not typical behaviors for well-differentiated invasive SCCs. Invasive SCC is at risk of metastasizing with increasing tumor depth and a shift toward poor differentiation, among other factors.

The various clinical, dermatoscopic [9,10], and histopathologic features of KA and SCC overlap. Dermatoscopy features of keratinization are more reliable than vascular features in diagnosing KA and SCC [9]. Pigmented SCC [11] and pigmented keratoacanthoma [12] are rare; thus, pigmented dermatoscopy features are not useful for routine dermatoscopic guided diagnosis to confirm these tumors. There are no histologic findings proven to predict biologic behavior in KA [13]. Acantholysis can occur in SCC and when identified, has been stated to exclude keratoacanthoma [14]. Various biochemical markers have not been found to provide a pathognomonic distinction between KA and SCC. This study examined dermatoscopically identified vascular features comparing KA to SCC.

Methods: The setting for the study was a single private practice in Sydney, Australia. Data collection ran from 2009 until 2011.

Inclusion criteria: All patients examined within the study time window were considered for inclusion in the study. All cases required full excision down to fat, prior to submission for routine histopathologic assessment. All cases accepted into the study had histopathologic confirmation as either KA or invasive SCC.

Exclusion criteria: Any previous surgical or topical medical intervention on the site of the excision resulted in exclusion. Medical intervention included field effect photodynamic therapy, or localized radiotherapy. Sites juxtaposed to scars or tattoos were excluded. Collision situations between either a KA or SCC, and any other diagnostic entity based on clinical, dermatoscopy, or histopathology evidence were also excluded. Cases of SCC *in situ* without any invasion were excluded. Tumors were collected from all presenting body sites. There were no exclusions based on body site.

Definition of vessel morphologies: The vessel morphologies chosen are all established and well known in the published literature on dermatoscopy. Serpentine vessels are equivalent to linear-irregular vessels. However, the vast majority of this published work (on these vessel morphologies) is on entities that are neither KA nor invasive SCC.

Definition of large “thick” vessels: A large vessel was defined as a dermatoscopically identified blood-filled vessel within the tumor “footprint”, with a diameter greater than the diameter of any visible vessels in the area, from the circumferential tumor margin out to a distance of 10mm. This assessment was qualitative, rather than done by actual physical measurement. Thus, the method was chosen as it was rapid, easy to perform, reproducible, and may be relevant in practice.

Definition of central and peripheral tumor vessels: Each tumor was divided into a central area (with a width of half the tumor diameter) and remaining peripheral area, adjusted for the tumor shape. The central and peripheral tumor areas were then divided into quadrants by horizontal and vertical axes. Vessels were recorded as present in any quadrant when one or more vessels of any morphology were observed within that quadrant.

Definition of the proportion of pink in a tumor area: The presence of pink within a tumor was recorded as either: no pink within the tumor area, pink less than half the tumor area or pink equal to half or more of the tumor area. Pink areas could be any shape or intensity within the tumor margin.

Collection of the dermatoscopy vascular data for each case was recorded direct from each patient, using a Delta 20 Heine dermatoscope, not photographs. To avoid compression on vessels, every case was examined with transparent ultrasound gel applied between the glass plate of the dermatoscope and the tumor. Validation of the vascular features was assessed by comparing the recording of two observers (JP and DS). Each observer was blinded to the other observer’s recording. Concordance between the observers’ records was checked by calculating Kappa values on 67 consecutive cases. Histopathologic diagnosis of each case was performed by one of five pathologists, using routine hematoxylin and eosin staining. This study was approved by the Ethics Committee of the University of Queensland.

Results: Branching vessels were identified in 25.0% of KA (n=100), compared to 10.7% of SCC (n=410), $P < 0.01$. Figure 1 provides an example of branching large diameter vessels

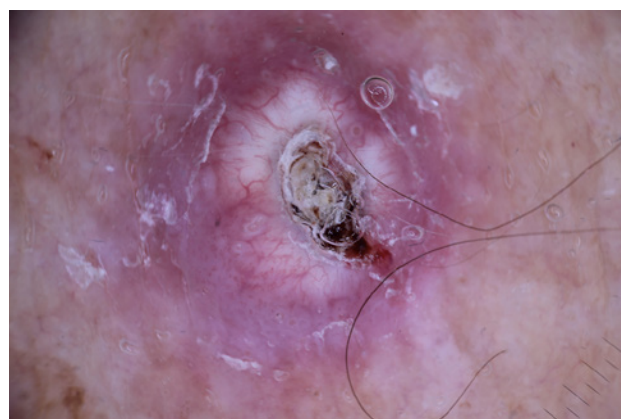

Figure 1. KA: non-polarized dermatoscopy image taken with a Dermfoto dermatoscope displaying large diameter branching vessels around a central keratin plug. [Copyright: ©2014 Pyne et al.]

in a dermatoscopy image of a KA. Large vessels occurred in 20.0% of KA, compared to 12.4% of SCC ($P=0.05$). Figure 2 is a dermatoscopy image of an SCC; branching and large diameter vessels are not seen. Recorded vessel morphologies comparing SCC with KA are set out in Figure 3. See also Figures 4 and 5.

The inter observer Kappa values for the vascular features are summarized in Table 1.

Discussion

Data from this study found that only branching vessels were significantly different when comparing the two entities. This limited finding is consistent with the concept that vessels are not as useful as keratin features in the differential diagnosis process, supporting findings from earlier studies [9]. While branching vessels may be a feature of some KA, an increased incidence of branching vessels has also been reported as associated with well-differentiated SCC of increasing tumor

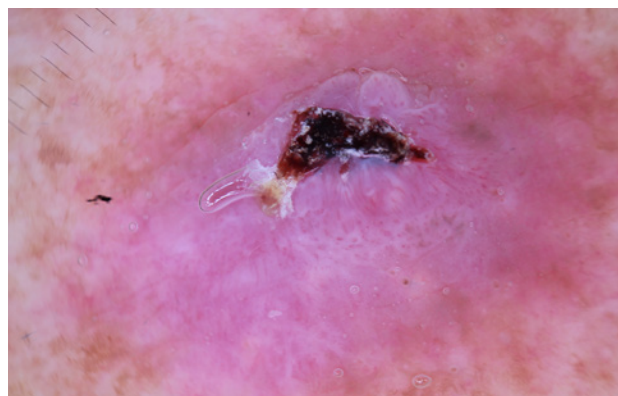


Figure 2. SCC: non-polarized dermatoscopy image taken with a Dermfoto dermatoscope displaying peripheral hairpin or loop and dot vessels. Vessels do not display large diameters or branching morphology. [Copyright: ©2014 Pyne et al.]

depth, and SCC with a shift toward poor differentiation [15]. Limitations of this study include the possibility of the confounding effect of including SCC cases with increased tumor

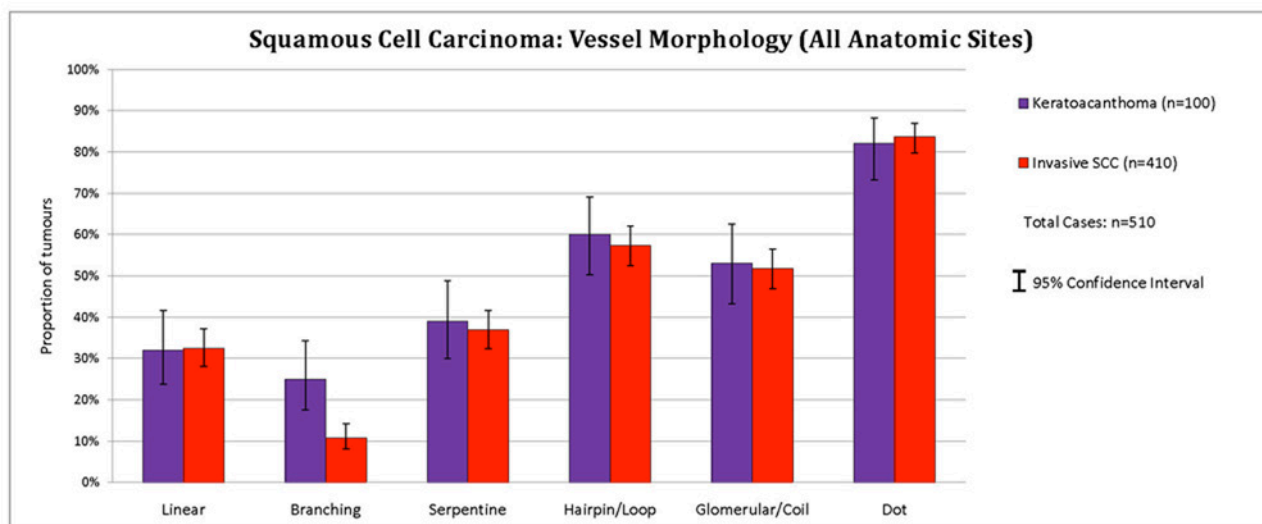


Figure 3. SCC: vessel morphologies of SCC compared with KA. [Copyright: ©2014 Pyne et al.]

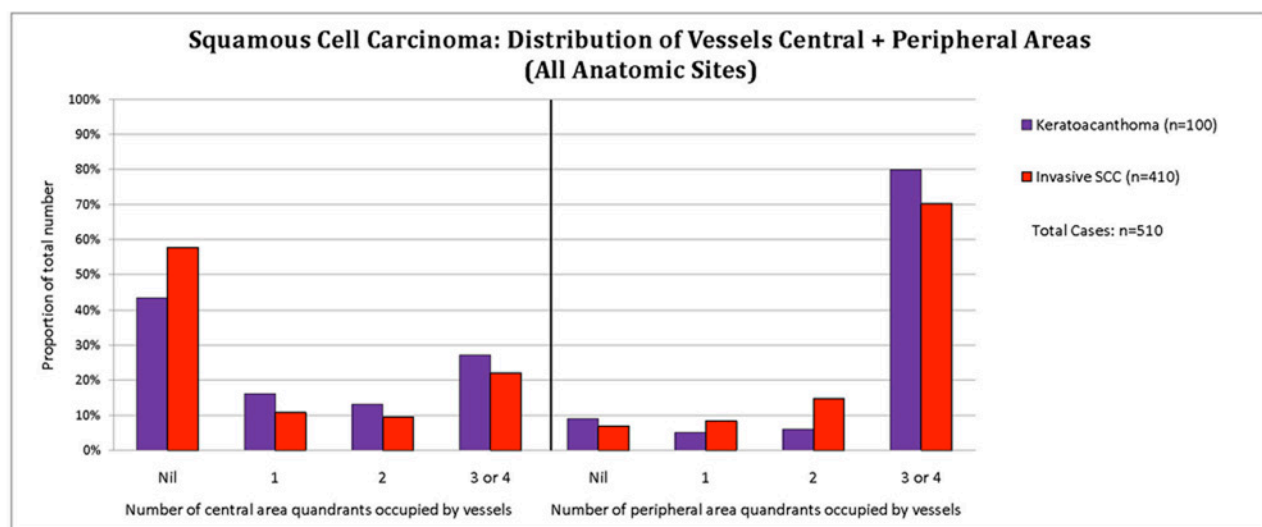


Figure 4. SCC: distribution of vessels in the central and peripheral tumor areas compared with KA. No distinctive associations are seen. [Copyright: ©2014 Pyne et al.]

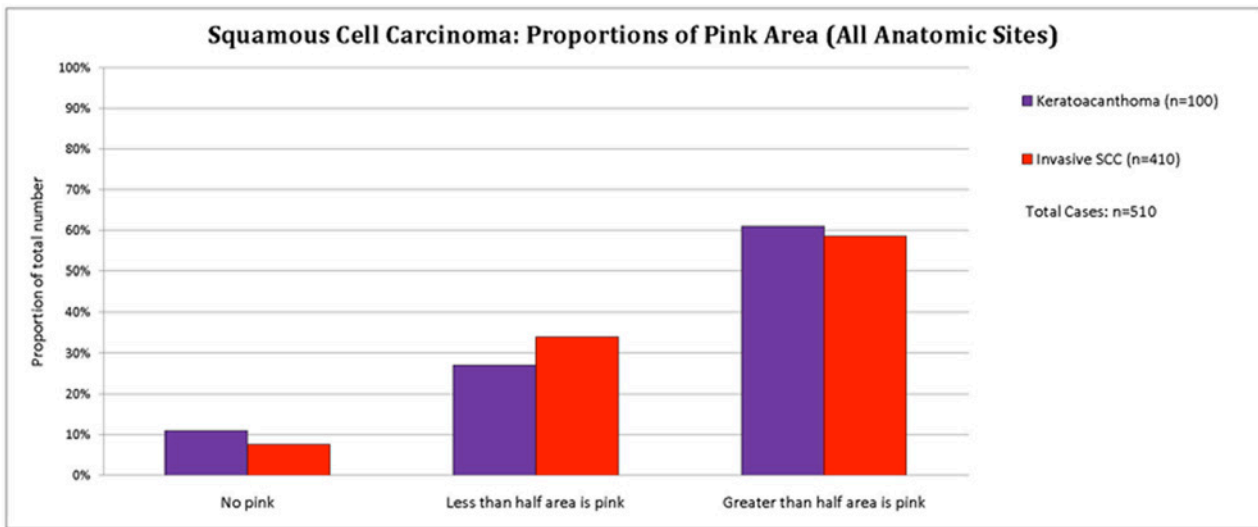


Figure 5. SCC: proportions of pink area within the tumor compared with KA. Pink areas were assessed using a Pearson Chi Square test. No association was demonstrated, $P > 0.1$. [Copyright: ©2014 Pyne et al.]

TABLE 1. Kappa values of the vascular features. Agreement between two observers. [Copyright: ©2014 Pyne et al.]

Vessel Feature	Kappa Value	Confidence Interval 95%
Linear	1.00	1.00 – 1.00
Branching	0.87	0.81 – 0.94
Serpentine	0.69	0.56 – 0.82
Loop	0.71	0.61 – 0.81
Coil	0.80	0.70 – 0.90
Dot	0.60	0.47 – 0.74
Large	0.94	0.87 – 1.00
Central	0.95	0.90 – 1.00
Peripheral	0.88	0.75 – 1.00
Pink Areas	0.83	0.71 – 0.95

depth, and or moderate, or poor differentiation. Branching vessels were observed in 10.7% of the 410 SCC cases in this study (well, moderate or poorly differentiated tumors combined), a subset of 294 consecutive cases were assessed for branching vessels in a separate study [15]. In this separate study [15] branching vessels were noted in 7.5% of well-differentiated SCC (n=255) and 28.2% of moderate or poorly differentiated SCC (n=39). The significance of branching vessels in a radial pattern [9] combined with prominent keratin expression as clues to KA is worthy of more investigation. The irregular arrangement of branching vessels in poorly differentiated SCC has yet to be quantified.

Although not highly statistically significant, vessels with large diameters were more frequent in KA, compared to

SCC. Data from the central versus peripheral areas presence of vessels and the selected proportions of pink areas within the tumor did not show any highly significant differences between KA and SCC. Other vascular features such as vessel polymorphism, the spatial arrangement of vessels and vessel density (vessels per unit area) could be additional areas for future investigation.

In practice, as well as keratin features, the symmetry and growth rate of a lesion may be other clues to resolving the differential diagnosis of KA versus SCC. Anecdotal observation by the authors during this study noted these large diameter vessels seemed more prevalent, with larger and thicker KAs. Future study may examine if there is a relationship between increasing tumor depth and variation in vascular features in KA.

Conclusion

Branching and large diameter vessels were found to have a higher incidence in KA, compared to invasive SCC. In practice, facilitating this dermatoscopy differential diagnosis relies on additional clinical and dermatoscopic features, for example rapid growth and lesion *circular* symmetry favor KA.

References

1. Beham A, Requare S, Soyer HP, et al. Keratoacanthoma: a clinically distinct variant of well differentiated squamous cell carcinoma. *Adv Anat Pathol.* 1998;5(5):269–80.
2. Weedon D, Malo J, Brooks D, et al. Keratoacanthoma: is it really a variant of squamous cell carcinoma? *ANZ J Surg.* 2010;80(3):129–30.
3. Ko CJ. Keratoacanthoma: facts and controversies. *Clin Dermatol.* 2010;28(3):254–61.
4. Misago N, Inoue T, Koba S, Narisawa Y. Keratoacanthoma and other types of squamous cell carcinoma with crateriform

- architecture: Classification and identification. *J Dermatol*. 2013; 40(6):443-52.
5. Pisciole F, Boi S, Zumiani G, et al. A gigantic metastasizing keratoacanthoma. *Am J Dermatopathol*. 1984;6:123-9.
 6. Petrie M, Eliezri Y, Campanelli C. Keratoacanthoma of the head and neck with perineural invasion: incidental finding or cause for concern? *Dermatol Surg*. 2010;36(7):1209-13.
 7. Godbolt AM, Sullivan JJ, Weedon D. Keratoacanthoma with perineural invasion: a report of 40 cases. *Australas J Dermatol*. 2001;42(3):168-71.
 8. Tschandl P, Rosendahl C, Williamson R, Weedon D. A keratoacanthoma with venous invasion. *Dermatol Pract Concept*. 2012;2(4):3. <http://dx.doi.org/10.5826/dpc.0204a03>
 9. Rosendahl C, Cameron A, Argenziano G, et al. Dermoscopy of squamous cell carcinoma and keratoacanthoma. *Arch Dermatol*. 2012;148(12):1386-92.
 10. Zalaudek I, Giacomel J, Schmid K, et al. Dermoscopy of facial actinic keratosis, intraepidermal carcinoma and invasive squamous cell carcinoma: a progression model. *J Am Acad Dermatol*. 2012;66(4):589-97.
 11. Rosendahl C, Cameron A, Bulinska A, et al. Cutaneous pigmented invasive squamous cell carcinoma: a case report with dermoscopy and histology. *Dermatol Pract Concept*. 2011;1(1):14. <http://dx.doi.org/10.5826/dpc.0101a14>
 12. Zalaudek I, Giacomel J, Leinweber B. Squamous cell carcinoma including actinic keratosis, Bowens disease, keratoacanthoma and its pigmented variants. In: Soyer HP, Argenziano G, Hofmann Wellenhof R, Jorh, RH (eds.). *Color Atlas of Melanocytic Lesions of the Skin*. Berlin: Springer; 2007:295-302.
 13. Chartier M, Rothe MJ, Grant-Kels JM. Keratoacanthoma. In: Rigel D, Friedman RJ, Dzubow LM, et al. (eds.). *Cancer of the Skin*. Philadelphia: Elsevier, 2005:395-409.
 14. Elston DM. Malignant tumors of the epidermis. In: Elston DM, Ferringer T, Ko CJ, et al. (eds.). *Dermatopathology*. 2nd ed. Edinburgh: Elsevier, 2014:56-70.
 15. Pyne JH, Sapkota D, Wong JC. Squamous cell carcinoma: variation in dermoscopic vascular features between well and non-well differentiated tumors. *Dermatol Pract Concept*. 2012;2(4):5. <http://dx.doi.org/10.5826/dpc.0204a05>