

Umbilical Quilting Suture Technique during Single-Port Laparoscopic Surgery

Jung Woo Chang, MD, Jeongseok Oh, MD, Un Suk Jung, MD, PhD

ABSTRACT

Background and Objectives: Single-port laparoscopic surgery (SPLS) is popular in the gynecological field, because it is less invasive and leaves a smaller scar. However, the postoperative shape of the umbilicus is often distorted due to the intensive procedures performed through the small opening. In this report, we describe a technique for forming a satisfactory umbilicus in SPLS.

Methods: From March 2016 through April 2017, 32 patients were treated with SPLS by a single gynecologic surgeon. Group A (14 cases) underwent conventional umbilicus closure, and group B (18 cases) underwent a quilting suture technique. The umbilical shapes of each group were assessed by a plastic surgeon as was the patients' satisfaction. Evaluations were performed immediately after surgery and every month for 6 months thereafter.

Results: The postoperative umbilical shape in group A showed features, such as loss of depression, disappearance of the central vertical line, and irregularly bulging tissue, whereas group B had a shape similar to that of the natural umbilicus and maintained its depression and vertical line. The average scores of the plastic surgeons' evaluations immediately after the operation were 10.4 for group A and 15.1 for group B. The final scores obtained 6 months after surgery were 15.2 and 17.8, respectively. The patients' satisfaction scores immediately after the operation were 4.9 for group A and 7.3 for group B. The scores

increased gradually, to 8.1 and 9.2, respectively, at 6 months after surgery.

Conclusion: Performing quilting sutures during wound closure in SPLS is effective for making an ideal umbilicus and ensuring patients' satisfaction.

Key Words: Quilting suture, Single-port laparoscopic surgery, Umbilicoplasty.

INTRODUCTION

Single-port laparoscopic surgery (SPLS) is currently a popular option in gynecologic surgery. It allows operations to be less invasive and provides a cosmetic advantage, because only a single small scar remains. This scar is markedly shorter than that associated with classic laparotomy, and it is usually hidden within the umbilicus, because the entry of the single trocar is through the umbilicus.¹⁻³ The cosmetic advantage is appealing to gynecologic patients, especially to young women, and the demand for SPLS is increasing.⁴⁻⁶

Although the scar is small, patients often complain about the shape of their umbilicus after the operation. The immediate postoperative shape of the umbilicus is not ideal. Intensive procedures are performed through the small opening within the umbilicus, and the shape of the umbilicus usually becomes distorted after the operation. Typically, the depressed vertical line disappears, and irregularly bulging tissue is observed around the incision line. These are the main features that cause dissatisfaction.

To obtain more advanced results from SPLS, surgeons should not overlook the postoperative shape of the umbilicus. Herein, we introduce our experience of making an ideal umbilicus by a quilting suture technique during SPLS.

MATERIALS AND METHODS

This study was conducted in conformity with the World Medical Association Declaration of Helsinki. This study was approved by the Institutional Review Board of Hanyang university Guri hospital. From March 2016 through April 2017, 32 gynecologic patients were treated with SPLS

Department of Plastic and Reconstructive Surgery (Drs Chang and Oh) and Department of Obstetrics and Gynecology (Dr Jung), Hanyang University Guri Hospital, Hanyang University College of Medicine, Guri, Korea.

Disclosures: none reported.

I thank my friend, Yang Jun Ho (CEO, Odinue corp, Seoul, Republic of Korea) for his assistance in our research.

Address correspondence to: Un Suk Jung, MD, PhD, Department of Obstetrics and Gynecology, Hanyang University Guri Hospital, Hanyang University College of Medicine, 153, Gyeongchun-ro, Guri-si, Gyeonggi-do 11923, Republic of Korea. Telephone: +82-31-560-2346, Fax: +82-2-31-560-2402, E-mail: petrow@naver.com.

DOI: 10.4293/JSLS.2017.00088

© 2018 by JSLS, Journal of the Society of Laparoendoscopic Surgeons. Published by the Society of Laparoendoscopic Surgeons, Inc.

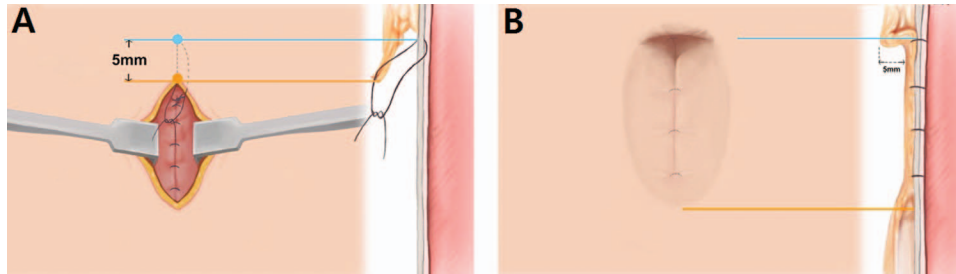


Figure 1. The quilting suture technique. The sutures are placed between the subcutaneous skin flap and the underlying fascia. **(A)** The most cephalad point is fixed on the fascia 5 mm higher in the cephalad direction to make a T-shaped edge. **(B)** The quilting is performed with 4 suture points in a cephalad-to-caudal fashion, to make a natural depression.

Table 1.
Demographics of the Patients

Variables	Group A	Group B	P
Patients, n	14	18	
Age, years			.382*
Mean	35.5	37.3	
Range	19–48	15–55	
BMI, kg/m ²			.754*
Mean	24.3	23.9	
Range	18.2–30.1	14.6–31.8	
Operative time, min			.156 [†]
Mean	85.8	86.1	
Range	84–94	70–100	

Group A vs Group B, by **t*-test and [†]Mann-Whitney test. BMI, body mass index.

by a single gynecologic surgeon. After the operation, a plastic surgeon evaluated the shape of the umbilicus. The evaluation was performed immediately after surgery, and each month for 6 months thereafter. At the same time, patients' satisfaction with the shape of their umbilicus was assessed. Patients who underwent prior surgery through the umbilicus were excluded from this study, as were those who refused to undergo follow-up.

The patients were divided into 2 groups: group A and group B. Gynecologic surgeries were performed in same manner in both groups. The single port was inserted through a vertical incision through the umbilicus, and laparoscopic surgeries were performed. There was no difference among the patients in the incision length in the umbilicus. When a large specimen had to be extracted through the umbilical incision, the specimen was always morcellated before extraction. When suturing the umbilical incision site at the end of the operation, group A

underwent wound closure in the classic manner; The fascia and the subcutaneous tissue were both closed with simple interrupted sutures in a layer-by-layer fashion, and the skin was closed with topical adhesive (2-octyl cyanoacrylate, Dermabond; Ethicon, Inc., Somerville, NJ, USA).

Group B underwent wound closure with a new suture technique. After the fascia was closed with simple sutures, the subcutaneous layer was closed with quilting sutures (**Figure 1**). The quilting sutures (2-0 polyglactin, Vicryl; Ethicon, Inc.) were placed in the subcutaneous skin flap and then through the underlying fascia to make a natural depression. The quilting was performed with 4 points of suturing in a cephalad-to-caudal fashion, and the most cephalad point was fixed on the fascia at a point 5 mm higher in the cephalad direction to make a T-shaped edge. After the quilting, the skin was closed with topical adhesive (2-octyl cyanoacrylate (Dermabond; Ethicon, Inc.). As a compressive dressing on the wound, mesh tulle (chlorhexidine acetate-coated mesh, Bactigras; Smith & Nephew, London, UK) was crumpled and fitted into the depression.

The outcome of the umbilical shape was assessed by a single plastic surgeon and in terms of the patient's own satisfaction. The plastic surgeon scored the shape of the umbilicus using a 20-point scale, on which a score of 20 points corresponded to an ideal umbilicus. The scale included 5 different aesthetic aspects: overall aesthetics, shape, scar, depth, and natural appearance. The plastic surgeon was blinded to the choice of closure method, and the assessment was performed on photographs of each patient. The photographs were shown in a randomized order to decrease the chance of bias. The patients' satisfaction was assessed by their responses to a questionnaire, on which a score of 10 points corresponded to the highest level of satisfaction.

Statistical analysis of the difference in the variables between the 2 groups was performed with the software IBM

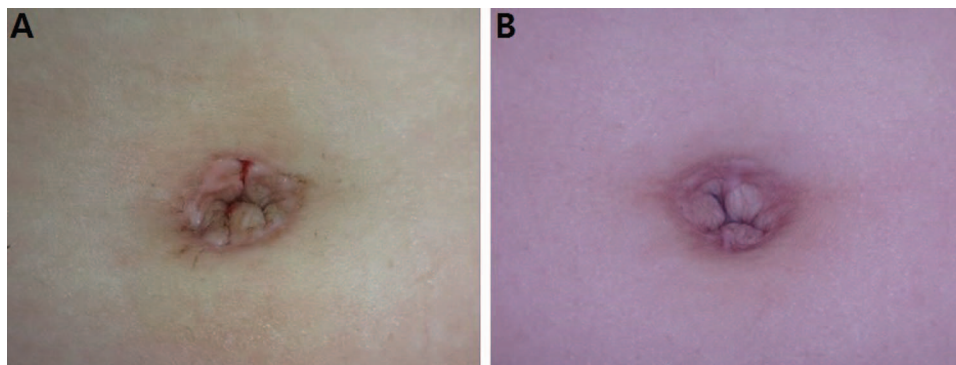


Figure 2. A 23-year-old patient underwent a single-port laparoscopic right salpingectomy for ectopic pregnancy, and the wound was closed by the conventional method. **(A)** The umbilicus immediately after surgery. **(B)** The umbilicus 6 months after surgery.

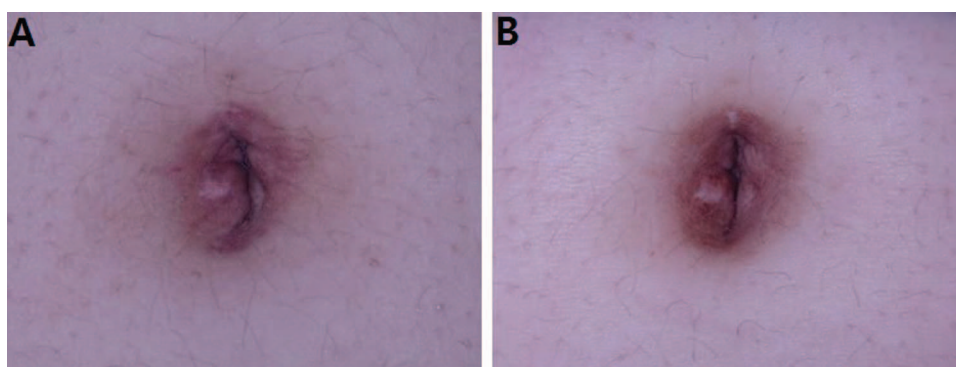


Figure 3. A 15-year-old patient underwent a single-port laparoscopic right ovarian cystectomy, and the wound was closed with the quilting suture technique. **(A)** The umbilicus immediately after surgery. **(B)** The umbilicus 6 months after surgery.

SPSS Statistics ver. 20.0 (IBM Corp., Armonk, NY, USA). Differences of $P < .05$ were considered statistically significant.

RESULTS

Among 32 cases, 14 cases were included in group A, which underwent the classic procedure, whereas 18 cases were included in group B, which underwent the new procedure. Patient's mean age and BMI and the operative time are given in **Table 1**. The mean body mass index (BMI) of each group was 24.3 (range, 18.2–30.1) and 23.9 (range, 14.6–31.8 kg/m²) kg/m². There was no difference in the operative time between the groups, which were 85.8 (range, 84–94) and 86.1 (range, 70–100) minutes, respectively (**Table 1**). No wound problems, such as dehiscence or infection within the umbilicus, were observed in either group.

However, the postoperative umbilical shape was markedly different between the groups. The typical shape of the umbilicus in group A included the following 3 fea-

Month	Group A	Group B	Gap
0	10.4	15.1	4.7
1	11.6	15.4	3.8
2	12.1	15.9	3.8
3	13.3	16.6	3.3
4	13.9	17.1	3.2
5	14.9	17.5	2.6
6	15.2	17.8	2.6

Maximum score, 20. $P < .05$, Group A vs Group B mean scores for all months, by Mann-Whitney test.

tures: loss of the depression, disappearance of the central vertical line, and irregularly bulging tissue (**Figure 2**). The overall shape became takes on a “cauliflower” appearance. In contrast, the typical shape of the umbilicus in group B was similar to the natural umbilical shape, with

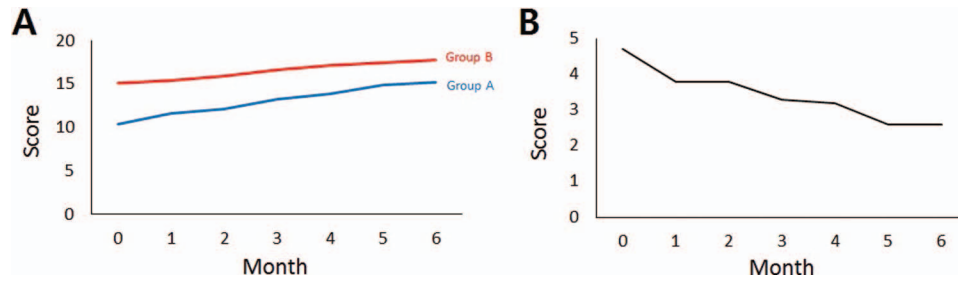


Figure 4. The average scores of the plastic surgeons' evaluations of the postoperative umbilical shape. **(A)** The average scores of the 2 groups at every follow-up period. **(B)** The score gap between the 2 groups at every follow-up period.

Table 3.

Mean Scores of the Patients' Satisfaction With Postoperative Umbilical Shape

Month	Group A	Group B	Gap
0	4.9	7.3	2.4
1	5.4	7.5	2.1
2	6.3	8.1	1.8
3	6.6	8.6	2.0
4	7.1	8.8	1.7
5	7.8	9.0	1.2
6	8.1	9.2	1.1

Maximum satisfaction score, 10. $P < .05$, Group A vs Group B mean scores for all months, by Mann-Whitney test.

the depression and central vertical line maintained (**Figure 3**).

The average scores of the plastic surgeons' evaluations immediately after the operations were 10.4 for group A and 15.1 for group B. The average scores increased gradually, and the final scores obtained 6 months after surgery were 15.2 and 17.8, respectively. In every follow-up period, the average score was significantly higher in group B ($P < .05$). During the 6 months, the evaluation scores increased by 4.8 in group A, whereas they increased by 2.7 in group B. The score gap between the 2 groups was 4.7 in the immediate postoperative evaluation and 2.6 at 6 months after surgery (**Table 2, Figure 4**).

The patients' satisfaction scores immediately after the operation were 4.9 for group A and 7.3 for group B, on average. The scores increased gradually, to 8.1 and 9.2, respectively, 6 months after surgery. In every follow-up period, the average score was significantly higher in group B ($P < .05$). The score increased by 3.2 in group A, whereas it increased by 1.9 in group B during

the 6-month follow-up period. The score gap between the 2 groups was 2.4 in the immediate postoperative period, and 1.1 at 6 months after surgery (**Table 3, Figure 5**).

DISCUSSION

Laparoscopic surgery has been shown to have many advantages in the treatment of benign gynecologic diseases.¹ Furthermore, gynecologic surgeons have focused on decreasing the size and number of ports to ensure a minimally invasive approach. Recent developments in laparoscopic equipment and surgical techniques have led to the challenges of using a single abdominal incision in gynecologic surgery.² SPLS in gynecology has become a reasonable alternative to multiple-port laparoscopic surgery and is associated with comparable tissue injuries, better cosmesis, less postoperative pain, and a shorter recovery period.³ Of these advantages, the most noticeable benefit of SPLS may be cosmetic improvement, as it is performed via a hidden umbilical incision.^{4,5} Because scars can have psychological consequences, postoperative scar cosmesis is a critical concern of women, especially young women.⁶⁻⁸

Although SPLS has advanced cosmetic results, it cannot avoid the postoperative distortion of the umbilical shape. The interactions between multiple instruments through a small umbilical incision often cause soft tissue injury in the umbilicus, resulting in postoperative distortions. As patients now have demanding standards, this distortion often leads patients to complain and can even have psychological consequences.⁹

The ideal umbilicus has an appropriate, symmetric depression. It is a T- or vertical-shaped umbilicus with a superior hood or shelf.¹⁰⁻¹⁶ Typically, the distorted umbilicus after SPLS loses the ideal features. As the vertical incision line on the center becomes distorted, the umbili-

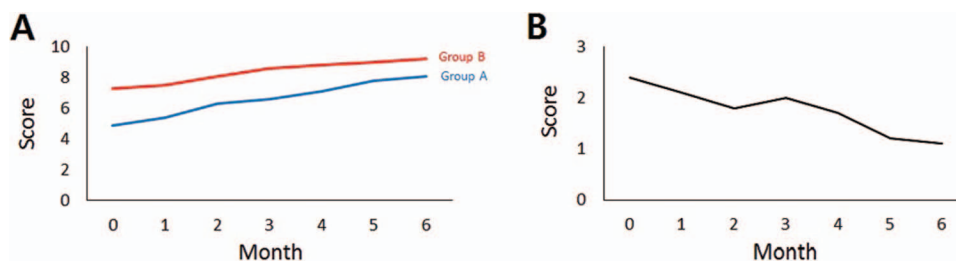


Figure 5. The average scores of the patients' satisfaction with the postoperative umbilical shape. (A) The average scores of the 2 groups at every follow-up period. (B) The score gap between the 2 groups at every follow-up period.

cus loses its symmetry.¹⁷ The cutaneous tissues around the incision line are macerated by instruments, and irregular bulging areas emerge within the umbilicus. Overall, the umbilicus has a cauliflower appearance, with a lack of depression. In early cases in our study period, we performed the classic procedure when closing the incision line. The postoperative umbilicus in these cases showed this typical appearance, and the cases were classified as group A.

After experiencing unsatisfactory results, we decided to apply the new technique, and the patients in these later cases who underwent the new procedure were classified as group B. To overcome postoperative distortion, quilting sutures on the incision site are needed during wound closure.^{8,18,19} Anchoring the skin flap on the underlying fascia provides a depressed vertical line on the center of the umbilicus, whereas the conventional wound closure procedure without quilting sutures does not guarantee a straight vertical line and the presence of a definite depression within the umbilicus. As the center line is fixed straight on the underlying fascia, the tissues around the incision line do not bulge. When performing the quilting sutures, 4 points of fixation are appropriate, because the incision site is not very long. The most cephalad point should be fixed on the fascia 5 mm higher in the cephalad direction to make a cliff-like appearance on the cephalad portion of the depression. As the depression is cliff-like in the cephalad portion and elevates gradually in the caudal portion, the entire depression within the umbilicus becomes T-shaped.^{14,20} To maintain the ideal features of the umbilicus after surgery, a mild compression dressing should be applied to the central depression.^{6,10,14}

The results of the evaluations of the umbilical shape by the plastic surgeon were superior at every follow-up point in the group of patients who underwent quilting suturing. In the immediate postoperative phase, the average score gap between the groups was remarkably large, although it gradually decreased in the later postoperative period.

However, there was a clear gap, even at 6 months after the operation, which is the end point of mature scar formation. Although both groups showed improvements in umbilical shape as time passed, the final result was also superior in the group treated with the new technique. Patients' satisfaction likewise showed a similar pattern. This means that the new technique with quilting sutures provided better results for the postoperative shape of the umbilicus, especially in the immediate postoperative phase, and it led to fewer complaints in the early postoperative period. As there was no difference in the operative time between both groups, the new technique is an efficient way of obtaining ideal results and reducing patients' complaints.

In conclusion, using quilting sutures during the closure of the incision site within the umbilicus is an effective method in SPLS. It provides better cosmetic results, while maintaining the functional benefits of conventional surgical procedures. As an ideal umbilical shape can be obtained without additional operative time, the quilting suture technique is practical in SPLS.

References:

1. Nieboer TE, Johnson N, Lethaby A, et al. Surgical approach to hysterectomy for benign gynaecological disease. *Cochrane Database Syst Rev.* 2009;Cd003677.
2. Escobar PF, Fader AN, Paraiso MF, Kaouk JH, Falcone T. Robotic-assisted laparoendoscopic single-site surgery in gynecology: initial report and technique. *J Minim Invasive Gynecol.* 2009;16:589–591.
3. So KA, Lee JK, Song JY, et al. Tissue injuries after single-port and multiport laparoscopic gynecologic surgeries: a prospective multicenter study. *Exp Ther Med.* 2016;12:2230–2236.
4. Eom JM, Ko JH, Choi JS, Hong JH, Lee JH. A comparative cross-sectional study on cosmetic outcomes after single port or conventional laparoscopic surgery. *Eur J Obstet Gynecol Reprod Biol.* 2013;167:104–109.

5. Lee JH, Choi JS, Jeon SW, Son CE, Lee SJ, Lee YS. Single-port laparoscopic myomectomy using transumbilical GelPort access. *Eur J Obstet Gynecol Reprod Biol.* 2010;153:81–84.
6. Vercelli S, Ferriero G, Sartorio F, Stissi V, Franchignoni F. How to assess postsurgical scars: a review of outcome measures. *Disabil Rehabil.* 2009;31:2055–2063.
7. Park SY, Kim KH, Yuk JS, Ji HY, Lee JH. Skin closure methods after single port laparoscopic surgery: a randomized clinical trial. *Eur J Obstet Gynecol Reprod Biol.* 2015;189:8–12.
8. Zhou X, Qi X, Jiang B, Sha Y, Song D. Transumbilical endoscopic technique for complete closure of inguinal hernias in female pediatric patients. *Exp Ther Med.* 2017;13:41–44.
9. Gangl O, Hofer W, Tomaselli F, Sautner T, Fugger R. Single incision laparoscopic cholecystectomy (SILC) versus laparoscopic cholecystectomy (LC): a matched pair analysis. *Langenbecks Arch Surg.* 2011;396:819–824.
10. Pfulg M, Van de Sijpe K, Blondeel P. A simple new technique for neo-umbilicoplasty. *Br J Plast Surg.* 2005;58:688–691.
11. Kajikawa A, Ueda K, Suzuki Y, Ohkouchi M. A new umbilicoplasty for children: creating a longitudinal deep umbilical depression. *Br J Plast Surg.* 2004;57:741–748.
12. Ikeda H, Yamamoto H, Fujino J, et al. Umbilicoplasty for large protruding umbilicus accompanying umbilical hernia: a simple and effective technique. *Pediatr Surg Int.* 2004;20:105–107.
13. Schaefer IM, Seeliger S, Strauss A, Fuzesi L, Ringert RH, Loertzer H. A three-step technique for umbilicoplasty in a patent urachus. *BJU Int.* 2012;109:640–644.
14. Craig SB, Faller MS, Puckett CL. In search of the ideal female umbilicus. *Plast Reconstr Surg.* 2000;105:389–392.
15. Yu D, Novicoff WM, Gampper TJ. The average size and position of the umbilicus in young men and women. *Ann Plast Surg.* 2016;76:346–348.
16. Lee SJ, Garg S, Lee HP. Computer-aided analysis of the “beautiful” umbilicus. *Aesthet Surg J.* 2014;34:748–756.
17. Menon A, Ganapathi A. Neoumbilicoplasty in a laparoscopic port site: description of a new technique and review of literature. *J Clin Diagn Res.* 2017;11:Pd04–pd05.
18. Kim TJ, Lee YY, Cha HH, et al. Single-port-access laparoscopic-assisted vaginal hysterectomy versus conventional laparoscopic-assisted vaginal hysterectomy: a comparison of perioperative outcomes. *Surg Endosc.* 2010;24:2248–2252.
19. Malic CC, Spyrou GE, Hough M, Fourie L. Patient satisfaction with two different methods of umbilicoplasty. *Plast Reconstr Surg.* 2007;119:357–361.
20. Mazzocchi M, Trignano E, Armenti AF, Figus A, Dessy LA. Long-term results of a versatile technique for umbilicoplasty in abdominoplasty. *Aesthetic Plast Surg.* 2011;35:456–462.