

Coexisting Brenner Tumor and Endometrial Carcinoma

Mitakshara Sharma, Babita Khangar, Varuna Mallya, Nita Khurana, Sangeeta Gupta¹

Departments of Pathology and ¹Obstetrics and Gynecology, Maulana Azad Medical College, New Delhi, India

ABSTRACT

Brenner tumor is a rare ovarian neoplasm that is seen in women of the fifth to sixth decade. Classified as benign, borderline, and malignant, these tumors may be associated with estrogen production, thus altering the estrogen–progesterone ratio. High estrogen stimulates the endometrium and this is responsible for producing various pathologies, namely, hyperplasia, atypia, and carcinoma. Very few case reports have been published highlighting the same. A case report is being presented here of a coexisting Brenner tumor and well-differentiated endometrial carcinoma in a 55-year-old nulliparous postmenopausal woman.

KEYWORDS: Brenner tumor, endometrial adenocarcinoma, estrogen, nulliparous

INTRODUCTION

Ovarian tumors are a major cause of mortality and morbidity in females and present with marked variation in their histological types. The surface epithelial tumors are the most common type of ovarian tumors and are classified into five distinct subtypes including serous, mucinous, endometrioid, transitional, and clear cell types.^[1] Brenner tumors are uncommon, solid fibro-epithelial neoplasm with transitional cell appearance of the proliferating epithelial element representing metaplasia. These are rare tumors and comprise 2%–3% of ovarian neoplasms.^[2] Incidental Brenner tumors are not uncommon in oophorectomy specimens but are rather difficult to diagnose, often missed, and so the true incidence of these cannot be assessed. Rarely, these could be associated with endometrial disorders.^[3] We present a case of incidental finding of Brenner tumor in a 55-year-old female with endometrial carcinoma which is rare and seldom reported.

CASE REPORT

A 55-year-old obese, nulliparous postmenopausal female presented with the complaints of bleeding per vaginum. On examination, she was found to be a diabetic with elevated blood pressure. The vulva, vagina, and cervix were normal. Her ultrasound was unremarkable. The uterus was anteverted, mobile, and bulky. Total abdominal hysterectomy along with lymph node resection was performed. The specimens

were sent for histopathological examination in 10% formalin. The uterus with cervix and bilateral adnexae measured 10 cm × 10 cm × 7 cm. Cut section of the uterus was unremarkable [Figure 1]. The lymph nodes sent in separate containers were sampled separately. Microscopy of the endometrium revealed tumor cells arranged in well-preserved glandular architecture with scant-intervening stroma. A diagnosis of well-differentiated endometrial carcinoma-endometrioid type (Grade – I) with invasion into more than 50% of myometrium was given [Figure 2a]. The serial sectioning of the myometrium also revealed a leiomyoma measuring 3 cm in diameter. The left ovary was grossly unremarkable and measured 3 cm × 2 cm × 1 cm. However, on microscopy, there were nests of epithelium mimicking urinary tract with longitudinal grooves. Some of these nests also showed cystic change. The intervening stroma was fibrotic [Figure 2b]. No atypia was noted in these nests. These findings were consistent with Brenner tumor of the left ovary. The other ovary and bilateral tubes were unremarkable. Seven lymph nodes were identified, all showed reactive changes. A final diagnosis of well-differentiated endometrioid carcinoma with unilateral Brenner tumor was given.

Address for correspondence: Dr. Varuna Mallya,

Room No: 269, Department of Pathology, Maulana Azad Medical College, New Delhi - 110 002, India.

E-mail: varunamallya@gmail.com

This is an open access article distributed under the terms of the Creative Commons Attribution-NonCommercial-ShareAlike 3.0 License, which allows others to remix, tweak, and build upon the work non-commercially, as long as the author is credited and the new creations are licensed under the identical terms.

For reprints contact: reprints@medknow.com

How to cite this article: Sharma M, Khangar B, Mallya V, Khurana N, Gupta S. Coexisting brenner tumor and endometrial carcinoma. J Mid-life Health 2017;8:89-91.

Access this article online

Quick Response Code:



Website: www.jmidlifehealth.org

DOI: 10.4103/jmh.JMH_3_17

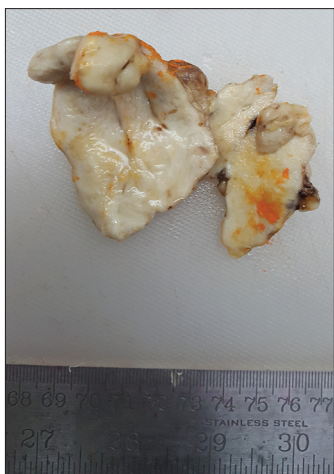


Figure 1: Gross photograph showing unremarkable endometrial cavity

DISCUSSION

Ovarian neoplasms are the fourth most frequent cause of death from cancer in women in Europe, the United States, and East India.^[4] The incidence in India being 5.4%,^[5] ovarian neoplasms usually present with abdominal lump and pelvic pain, in case of hormone-secreting tumors present with abnormal uterine bleeding. Many of them are asymptomatic.

Brenner tumor is a rare ovarian neoplasm. It usually presents at the fifth to sixth decades of life.^[6] Symptoms of Brenner tumor include vaginal bleeding due to estrogen production, palpable pelvic mass, pelvic pain, and rarely may be associated with ascites and hydrothorax in the Pseudo-Meigs' syndrome.

In 1907, Brenner described transitional cell tumors of the ovary for the first time. Transitional cell tumors further include two distinct clinico-pathological entities: (1) Transitional cell carcinomas and Brenner tumors. Brenner tumors are further divided into three different categories by the WHO as (a) benign, (b) borderline, and (c) malignant. Benign tumors are more common accounting for about 98% of Brenner tumors, mostly unilateral and <5 cm whereas borderline or malignant are rare, >5 cm at diagnosis and usually bilateral.^[7]

In the present case, the ovary measured <5 cm and no atypia was noted. In about 20% of cases, Brenner tumors occur together in association with mucinous cystadenoma, serous cystadenoma, or a benign cystic teratoma. These tumors can occur at extra-ovarian sites including myometrium and the testis.

Etiopathogenesis and hormonal activity of these tumors are still an enigma. Many theories have been proposed for the site of origin of these tumors, namely, whalthards nests, germ cells, germinal epithelium, rete ovarii, follicular structures, or from gonadal stroma. The most

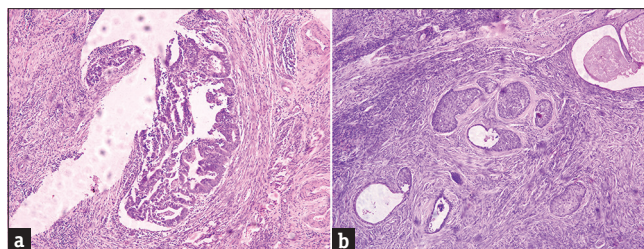


Figure 2: (a) Photomicrograph showing atypical cells arranged in glandular configurations (H and E, ×400). (b) Photomicrograph showing nests of transitional cells separated by fibrotic stroma (H and E, ×400)

acceptable theory is that the tumor arises from the urinary tract epithelium, either from the mesonephric remnants or by metaplasia of the germinal epithelium. This theory is supported by the co-existence of Brenner tumor with mucinous cystadenoma and histological features of Brenner tumor.^[8]

Brenner tumor is often associated with endometrial hyperplasia in 4%–14% of cases and stromal luteinization with estrogen production. The abnormal vaginal bleeding in our case may be attributed to this.^[9] Brenner tumors may cause an imbalance in the estrogen and progesterone production and this may be responsible in the development of endometrial carcinoma.^[3] The stromal component of the Brenner tumor which resembles the theca cells of the ovary produces estrogen which may be responsible for hyperplasia, atypia, and carcinoma of the endometrium. It is a well-known fact that unopposed estrogen along with diabetes, obesity, and hypertension is a risk factor for Type I endometrial carcinoma. The patient in our case had diabetes, hypertension, was obese and nulliparous, and the incidental Brenner tumor in her ovary probably was secreting estrogen, thus explaining the coexistence of endometrioid carcinoma.

Brenner tumors are composed of epithelial nests surrounded by proliferating dense stromal tissue. The epithelial cells are round or polygonal and have round or oval nuclei, small nucleoli, and clear to eosinophilic cytoplasm. The central portion may undergo cystic change. Similar findings were seen in the present case.^[10]

Both sonography and computed tomography may show Brenner tumors, but both techniques are limited in specificity and sensitivity because of the tumor's nonspecific appearance, tumor's small size, or presence of a coexistent epithelial lesion.

Management of Brenner tumor is similar to that of ovarian fibromas and depends on the patient's fertility status. Bilateral salpingo-oophorectomy is the treatment of choice for postmenopausal women, and simple excision with ovarian preservation is preferred for younger women.

In our case, total abdominal hysterectomy and bilateral salpingo-oophorectomy were done because of her slightly bulky uterus and the possibility of malignancy. Prognosis of patients with Brenner tumors is usually excellent.^[7] Our patient is disease free 3 months after her surgery.

CONCLUSION

Brenner tumors are most often solid neoplasms commonly found incidentally and frequently seen in association with other epithelial neoplasms. This case is presented here to highlight the importance to evaluate the endometrium so as to exclude endometrial atypia and carcinomas in such patients due to unopposed estrogen stimulation arising from Brenner tumor. Ours is one of the few cases of Brenner tumor presenting with endometrial carcinoma which adds to the scarce data.

Financial support and sponsorship

Nil.

Conflicts of interest

There are no conflicts of interest.

REFERENCES

1. Lee KR, Tavassoli FA, Prat J. Surface epithelial-stromal tumours. In: Tavassoli FA, Devilee P, editors. Pathology and Genetics Tumours of the Breast and Female Genital Organs, World Health Organization Classification of Tumours. Lyon: IARC Press; 2003. p. 140-3.
2. Longacre TA, Gilks CB. Surface epithelial-stromal tumors of the ovary. In: Nucci MR, Oliva E, Goldblum JR, editors. Gynecologic Pathology. London: Churchill Livingstone Elsevier; 2009. p. 393-444.
3. Indraccolo U, Cingolani N, Indraccolo SR. Bilateral brenner tumor with endometrial adenocarcinoma in a postmenopausal woman. *Eur J Gynaecol Oncol* 2007;28:233-4.
4. Sen U, Sankaranarayanan R, Mandal S, Ramanakumar AV, Parkin DM, Siddiqi M. Cancer patterns in Eastern India: The first report of the Kolkata cancer registry. *Int J Cancer* 2002;100:86-91.
5. Kauff ND, Satagopan JM, Robson ME, Scheuer L, Hensley M, Hudis CA, *et al.* Risk-reducing salpingo-oophorectomy in women with a BRCA1 or BRCA2 mutation. *N Engl J Med* 2002;346:1609-15.
6. Athey PA, Siegel MF. Sonographic features of brenner tumor of the ovary. *J Ultrasound Med* 1987;6:367-72.
7. Takahama J, Ascher SM, Hirohashi S, Takewa M, Ito T, Iwasaki S, *et al.* Borderline brenner tumor of the ovary: MRI findings. *Abdom Imaging* 2004;29:528-30.
8. Seidman JD, Russell P, Kurman RJ. Surface epithelial tumors of the ovary. In: Kurman RJ, editor. Blaustein's Pathology of the Female Genital Tract. 5th ed. New York: Springer Verlag; 2002. p. 879.
9. Sternberg WH. Non-functioning ovarian neoplasm's. In: Grady HG, Smith DE, editors. The Ovary. Baltimore: Williams and Wilkins; 1963. p. 209-15.
10. Girling JC, Soutter WP, Stanton SL, editors. Gynaecology. 2nd ed. London: Churchill Livingstone; 1997. p. 615-27.