



Case Report

A rare appearance of the trigeminocardiac reflex during resection of posterior parasagittal meningioma

Miguel A. Recinos¹, Jason Hsieh², Hussain Mithaiwala³, Joti Juneja Mucci³, Pablo F. Recinos^{1,2}

¹Brain Tumor and Neuro-Oncology Center, Cleveland Clinic, Departments of ²Neurological Surgery and ³Anesthesiology, Cleveland Clinic, Cleveland, Ohio, United States.

E-mail: Miguel A. Recinos - mrecinos1995@gmail.com; Jason Hsieh - hsiehj@ccf.org; Hussain Mithaiwala - hussain.mithaiwala@johnmuirhealth.com; Joti Juneja Mucci - junejaj@ccf.org; *Pablo F. Recinos - recinop@ccf.org



*Corresponding author:

Pablo F. Recinos,
Brain Tumor and Neuro-
Oncology Center, Cleveland
Clinic, 9500 Euclid Avenue,
CA5-87, Cleveland - 44195,
Ohio, United States.

recinop@ccf.org

Received : 18 October 2020

Accepted : 25 March 2021

Published : 26 April 2021

DOI

10.25259/SNI_737_2020

Quick Response Code:



ABSTRACT

Background: Although a well-recognized phenomenon of the tentorium and posterior fossa, the trigeminocardiac reflex (TCR) has been rarely reported during surgery involving the posterior falx cerebri.

Case Description: We present the case of a 63-year-old woman who underwent repeat resection of an atypical parasagittal meningioma involving the posterior falx. During resection, TCR was repeatedly elicited during manipulation and coagulation of the falx. Air embolism and cardiac etiologies were initially considered while TCR was not suspected, given the location. Ultimately, TCR was recognized when asystole self-resolved upon cessation of stimulus and due to its reproducibility.

Conclusion: Awareness by the anesthesiologist and neurosurgeon of the possibility of TCR during falcine procedures can help with rapid identification to avoid a potentially catastrophic outcome.

Keywords: Air embolism, Falx, Nervous tentorii, Trigeminal nerve, Vagus nerve

INTRODUCTION

Elicitation of the trigeminocardiac reflex (TCR) by mechanical, electrical, or chemical stimuli may result in the sudden onset of bradycardia, hypotension, and gastric hypermotility.^[2,10] Afferent activation of the TCR through the trigeminal sensory nerve and nuclei leads to efferent activation of the vagus nerve, decreasing output from the sinoatrial node and leading to cardiac problems such as hypotension, bradycardias, and arrhythmias [Figure 1].^[1-3,10,13] Removal of the stimulus normally results in termination of the reflex.^[10] TCR can occur during direct manipulation of the trigeminal nerve, during craniofacial surgery, and during resection of lesions in the cavernous sinus, cerebellopontine angle, and the pituitary fossa. The occurrence of TCR during cranial surgery in other locations, however, is uncommon.^[2,10,13]

Surgeons operating on parasagittal meningiomas and other lesions in the region of the cerebral venous sinuses must remain vigilant for the possibility of venous air embolism (AE). Inadvertent entry into venous sinuses can allow the entry of air into the low-pressure venous return, resulting in entrapped air in the right atrium. Potential consequences of AE include hypotension, myocardial infarction, and arrhythmia. If air is instead shunted to the systemic circulation through

This is an open-access article distributed under the terms of the Creative Commons Attribution-Non Commercial-Share Alike 4.0 License, which allows others to remix, tweak, and build upon the work non-commercially, as long as the author is credited and the new creations are licensed under the identical terms.

©2021 Published by Scientific Scholar on behalf of Surgical Neurology International

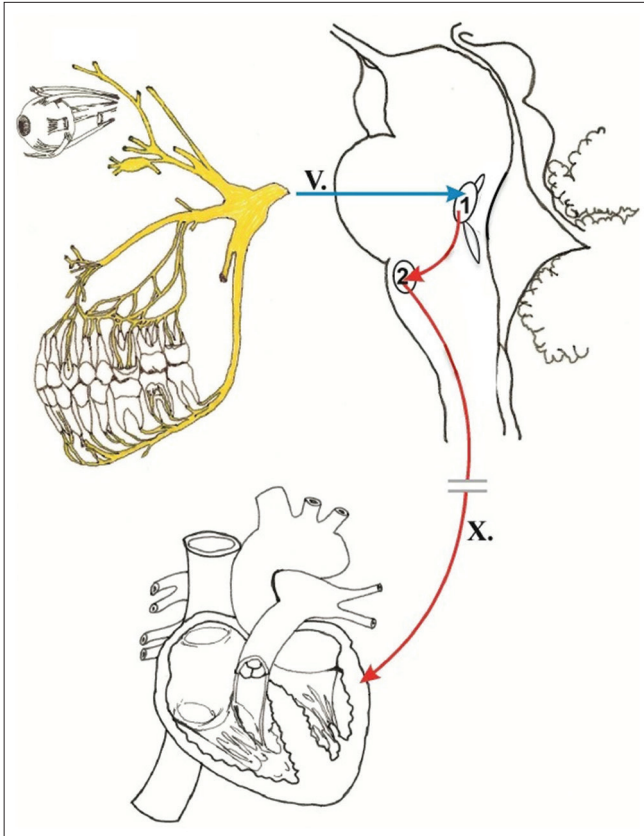


Figure 1: Afferent stimulus that may elicit the trigeminocardiac reflex travel along any of the main branches of CN V. The 1st division (V1) innervates the falx through a recurrent branch, the nervous tentorii. Stimuli (blue arrow) travel through the Gasserian ganglion to the chief sensory nucleus of the trigeminal nerve (1). The spinal nucleus of the trigeminal nerve is also involved in processing nociceptive stimuli. Interneuronal fibers (upper red arrow) join the trigeminal nucleus and the dorsal motor nucleus of the vagus nerve (2), from which efferent vagal parasympathetic preganglionic fibers (lower red arrow) emerge to travel to diverse systemic locations including parasympathetic ganglia responsible for modulation of the heart rate through the sinoatrial node. This figure is used with permission from the publishers. Reference: Abdulazim A, Martin N, Sadr-Eshkevari P, Prochnow N, Sandu N, Bohluli B, et al. Trigemino-cardiac reflex in neurosurgery - current knowledge and prospects. In: Signorelli F, editor. *Explicative Cases of Controversial Issues in Neurosurgery*. London: InTech; 2012. p. 3-18.

a patent foramen ovale, sequelae may include arterial ischemia including cerebral infarction.^[9,12] The reported incidence of AE during parasagittal meningioma surgery varies widely, from 1.5% to 50%.^[8,9] Thus, intraoperative monitoring of high-risk parasagittal meningioma cases is critical for rapid recognition of AE to subsequently prevent serious, permanent complications.

We present a unique case of TCR, that occurred during resection of an atypical parasagittal meningioma found in the middle to posterior third of the superior sagittal sinus

(SSS). While preparation for AE was performed and there was a heightened awareness of the possibility of cardiac events due to the patient's cardiac risk factors, elicitation of TCR was unexpected and knowledge of its possibility in future similar cases would help to more rapidly recognize TCR and guide intraoperative management.

CASE REPORT

The patient was a 63-year-old woman with a recurrent parafalcine meningioma. She had presented originally 6 years prior with focal right lower extremity motor seizures and was found to have an approximately 4 cm bilateral parafalcine meningioma at the paracentral lobule that was eccentric to the left. Her initial resection was aborted due to sustained ST elevations before dural opening. After cardiac catheterization, evaluation, and clearance, she underwent resection 1 month later through a bicoronal approach. The tumor was heavily calcified, invading, and densely adherent to the falx and sinus, and although sinus bleeding was encountered, a Simpson Grade III resection was achieved. The sinus was preserved. Pathology revealed the WHO Grade II atypical meningioma. Notably, she was later diagnosed with coronary artery disease.

She underwent adjuvant radiotherapy (54 Gy) and later twice underwent gamma knife radiosurgery for progressive disease at 4 years and 5 years postoperatively. Six years postoperatively, she experienced worsening seizures and imaging revealed meningioma recurrence. Preoperative vascular imaging showed SSS occlusion [Figure 2] and repeat surgery was recommended.

Perioperatively, a central line was placed, and precordial Doppler was used due to concern for possible AE. We opened and extended her prior bicoronal incision. After significant dissection through scar tissue and extension of craniotomy, we began resection of the tumor. During tumor resection, the falx was being coagulated and the patient became profoundly bradycardic, then asystolic [Figure 3]. Given that tumor invading the SSS was being resected, there was concern for AE and we copiously irrigated the field and placed the head in Trendelenburg position, followed by tamponade with wet sponges. She remained asystolic for approximately ten seconds and then became profoundly bradycardic for approximately 1 min. There was no evidence of AE on precordial Doppler or end-tidal CO₂ monitoring, and the patient recovered spontaneously during medical interventions by the anesthesia team.

After discussion between the anesthesia and neurosurgery teams, AE and a cardiac etiology were ruled out and surgery resumed. By careful exploration of the tumor-falcine-sinus interface, we confirmed that the sinus was occluded by tumor and began to coagulate it again to sacrifice it to improve resection. Given the likely chronic nature of her sinus occlusion, we felt confident that this would not result in venous congestion. During repeat coagulation of the SSS

and posterior falx, profound bradycardia occurred again and self-resolved upon cessation of coagulation. This was repeatedly reproducible. After sacrifice of the sinus and falx in the region of the tumor and careful dissection, we were able to achieve a Simpson Grade I resection. The remainder of the case was uncomplicated.

DISCUSSION

The TCR was first described in rabbits by Kumada *et al.* in 1977 during neurostimulation experiments and first reported in humans by Brown and Preul in 1988 as a trigeminal depressor response.^[4,7] Furthermore, TCR was first introduced into neurosurgery by Schaller *et al.* in 1999 where it presented during a surgery in the cerebellopontine angle.^[11] Yet, despite the fact that knowledge about TCR and its etiology has improved markedly in the past several decades, the literature regarding TCR in the posterior third of the falx cerebri is sparse. However, there are two case reports

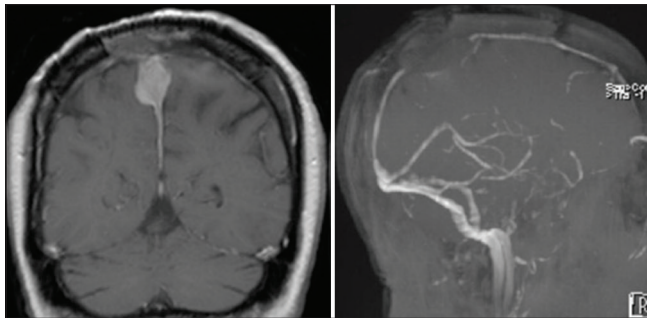


Figure 2: Preoperative imaging studies. Coronal T1 postcontrast MRI demonstrating recurrent progressive atypical meningioma (Left). 3D sagittal reconstruction of MRV demonstrating occlusion of middle/posterior third of the superior sagittal sinus (Right).

which detail circumstances similar to those we encountered, as well as one article in which TCR was elicited during resection of a falcine meningioma in the SSS. In all three works, a TCR was produced through manipulation of the falx cerebri. In addition, both of the case reports attributed the innervation of the falx by the nervous tentorii as the pathway for the TCR response.^[2,5,13]

The falx is innervated by the nervus tentorii, which is a recurrent branch of cranial nerve VI.^[2,13] Projections are known to exist between the vagus nuclei and trigeminal ganglia in the dorsal region of the trigeminal tract. The vagus nerve is an essential part of the parasympathetic pathway, innervating the heart, digestive tract, and lungs. Therefore, stimulation of the falx can result in hyperactivity of the trigeminal ganglion, triggering an action potential in the vagus nerve and initiating a TCR [Figure 1].^[1,2]

TCR can usually be terminated by simple removal of the triggering stimulus and intraoperatively may be coupled with anesthetic maneuvers to correct mild hemodynamic and metabolic perturbations. If hypotension and bradycardia do not correct immediately, anticholinergic agents (such as glycopyrrolate or atropine) can be administered to mitigate these factors. In extreme cases where stimulus removal and administration of anticholinergic fails to terminate TCR, cardiac life support should be utilized to avoid potentially fatal hemodynamic instability.^[5,6,10,11] TCR was confirmed in this case after reasonably excluding other etiologies (AE and a cardiac event) and by the fact that it met the diagnostic criteria - being initiated by a thermal response, resolving when the stimulus was stopped, and being reproducible.

Although TCR was the physiological explanation in this case, monitoring for AE is important when performing high-risk

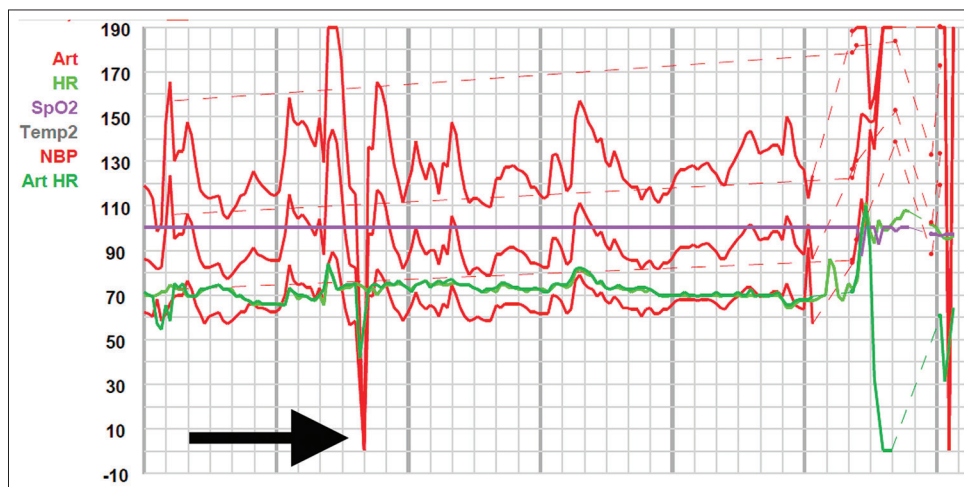


Figure 3: Intraoperative anesthesia record demonstrating the first moment of more sustained asystole. Although other brief asystolic instances occurred, they were too short to be recorded in the anesthesia flow sheet due to immediate recognition of trigeminocardiac reflex and cessation of stimulus.

meningioma operations such as the one described in this report. The three most common methods used to detect AE are a right atrial central venous pressure line (that can also aspirate air), transesophageal echocardiography, and precordial Doppler.^[9,12] Other methodologies include evaluating end-tidal CO₂ and, much less commonly, end-tidal nitrogen. In this case, precordial Doppler and a central line were placed. AE can be treated by first lowering the head. The next steps are to flood the field with irrigation, aspirate air by means of central line, and administer 100% oxygen to the patient to reduce embolus volume. In the case of massive AE producing asystole, the patient can require cardiopulmonary resuscitation.^[9,12] The anesthesiologist and the surgeon communicate to perform these actions promptly and effectively. The role of coordination between both parties is critical to treating the embolism.

In the present case, after the first incident of bradycardia was reported, AE was immediately considered, as was a cardiac event, due to the patient's history of cardiac disease. However, in cases involving the falcine region, TCR should also be taken into consideration to prevent asystole. The important distinction is that asystole from TCR was the only potential etiology that could self-resolve by immediately stopping the initiating stimulus, whereas asystole from AE or a cardiac etiology would likely necessitate cardiopulmonary resuscitation. Both the anesthesia and neurosurgical teams should be aware that TCR can result from stimulation of the posterior falx. By rapidly communicating the changes seen, the offending stimulus can be immediately stopped before the patient progressing to asystole and potential cardiac arrest. Typically, the anesthesia team goes through an algorithm when significant cardiovascular changes occur. The first step is typically to tell neurosurgeon to stop any stimulus to assess for resolution of cardiac changes. This case further highlights the importance of this step in such an algorithm.

CONCLUSION

Awareness by the anesthesiologist and neurosurgeon of the possibility of TCR during falcine procedures can help with rapid identification to avoid a potentially catastrophic outcome.

Declaration of patient consent

The authors certify that they have obtained all appropriate patient consent.

Financial support and sponsorship

Nil.

Conflicts of interest

Dr. Recinos is a consultant for Stryker.

REFERENCES

1. Abdulazim A, Stienen MN, Sadr-Eshkevari P, Prochnow N, Sandu N, Bohluli B, *et al.* Trigemino-cardiac reflex in neurosurgery current knowledge and prospects. In: Signorelli F, editor. *Explicative Cases of Controversial Issues in Neurosurgery*. London: InTech; 2012. p. 3-18.
2. Bauer DF, Youkilis A, Schenck C, Turner CR, Thompson BG. The falcine trigeminocardiac reflex: Case report and review of the literature. *Surg Neurol* 2005;63:143-8.
3. Borghei-Razavi H, Das P, Maurtua M, Recinos PF. Unusual appearance of trigemino-cardiac reflex during cerebellopontine angle surgery. *World Neurosurg* 2018;112:298-9.
4. Brown JA, Preul MC. Trigeminal depressor response during percutaneous microcompression of the trigeminal ganglion for trigeminal neuralgia. *Neurosurgery* 1988;23:745-8.
5. Das KK, Gosal JS, Sharma P, Mehrotra A, Bhasora K, Sardhara J, *et al.* Falcine meningiomas: analysis of the impact of radiologic tumor extensions and proposal of a modified preoperative radiologic classification scheme. *World Neurosurg* 2017;104:248-58.
6. Fayon M, Gauthier M, Blanc VF, Ahronheim GA, Michaud J. Intraoperative cardiac arrest due to the oculocardiac reflex and subsequent death in a child with occult epstein-barr virus myocarditis. *Anesthesiology* 1995;83:622-4.
7. Kumada M, Dampney RAL, Reis DJ. The trigeminal depressor response: A novel vasodepressor response originating from the trigeminal system. *Brain Res* 1977;119:305-26.
8. Raza SM, Gallia GL, Brem H, Weingart JD, Long DM, Olivi A. Perioperative and long-term outcomes from the management of parasagittal meningiomas invading the superior sagittal sinus. *Neurosurgery* 2010;67:885-93.
9. Sahoo BK. Incidence and Complications of Venous Air Embolism in Patients Undergoing Selective Intracranial Surgeries by Using Transesophageal Echocardiography. Thiruvananthapuram, Kerala, India: D.M. Dissertation, Department of Anaesthesiology, Sree Chitra Tirunal Institute for Medical Sciences and Technology; 2017.
10. Schaller B, Cornelius JF, Prabhakar H, Koerbel A, Gnanalingham K, Sandu N, *et al.* The trigemino-cardiac reflex: An update of the current knowledge. *J Neurosurg Anesthesiol* 2009;21:187-95.
11. Schaller B, Probst R, Strebel S, Gratzl O. Trigemino-cardiac reflex during surgery in the cerebellopontine angle. *J Neurosurg* 1999;90:215-20.
12. Shaikh N, Ummunisa F. Acute management of vascular air embolism. *J Emerg Trauma Shock* 2009;2:180.
13. Takano K, Kinoshita M, Hashimoto N, Tanigami H, Yoshimine T. A reminder about the trigeminocardiac reflex in surgeries at the posterior third of the falx cerebri. *Interdiscip Neurosurg Adv Tech Case Manag* 2014;1:47-9.

How to cite this article: Recinos MA, Hsieh J, Mithaiwala H, Mucci JJ, Recinos PF. A rare appearance of the trigeminocardiac reflex during resection of posterior parasagittal meningioma. *Surg Neurol Int* 2021;12:183.