

Poor prognosis of pulmonary sarcomatoid carcinoma with *KRAS* mutation and *ALK* fusion

This article was published in the following Dove Medical Press journal:
OncoTargets and Therapy

Fangmin Chen
Qihua Gu
Chengping Hu
Xiaoling Cai
Shuhua Lei

Department of Respiratory Medicine,
Xiangya Hospital of Central South
University, Changsha, People's
Republic of China

Abstract: Pulmonary sarcomatoid carcinoma (PSC) is a rare subtype of poorly differentiated non-small-cell lung cancer (NSCLC), and no effective treatment is available in clinical practice currently. In the present report, a 61-year-old male patient was hospitalized due to cough, dyspnea, and right chest pain. Computed tomography (CT) showed spot- and piece-shaped shadows. The patient became very weak and had breathing difficulty after preliminary anti-pneumonia treatment with cefoperazone–sulbactam. Physical examination revealed dull sound by percussion and decreased breath sounds in the right lateral lung areas by auscultation. A second CT scan revealed a large amount of pleural effusion, and the patient was diagnosed with bloody pleural effusion through pleural space puncture. Multiple nodular lesions were found in the right pleural cavity under thoracoscopy. PSC was confirmed by biopsy and histopathology in combination with immunohistochemistry (IHC). Single-photon emission CT (SPECT) scan indicated multiple bone metastases. *KRAS* exon 2 mutation and *EML4-ALK* fusion were identified in carcinoma tissue by IHC and amplification refractory mutation system (ARMS)-PCR. The patient received one cycle of first-line combination chemotherapy of cisplatin and paclitaxel liposomes. However, the patient did not respond to the platinum-based combination chemotherapy within 3 weeks and was thus administered oral crizotinib instead of chemotherapy. Unfortunately, he still had rapid disease progression and died 2 weeks after the initiation of crizotinib treatment. Collectively, our results suggest that a PSC patient with coexistent *KRAS* mutation and *ALK* rearrangement would not benefit from chemotherapy and tyrosine kinase inhibitor (TKI) treatment. **Keywords:** pulmonary sarcomatoid carcinoma, *KRAS* mutation, *ALK* rearrangement, chemotherapy, crizotinib, targeted therapy

Introduction

Pulmonary sarcomatoid carcinoma (PSC) is a rare subtype of poorly differentiated non-small-cell lung cancer (NSCLC) and is defined as carcinoma with pleomorphic, sarcomatoid, or sarcomatous elements. It can be divided into five histological types as follows: pleomorphic carcinoma, spindle cell carcinoma, giant cell carcinoma, carcinosarcoma, and pulmonary blastoma.¹ As a rare form of lung malignancy, PSC has a significantly worse prognosis compared with other forms of NSCLC.² Chemotherapy and oral administration of small molecule tyrosine kinase inhibitors (TKIs) are commonly used in the treatment of NSCLC. Before choosing chemotherapy or molecular targeted therapy, genes such as *EGFR*, *ALK*, *ROS1*, and *KRAS* should be analyzed. Although the incidence rate of *ALK* rearrangement in NSCLC is <5% and that of *KRAS* mutation ranges from 24% to 27.6%,^{3–5} *ALK* rearrangements are mutually exclusive with mutations in *EGFR* or *KRAS*.^{3,4,6} Only a few NSCLC patients have both *KRAS* mutation and *ALK* rearrangement, and concomitant *KRAS* mutation and *ALK* rearrangement in PSC has not been reported so far.

Correspondence: Qihua Gu
Department of Respiratory Medicine,
Xiangya Hospital of Central South
University, No. 87, Xiangya Road,
Changsha 410008, Hunan, People's
Republic of China
Tel +86 187 1110 4129
Email guqh06@163.com

NSCLC accompanied by *ALK* rearrangements is highly sensitive to *ALK* TKIs, such as crizotinib and ceritinib.⁷⁻⁹ However, *KRAS* mutations may decrease the efficacy of chemotherapy and oral molecular targeted therapy to NSCLC.¹⁰⁻¹³ It has been reported that PSC is highly resistant to conventional first-line chemotherapy.¹⁴⁻¹⁶ However, the response of *KRAS* mutation and *ALK* fusion-positive PSC to chemotherapy and molecular targeted therapy remains largely unexplored. In the present work, we report a case of PSC with coexistent *KRAS* exon 2 mutation and *EML4-ALK* fusion, who failed to respond to chemotherapy and crizotinib.

Case presentation

A 61-year-old male patient was hospitalized on February 5, 2018, because of cough and dyspnea. The patient had been ill for the past 15 days, exhibiting cough, dyspnea, and right chest pain. Computed tomography (CT) showed spot- and piece-shaped shadows. The patient was treated with cefoperazone-sulbactam in the early stage due to a preliminary diagnosis of pneumonia. However, anti-pneumonia therapy failed, and his condition worsened. He presented symptoms of extreme breathing difficulty and was hospitalized. Physical examination revealed dull sound by percussion and decreased breath sounds in the right lateral lung areas by auscultation. The second CT scan revealed a

large amount of pleural effusion in the right lateral pleural cavity. He was diagnosed with bloody pleural effusion through pleural space puncture. Biopsy pathology and immunohistochemistry examination can be seen in Figure 1. Thoracoscopy revealed multiple nodular lesions in the right pleural cavity (Figure 1A). Lesion tissues were collected for biopsy. PSC was confirmed through biopsy and histopathology (Figure 1B). IHC showed tumor cells positive for CK7 (clone MX053; Figure 1C) while being negative for TTF-1 (clone MX011), Napsin A (clone MX015), CK5/6 (clone D5/16B4), Calretinin (clone SP13), WT1 (clone WT49), and MC (clone HBME-1). After thoracoscopy, CT revealed spot- and piece-shaped shadows and multiple solid lesions in the right lung as well as nodular pleural thickening (Figure 2A). Moreover, the enlargement of mediastinal lymph nodes was also observed. Single-photon emission CT (SPECT) scan revealed multiple bone metastases (Figure 2B). To make a treatment choice, nine genetic tests including EGFR, *KRAS*, ROS1, BRAF, NRAS, PIK3CA, HER-2, RET, and *ALK* were performed by amplification refractory mutation system (ARMS)-PCR. The ARMS-PCR revealed *KRAS* exon 2 mutation and *EML4-ALK* fusion, while the EGFR, ROS1, BRAF, NRAS, PIK3CA, HER-2, and RET genes were wild type. We further verified the *KRAS* exon 2 mutation by performing Sanger's sequencing to analyze the

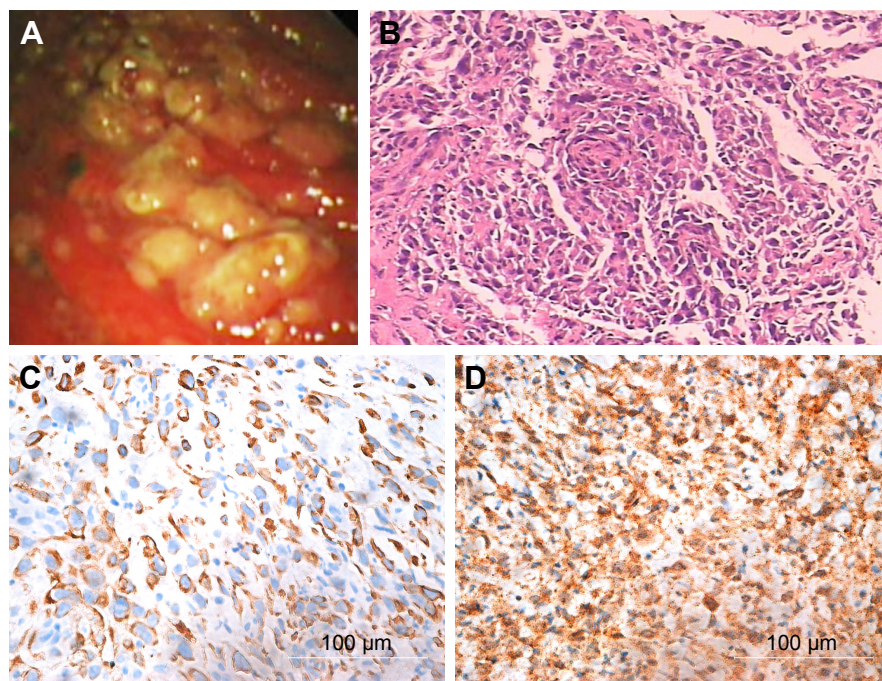


Figure 1 Biopsy pathology and IHC examination. (A) Thoracoscopic photography. Multiple nodular lesions were found in right pleural cavity under thoracoscopy. (B) Histopathological examination (H&E). The pleural tissue showed neoplasia, large nuclei, deep staining, and strong heterogeneity, which was similar to sarcoma. (C) IHC, DAB staining. It showed positive CK7 staining in tumor tissue. (D) IHC, DAB staining. It showed strong positive EML4-ALK staining in tumor tissue.

Abbreviation: IHC, immunohistochemistry.

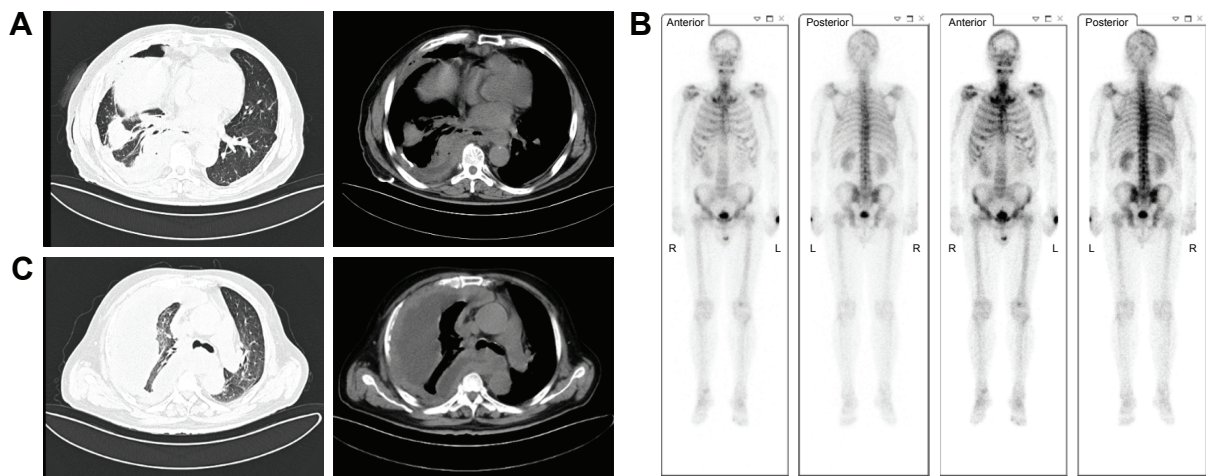


Figure 2 Images of CT and SPECT. **(A)** CT image. After thoracoscopy, most pleural effusion was drained. CT revealed spot- and piece-shaped shadows, showing multiple solid lesions in the right lung. **(B)** SPECT image. General bone scan showed multiple metabolic abnormalities and concentration points. **(C)** CT image. Pleural effusion increased further, and the pleura became much thickened with multiple nodules.

Abbreviations: CT, computed tomography; SPECT, single-photon emission CT.

KRAS gene sequence (an arrow shows code 12 GGT to GAT; Figure 3A). *ALK* rearrangement was also further confirmed by examining *ALK* expression (clone D5F3; Hoffman-La Roche Ltd., Basel, Switzerland) using IHC (Figure 1D) and FISH assay (Figure 3B). The patient was finally diagnosed as PSC T4N3M1C stage IVB *KRAS*(+) *ALK*(+). From February 14, 2018, to March 5, 2018, the patient received one cycle of first-line combination chemotherapy of cisplatin and paclitaxel liposomes. However, the platinum-based combination chemotherapy did not work within 3 weeks. The patient's pleural effusion was still growing rapidly. He experienced breathing difficulty and exhibited a loss of appetite and fatigue. A repeat CT showed increased pleural effusion with further thickening of the pleura and presence of multiple nodules (Figure 2C). Based on the CT results, the patient was orally administered with crizotinib instead of chemotherapy. Unfortunately, he still exhibited rapid disease progression and died on April 2018, 2 weeks after the initiation of crizotinib treatment.

Discussion

PSC is a rare, poorly differentiated, and highly aggressive type of NSCLC.² Radiotherapy, chemotherapy, and TKIs are commonly used in the treatment of advanced NSCLC. In patients with *ALK* fusion-positive NSCLC, small molecule TKIs are more efficient compared with the platinum-based combination chemotherapy. For example, NSCLC with *ALK* rearrangements is susceptible to the *ALK* TKI, crizotinib, and the overall response rate is as high as 70%–80%.^{9,17} Moreover, only few NSCLC patients have multiple oncogenic mutations, and coexistence of *ALK* rearrangement and *KRAS* mutation accounts for only ~13% of the multi-gene mutations.¹⁸ Therefore, crizotinib is the preferred therapeutic scheme for patients with *ALK* fusion-positive NSCLC.

In the present case, the patient, diagnosed with PSC positive for *KRAS* exon 2 mutation and *EML4-ALK* fusion, could not receive surgery or radiation as he was in late-stage disease. PSC is a rare type of lung cancer, and PSC

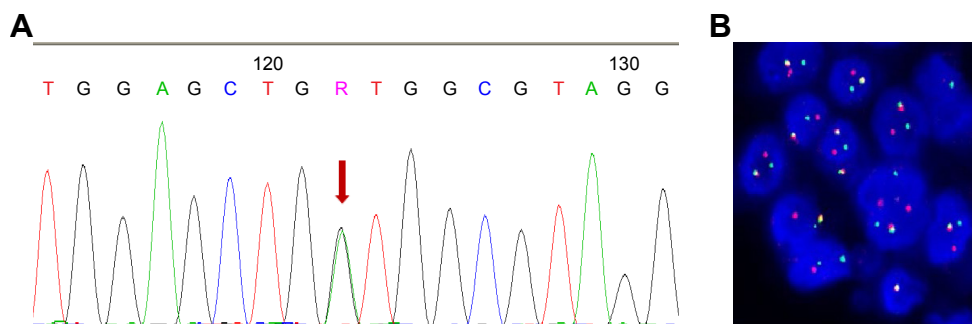


Figure 3 **(A)** Sanger's sequencing further confirms *KRAS* exon 2 mutation (the arrow shows code 12 GGT to GAT). **(B)** *ALK* rearrangement revealed by the split of red and green probes in FISH assay with 75% of rearranged cells.

with coexistent *KRAS* mutation and *ALK* fusion has never been reported before. There is no experience of success or guideline for treatment of such disorders in clinical practice. Referring to the commonly used treatment for NSCLC, the patient should be treated with crizotinib because of positive EML4-*ALK* fusion.¹⁹ However, NSCLC may fail to respond to molecular targeted therapy because of adverse TP53 and *KRAS* mutations.¹³ Moreover, in this patient, PSC progressed rapidly. If the patient failed to respond to oral administration of TKI crizotinib, he might never have another chance of chemotherapy. Therefore, after fully considering the benefits and potential risks, the patient preferred combination chemotherapy of cisplatin and paclitaxel. Unfortunately, the platinum-based combination chemotherapy failed, and the patient's condition deteriorated rapidly. Therefore, the patient was orally administered with crizotinib instead of chemotherapy. However, he failed to respond to the oral crizotinib treatment and died in April 2018.

As a very rare disease, there is still a lack of effective treatment for PSC. Surgical treatment should be considered first in the early stages. Advanced PSC always has a very poor prognosis and responds poorly to conventional platinum-based chemotherapy.^{14,20} It has been reported that *ALK* inhibitors may be an effective treatment for *ALK* rearrangement in PSC.¹⁹ However, *KRAS* mutations can result in a detrimental impact on prognosis and responsiveness to platinum-based chemotherapy in NSCLC^{18,21} as well as in PSC.^{14–16} In the present report, the patient with coexistent *KRAS* mutation and *ALK* rearrangement failed to respond to platinum-based chemotherapy, and his condition deteriorated rapidly even when he was administered the *ALK* inhibitor, crizotinib. The results of treatment, in this case, were consistent with the literature that *KRAS* mutations can result in primary resistance to crizotinib.^{10–13} In recent years, high expression of PD-L has been reported in PSC,^{22,23} which can offer the therapeutic possibility of immunotherapy.^{23–25} In addition to tumor PD-L1 expression being linked to *KRAS* mutations, higher response rates to anti-PD-L1 antibody treatment are also reported in the *KRAS*-mutated NSCLC.²⁵ Therefore, it is necessary to investigate the mechanisms underlying the PD1/PD-L1 immunological therapy in future studies.

Conclusion

PSC is a rare, highly malignant NSCLC with poor prognosis, and there is no available effective treatment in clinical practice. Here, we report a case of PSC positive for *KRAS* exon 2 mutation and EML4-*ALK* fusion, who failed to respond to platinum-based chemotherapy. The patient's

condition deteriorated rapidly even with *ALK* inhibitor, crizotinib treatment. Our results suggest that a PSC patient with coexistent *KRAS* mutation and *ALK* rearrangement would not benefit from chemotherapy and TKI treatment.

Consent

Written informed consent from the patient and approval of the medical ethics committee of Xiangya Hospital (ethical number: 201803294) have been obtained to publish the article.

List of abbreviations

ARMS, amplification refractory mutation system; CT, computed tomography; IHC, immunohistochemistry; NSCLC, non-small-cell lung cancer; PSC, pulmonary sarcomatoid carcinoma; SPECT, single-photon emission CT; TKI, tyrosine kinase inhibitor.

Acknowledgments

We would like to thank the authority of bronchoscopy room of Xiangya Hospital for providing technical support. The authors are also grateful to Dr Richard Liang from Scientific Writing Solutions, USA, for his help in language editing. This work was supported by the National Key R&D Program of China (Grant No 2016YFC1303800).

Disclosure

The authors report no conflicts of interest in this work.

References

1. Beasley MB, Brambilla E, Travis WD. The 2004 world health organization classification of lung tumors. *Semin Roentgenol.* 2005;40(2):90–97.
2. Yendamuri S, Caty L, Pine M, et al. Outcomes of sarcomatoid carcinoma of the lung: a surveillance, epidemiology, and end results database analysis. *Surgery.* 2012;152(3):397–402. doi:10.1016/j.surg.2012.05.007
3. Gainor JF, Varghese AM, Ou SH, et al. *ALK* rearrangements are mutually exclusive with mutations in *EGFR* or *KRAS*: an analysis of 1,683 patients with non-small cell lung cancer. *Clin Cancer Res.* 2013;19(15):4273–4281. doi:10.1158/1078-0432.CCR-13-0318
4. Sequist LV, Heist RS, Shaw AT, et al. Implementing multiplexed genotyping of non-small-cell lung cancers into routine clinical practice. *Ann Oncol.* 2011;22(12):2616–2624. doi:10.1093/annonc/mdr489
5. Terra SB, Jang JS, Bi L, et al. Molecular characterization of pulmonary sarcomatoid carcinoma: analysis of 33 cases. *Mod Pathol.* 2016;29(8):824–831. doi:10.1038/modpathol.2016.89
6. Shaw AT, Yeap BY, Mino-Kenudson M, et al. Clinical features and outcome of patients with non-small-cell lung cancer who harbor EML4-*ALK*. *J Clin Oncol.* 2009;27(26):4247–4253. doi:10.1200/JCO.2009.22.6993
7. Friboulet L, Li N, Katayama R, et al. The *ALK* inhibitor ceritinib overcomes crizotinib resistance in non-small cell lung cancer. *Cancer Discov.* 2014;4(6):662–673. doi:10.1158/2159-8290.CD-13-0846
8. Malik SM, Maher VE, Bijwaard KE, et al. U.S. food and drug administration approval: crizotinib for treatment of advanced or metastatic non-small cell lung cancer that is anaplastic lymphoma kinase positive. *Clin Cancer Res.* 2014;20(8):2029–2034. doi:10.1158/1078-0432.CCR-13-3077

9. Kwak EL, Bang Y-J, Camidge DR, et al. Anaplastic lymphoma kinase inhibition in non-small-cell lung cancer. *N Engl J Med*. 2010;363(18):1693–1703. doi:10.1056/NEJMoa1006448
10. Ulivi P, Chiadini E, Dazzi C, et al. Nonsquamous, non-small-cell lung cancer patients who carry a double mutation of EGFR, EML4-ALK or KRAS: frequency, clinical-pathological characteristics, and response to therapy. *Clin Lung Cancer*. 2016;17(5):384–390. doi:10.1016/j.clc.2015.11.004
11. Mengoli MC, Barbieri F, Bertolini F, Tiseo M, Rossi G. K-RAS mutations indicating primary resistance to crizotinib in ALK-rearranged adenocarcinomas of the lung: report of two cases and review of the literature. *Lung Cancer*. 2016;93:55–58. doi:10.1016/j.lungcan.2016.01.002
12. Sahnane N, Frattini M, Bernasconi B, et al. EGFR and KRAS mutations in ALK-positive lung adenocarcinomas: biological and clinical effect. *Clin Lung Cancer*. 2016;17(1):56–61. doi:10.1016/j.clc.2015.08.001
13. Doebele RC, Pilling AB, Aisner DL, et al. Mechanisms of resistance to crizotinib in patients with ALK gene rearranged non-small cell lung cancer. *Clin Cancer Res*. 2012;18(5):1472–1482. doi:10.1158/1078-0432.CCR-11-2906
14. Vieira T, Girard N, Ung M, et al. Efficacy of first-line chemotherapy in patients with advanced lung sarcomatoid carcinoma. *J Thorac Oncol*. 2013;8(12):1574–1577. doi:10.1097/JTO.0000437008.00554.90
15. Lococo F, Gandolfi G, Rossi G, et al. Deep sequencing analysis reveals that KRAS mutation is a marker of poor prognosis in patients with pulmonary sarcomatoid carcinoma. *J Thorac Oncol*. 2016;11(8):1282–1292. doi:10.1016/j.jtho.2016.04.020
16. Mehrad M, Roy S, LaFramboise WA, et al. KRAS mutation is predictive of outcome in patients with pulmonary sarcomatoid carcinoma. *Histopathology*. 2018;73(2):207–214. doi:10.1111/his.13505
17. Solomon BJ, Mok T, Kim DW, et al. First-line crizotinib versus chemotherapy in ALK-positive lung cancer. *N Engl J Med*. 2014;371(23):2167–2177. doi:10.1056/NEJMoa1408440
18. Guibert N, Barlesi F, Descourt R, et al. Characteristics and outcomes of patients with lung cancer harboring multiple molecular alterations: results from the IFCT study biomarkers France. *J Thorac Oncol*. 2017;12(6):963–973. doi:10.1016/j.jtho.2017.02.001
19. Chen X, Zhang Y, Lu J, et al. Pulmonary sarcomatoid carcinoma with ALK rearrangement: frequency, clinical-pathologic characteristics, and response to ALK inhibitor. *Transl Oncol*. 2017;10(2):115–120. doi:10.1016/j.tranon.2016.11.009
20. Ung M, Rouquette I, Filleron T, et al. Characteristics and clinical outcomes of sarcomatoid carcinoma of the lung. *Clin Lung Cancer*. 2016;17(5):391–397. doi:10.1016/j.clc.2016.03.001
21. Johnson ML, Sima CS, Chaft J, et al. Association of KRAS and EGFR mutations with survival in patients with advanced lung adenocarcinomas. *Cancer*. 2013;119(2):356–362. doi:10.1002/cncr.27730
22. Velcheti V, Rimm DL, Schalper KA. Sarcomatoid lung carcinomas show high levels of programmed death ligand-1 (PD-L1). *J Thorac Oncol*. 2013;8(6):803–805. doi:10.1097/JTO.0b013e318292be18
23. Vieira T, Antoine M, Hamard C, et al. Sarcomatoid lung carcinomas show high levels of programmed death ligand-1 (PD-L1) and strong immune-cell infiltration by TCD3 cells and macrophages. *Lung Cancer*. 2016;98:51–58. doi:10.1016/j.lungcan.2016.05.013
24. Reck M, Rodriguez-Abreu D, Robinson AG, et al. Pembrolizumab versus chemotherapy for PD-L1-positive non-small-cell lung cancer. *N Engl J Med*. 2016;375(19):1823–1833. doi:10.1056/NEJMoa1606774
25. Garon EB, Rizvi NA, Hui R, et al. Pembrolizumab for the treatment of non-small-cell lung cancer. *N Engl J Med*. 2015;372(21):2018–2028. doi:10.1056/NEJMoa1501824

OncoTargets and Therapy

Publish your work in this journal

OncoTargets and Therapy is an international, peer-reviewed, open access journal focusing on the pathological basis of all cancers, potential targets for therapy and treatment protocols employed to improve the management of cancer patients. The journal also focuses on the impact of management programs and new therapeutic agents and protocols on

Submit your manuscript here: <http://www.dovepress.com/oncotargets-and-therapy-journal>

patient perspectives such as quality of life, adherence and satisfaction. The manuscript management system is completely online and includes a very quick and fair peer-review system, which is all easy to use. Visit <http://www.dovepress.com/testimonials.php> to read real quotes from published authors.

Dovepress