

Carotid Body Tumor Presenting as Parotid Swelling Misdiagnosed as Pleomorphic Adenoma: A Rare Presentation

Prem Chand, Rommel Singh, Bimaljot Singh, Rachan Lal Singla

Department of Surgery, Rajindra Hospital/Government Medical College, Patiala, Punjab, India

ABSTRACT

Carotid body tumor (CBT) also known as chemodectoma is a rare tumor of neuroendocrine tissue of carotid body and is the most commonly seen jugular paraganglioma. In most cases, it is benign but it can be malignant. Extra adrenal paraganglioma is rare. We present such a rare case where unusual presentation of chemodectoma was seen as a parotid swelling. This swelling was misdiagnosed as a pleomorphic adenoma on clinical examination, ultrasonography, and fine-needle aspiration cytology and superficial parotidectomy was done for the same, but on histopathological examination it was found to be CBT presenting as a parotid swelling.

KEYWORDS: Carotid body tumor, chemodectoma, paraganglioma, parotid swelling

Address for correspondence:

Dr. Bimaljot Singh,
Department of Surgery, Government Medical College, Rajindra Hospital,
Patiala, India.
E-mail: drbimal.defined@gmail.com

Access this article online

Quick Response Code:



Website: www.nigerianjsurg.com

DOI:
10.4103/1117-6806.162588

INTRODUCTION

Carotid body tumor (CBT) is one of the most commonly seen jugular paragangliomas involving the carotid body chemoreceptors but rarely seen clinically, so the corresponding diagnosis and management remain difficult.

Paragangliomas (PGLs) are uncommon tumors (incidence 1–2 per 100,000) and based on their locations, the tumors are often given special designations.^[1] Only 3% of all PGLs occur within the head and neck of which the majority are located in the carotid body (CBTs), temporal-bone/middle-ear (glomus jugulare), and the vagus nerves in the neck (vagal PGLs).^[2,3]

Carotid body tumor is often seen in patients at the age from 50 to 70 years old with higher incidence in female than that in male. Most patients receive medical treatment for accidental finding of the transverse masses in the cervical part, and hence some patients may complain of such symptoms as local tremor or pulse-like vibratory sense in the mass site, and headache, change in voice, vertigo, etc. Involved nerves can lead to the corresponding symptoms in the nerve-dominated area, but symptoms mediated by endocrine changes are rare.^[4] Physical checkup can find typical transverse beating masses, characterized by high-transverse mobility but low longitudinal mobility.

Color Doppler sonography and digital subtraction angiography (DSA) play a very important role in the confirmation of the clinical diagnosis of CBTs, and DSA is regarded as the gold standard for the final diagnosis of CBTs. With the rapid development of computed tomography technology, subtraction computed tomographic angiography can facilitate the 3D-reconstructed image that can help demonstrate more directly the relationship of the tumor with the surrounding tissues. DSA cannot only provide us with information such as intracranial and extracranial blood circulation and Sharnblin's classification but also opportunity for embolization of blood vessels, resulting in decrease in intraoperative blood loss by occlusion of the blood vessels feeding the tumor through ultraselection arterial embolism.^[5,6] Some researchers recently reported that preoperative application of covered stents for blocking the blood vessels feeding the tumor could achieve satisfactory therapeutic effects.^[7]

CASE REPORT

A 65-years-old female, known case of hypertension, had a swelling in the right parotid region for 2 years which increased progressively. She had a feeling of discomfort in the region of the right parotid swelling on and off but had no other symptom. On examination, there was single swelling behind the angle of the mandible raising the right ear pinna. It was firm in consistency and was mobile. Ultrasonography showed it to be a 23.7mm × 21.8 mm mass in the middle part of the parotid gland with well-defined margins. On fine needle

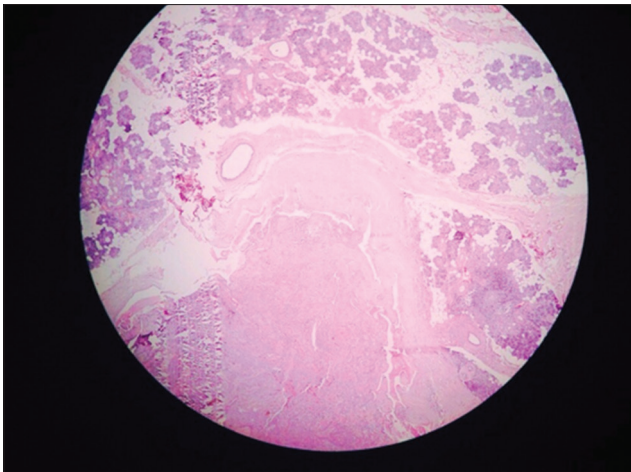


Figure 1: Histopathological picture found confirming diagnosis of carotid body tumor

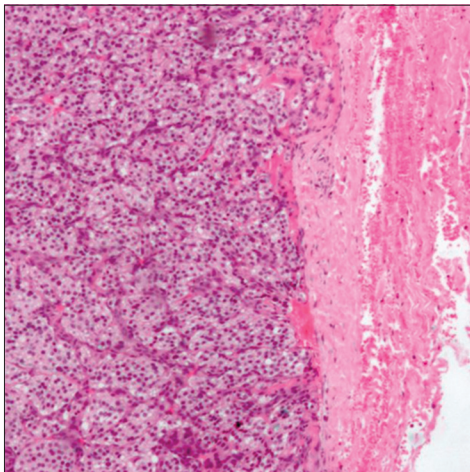


Figure 2: Histopathological picture showing chemodectoma

aspiration cytology, it was reported to be a pleomorphic adenoma. Superficial parotidectomy was done and postoperative period was uneventful. The excised parotid swelling was sent for histopathological examination that came out to be a chemodectoma [Figures 1 and 2].

DISCUSSION

Most of the parotid gland tumors (80%) are benign comprising of pleomorphic adenoma and Warthin's tumor, both in solid and cystic forms.^[8,9] Remaining entities include oncocytoma, basal cell adenoma, and ductal papilloma in the benign category. Mucoepidermoid carcinoma, polymorphous low-grade adenocarcinoma, acinic cell carcinoma, adenoid cystic carcinoma, malignant mixed tumor, and squamous cell carcinoma are amongst the malignant category.^[8] Neuroendocrine carcinomas have also been reported in the parotid gland.^[10] In our patient,

the parotid gland tumor that was diagnosed as pleomorphic adenoma on examination and investigations came out to be chemodectoma/CBT histopathologically [Figures 1 and 2].

Paragangliomas most commonly present as an asymptomatic palpable mass in the anterior triangle of the neck. The mass is usually slow growing and can easily be confused by the clinicians for a lymph node or other head and neck tumors.^[1,2] Our patient had an asymptomatic palpable mass in the parotid region that increased progressively in 2 years. Fine needle aspiration cytology reported it to be pleomorphic adenoma. This mass was excised, and histopathology report came out to be CBT [Figures 1 and 2], which is very rare.

REFERENCES

1. Sevilla García MA, Llorente Pendás JL, Rodrigo Tapia JP, García Rostán G, Suárez Fente V, Coca Pelaz A, *et al.* Head and neck paragangliomas: Revision of 89 cases in 73 patients. *Acta Otorrinolaringol Esp* 2007;58:94-100.
2. Barnes L, Tse LL, Hunt JL, Michaels L. Tumors of paraganglionic system: Introduction. In: Barnes L, Eveson J, Reichart P, Sidransky D, editors. *WHO Classification of Tumours*. Lyon: IARC Press; 2005. p. 361-70.
3. Choussy O, Babin E, De Barros A, Bon-Mardion N, Marie JP, Dehesdin D. Vagal paraganglioma of the neck: A case report. *Ear Nose Throat J* 2009;88:E1-3.
4. Zhu J, Han D, Zhou J. Retrospective analysis of the diagnosis and surgical treatment of carotid body tumor. *Lin Chuang Er Bi Yan Hou Ke Za Zhi* 2005;19:817-9.
5. Yuejin Y, Pei Z, Yingmao R, Laifeng S, Xinglin X, Yongli L, *et al.* Experience in surgical resection of 11 cases of carotid body tumor after ultraselection artery embolism. *Chin Med Sci J* 2002;17:236-41.
6. Bettencourt P, Friões F, Azevedo A, Dias P, Pimenta J, Rocha-Gonçalves F, *et al.* Prognostic information provided by serial measurements of brain natriuretic peptide in heart failure. *Int J Cardiol* 2004;93:45-8.
7. Tripp HF Jr, Fail PS, Beyer MG, Chaisson GA. New approach to preoperative vascular exclusion for carotid body tumor. *J Vasc Surg* 2003;38:389-91.
8. Krane J, Faquin W. Salivary gland. In: Cibas ES, Ducatman BS, editors. *Cytology, Diagnostic Principles and Clinical Correlates*. Philadelphia: Saunders; 2009. p. 285-318.
9. Moatamed NA, Naini BV, Fathizadeh P, Estrella J, Apple SK. A correlation study of diagnostic fine-needle aspiration with histologic diagnosis in cystic neck lesions. *Diagn Cytopathol* 2009;37:720-6.
10. Meacham R, Matrk L, Ozer E, Ozer HG, Wakely P, Shah M. Neuroendocrine carcinoma of the head and neck: A 20-year case series. *Ear Nose Throat J* 2012;91:E20-4.

How to cite this article: Chand P, Singh R, Singh B, Singla RL. Carotid body tumor presenting as parotid swelling misdiagnosed as pleomorphic adenoma: A rare presentation. *Niger J Surg* 2015;21:157-8.

Source of Support: Nil, **Conflicts of Interest:** None declared.