



Is Abnormal Electrodiagnostic Finding Related to the Cross-Sectional Area of the Nerve Root in Cervical Radiculopathy?

JuHyong Jeoung, MD, Hyuk Sung Choi, MD, Sang Rok Woo, MD,
Seok Kang, MD, PhD, Joon Shik Yoon, MD, PhD

Department of Physical Medicine and Rehabilitation, Korea University Guro Hospital, Seoul, Korea

Objective To assess the relevance of electrodiagnosis (EDX) in the cross-sectional area (CSA) of the nerve root of patients with cervical radiculopathy (CR) by using high-resolution ultrasonography (HRUS).

Methods The CSAs of the cervical nerve roots at C5, C6, and C7 were measured bilaterally using HRUS in 29 patients with unilateral CR whose clinical symptoms, magnetic resonance imaging (MRI) findings, and EDX results corresponded with each other (CR-A group), and in 26 patients with unilateral CR whose clinical symptoms and MRI findings matched with each other but did not correspond with the EDX findings (CR-B group).

Results The CSA of the affected side in each nerve root was significantly larger than that of the unaffected side in both the CR-A and CR-B groups. The side-to-side difference in the bilateral CSAs of the nerve root and the ratio of the CSAs between the unaffected and affected sides were statistically larger in the CR-A group than in the CR-B group.

Conclusion The increased CSAs in the CR-A group reflect the physiological changes of the cervical nerve root, which is supported by the EDX findings.

Keywords Radiculopathy, Electrodiagnosis, Magnetic resonance imaging, Spinal nerve roots, Ultrasonography

INTRODUCTION

Cervical radiculopathy (CR) is one of the main categories of cervical spondylosis, which is a degenerative aging process that affects the cervical spine structure [1]. It is a pathological process that affects the nerve root exiting the

spinal cord via compression or inflammation at the nerve root or its surroundings [2]. The diagnosis of CR involves a comprehensive process that encompasses various diagnostic methods, such as patient history and physical examination, and modalities, such as magnetic resonance imaging (MRI) and electrodiagnosis (EDX) [1,3].

Received July 30, 2020; Revised September 8, 2020; Accepted October 8, 2020; Published online April 30, 2021

Corresponding author: Joon Shik Yoon

Department of Physical Medicine and Rehabilitation, Korea University Guro Hospital, 148 Gurodong-ro, Guro-gu, Seoul 08308, Korea. Tel: +82-2-2626-1500, Fax: +82-2-2626-1513, E-mail: rehab46@korea.ac.kr

ORCID: JuHyong Jeoung (<https://orcid.org/0000-0002-2671-893X>); Hyuk Sung Choi (<https://orcid.org/0000-0002-0987-2185>); Sang Rok Woo (<https://orcid.org/0000-0003-0248-8153>); Seok Kang (<https://orcid.org/0000-0001-5614-4175>); Joon Shik Yoon (<https://orcid.org/0000-0002-8985-279X>).

© This is an open-access article distributed under the terms of the Creative Commons Attribution Non-Commercial License (<http://creativecommons.org/licenses/by-nc/4.0>) which permits unrestricted noncommercial use, distribution, and reproduction in any medium, provided the original work is properly cited.
Copyright © 2021 by Korean Academy of Rehabilitation Medicine

MRI is the technique of choice for the diagnosis of CR [4]. It can visualize the neural structure directly and non-invasively. In addition, it has a higher predictive value than other imaging modalities [5]. However, it is not readily available owing to its high cost and contraindications such as the presence of a pacemaker, defibrillator, or deep brain stimulator.

The usefulness of high-resolution ultrasonography (HRUS) has emerged as a complementary modality because of its easy accessibility. Moreover, it can identify nerve enlargement due to pathological changes by measuring the cross-sectional area (CSA) of the nerve [6]. Recently, several studies have evaluated the cervical nerve root by using HRUS. For example, one study measured the normative reference values for the CSA of the cervical nerve root at each level [7] and identified swelling of the cervical nerve root in patients with chronic inflammatory demyelinating polyradiculoneuropathy by measuring the CSA [8]. Other studies have also identified swelling of the cervical nerve root in patients with CR by using ultrasonography [9,10]. In these studies, ultrasonography findings confirmed that the cervical nerve root was more swollen on the affected side than on the unaffected side.

However, in previous studies for identifying cervical root swelling in patients with CR, EDX was not included as an essential diagnostic modality. For example, in our previous study [9], we performed ultrasonography scanning of the cervical nerve root of patients with symptomatic CR who showed abnormal findings in at least one of the two diagnostic tests, namely MRI or EDX. In addition, Takeuchi et al. [10] did not consider EDX as a diagnostic tool for CR and performed the ultrasonography scanning of symptomatic patients who showed abnormal MRI findings.

Several studies have reported cases in which the patient's symptoms did not correspond with the MRI findings. Moreover, in one study, patients who had definite disc herniation or degenerative disc disease on MRI findings did not have any clinical symptoms [5]; MRI findings do not reflect the physiological state of the nerve roots in patients with CR. By contrast, EDX tests reflect the physiological and functional status of the nerve root [11].

Although the two modalities provide different kinds of information (structural vs. functional), they are complementary and not mutually exclusive. Thus, relying solely on one diagnostic procedure may be misleading and

counterproductive [12].

Some cases showed inconsistency between MRI and EDX findings [13,14]. Therefore, if the MRI and EDX findings at the same nerve root level are both abnormal, this can be assumed to reflect the pathophysiological status of the CR better. Considering these findings, we hypothesized that if we measure the CSAs of patients with CR who have not only abnormal MRI findings but also abnormal EDX findings at the same cervical level, some difference in the CSA of the cervical nerve root would be observed between these patients and those with abnormal MRI findings only. Thus, we aimed to assess the relevance of EDX and MRI findings from the CSA of the nerve root in patients with CR by using HRUS.

MATERIALS AND METHODS

Subjects and data collection

This prospective study was conducted from March 2019 to December 2019 at our clinic in patients with clinical symptoms of CR who were referred to the Department of Physical Medicine and Rehabilitation. All the patients included in this study exhibited various symptoms, such as pain in the neck or unilateral upper extremity, and sensory symptoms, such as paresthesia, numbness, or tingling sensation, or weakness corresponding to the involved myotome. In addition, patients who showed abnormal findings on physical examinations such as manual muscle test, Spurling's sign, axial compression test, or shoulder abduction relief sign that suggested CR were included in this study. Patients with bilateral or multilevel CR, myelopathy, history of surgical intervention, diabetes, or other systemic organ dysfunction were excluded.

After screening patients using the above-mentioned criteria, both MRI and EDX were performed to confirm the diagnosis of radiculopathy and the involved cervical segment level.

The abnormal MRI findings that indicated CR in this study were as follows: foraminal stenosis by disc herniation, focal compression by bony structures, or displacement of the nerve root. In addition, EDX was performed to obtain information about the physiological state of the cervical nerve root corresponding with the symptoms. In the patients with CR, the sensory nerve action potentials were usually within the reference range, and compound

motor action potentials were within the reference range or reduced. In needle EDX, neuropathic motor unit action potentials and reduced recruitment patterns were observed in the myotomes of the affected cervical level. In addition to these findings, abnormal spontaneous activities can be found in some patients. On the basis of these findings, we identified a patient with cervical radiculopathy.

After MRI and EDX analyses, the involved patients were classified as follows. First, patients who showed abnormal findings on both tests were selected as CR group A (CR-A). Next, the patients who showed abnormal MRI findings only were selected as CR group B (CR-B). Finally, 29 and 26 patients were enrolled in the CR-A and CR-B groups, respectively. Ultrasonography scanning was performed for both patient groups to measure the CSA of the cervi-

cal nerve root. All the participants provided informed consent, and this study was approved by the Institutional Review Board of Korea university Guro Hospital.

Ultrasonographic measurements

A ultrasonography scan for the cervical nerve roots was performed in the CR-A and CR-B patient groups. The physiatrist who performed ultrasonography scanning had >5 years of experience in musculoskeletal ultrasonography. Ultrasonography scanning was performed bilaterally for all eligible patients to compare the affected and unaffected sides. The cervical roots were scanned using HRUS (RS85; Samsung Medison, Seoul, Korea), primarily interfaced with a 3- to 12-MHz linear-array transducer. During the examination, the patients were asked to lie supine. Ultrasonography scanning began

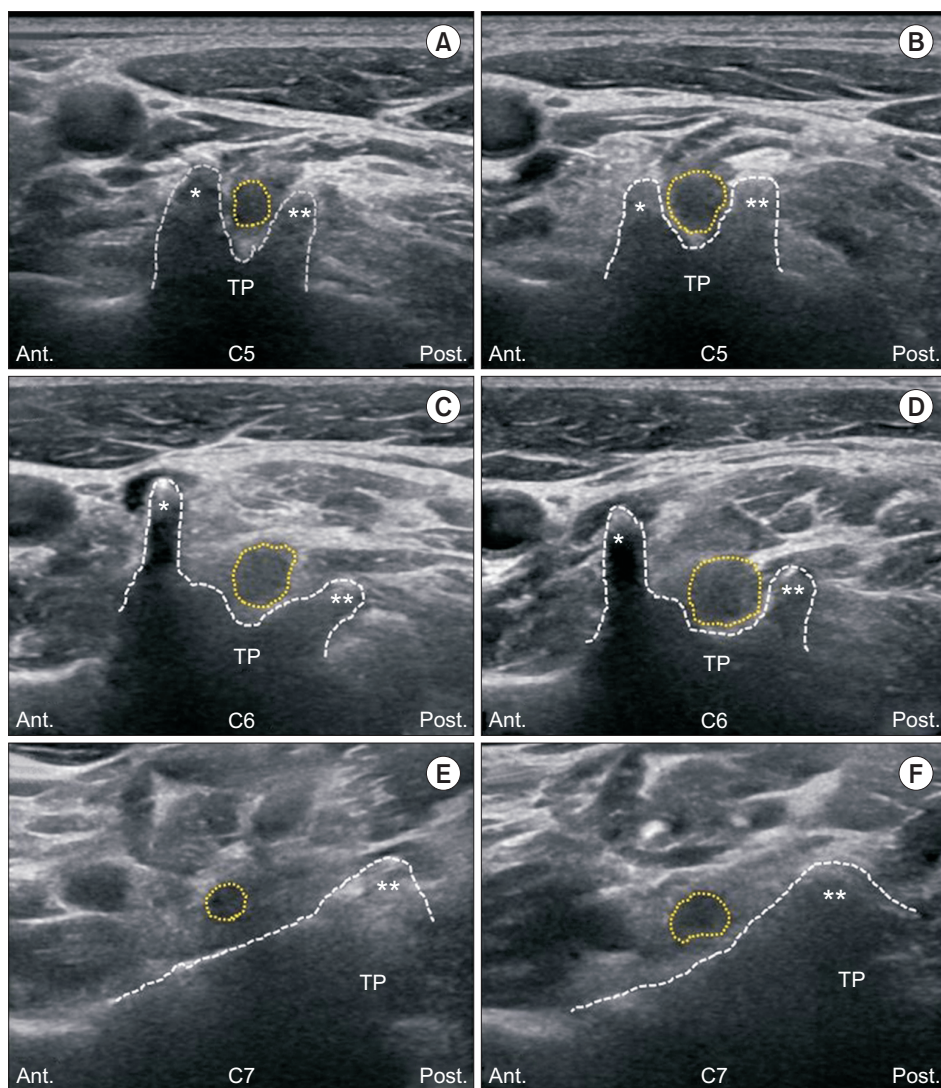


Fig. 1. Transverse ultrasonographic images of the cervical nerve root. (A, C, E) Unaffected side of the C5, C6, and C7 nerve roots, respectively. (B, D, F) Affected side of the C5, C6, and C7 nerve roots, respectively. Ant., anterior; Post., posterior; TP, transverse process; *, anterior tubercle; **, posterior tubercle; dotted circle, nerve root; dotted line, shape of the tubercles of the cervical spine.

with the identification of the C6 transverse process. After identifying the cricoid cartilage of the neck first, at the same level (C6), the transducer was moved laterally to find the C6 transverse process. From the transverse plane, the nerve root passing between the anterior and posterior tubercles could be identified. The transducer was moved superiorly or inferiorly from the C6 transverse process to image the C5 and C7 nerve roots. To obtain the most accurate representative value of the CSA, the transducer was maintained at the most proximal location as possible, typically at the point where the nerve root

exited over the transverse process [7]. The transducer was then manipulated on the skin until the most accurate representation of the CSA could be obtained, with the most circular shape and brightest echo of the nerve root, representing the absence of anisotropy [7,15]. As a previous study demonstrated that the C8 root is technically difficult to visualize in individuals who are obese or have a short neck and that ultrasonography measurement of the C8 root is relatively inaccurate, it was excluded from this study [15]. The CSA of each nerve root was measured using the trace function of the ultrasonography device, tracing just inside the hyperechoic rim of each nerve root. Fig. 1 shows the transverse ultrasonographic images from each level of the unaffected and affected nerve roots of a patient with CR and how we measured the CSA of the nerve roots. Fig. 1A, 1C, and 1E show the unaffected side of the C5, C6, and C7 nerve roots, respectively; Fig. 1B, 1D, and 1F show the affected side of the C5, C6, and C7 nerve roots, respectively. The dotted circles show the sectional shape of the cervical nerve root.

Table 1. Baseline characteristics of the CR-A and CR-B patient groups

	CR-A (n=29)	CR-B (n=26)	p-value
C5 NR			
Right	2 (40)	2 (67)	
Left	3 (60)	1 (33)	
C6 NR			
Right	6 (67)	5 (63)	
Left	3 (33)	3 (37)	
C7 NR			
Right	9 (60)	10 (67)	
Left	6 (40)	5 (33)	
Sex			0.244
Male	19	13	
Female	10	13	
Age (yr)	62 (55-67)	60 (57-65)	0.472
BMI (kg/m ²)	27 (25-29)	28 (26-29)	0.765

Values are presented as number (%) or median (interquartile range).

CR-A, cervical radiculopathy group A; CR-B, cervical radiculopathy group B; NR, nerve root; BMI, body mass index.

Statistical analysis

Statistical analysis was performed using the SPSS version 22.0 software (IBM, Armonk, NY, USA). Owing to the small sizes of the patient groups, a normal distribution could not be assumed. Therefore, we used a non-parametric test. The Mann-Whitney U test and Pearson chi-square test were used to analyze the categorical demographic data (Table 1). The Wilcoxon signed-rank test was performed instead of a paired t-test to compare the difference in the CSAs of the nerve roots between the affected and unaffected sides in both patient groups (Table 2).

Side-to-side differences of the nerve root CSAs between

Table 2. CSAs of the cervical NRs of the CR-A and CR-B patient groups

CSA (mm ²)	CR-A		CR-B		p-value (affected vs. unaffected)	
	Affected side	Unaffected side	Affected side	Unaffected side	CR-A	CR-B
C5 NR	11.21 (9.98-12.63)	7.87 (6.85-9.11)	10.96 (9.45-11.55) ^{a)}	8.11 (7.63-8.67) ^{a)}	0.016*	0.036*
C6 NR	13.32 (12.27-14.68)	10.05 (9.64-10.77)	12.81 (11.94-13.88)	10.62 (9.61-11.95)	0.022*	0.031*
C7 NR	14.80 (13.57-15.74)	11.83 (10.31-13.04)	13.54 (12.43-4.77)	12.49 (11.67-13.64)	0.027*	0.043*

Values are presented as median (interquartile range).

CSA, cross-sectional area; CR-A, cervical radiculopathy group A; CR-B, cervical radiculopathy group B; NR, nerve root.

^{a)}The interquartile range value could not be obtained because of the small sample size.

*p<0.05.

Table 3. S-S difference and S-S ratio of the cervical NRs in the CR-A and CR-B patient groups

Δ CSA (mm ²)	S-S difference		S-S ratio		p-value	
	CR-A	CR-B	CR-A	CR-B	S-S difference	S-S ratio
C5 NR	3.33 (2.95-3.67)	2.85 (1.82-2.88) ^{a)}	1.42 (1.24-1.62)	1.33 (1.24-1.35) ^{a)}	0.021*	0.038*
C6 NR	2.61 (2.24-2.97)	2.36 (1.95-2.68)	1.30 (1.13-1.49)	1.11 (1.05-1.17)	0.045*	0.035*
C7 NR	3.05 (2.60-3.24)	1.45 (1.03-1.84)	1.26 (1.15-1.38)	1.12 (1.05-1.23)	0.012*	0.044*

Values are presented as median (interquartile range).

CSA, cross-sectional area; CR-A, cervical radiculopathy group A; CR-B, cervical radiculopathy group B; S-S difference, difference in CSAs between the affected and unaffected sides; S-S ratio, ratio of the CSAs between the unaffected and affected sides; NR, nerve root.

^{a)}The interquartile range value could not be obtained because of the small sample size.

*p<0.05.

the affected and unaffected sides (S-S difference) were calculated in both patient groups. In addition, the ratio of the CSAs between the unaffected and affected sides (S-S ratio) was calculated. The Mann-Whitney U test was performed to obtain the statistical results for the S-S difference and S-S ratio (Table 3). A p-value of <0.05 was considered statistically significant.

RESULTS

From ultrasonography scanning, the CSAs of the affected and unaffected sides of the CR-A and CR-B groups were measured. Then, the S-S difference in the CSAs of the nerve root at the same level between the affected and unaffected sides was obtained. In addition, we calculated the S-S ratio of the CSA between the affected and unaffected sides.

The baseline characteristics of the patients in the CR-A and CR-B groups are shown in Table 1. No statistically significant differences in sex, age, and body mass index were found between the CR-A and CR-B groups. The median CSA values of the affected and unaffected sides of the cervical nerve roots in the CR-A and CR-B groups are shown in Table 2. The CSAs of the affected nerve roots were statistically significantly larger than those of the unaffected nerve roots in both the CR-A and CR-B groups.

The S-S difference and S-S ratio of each cervical nerve root in the CR-A and CR-B groups are shown in Table 3. The S-S difference and S-S ratio in the CR-A group were statistically larger than those in the CR-B group.

DISCUSSION

In a previous study on the diagnostic modality for CR, Ashkan et al. [14] suggested that in neurosurgery patients with CR symptoms, a sufficient clinical assessment needs only to be supplemented with confirmatory evidence from an MRI scan, and the routine neurophysiological studies are not required. However, structural abnormalities on MRI do not necessarily indicate the underlying cause of the presenting clinical symptoms [16]. Some patients who had no symptoms at all showed abnormal MRI findings, including disc herniation in 10% of asymptomatic subjects aged <40 years and foraminal stenosis in 20% of subjects aged >40 years [17]. Moreover, MRI itself cannot reflect the physiological and functional changes in the nerve root. In this regard, EDX is a diagnostic method that can compensate for the limitations of MRI. Electrophysiological studies can assess the dynamic changes in nerve root function and rule out other neurological causes such as entrapment neuropathies or peripheral neuropathy. They can also provide prognostic information about the treatment outcomes of surgical procedures. Nicotra et al. [17] suggested that in patients who are planned to undergo surgery whose EDX and MRI findings are discordant, the EDX abnormalities will correspond more to the clinical level of symptoms because they represent the functional compromise of the nerve root. However, EDX also has several limitations. For example, owing to the nature of the test, it is painful, and it may not provide an accurate diagnosis of conditions such as mild or sensory dominant radiculopathy [14]. Therefore, in the diagnosis of CR, the two modalities complement each other.

In our previous study, we measured the CSAs of symptomatic patients with CR confirmed using at least one of the two modalities, MRI or EDX [9]. In this study, however, we screened patients who had both abnormal MRI and EDX findings at the same root level (CR-A). We then compared the CSAs of the cervical nerve roots in the group with those in the patient group who had abnormal MRI findings only (CR-B). We assumed that greater swelling of the nerve root will be found in the CR-A group than in the CR-B group because abnormal EDX findings would reflect the abnormal physiological state of the nerve root and the CR status better. Through this comparison, we proved the hypothesis that the CSAs of the cervical nerve roots would have some difference between the groups.

In entrapment neuropathies, the external compression of a nerve causes internal structural changes. Impaired venous flow leads to increased intraneural interstitial pressure, resulting in reversible intraneural edema. Through HRUS, the swollen appearance of the entrapped nerve root can be identified. These ultrasonography findings in patients with entrapment neuropathies reflect the aforementioned pathophysiological reactions [18,19]. In this study, we measured the CSAs of the cervical nerve roots in the CR-A and CR-B groups. Our results showed that the S-S difference and S-S ratio were greater in the CR-A group than in the CR-B group. This result can be thought of as reflecting the abnormal physiological conditions of the nerve root, as supported by the EDX test result.

This study has several limitations. First, the small population size may have influenced the results and prevented a generalization about the effect of adding the EDX element in the CSAs of nerve roots. Therefore, further investigations with more patients with CR are necessary to identify meaningful differences in CSA between the CR-A and B groups.

Second, the ultrasonography scanning of cervical nerve roots was performed by one physiatrist, so inter-examiner consistency could not be verified. Moreover, ultrasonography is an operator-dependent test, and because the examiner was not blinded, bias may have affected the measurements of the CSAs.

In conclusion, the CSAs of the nerve roots in the symptomatic patients who showed both abnormal MRI and EDX findings were greater than those in the patients who showed abnormal MRI findings only. The increased CSAs

in the CR-A group reflect the physiological changes of the cervical nerve root, which is supported by the EDX findings.

CONFLICT OF INTEREST

No potential conflict of interest relevant to this article was reported.

ACKNOWLEDGMENTS

This research was supported by Basic Science Research Program through the National Research Foundation of Korea (NRF) funded by the Ministry of Science, ICT & Future Planning (No. NRF-2020R1A2C1009024).

AUTHOR CONTRIBUTION

Conceptualization: Jeoung JH, Yoon JS. Methodology: Jeoung JH, Yoon JS. Formal analysis: Jeoung JH. Funding acquisition: Yoon JS. Project administration: Choi HS, Woo SR. Visualization: Jeoung JH. Writing - original draft: Jeoung JH. Writing - review and editing: Kang S, Yoon JS. Approval of final manuscript: all authors.

REFERENCES

1. Abbed KM, Coumans JV. Cervical radiculopathy: pathophysiology, presentation, and clinical evaluation. *Neurosurgery* 2007;60(1 Suppl 1):S28-34.
2. Ellenberg MR, Honet JC, Treanor WJ. Cervical radiculopathy. *Arch Phys Med Rehabil* 1994;75:342-52.
3. Van Zundert J, Huntoon M, Patijn J, Lataster A, Mekhail N, van Kleef M, et al. Cervical radicular pain. *Pain Pract* 2010;10:1-17.
4. Manelfe C. Imaging of the spine and spinal cord. *Curr Opin Radiol* 1991;3:5-15.
5. Malanga GA. The diagnosis and treatment of cervical radiculopathy. *Med Sci Sports Exerc* 1997;29(7 Suppl):S236-45.
6. Bianchi S. Ultrasound of the peripheral nerves. *Joint Bone Spine* 2008;75:643-9.
7. Haun DW, Cho JC, Kettner NW. Normative cross-sectional area of the C5-C8 nerve roots using ultrasonography. *Ultrasound Med Biol* 2010;36:1422-30.
8. Tazawa K, Matsuda M, Yoshida T, Shimojima Y, Gono

- T, Morita H, et al. Spinal nerve root hypertrophy on MRI: clinical significance in the diagnosis of chronic inflammatory demyelinating polyradiculoneuropathy. *Intern Med* 2008;47:2019-24.
9. Kim E, Yoon JS, Kang HJ. Ultrasonographic cross-sectional area of spinal nerve roots in cervical radiculopathy: a pilot study. *Am J Phys Med Rehabil* 2015;94:159-64.
 10. Takeuchi M, Wakao N, Hirasawa A, Murotani K, Kamiya M, Osuka K, et al. Ultrasonography has a diagnostic value in the assessment of cervical radiculopathy: a prospective pilot study. *Eur Radiol* 2017;27:3467-73.
 11. Lance JW, Burke D. Mechanisms of spasticity. *Arch Phys Med Rehabil* 1974;55:332-7.
 12. Reza Soltani Z, Sajadi S, Tavana B. A comparison of magnetic resonance imaging with electrodiagnostic findings in the evaluation of clinical radiculopathy: a cross-sectional study. *Eur Spine J* 2014;23:916-21.
 13. Partanen J, Partanen K, Oikarinen H, Niemitukia L, Hernesniemi J. Preoperative electroneuromyography and myelography in cervical root compression. *Electromyogr Clin Neurophysiol* 1991;31:21-6.
 14. Ashkan K, Johnston P, Moore AJ. A comparison of magnetic resonance imaging and neurophysiological studies in the assessment of cervical radiculopathy. *Br J Neurosurg* 2002;16:146-8.
 15. Won SJ, Kim BJ, Park KS, Kim SH, Yoon JS. Measurement of cross-sectional area of cervical roots and brachial plexus trunks. *Muscle Nerve* 2012;46:711-6.
 16. Jensen MC, Brant-Zawadzki MN, Obuchowski N, Modic MT, Malkasian D, Ross JS. Magnetic resonance imaging of the lumbar spine in people without back pain. *N Engl J Med* 1994;331:69-73.
 17. Nicotra A, Khalil NM, O'Neill K. Cervical radiculopathy: discrepancy or concordance between electromyography and magnetic resonance imaging? *Br J Neurosurg* 2011;25:789-90.
 18. Bianchi S, Montet X, Martinoli C, Bonvin F, Fasel J. High-resolution sonography of compressive neuropathies of the wrist. *J Clin Ultrasound*. 2004;32:451-61.
 19. G Bodner. Nerve compression syndromes. In: Peer S, Bodner G, editors. *High-resolution sonography of the peripheral nervous system*. 2nd ed. Berlin, Germany: Springer; 2008. p. 72-122.