

Prediction accuracy of incisal points in determining occlusal plane of digital complete dentures

Kenta Kashiwazaki¹, Yuriko Komagamine^{1*}, Sahaprom Namano¹, Ji-Man Park², Maiko Iwaki³, Shunsuke Minakuchi¹, Manabu Kanazawa³

¹Gerodontology and Oral Rehabilitation, Graduate School of Medical and Dental Sciences, Tokyo Medical and Dental University (TMDU), Tokyo, Japan

²Department of Prosthodontics and Dental Research Institute, Seoul National University School of Dentistry, Seoul, Republic of Korea

³Digital Dentistry, Graduate School of Medical and Dental Sciences, Tokyo Medical and Dental University (TMDU), Tokyo, Japan

ORCID

Kenta Kashiwazaki

<https://orcid.org/0009-0004-9593-8444>

Yuriko Komagamine

<https://orcid.org/0000-0001-8769-5121>

Sahaprom Namano

<https://orcid.org/0000-0003-1832-8621>

Ji-Man Park

<https://orcid.org/0000-0003-0018-1166>

Maiko Iwaki

<https://orcid.org/0000-0001-5326-9482>

Shunsuke Minakuchi

<https://orcid.org/0000-0003-2217-7539>

Manabu Kanazawa

<https://orcid.org/0000-0003-2587-5455>

Corresponding author

Yuriko Komagamine

Gerodontology and Oral Rehabilitation, Graduate School of Medical and Dental Sciences, Tokyo Medical and Dental University (TMDU), 1-5-45 Yushima, Bunkyo-ku, Tokyo 113-8549, Japan

Tel +81-03-5803-4645

E-mail

y.komagamine.gerd@tmd.ac.jp

Received July 15, 2023 /

Last Revision October 21, 2023 /

Accepted December 15, 2023

This study received financial support from Emium Co., Ltd. (Tokyo, Japan) and Core Concept Technology Co., Ltd. (Tokyo, Japan), although the data interpretation and presentation of the information were not influenced by this personal or financial relationship.

PURPOSE. This study aimed to predict the positional coordinates of incisor points from the scan data of conventional complete dentures and verify their accuracy.

MATERIALS AND METHODS. The standard triangulated language (STL) data of the scanned 100 pairs of complete upper and lower dentures were imported into the computer-aided design software from which the position coordinates of the points corresponding to each landmark of the jaw were obtained. The x, y, and z coordinates of the incisor point (X_p , Y_p , and Z_p) were obtained from the maxillary and mandibular landmark coordinates using regression or calculation formulas, and the accuracy was verified to determine the deviation between the measured and predicted coordinate values. Y_p was obtained in two ways using the hamular-incisive-papilla plane (HIP) and facial measurements. Multiple regression analysis was used to predict Z_p . The root mean squared error (RMSE) values were used to verify the accuracy of the X_p and Y_p . The RMSE value was obtained after cross-validation using the remaining 30 cases of denture STL data to verify the accuracy of Z_p . **RESULTS.** The RMSE was 2.22 for predicting X_p . When predicting Y_p , the RMSE of the method using the HIP plane and facial measurements was 3.18 and 0.73, respectively. Cross-validation revealed the RMSE to be 1.53. **CONCLUSION.** Y_p and Z_p could be predicted from anatomical landmarks of the maxillary and mandibular edentulous jaw, suggesting that Y_p could be predicted with better accuracy with the addition of the position of the lower border of the upper lip. [J Adv Prosthodont 2023;15:281-9]

KEYWORDS

Automation; Incisor point; Anatomical landmarks; Digital complete dentures; CAD

© 2023 The Korean Academy of Prosthodontics

© This is an Open Access article distributed under the terms of the Creative Commons Attribution Non-Commercial License (<https://creativecommons.org/licenses/by-nc/4.0>) which permits unrestricted non-commercial use, distribution, and reproduction in any medium, provided the original work is properly cited.

INTRODUCTION

Most of the fabrication processes of conventional complete dentures are automated in the fabrication process of digital complete dentures,¹⁻³ but virtual tooth arrangement and festooning require the skilled experience and technical skills of dental technicians. Therefore, even during the fabrication of complete digital dentures, skilled computer technicians perform tooth arrangements and festooning. In addition, the fabrication process of digital complete dentures can be completed without the “trial fitting” time for the patient; however, many studies have recommended a trial fitting time because patients often complain about the esthetic aspect of the final digital dentures.⁴ Even skilled dentists may make errors in checking the lip support and position of the anterior incisors, which are related to esthetic complaints.

Although no studies have reported the automation of festooning, several reports have been published on the automation of tooth arrangement. Busch and Kordass⁵ reported a method of tooth arrangement based on information only from edentulous maxillary and mandibular jaws. They performed a brief maxillomandibular registration at the chairside and determined the occlusal vertical dimension and occlusal plane between the edentulous maxillary and mandibular jaws based on additional information from the lower margin of the upper lip and the midline of the face. They constructed an algorithm that automatically calculated the position of the tooth arrangement based on the interalveolar crest line and the residual ridge crest from the anterior teeth to the molars. Dai *et al.*⁶ constructed an algorithm for formulating an ideal artificial tooth position curve that can calculate the position of artificial teeth following maxillomandibular registration. Yu *et al.*⁷ developed an original method for virtual tooth arrangement based on information obtained from scanned models of the upper and lower dentures, anatomical features of the midline of the face, and anatomical features of the upper and lower jaws. Thus, the current automation of tooth arrangement has focused on determining the dental arch, artificial teeth position, and tooth arrangement methods. However, preventing errors in molar tooth arrangement and reducing the frequen-

cy of rearrangement of all tooth arrangements would be possible if the position of the anterior teeth, which greatly affects the esthetics, can be automatically determined.

Therefore, we investigated a method for automatically determining the occlusal plane from the maxillary and mandibular edentulous jaw data. The occlusal plane was assumed to be parallel to the hamular-incisive-papilla (HIP) plane,^{8,9} which can be determined from the maxillary landmarks. Because the occlusal plane is determined by at least three points, two points behind the occlusal plane were set as one-half of the retromolar pad (RP)¹⁰ and the remaining point was set as the incisal point, which is the mid-point between the proximal angles of the left and right central incisors of the mandible. The occlusal plane can be determined automatically once the incisor point is determined. Furthermore, the position of the anterior teeth can be automatically determined, and the artificial teeth can be automatically arranged.

This study aimed to obtain the positional coordinates of each landmark from the scan data of edentulous maxilla and mandible for complete dentures and to verify the prediction and accuracy of the positional coordinates of the incisor points.

MATERIALS AND METHODS

In this study, the upper and lower complete dentures used by edentulous participants were scanned, and the standard triangulated language (STL) data of the scanned dentures were imported into the computer-aided design (CAD) software. Finally, the position coordinates of the points corresponding to each landmark on the jaw were obtained from the points in the STL denture data.

The protocol for this study was approved by the Ethics Review Committee of our institution (D2019-062) and registered with the University Hospital Medical Information Network Center (UMIN-CTR Unique Trial No. UMIN 000042470).

The selection criteria for the study participants were as follows: (i) complete denture fabrication and adjustment at the university by dentists with at least 10 years of experience and who had obtained specialist qualifications in prosthodontics, (ii) received a full ex-

planation of the study, fully understood, and consented to it in writing of their own free will and (iii) all necessary landmarks must be covered by the denture. In addition, those who (i) did not meet the selection criteria or (ii) requested to withdraw consent were excluded. Written informed consent was obtained from all the participants and only those who provided informed consent were included in the study. The upper and lower complete dentures of 100 patients which both the patients and the operators judged to have no problems with retention and stability, were scanned with an extraoral scanner (E3; 3Shape A/S). Then, the STL data were obtained and imported into AutoDesk Fusion 360 3D modeling program (AutoDesk, San Rafael, CA, USA) that enabled the measurements of the distance between each landmark of the jaw, which were used for the calculation and prediction of the coordinates of the incisor points, the midpoint between the proximal angles of the left and right mandibular central incisors, on the edentulous jaw data. In addition, the scanned upper and lower complete dentures were fabricated in the ideal midline and occlusal plane, and the predicted values using anatomical landmarks in this study were compared on this basis. Regarding the identification of each anatomical landmark in the data, the left and right hamular notches were considered to be particularly difficult to identify among the anatomical landmarks used in this study. Therefore, inter-rater reliability was determined by identifying the left and right hamular notches in 10 cases by three dentists in advance. As a result, the interclass correlation coefficients (ICCs) of the right and left hamular notches were 0.99 and 0.99, respectively, in all x-, y-, and z-coordinates, indicating a high inter-rater reliability among the three dentists. Therefore, the identification of each anatomical landmark in the 100 cases in this study was performed by only one of the three dentists.

The incisal point for automated occlusal plane determination was predicted. First, the occlusal plane was assumed to be parallel to the HIP plane, which can be determined from the maxillary landmarks. Since the occlusal plane is determined by at least three points, two points posterior to the occlusal plane were set as the center of the retromolar pad, and the remaining one point was set as the incisal

points. Each landmark on the maxillary and mandibular jaws was shown as a point on the spatial coordinates constructed from the x-, y-, and z-axes. The x-axis is the left-right direction of the incisor point viewed from the frontal plane, the y-axis is the vertical direction of the incisor point viewed from the frontal plane, and the z-axis is the anteroposterior direction of the incisor point viewed from the frontal plane (Fig. 1). In addition, the incisor point was set as the origin for all scan data.

The x-, y-, and z-coordinates of the incisor points (X_p , Y_p , and Z_p) were obtained from the coordinates of landmarks in the maxilla and mandible, respectively, using regression or calculation formulas, and the accuracy was verified to determine the deviation between the measured and predicted coordinate values. The landmarks used to predict the positional coordinates of the incisor points were the posterior margin of the hamular notch (HN), the center of the incisive papilla (IP) of the maxilla, and the center of the retromolar pad (RP) of the mandible (Fig. 1). X_p and Y_p were obtained from the formulas, and Z_p was obtained from the regression equations. To verify the accuracy of each coordinate, root mean squared error (RMSE) values were obtained for X_p and Y_p , and the RMSE values for Z_p were obtained by cross-validation.

X_p was calculated by assuming that the midline of the maxillary palate was equal to the midline of the face. That is, the x-coordinate of the midpoint of the

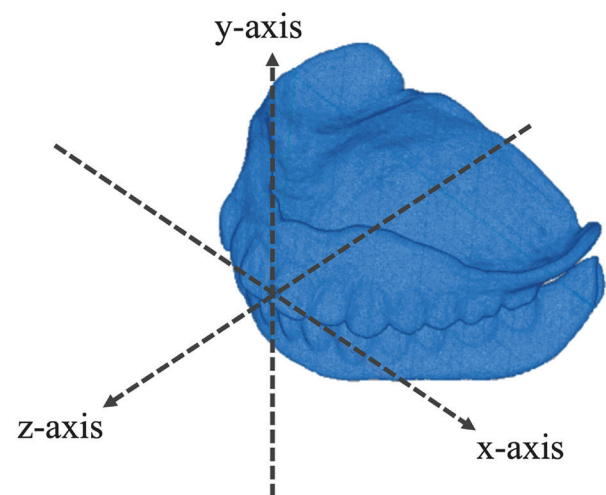


Fig. 1. Three coordinates and each landmark on the upper and lower jaws.

line connecting the left and right HNs was used as the predicted X_p (Fig. 2).

The following two methods were used to calculate the Y_p .

Y_p was calculated assuming that the HIP plane is parallel to the occlusal plane. More specifically, Y_p was calculated assuming that the vertical line segment from IP, the anterior reference point of the HIP plane, down to the occlusal plane (h_1) and the vertical line segment from RP, the posterior reference point of the occlusal plane, up to the HIP plane (h_2) are equal. However, because RP exists on both sides, when Y_p was calculated, the average value of h_2 was used (Fig. 3).

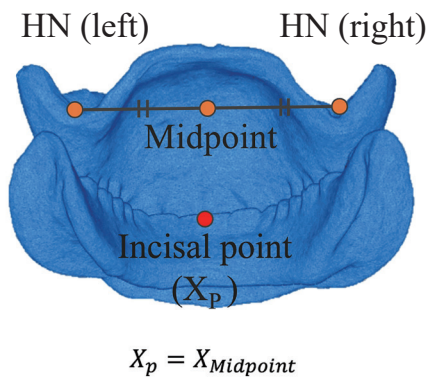


Fig. 2. How to obtain x-coordinates of incisal point. $X_{Midpoint}$, x-coordinate of the midpoint of the line connecting the left and right HNs.

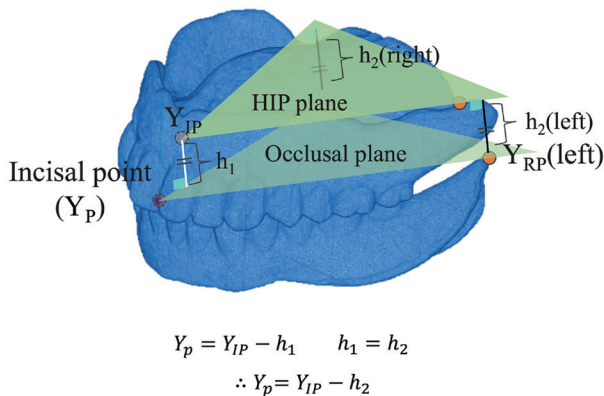


Fig. 3. How to obtain y-coordinates of incisor point by the method using the HIP plane. Y_{IP} , y-coordinate of the IP; Y_{RP} , y-coordinate of the RP; h_1 , distance of vertical line segment from IP to the occlusal plane; h_2 , distance of vertical line segment from RP to the HIP plane.

The distance from IP to the lower border of the upper lip was measured using calipers as shown in Fig. 4 and Fig. 5, and the measured distance was subtracted from Y_{IP} . The direction of measurement was from the IP to the lower border of the upper lip. Regarding facial measurements, as with the identification of the landmark, inter-rater reliability was determined by performing facial measurements in 10 cases by three dentists. As a result, the ICC was 0.89, indicating high inter-rater reliability among the three dentists. Therefore, the facial measurements of the 100 cases in this study were performed one at a time by only one of the three dentists.

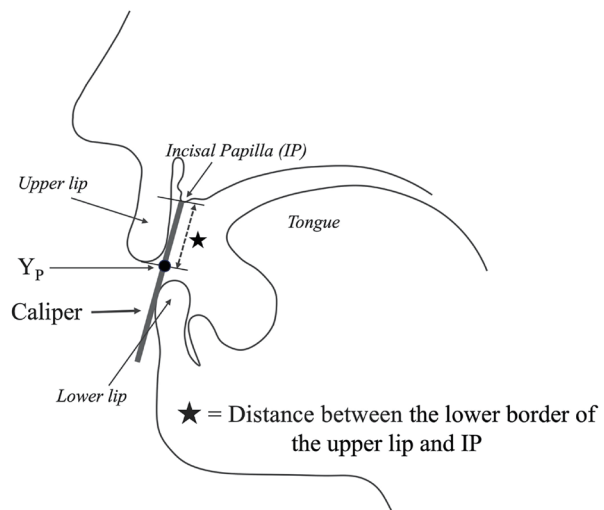


Fig. 4. How to obtain y-coordinates of incisor point by the method using the facial measurement.

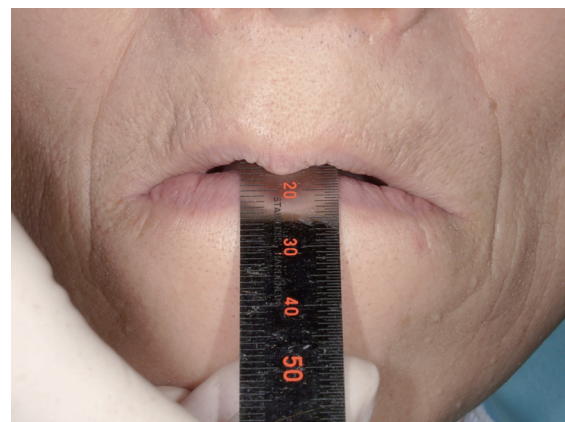

Fig. 5. Photograph of the facial measurement.

Z_p was predicted by a multiple regression analysis using the line segment A-D shown in Fig. 6 between the landmarks. The lines are defined as follows: line segment A (LA) is defined as the bottom of the right triangle abc, line segment B (LB) is the perpendicular bisector of the HIP plane, line segment C (LC) is the distance of the line connecting the IP and HN, and line segment D (LD) is half the distance of the line connecting the left and right HN. As LC exists on both sides of the HIP plane, the average value was used in obtaining the length of LC in this study. Lengths of LA-LD were calculated by assuming that the HIP plane is an isosceles triangle and applying the cubic equation theorem. For multiple regression analysis, randomly selected 70 cases of the STL data were used, with the sum of the lengths of LA and LB as the dependent variables and the lengths of LC and LD as the independent variables. Z_p was predicted by adding the lengths of LA and LB to the z-coordinate value of the midpoint of the line connecting the left and right HN ($Z_{Midpoint}$). The stepwise method was used to select variables for the multiple regression analysis.

The RMSE was used to verify the accuracy of X_p and Y_p . The RMSE is the square root of the difference between the observed and predicted values. The formula used to calculate the RMSE is shown below.

$$RMSE = \sqrt{\frac{1}{n} \sum_{i=1}^n (y_i - \hat{y}_i)^2}$$

y_i : Observed value, (\hat{y}_i): Predicted value, n: Total sample size

A smaller RMSE indicates that the predicted values are closer to the measured values, suggesting better prediction. Multiple regression analysis for Z_p prediction was conducted using the SPSS software (version 23.0, IBM). To verify the accuracy of Z_p , the RMSE value was obtained after cross-validation using the remaining 30 cases of denture STL data that were not used in the multiple regression analysis. Cross-validation refers to a method in statistics in which sample data are divided, a portion of the data is first analyzed, and the remaining portion is used to test the analysis and confirm the validity of the analysis itself.¹¹ In this study, the regression equations obtained by multiple regression analysis in randomly selected 70 cases of the denture STL were used to calculate the Z_p of the remaining 30 cases of denture STL data, and their accuracy was assessed by the RMSE value.

In this study, the x- and y-coordinates of the incisal point were calculated by a formula; whereas, for the z-coordinate, multiple regression analysis was used to predict the coordinates. To calculate the sample size for the multiple regression analysis, the effect size was set to 0.15, the significance level to 5%, the power to 80%, and the number of independent variables to 2, and the required sample size calculated using G* power was 68. Therefore, the sample size was set to

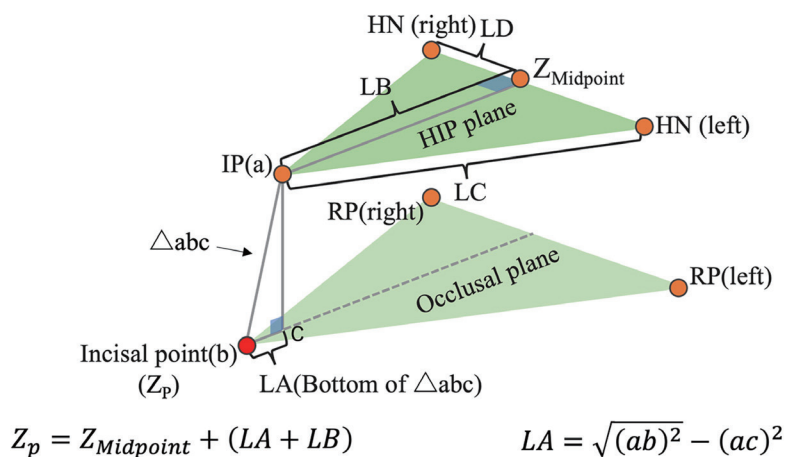


Fig. 6. How to obtain z-coordinates of incisor point.

70 to predict the z-coordinate by multiple regression analysis. Subsequently, to perform cross-validation as a verification of the accuracy of the z-coordinates predicted by multiple regression analysis, we decided to use a 7:3 ratio between the sample size required for the regression equation and that required for accuracy verification, referring to previous literature,¹¹ and set the sample size required for the accuracy verification to 30. Therefore, the total sample size was 100, which was set as the sample size in this study.

RESULTS

The results of each analysis for verifying the accuracy of X_p , Y_p , and Z_p are shown in Table 1 and Table 2 for the multiple regression analysis of Z_p . For the prediction of X_p , the RMSE was 2.22. For the prediction of Y_p , the RMSE of the method using the HIP plane was 3.18. In contrast, the RMSE of the method using facial measurements was 0.73.

For the prediction of Z_p , the multiple regression analysis detected the length of LC ($P < .01$) as a significant independent variable for the dependent variable. The multiple regression analysis resulted in the following regression equation.

$$(LA + LB) = 1.03LC - 0.23LD + 6.68$$

Therefore, the equation of Z_p is below.

$$Z_p = Z_{\text{Midpoint}} + (LA + LB) = Z_{\text{Midpoint}} + 1.03LC - 0.23LD + 6.68$$

The R^2 value of the regression equation was 0.84. Cross-validation demonstrated an RMSE value of 1.53.

DISCUSSION

This is the first study to investigate the calculation of the coordinates of the incisal point from the coordinates of each landmark of the jaw so that the occlusal plane can be automatically obtained only from the information of the maxillary and mandibular edentulous jaw data.

In the results of this experiment for predicting the accuracy of the incisal point (X_p , Y_p , Z_p) and predicting the occlusal plane of digital complete dentures, the RMSE for predicting X_p was 2.22. As the left-right position of the incisor point is related to the midline of the denture, the deviation between the measured and predicted coordinates of the left-right position of the incisor point is considered to be the deviation between the midline of the face and the midline of the

Table 1. Accuracy verification of X_p , Y_p and Z_p

Coordinate of the incisor point	Predicted value [†] (mm)	RMSE (mm)
X_p	1.74	2.22
Y_p	Method using HIP plane	3.18
	Method using facial measurement	0.73
Z_p	1.24	1.53

X_p , x-coordinate of the incisor point; Y_p , y-coordinate of the incisor point; Z_p , z-coordinate of the incisor point; RMSE, root mean squared error; HIP plane, hamular-incisive-papilla plane.

[†] Data are presented as the mean.

Table 2. Stepwise multiple regression analysis for Z_p

Dependent variable	Independent variables	Partial regression coefficient	Standard regression coefficient	P value
LA + LB	LC	1.03	0.95	< .01
	LD	-0.23	-0.11	.05
	Literal constant	6.68		.04

$R^2 = 0.84$, adjusted $R^2 = 0.83$

Z_p , z-coordinate of the incisor point; LA, Line segment A; LB, Line segment B; LC, Line segment C; LD, Line segment D.

denture. Therefore, based on the results of this study, if the right and left positions of the incisal points are set with reference to the midline of the palate, a deviation of ≥ 2 mm from the midline of the face may occur. Seki *et al.*¹² reported a deviation of ≤ 1.0 mm between the midline of the face and the denture to be clinically acceptable, suggesting that the arranged tooth position based on the left-right position of the incisor points with reference to the midline of the palate is likely to require correction because the deviation is out of the acceptable range. Jayalakshmi *et al.*¹³ investigated the degree of misalignment between the midline of the face and the midline of the anterior teeth in dentulous individuals and found that approximately half of the male and female individuals had a misalignment of 0 - 1 mm, and the other half had a misalignment of 1 - 3 mm. Therefore, there is a 50% chance that the midlines of the face and palate are already misaligned when the teeth remain, suggesting a tendency for the midline of the face and incisor points with reference to the midline of the palate to be misaligned. The above results suggest that the left-right positional coordinates of the incisor points require those of the midline of the face as additional information because the accuracy of the incisor point positional coordinates is low based on the data of the edentulous jaw alone.

To predict Y_p , two methods were used in this study: one using the HIP plane and the other using facial measurements; the RMSE results suggest that the method using facial measurements is more accurate than that using the HIP planes. Although several studies have reported that the HIP plane is parallel to the occlusal plane, the RMSE results for the prediction of the vertical coordinates of the incisor points revealed a discrepancy of 3 mm between the measured and predicted values. Khan and Abbas¹⁴ reported the amount of maxillary central incisors (2.93 ± 1.57 mm), lateral incisors (1.87 ± 1.12 mm), and canines (0.59 ± 0.62 mm) exposed in edentulous women aged 20 - 65 years. Based on these results, the deviation in the amount of exposure of the anterior teeth reported by Khan *et al.* ranged from 0.62 - 1.57 mm; on the other hand, the RMSE of Y_p calculated using the HIP plane in the present study was 3 mm, which was considered to be beyond the deviation range for the

amount of exposure of anterior teeth and might be beyond the clinically acceptable range. The reason for this discrepancy is presumably attributed to a large number of cases in which the parallelism between the occlusal plane and the HIP plane was lost due to the progression of jaw resorption in the maxillary anterior teeth in this study. Most studies that reported parallelism between the occlusal and HIP planes were conducted in dentulous individuals⁸ or edentulous individuals with well-volumed ridges.⁹ Jayachandran *et al.*¹⁵ reported that the IP remains in a fixed position after tooth loss, but the HN may disappear because of increased jaw resorption. The number of cases of significant jaw resorption has recently increased owing to the aging of edentulous patients.¹⁶ In contrast, as a method using facial measurements, the position of the lower border of the upper lip was used in this study, with reference to a previous review on the esthetic properties of dentures,¹⁷ in which Busch and Kordass⁵ used the position of the lower border of the upper lip. Therefore, the accuracy of the Y_p can be improved by using the vertical position coordinates of the lower border of the upper lip as additional information.

For the prediction of Z_p , a regression equation was obtained to predict the ZP in this study. The incisor point is approximately 12 mm anterior to the IP¹⁸; however, artificial teeth tend to be arranged posteriorly.¹⁹ Since Z_p has a great influence on lip support, determining Z_p only by the position of the IP is challenging owing to the involvement of many factors, such as patient preference and occlusal height. In the results of the multiple regression analysis, the significant independent variable was the distance between the IP and HN with the dependent variables, the sum of the distance between the incisal point and the IP, and the distance between the IP and midpoint of the HN. The R^2 value of the regression equation obtained from the multiple regression analysis was 0.8, suggesting a strong correlation between the measured and predicted values, and highly accurate predictions could be made. The RMSE value of the cross-validation was 1.53, which indicates that the deviation of the anteroposterior positional coordinates of the incisor points is within 1 - 2 mm and that fine adjustment is necessary in clinical practice; however, no major

modification is required.

The following points may be considered as limitations of this study: first, the coordinates of the landmarks, including the incisor points, were obtained from the data of the denture; therefore, a discrepancy could exist with respect to the coordinates on the jaw due to lack of accuracy of the denture impression surface. However, the dentures used in this study had been thoroughly verified to have no problems with fit, retention, or stability; therefore, discrepancies from the coordinates on the jaw were not considered to be a problem. Second, the selection criteria for the participants in this study were only “those who had complete denture fabrication and adjustment at our university,” and there were no particular selection criteria based on the degree of resorption of the jaw. For example, McGarry *et al.*²⁰ classified the degree of jaw resorption in edentulous patients; however, the percentage of patients with each degree of jaw resorption was not examined in this study. Likely, a bias in the number of individuals at the jaw resorption level may affect the RMSE. However, the present study suggests that predicting the coordinates of the incisor points is possible. Third, the hamular notches were assumed to be symmetrical in this study; however, this might not be true in some cases. Finally, although the number of cases collected in this study was 100, increasing the accuracy of the prediction of the positional coordinates of the incisor points by using a larger number of cases by equalizing the number of individuals with each level of jaw resorption would be necessary in future studies.

The determination of incisal points from anatomical landmarks has not been discussed previously. However, this study suggests that the incisal point could be identified from anatomical landmarks, and it is expected to be feasible to predict the coordinates of the incisal point and automatically determine the occlusal plane from the anatomical landmark, which might lead to automatic tooth arrangement. The realization of these denture fabrication processes might enable complete automation of digital complete denture fabrication, which could standardize denture quality and provide high-quality dentures to patients, independent of clinical experience.

CONCLUSION

Under the limited conditions of this study, it was suggested that Z_p could be predicted with high accuracy from the anatomical landmarks of the edentulous maxilla and mandible. We also found that Y_p could be predicted more accurately from the anatomical landmarks of the maxilla and mandible with the addition of the position of the lower border of the upper lip.

REFERENCES

1. Kanazawa M, Inokoshi M, Minakuchi S, Ohbayashi N. Trial of a CAD/CAM system for fabricating complete dentures. *Dent Mater J* 2011;30:93-6.
2. Iwaki M, Kanazawa M, Arakida T, Minakuchi S. Mechanical properties of a polymethyl methacrylate block for CAD/CAM dentures. *J Oral Sci* 2020;62:420-2.
3. Soeda Y, Kanazawa M, Arakida T, Iwaki M, Minakuchi S. CAD-CAM milled complete dentures with custom disks and prefabricated artificial teeth: a dental technique. *J Prosthet Dent* 2022;127:55-8.
4. Kanazawa M, Iwaki M, Arakida T, Minakuchi S. Digital impression and jaw relation record for the fabrication of CAD/CAM custom tray. *J Prosthodont Res* 2018;62:509-13.
5. Busch M, Kordass B. Concept and development of a computerized positioning of prosthetic teeth for complete dentures. *Int J Comput Dent* 2006;9:113-20.
6. Dai N, Yu X, Fan Q, Yuan F, Liu L, Sun Y. Complete denture tooth arrangement technology driven by a reconfigurable rule. *PLoS One* 2018;13:e0198252.
7. Yu X, Cheng X, Dai N, Chen H, Yu C, Sun Y. Study on digital teeth selection and virtual teeth arrangement for complete denture. *Comput Methods Programs Biomed* 2018;155:53-60.
8. Fu PS, Hung CC, Hong JM, Wang JC. Three-dimensional analysis of the occlusal plane related to the hamular-incisive-papilla occlusal plane in young adults. *J Oral Rehabil* 2007;34:136-40.
9. Tambake D, Shetty S, Satish Babu CL, Fulari SG. Analysis of relative parallelism between hamular-incisive-papilla plane and campers plane in edentulous subjects: a comparative study. *J Indian Prosthodont Soc* 2014;14:132-6.
10. Sahoo S, Singh D, Raghav D, Singh G, Sarin A, Kumar P.

Systematic assessment of the various controversies, difficulties, and current trends in the reestablishment of lost occlusal planes in edentulous patients. *Ann Med Health Sci Res* 2014;4:313-9.

11. Kohavi R. A study of cross-validation and bootstrap for accuracy estimation and model selection. *Proceedings of the Fourteenth International Joint Conference on Artificial Intelligence* 1995;2:1137-43.
12. Seki T, Suzuki T, Hayakawa I. Influence of midline position and incisal inclination on esthetic evaluation of complete denture wearers. *Prosthodont Res Pract* 2006;5:150-6.
13. Jayalakshmi NS, Ravindra S, Nagaraj KR, Rupesh PL, Harshavardhan MP. Acceptable deviation between facial and dental midlines in dentate population. *J Indian Prosthodont Soc* 2013;13:473-7.
14. Khan F, Abbas M. The mean visible labial length of maxillary and mandibular anterior teeth at rest. *J Coll Physicians Surg Pak* 2014;24:931-4.
15. Jayachandran S, Ramachandran CR, Varghese R. Occlusal plane orientation: a statistical and clinical analysis in different clinical situations. *J Prosthodont* 2008;17:572-5.
16. Ivanhoe JR, Cibirka RM, Parr GR. Treating the modern complete denture patient: a review of the literature. *J Prosthet Dent* 2002;88:631-5.
17. Shetty S, Zargar NM, Shenoy K, Rekha V. Occlusal plane location in edentulous patients: a review. *J Indian Prosthodont Soc* 2013;13:142-8.
18. Grave AM, Becker PJ. Evaluation of the incisive papilla as a guide to anterior tooth position. *J Prosthet Dent* 1987;57:712-4.
19. Isa ZM, Abdulhadi LM. Relationship of maxillary incisors in complete dentures to the incisive papilla. *J Oral Sci* 2012;54:159-63.
20. McGarry TJ, Nimmo A, Skiba JF, Ahlstrom RH, Smith CR, Koumjian JH. Classification system for complete edentulism. *The American College of Prosthodontics. J Prosthodont* 1999;8:27-39.