

Ocular side effects of antirheumatic medications: a qualitative review

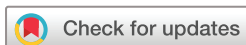Clara M Castillejo Becerra,¹ Yue Ding,² Beatrice Kenol,² Andrew Hendershot,³ Alexa Simon Meara ²

To cite: M Castillejo Becerra C, Ding Y, Kenol B, *et al*. Ocular side effects of antirheumatic medications: a qualitative review. *BMJ Open Ophthalmology* 2020;**5**:e000331. doi:10.1136/bmjophth-2019-000331

► Additional material is published online only. To view please visit the journal online (<http://dx.doi.org/10.1136/bmjophth-2019-000331>).

CMCB and YD contributed equally.

Received 9 May 2019
Revised 29 September 2019
Accepted 9 November 2019



© Author(s) (or their employer(s)) 2020. Re-use permitted under CC BY-NC. No commercial re-use. See rights and permissions. Published by BMJ.

¹College of Medicine, Ohio State University, Columbus, Ohio, USA

²Division of Rheumatology and Immunology, Ohio State University, Columbus, Ohio, USA

³Department of Ophthalmology, Ohio State University, Columbus, Ohio, USA

Correspondence to

Dr Alexa Simon Meara; [Alexa.meara@osumc.edu](mailto:meara@osumc.edu)

ABSTRACT

Topic This paper reviews the ocular side effects of medications used in the treatment of rheumatological conditions.

Clinical relevance Rheumatic diseases are inflammatory conditions that may affect the skin, blood vessels, joints, muscles and internal organs. Immunosuppressive agents are often used as treatment and while powerful, they carry side effects and toxicities that need careful monitoring. Ophthalmic complications have been reported with the use of antirheumatic medications; however, there is a lack of literature synthesising these reports. This paper addresses this gap and hopes to inform both rheumatologists and ophthalmologists as they work together on the management of patients with rheumatological conditions.

Methods PubMed literature search was conducted from November to September 2019 searching for ocular side effects with the use of 25 rheumatological drugs.

Results A total of 111 papers were included in this review. Adverse side effects were divided into non-infectious and infectious causes. Traditional disease-modifying antirheumatic drugs (DMARDs) were associated with pruritus, irritation and dryness of the conjunctiva while biologic DMARDs showed reports of new-onset/recurrent uveitis and demyelinating conditions. Infectious side effects included episodes of cytomegalovirus retinitis, toxoplasmic chorioretinitis and endophthalmitis. Other serious side effects were encountered and included in this review.

Conclusion The goal of this paper is to inform healthcare providers about potential ocular side effects from rheumatological medications. Healthcare providers are encouraged to learn more about these ophthalmic complications and find relevance within their clinical practice.

INTRODUCTION

Rheumatic diseases are inflammatory conditions that may affect the skin, blood vessels, joints, muscles and internal organs. Standard of care focuses on targeting this overactive inflammatory response with the use of disease-modifying antirheumatic drugs (DMARDs). For those patients with inadequate response, the newer biologic agents have proven to be effective therapeutic options. While these therapies have revolutionised the treatment of rheumatic diseases, they are not free of toxicity. Many ophthalmic complications have

been reported with the use of traditional and biologic DMARDs.

Hydroxychloroquine is one of the most well-known rheumatological drugs used in the treatment of systemic lupus erythematosus. Due to the risk of irreversible retinopathy, the American Academy of Ophthalmology recommends a baseline fundus examination and annual screening after 5 years.¹ Another commonly used class of drugs are the corticosteroids which are associated with the development of early cataracts and glaucoma.² They also lead to impaired glucose control, which by itself is a major risk factor for diabetic eye disease. In the case of non-selective non-steroidal anti-inflammatory drugs (NSAIDs), ocular manifestations are clinically rare but may include corneal crystal deposition and the development of corneal oedema.³ For cyclooxygenase-2 (COX-2) inhibitors, conjunctivitis and blurred vision are two main adverse effects.⁴ Because antirheumatic medications can lead to a wide range of ocular toxicities, it is important for rheumatologists and ophthalmologists to work together in order to recognise these side effects and treat them early. In this paper, we review the ocular side effects of medications used in the treatment of common rheumatological conditions.

METHODS

Search strategy

Literature search was performed using PubMed, selecting for case reports, case series, reviews articles, retrospective/prospective studies and clinical trials available as of September 2019. The following search strategy was used for each of the antirheumatic agents: (generic drug name OR trade drug name) AND (adverse effects OR side effects OR adverse) AND (eye diseases OR eye OR ocular OR ophthalmic). A total of 25 antirheumatic agents were included in this review, with their names and class summarised in [table 1](#). In addition, we reviewed the cases reported on the National Registry of

Table 1

Antirheumatic medications

Class	Generic name	Trade name
<i>Traditional DMARDs</i>		
Antimetabolites	Azathioprine	Azasan, Imuran
	Methotrexate	Rheumatrex, Trexall, Otrexup, Rasuvo
	Mycophenolate mofetil	CellCept
	Leflunomide	Arava
T-cell/calcineurin inhibitor	Ciclosporin	Neoral, Gengraf, Sandimmune
Alkylating agent	Cyclophosphamide	
Aminosalicylate	Sulfasalazine	Azulfidine, Sulfazine
PDE4 inhibitor	Apremilast	Otezla
Janus kinase inhibitors	Baricitinib	Olumiant
	Tofacitinib	Xeljanz
<i>Biologic DMARDs</i>		
TNF inhibitor—monoclonal antibody	Infliximab	Remicade
	Adalimumab	Humira
	Golimumab	Simponi
	Certolizumab pegol	Cimzia
TNF inhibitor—soluble TNF receptor fusion protein	Etanercept	Enbrel
IL-1 antagonist	Anakinra	Kineret
	Canakinumab	Ilaris
IL-6 antagonist	Sarilumab	Kevzara
	Tocilizumab	Actemra
IL-12, IL-23 inhibitor	Ustekinumab	Stelara
IL-17 inhibitor	Secukinumab	Cosentyx
	Ixekizumab	Taltz
Antilymphocytic agents	Rituximab	Rituxan
	Abatacept	Orencia
<i>Interferons</i>		
Interferon type 1	Interferon alpha	

DMARD, disease-modifying antirheumatic drug; TNF, tumour necrosis factor.

Ocular Side effects and those recommended by outside reviewers. Duplicates were removed from the study.

Study selection

Titles and abstracts were screened for relevance and full-text manuscripts were obtained. If electronic copies were unavailable, efforts were made to request full-length manuscripts through the Health Sciences Library at The Ohio State University. From search results, articles that involve the antirheumatic medication of interest and discussion regarding ocular side effects in humans were identified. Studies were excluded from this review for several reasons: (1) unavailability of full-length articles; (2) multiple-drug treatments confounding effect of an individual drug; (3) unclear or vague ocular side effects; (4) lack of convincing evidence for cause and effect. The process of identification, screening, selection and

exclusion criteria used in this review are summarised in figure 1.

Assessment of methodological quality

The quality for each case report and case series was assessed using the tool proposed by Murad *et al*,⁵ limited to questions 2–6. The following questions suggest whether the methodological quality is low or high based on a binary response (yes or no): (1) Was the exposure adequately ascertained? (2) Was the outcome adequately ascertained? (3) Were other alternative causes that may explain the observation ruled out? (4) Was there a challenge/rechallenge phenomenon? (5) Was there a dose–response effect? The quality assessment scores and characteristics for each study are summarised in online supplementary table S1.

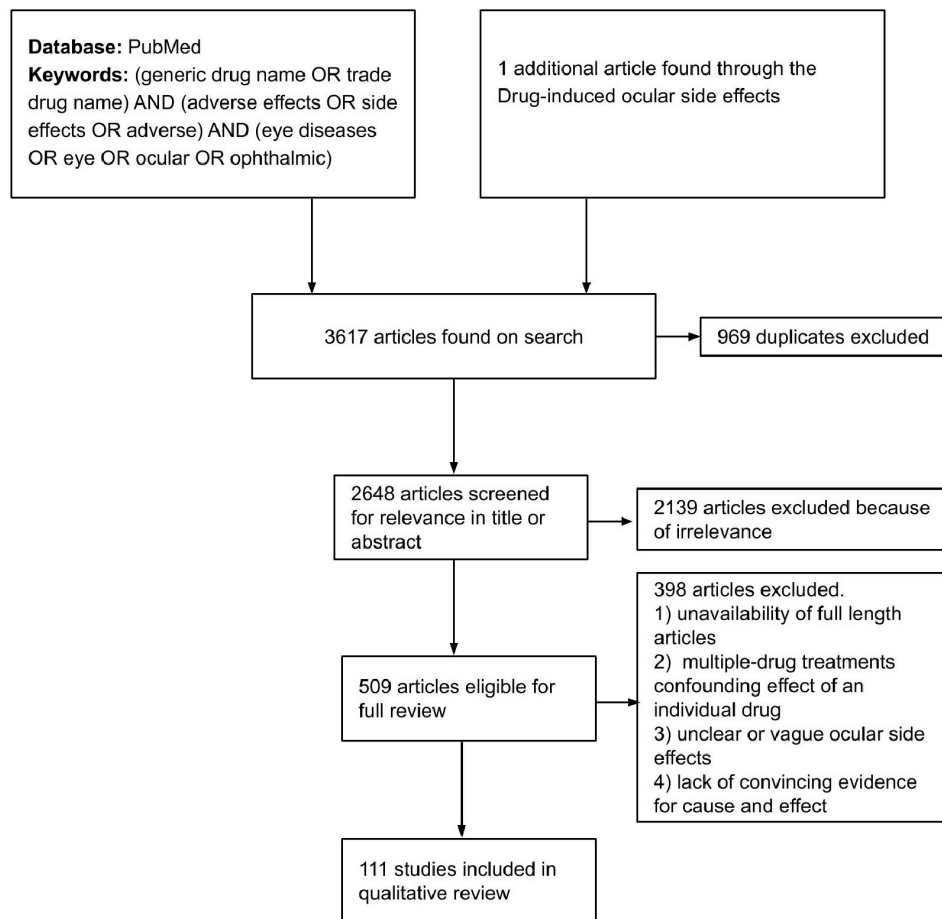


Figure 1 Flow diagram of study selection process.

Data synthesis

A total of 111 studies were included in this paper with a summary of the non-infectious and infectious side effects for each antirheumatic agents reported on [table 2](#). No attempts were made for statistical analysis. We excluded hydroxychloroquine, corticosteroids and NSAIDs from the current review as their ocular side effects are well established in the literature.

RESULTS

Traditional DMARDs

DMARDs are commonly used as part of the initial medications for rheumatic diseases. Some of the medications in this group include azathioprine, methotrexate, mycophenolate mofetil, leflunomide, ciclosporin and cyclophosphamide.

Azathioprine

Azathioprine is the 5-imidazolyl derivative of 6-mercaptopurine. It is an analogue of purine, which acts purine metabolism and nucleic acid synthesis to inhibit. Azathioprine is used in both antineoplastic and immunosuppressive processes due to its cytotoxic effects, known reduction of antibody production, decrease in B-cell production and decrease in T-cell-mediated responses.⁶ Like other immunosuppressants, azathioprine can lower immune response and there have been reports of

cytomegalovirus (CMV) retinitis and toxoplasmosis reactivation associated with the treatment of inflammatory bowel disease.^{7,8}

Methotrexate

Methotrexate competitively inhibits dihydrofolate reductase, disrupting the synthesis of purine and thymidylic acid. The result is reduced cellular proliferation, especially on highly proliferative cells and tissues. In a group of 13 patients receiving intermittent high-dose methotrexate (30–250 mg/kg), there were reported symptoms of generalised pruritus, burning, irritation and blurred vision.⁹ Generalised eye symptoms such as conjunctivitis, dry eyes and blepharitis were also noted in patients who received methotrexate as part of their chemotherapy regimen for postmolar gestational trophoblastic neoplasia.¹⁰ There is also a case report of internuclear ophthalmoplegia in a 26-year-old man after receiving intrathecal methotrexate for lymphoma.¹¹ Four case reports in 1992, 2002, 2005 and 2006 described optic disc swelling and visual field defects suspected to be optic neuropathy from methotrexate use.^{12–15} There is one case report of intraocular lymphoma after 9 months of treatment for temporal arteritis with prednisone and methotrexate,¹⁶ and another case of presumed methotrexate-induced mucosa-associated lymphoid tissue (MALT) lymphoma in 78-year-old female patient

Table 2

Ocular side effects of antirheumatic medications

Drug	Non-infectious side effects	Infectious side effects	References
Azathioprine	Retardation in corneal wound healing in albino rabbits	CMV retinitis, ocular toxoplasmosis reactivation	6–8
Methotrexate	Pruritus, burning, irritation, blurred vision, conjunctivitis, dry eyes, blepharitis, internuclear ophthalmoplegia, optic disc swelling, visual field defects, intraocular lymphoma, retinal cotton wool spots, corneal epitheliopathy	None reported	9–21
Mycophenolate mofetil	None in vivo; toxicity to retinal pigment epithelium in vitro	None reported	23
Leflunomide	Cystoid macular oedema	None reported	25
Ciclosporin	Potentiate steroid-induced cataracts	CMV anterior uveitis	27–31
Cyclophosphamide	Blurred vision, conjunctivitis, tearing, pruritus, burning of the eyes, soreness, grittiness, dryness, increased lacrimation, bilateral punctal stenosis	None reported	33–35
Sulfasalazine	Transient myopia	None reported	38
Apremilast	None reported	None reported	–
Baricitinib	None reported	None reported	–
Tofacitinib	None reported	None reported	–
TNF inhibitors	Paradoxical reactions (uveitis, sarcoid uveitis, sarcoid-like granulomatosis and scleritis) Demyelinating conditions (GBS, MFS, MS-like syndromes, optic neuritis, internuclear ophthalmoplegia, homonymous hemianopia, nystagmus, diplopia, visual field defects and scotomas)		39–58
Adalimumab	Diffuse retinopathy, central retinal vein occlusion, peripheral corneal infiltrates, acute retinal necrosis	Necrotising group A streptococcal periorbital infection, orbital abscess	59–64
Certolizumab	Shares side effects from TNF inhibitors class. No other reports found.	None reported	–
Etanercept	Acute ocular myositis, angioedema of the periorbital region, primary Intraocular lymphoma	Postoperative eyelid infection, TB uveitis, HHV6 uveitis, bilateral candida chorioretinitis, toxoplasmic chorioretinitis	65–73
Golimumab	Merkel cell carcinoma of the eyelid	None reported	74
Infliximab	Retinal vein thrombosis, rosacea keratitis	Endogenous endophthalmitis, endophthalmitis associated with <i>Purpureocillium lilacinum</i> , orbital cellulitis, CMV retinitis, toxoplasmic chorioretinitis	75–84
Anakinra	Nystagmus	None reported	85
Canakinumab	None reported	None reported	–
Sarilumab	Worsening uveitis and retinal infiltrates	None reported	86
Tocilizumab	Fulminant bilateral papilloedema	HTLV-1 uveitis, viral conjunctivitis, ophthalmic herpes zoster infection	87–90
Ustekinumab	None reported	Ophthalmic herpes	91
Secukinumab	None reported	Endogenous endophthalmitis	93
Ixekizumab	None reported	None reported	–
Rituximab	Retinal necrosis, conjunctivitis, macular oedema, transient IOP elevations and iridocyclitis with mutton-fat keratic precipitates	CMV retinitis	95–100
Abatacept	None reported	Infectious cornea ulcer	102
Interferon alpha	Ocular retinopathy, non-arteritic anterior ischaemic optic neuropathy, neuromyelitis optica, optic neuritis, cystoid macular oedema, Vogt–Koyanagi–Harada disease, abducens palsy, oculomotor nerve palsy, glaucoma, retinal vein thrombosis	None reported	105–129

CMV, cytomegalovirus; GBS, Guillain-Barre Syndrome; HHV6, human herpesvirus 6; HTLV-1, human T-cell leukaemia-lymphoma virus 1; IOP, intraocular pressure; MFS, Miller Fisher Syndrome; MS, Multiple Sclerosis; TB, tuberculosis; TNF, tumour necrosis factor.

with rheumatoid arthritis treated with methotrexate for >8 years.¹⁷ However, a large observational study following 19 591 patients over 89 710 person-years found no significant increased risk of lymphoma with methotrexate among patients with rheumatoid arthritis.¹⁸ There are case reports of retinal cotton wool spots after either intravitreal or systemic methotrexate.^{19 20} Case reports of corneal epitheliopathy were also noted after intravitreal injection of methotrexate for intraocular lymphoma.²¹

Mycophenolate mofetil

Mycophenolate mofetil inhibits inosine monophosphate dehydrogenase, preventing synthesis of purine nucleotides and reducing the production of lymphocytes.²² Originally used in the management of transplant patients, it is now used for the treatment of various autoimmune conditions such as uveitis. Search over PubMed did not yield reports of ocular side effects. Of interest, *in vitro* experiments showed decrease cell viability in human retinal pigment epithelium.²³

Leflunomide

Once absorbed in the body, leflunomide is converted to teriflunomide. It can then inhibit the enzyme dihydroorotate dehydrogenase and block the synthesis of ribonucleotide uridine monophosphate pyrimidine required for the synthesis of DNA and RNA.²⁴ A case report from 2004 shows a patient treated with leflunomide who developed bilateral cystoid macular oedema after 2 weeks of initiation of the drug. According to the report, the macular oedema symptoms resolved after cessation of leflunomide.²⁵

Ciclosporin

Ciclosporin is an inhibitor of T-cell-mediated responses.²⁶ It is a binder of cytoplasmic proteins called cyclophilins, with the subsequent complex that inhibits calcineurin. This process decreases activation of cytokines. There is a report of CMV anterior uveitis after topical ciclosporin A 0.05% ophthalmic emulsion.²⁷ Interestingly, the patient was not being infected with HIV and had been on ciclosporin eye emulsion for dry eyes. A study of 51 subjects was conducted comparing ocular side effects of different combinations of immunosuppressive regimen after renal transplant: steroids plus ciclosporin, steroids plus azathioprine, or steroids plus azathioprine plus ciclosporin. There was no statistically significant difference in macular hyperpigmentation or cataracts among these groups.²⁸ However, another study in 2003 of 140 subjects suggested that ciclosporin may potentiate steroid-induced cataracts. In this study, subjects were divided into two groups: one group received azathioprine plus steroids, another group received azathioprine plus steroids and ciclosporin. Despite the decrease in total dose of steroids with the addition of ciclosporin, more subjects in the ciclosporin group showed higher level of steroid-induced cataracts.²⁹

Ciclosporin A treatment in Behcet's disease was also shown to be associated with more central nervous system

(CNS) manifestations including internuclear ophthalmoplegia and diplopia. In a retrospective chart review of 117 patients with Behcet's disease, 6 of 21 patients were identified with new onset of neurological disease while being treated with ciclosporin A for maintenance therapy, while none of the patients on other medications showed new CNS manifestations. With ciclosporin level above therapeutic range, there are reports of ciclosporin-associated encephalopathies. In all six patients, ciclosporin A level was within therapeutic range.³⁰ A case report from 2001 also mentioned diplopia and eye abduction weakness bilaterally in a patient who received ciclosporin after allogeneic bone marrow transplantation. MRI demonstrated white-matter abnormalities. The symptoms ceased 2 days after stopping ciclosporin.³¹

Cyclophosphamide

Cyclophosphamide is an immunosuppressive agent known for its high potency and use in organ-threatening autoimmune manifestations such as vasculitis and lupus nephritis. It is an alkylating agent that interferes with DNA replication, thus inducing cellular apoptosis. Cyclophosphamide activation takes place in the liver, and it can be administered either parenterally or orally.³² On review, there are reports of blurred vision with its use on patients with cancer, lasting from less than an hour to 14 days.³³ The combination of cyclophosphamide, methotrexate and 5-fluorouracil (CMF) was commonly used in breast cancer treatment. In these patients, CMF therapy has been associated with conjunctivitis with symptoms such as tearing and pruritus in up to 42% of patients.³⁴ In another study regarding ocular symptoms associated with CMF therapy from 2001, patients experienced soreness, grittiness, dryness and increased lacrimation. One patient developed bilateral punctal stenosis after second round of CMF.³⁵

Sulfasalazine

In the colon, bacteria break down sulfasalazine into sulfapyridine and 5-aminosalicylic acid. Its mechanism of action has not been fully elucidated, but several theories, such as inhibition of nuclear factor-kappa B or tumour necrosis factor-alpha (TNF- α), are proposed.^{36 37} We found one case of transient myopia in 2003 following the addition of sulfasalazine for the treatment of rheumatoid arthritis. Following initiation of sulfasalazine 2 g daily for 3 weeks, visual acuity decreased from -3.0 to -4.0 DS to -1.0 DS. The medication was subsequently stopped with improved myopia and stable vision on examination.³⁸

Other small-molecule DMARDs

Newer immunosuppressive medications were also reviewed. Apremilast (brand name Otezla) is a phosphodiesterase-4 inhibitor used in treatment of psoriatic arthritis. Baricitinib (brand name Olumiant) and tofacitinib (Xeljanz) are Janus kinase (Jak) enzyme inhibitors. As of this article's publication, these drugs did not have reports of ocular toxicity.

Biologic DMARDs

Biologic drugs are the newer class of antirheumatic medications. Unlike traditional DMARDs, these target specific components of the immune response. Current agents include the TNF inhibitors (adalimumab, certolizumab, etanercept, golimumab and infliximab), anakinra, canakinumab, sarilumab, tocilizumab, ustekinumab, secukinumab, ixekizumab, rituximab and abatacept.

TNF inhibitors

TNF- α is a cytokine critical for the initiation and propagation of the immune response. TNF inhibitors block this important molecule and are used in the treatment of rheumatoid arthritis, psoriatic arthritis, juvenile arthritis, inflammatory bowel disease, ankylosing spondylitis and psoriasis. Although effective, caution is warranted as they make patients more susceptible to infection, malignancy and a wide range of systemic side effects. In the case of ocular side effects, uveitis is among the most commonly reported adverse events. This is known as the paradoxical reaction of anti-TNF agents, where we find the appearance or exacerbation of a condition that can normally be treated with this therapy.³⁹ TNF inhibitors have shown to be effective at reducing the frequency of uveitis flares in patients with Behcet disease, juvenile idiopathic arthritis (JIA), spondyloarthropathies, inflammatory bowel disease and sarcoidosis.⁴⁰ On the other hand, a number of case reports associate new-onset uveitis with the initiation of anti-TNF therapy, with etanercept as the main culprit. In terms of molecular structure, etanercept is a soluble TNF receptor fusion protein, while others such as infliximab, adalimumab, golimumab and certolizumab are known to be monoclonal antibodies. To shine light at these effects, Wendling *et al* conducted a population-based cohort study and identified 31 cases of new-onset uveitis in patients treated with TNF inhibitors for ankylosing spondylitis (19 cases), psoriatic arthritis (4 cases), rheumatoid arthritis (6 cases) and juvenile idiopathic arthritis (2 cases).⁴¹ Most of these occurred with the use of etanercept (23/31 cases). The authors also conducted a literature analysis and identified 121 additional cases of new-onset uveitis; etanercept was found to be implicated on 84.3% of these cases. Other paradoxical reactions of TNF inhibitors include sarcoid uveitis, sarcoid-like granulomatosis and scleritis.^{42–48}

This class of antirheumatic medications has also been attributed to the development of central and peripheral demyelination diseases such as Guillain-Barre, Miller-Fisher and other syndromes resembling multiple sclerosis.^{49,50} Ratnarajan *et al* describe a case of a 43-year-old woman who started infliximab therapy 9 weeks prior and presented with 3 days of worsening diplopia.⁵¹ On presentation, she was found to have mild ophthalmoparesis, pupillary unresponsiveness, lid twitches, lid hops and very high anti-GQ1b antibody titres. Intravenous immunoglobulin and plasmapheresis were avoided. Instead, her diplopia was managed with occlusion, with all symptoms resolving within 10 weeks.

Optic neuritis is another demyelinating disorder that is widely attributed to TNF inhibitors.⁵² In 2013, the results of the SABER study were released.⁵³ This was a large multi-institutional research initiative which showed optic neuritis to be rare among those who initiated anti-TNF therapy, approximately 5–10 per 100 000 patient-years, and occurring with similar frequency among those receiving non-biologic DMARD therapy. These findings opposed the large number of optic neuritis cases found in the literature and are important to consider as one makes conclusions about the adverse effects of TNF inhibitors. Other neurological side effects of TNF inhibition include internuclear ophthalmoplegia, homonymous hemianopia, nystagmus, diplopia, visual field defects and scotomas.^{54–58} We will now focus on the ocular adverse effects of the individual TNF inhibitors.

Adalimumab

A case of diffuse bilateral retinopathy was found in a woman treated with adalimumab for Crohn's disease.⁵⁹ Treatment was discontinued, but visual field loss persisted 6 months later. Hsu *et al* report a case of central retinal vein occlusion after the fifth dose of adalimumab for refractory psoriasis.⁶⁰ Although adalimumab was discontinued, the patient developed neovascular glaucoma resulting in vision loss. Another patient treated for Crohn's disease with a bimonthly dose of adalimumab developed bilateral peripheral corneal infiltrates 36 hours after injection.⁶¹ These were treated with topical corticosteroids but recurred after each treatment over the following weeks. Schechet *et al* describe a case of acute retinal necrosis in a patient treated for psoriasis.⁶² He underwent intravenous acyclovir and prophylactic laser barricade therapy; 7 years later, he was 20/20 without history of retinal detachment.

In terms of infectious side effects, a woman developed severe necrotising periorbital infection while receiving treatment with adalimumab.⁶³ She made a complete recovery after antibiotic therapy. There is also a report of an 11-year-old girl treated for chronic recurrent multifocal osteomyelitis with adalimumab who then developed acute sinusitis complicated by an orbital abscess and subdural empyema.⁶⁴ She underwent rhinosurgery and neurosurgery with intravenous antibiotics and had no long-term neurological sequelae.

Etanercept

Two separate case reports describe the use of etanercept and the development of orbital myositis.^{65,66} In one case, the patient developed ocular myositis a few months after initiation therapy, while in the other case, the patient developed symptoms a decade later. Both were treated with discontinuation of etanercept and high-dose steroid therapy. Another adverse effect of etanercept is the development of periorbital angioedema seen in the treatment of adult-onset Still's disease.⁶⁷ There is also a risk of primary intraocular lymphoma due to the immunosuppressive effects of etanercept as reported in a 50-year-old woman who was successfully treated with

serial intravitreal methotrexate injections and systemic chemotherapy.⁶⁸ For eyelid surgery, we found a case of postoperative eyelid infection in a patient taking etanercept.⁶⁹ Additional cases of tuberculosis, human herpesvirus 6, bilateral candida and toxoplasmic uveitis were identified which speak to the immunodeficient state in patients receiving etanercept therapy.^{70–73}

Golimumab

We found a case of eyelid Merkel cell carcinoma in a patient treated with golimumab for chronic rheumatoid arthritis.⁷⁴ The patient developed the tumour 6 months after initiation therapy and was treated with radical tumour excision, eyelid reconstruction, and radiation therapy of the eyelid and lymph nodes.

Infliximab

Multiple reports mentioned the development of retinal vein thrombosis with infliximab treatment in the setting of Crohn's disease, ulcerative colitis, plaque psoriasis and rheumatoid arthritis.^{75–78} Based on the temporal effects of infliximab therapy and thrombosis, the authors advocated for a causal relationship. Fasci-Spurio and Thompson described a case of severe bilateral rosacea-like keratopathy in a patient receiving infliximab therapy for rheumatoid arthritis.⁷⁹ The patient had a long-standing history of acne rosacea of the skin with ocular symptoms that began with infliximab therapy and improved with its withdrawal. Infectious side effects such as CMV retinitis, toxoplasmic chorioretinitis, orbital cellulitis and endogenous endophthalmitis have also been attributed to infliximab.^{73 80–83} In particular, Purpureocillium lilacinum endophthalmitis was diagnosed in a 71-year-old patient receiving infliximab for surgically induced necrotising scleritis. He was successfully treated with 27-gauge vitrectomy, and after 2 months of antibacterial and antifungal therapy, there was visual recovery.⁸⁴

Anakinra and canakinumab

The interleukin-1 receptor antagonist anakinra can be used for rheumatoid arthritis and neonatal-onset multisystem inflammatory disease (NOMID). A cohort study examined the 5-year outcomes of 26 patients with NOMID treated with anakinra 1–5 mg/kg/day for at least 36 months.⁸⁵ While visual acuity and peripheral vision remained stable, two patients on high-dose treatment developed nystagmus. Other manifestations included eye swelling, glaucoma and blurred vision with low-dose anakinra, and blepharospasm, eye pruritus and blurred vision with the high dose. Canakinumab targets interleukin-1 beta. Literature review did not yield case reports for the ocular side effects of canakinumab.

Sarilumab

Sarilumab works against the interleukin-6 receptor and can be used for moderate to severe rheumatoid arthritis. The phase II SATURN study investigated its efficacy and safety for the treatment of posterior segment non-infectious uveitis.⁸⁶ Subcutaneous administration

reduced vitreous haze on these patients with the most common adverse events being worsening uveitis and retinal infiltrates.

Tocilizumab

Tocilizumab is another interleukin-6 receptor inhibitor; it treats rheumatoid arthritis, giant cell arteritis and juvenile idiopathic arthritis. In a report by Roux *et al*, a patient developed ophthalmic herpes zoster virus infection with duplex bilateralis following 9 months of tocilizumab treatment.⁸⁷ Her infection combined the right ophthalmic region with vesicles on the tip, side and root of the nose, and the left C4 metamere with lesions on the anterior part of the shoulder. Symptoms improved with valacyclovir treatment and relapse again after each tocilizumab injection despite dose reduction. Tocilizumab was ultimately stopped. Another report by Terada *et al* showed recurrence of human T-cell leukaemia-lymphoma virus 1 (HTLV-1) uveitis and HTLV-1-associated myelopathy/tropical spastic paraparesis with tocilizumab administration. HTLV-1 symptoms improved with steroid-based therapy but worsened again with abatacept substitution.⁸⁸ The authors called for caution with the use of biologics in HTLV-1-infected individuals. A multicentre study on the use of tocilizumab for JIA-associated uveitis found one case of viral conjunctivitis and bullous impetigo that required temporary discontinuation of therapy.⁸⁹ Therapy was later restarted with no new adverse events. Burstzyn *et al* showed bilateral papilloedema in a child with steroid-dependent systemic JIA and tocilizumab treatment.⁹⁰ After urgent unilateral optic nerve sheath fenestration, vision was completely restored in one eye and partially recovered in the contralateral eye.

Ustekinumab

Ustekinumab blocks interleukin 12 and 23 to help patients with plaque psoriasis, psoriatic arthritis and severe Crohn's disease. Under the safety information for Stelera (ustekinumab), an episode of ophthalmic herpes was reported.⁹¹ No other adverse events were found on the literature.

Secukinumab

Secukinumab is a monoclonal antibody that binds to the protein interleukin 17A and is used to treat psoriatic arthritis, plaque arthritis and ankylosing spondylitis.⁹² In a report by Martinez *et al*, a diabetic patient developed osteomyelitis and unilateral endogenous endophthalmitis following secukinumab therapy.⁹³ Interleukin 17 inhibitor therapy was viewed as a predisposing factor for infection. On the other hand, no reports associate ixekizumab with ocular side effects.

Rituximab

Rituximab causes antibody-mediated B-cell depletion. It can be useful in rheumatoid arthritis, certain forms of vasculitis and haematological cancers.⁹⁴ In terms of side effects, a case of acute retinal necrosis was reported in a patient with scleroderma and rheumatoid arthritis

treated with rituximab.⁹⁵ A patient with microscopic polyangiitis also developed progressive outer retinal necrosis following rituximab and cyclophosphamide therapy.⁹⁶ Another reported side effect of rituximab is transient bilateral conjunctivitis, which was seen during infusion therapy for bronchial associated lymphoma.⁹⁷ Cystoid macular oedema was also reported in two patients with refractory granulomatosis with polyangiitis receiving rituximab.⁹⁸ In terms of infectious side effects, Chan *et al* found CMV retinitis to be more frequent in patients receiving concomitant rituximab and fludarabine-containing regimens than patients receiving fludarabine-containing regimens alone. Treatment in these patients require both intravitreal and systemic ganciclovir/foscarnet therapy progressing to secondary retinal atrophy in all patients and leading to blindness in 86% of affected eyes.⁹⁹ While most reported side effects have been the result of systemic treatment, intravitreal rituximab injections can lead to transient intraocular pressure (IOP) elevations and iridocyclitis with mutton-fat keratic precipitates as seen in the treatment of primary vitreoretinal lymphoma.¹⁰⁰

Abatacept

Abatacept works by binding to CD80/CD86 proteins on antigen-presenting cells and preventing T-cell activation. It is often prescribed after failure of first-line therapy in patients with moderate to severe rheumatoid arthritis.¹⁰¹ One study looked at its efficacy and safety profile in Sjogren's syndrome secondary to rheumatoid arthritis.¹⁰² Here, abatacept was associated with an infectious cornea ulcer that resolved with antibiotic eye drops.

Interferon alpha

Interferons are proteins released in response to viruses. Pegylated interferon has been used for treatment of hepatitis C infection. More recently, interferon alpha had been recommended for consideration in patients with Behcet's disease, especially those with sight-threatening or refractory uveitis.^{103 104} However, it is also known that interferon alpha can cause retinopathy, with possible optic nerve damage in severe cases.¹⁰⁵

Case reports of episcleritis are associated with interferon alpha-2b in the treatment of head and neck mucosal melanoma.¹⁰⁶ There are also reports of non-arteritic anterior ischaemic optic neuropathy, neuromyelitis optica, optic neuritis, retinopathy, cystoid macular oedema, Vogt-Koyanagi-Harada disease, abducens palsy, oculomotor nerve palsy, glaucoma and retinal vein thrombosis reported in patients treated with interferon alpha.¹⁰⁷⁻¹²⁹

DISCUSSION

While the surge of new antirheumatic agents has significantly improved patient outcomes, their widespread use raises safety concerns.^{130 131} All aforementioned drugs have immunosuppressive properties and carry the theoretical risk of ocular infections. At the same time, many of these drugs have non-infectious ocular side effects that are shared or unique among the class of medications.

Dosage is an important consideration which has not been fully elucidated due to the heterogeneity among different studies and lack of dose comparison within a given study. As an example of dose-related side effects, we have the cohort study of 26 patients with NOMID treated with low-dose (≤ 2.5 mg/kg/day) or high-dose anakinra (> 2.5 mg/kg/day).⁸⁵ While two patients in the high-dose group developed nystagmus compared with zero patients in the low-dose group, the small number of patients and affected individuals prevents generalised statements about dosage. Another consideration is the route of administration which was difficult to analyse as most of the rheumatological agents included in this review used only one route. It does appear that intravitreal and topical applications have more corneal specific side effects when compared with their systemic counterparts, as was seen with intravitreal methotrexate in cases of corneal epitheliopathy²¹ and intravitreal rituximab with mutton-fat keratic precipitates.¹⁰⁰

As conclusions are made based on this study, one must be aware of the following limitations. First, the literature search was conducted using PubMed, which can miss cases and studies not included in this search engine. Second, as a qualitative review, no conclusions can be made regarding the frequency or incidence of reported side effects. Third, most of the ocular toxicities came from case reports, which are considered the lowest level of evidence and lack direct proof of cause and effect. To address the last concern, efforts were made to evaluate the quality of each case report and case series using the framework proposed by Murad *et al*.⁵ Based on a set of five questions, most of the studies received a score of 3 or less which we deemed as low evidence. Only a handful of studies received a score of 4 or more because they included a challenge/rechallenge phenomenon or dose-response effect.

In summary, this study adds to the well-known ocular side effects of medications such as steroids, NSAIDs and hydroxychloroquine. It also calls for close collaboration between rheumatologists and ophthalmologists so that they can remain vigilant of medication-induced ocular side effects. Through early recognition and intervention, healthcare providers can address potentially serious and devastating effects to their patient's vision while reaping the benefits of anti-rheumatic medications.

Acknowledgements The authors thank The Health Sciences Library at The Ohio State University for technical assistance.

Contributors All authors contributed to the idea, writing and editing of the manuscript.

Funding The authors have not declared a specific grant for this research from any funding agency in the public, commercial or not-for-profit sectors.

Competing interests None declared.

Patient consent for publication Not required.

Provenance and peer review Not commissioned; externally peer reviewed.

Open access This is an open access article distributed in accordance with the Creative Commons Attribution Non Commercial (CC BY-NC 4.0) license, which permits others to distribute, remix, adapt, build upon this work non-commercially,

and license their derivative works on different terms, provided the original work is properly cited, appropriate credit is given, any changes made indicated, and the use is non-commercial. See: <http://creativecommons.org/licenses/by-nc/4.0/>.

ORCID ID

Alexa Simon Meara <http://orcid.org/0000-0002-8406-3556>

REFERENCES

- Marmor MF, Kellner U, Lai TYY, et al. Recommendations on screening for chloroquine and hydroxychloroquine retinopathy (2016 revision). *Ophthalmology* 2016;123:1386–94.
- Renfro L, Snow JS. Ocular effects of topical and systemic steroids. *Dermatol Clin* 1992;10:505–12.
- Hoppmann RA, Peden JG, Ober SK. Central nervous system side effects of nonsteroidal anti-inflammatory drugs. Aseptic meningitis, psychosis, and cognitive dysfunction. *Arch Intern Med* 1991;151:1309–13.
- Fraunfelder FW, Solomon J, Mehelas TJ. Ocular adverse effects associated with cyclooxygenase-2 inhibitors. *Arch Ophthalmol* 2006;124:277–9.
- Murad MH, Sultan S, Haffar S, et al. Methodological quality and synthesis of case series and case reports. *BMJ Evidence-Based Medicine* 2018;23:60–3.
- Ahmed AR, Moy R, Azathioprine MR. Azathioprine. *Int J Dermatol* 1981;20:461–7.
- Ammari W, Berriche O. Rétinite cytomegalovirus chez un patient atteint de rectocolite hémorragique sous azathioprine [CMV retinitis in a patient with ulcerative colitis taking azathioprine]. *Pan Afr Med J* 2015;21:227.
- Puga M, Carpio D, Sampil M, et al. Ocular toxoplasmosis reactivation in a patient with inflammatory bowel disease under treatment with azathioprine. *J Clin Gastroenterol* 2016;50:610.
- Doroshov JH, Locker GY, Gaasterland DE, et al. Ocular irritation from high-dose methotrexate therapy: pharmacokinetics of drug in the tear film. *Cancer* 1981;48:2158–62.
- Maestá I, Nitecki R, Horowitz NS, et al. Effectiveness and toxicity of first-line methotrexate chemotherapy in low-risk postmolar gestational trophoblastic neoplasia: The New England Trophoblastic Disease Center experience. *Gynecol Oncol* 2018;148:161–7.
- Lepore FE, Nissenblatt MJ. Bilateral internuclear ophthalmoplegia after intrathecal chemotherapy and cranial irradiation. *Am J Ophthalmol* 1981;92:851–3.
- Johansson BA. Visual field defects during low-dose methotrexate therapy. *Doc Ophthalmol* 1992;79:91–4.
- Sbeity ZH, Baydoun L, Schmidt S, et al. Visual field changes in methotrexate therapy. Case report and review of the literature. *J Med Liban* 2006;54:164–7.
- Balachandran C, McCluskey PJ, Champion GD, et al. Methotrexate-Induced optic neuropathy. *Clin Exp Ophthalmol* 2002;30:440–1.
- Clare G, Colley S, Kennett R, et al. Reversible optic neuropathy associated with low-dose methotrexate therapy. *J Neuroophthalmol* 2005;25:109–12.
- Rizkalla K, Rodrigues S, Proulx A, et al. Primary intraocular lymphoma arising during methotrexate treatment of temporal arteritis. *Can J Ophthalmol* 2005;40:585–92.
- Kobayashi Y, Kimura K, Fujitsu Y, et al. Methotrexate-associated orbital lymphoproliferative disorder in a patient with rheumatoid arthritis: a case report. *Jpn J Ophthalmol* 2016;60:212–8.
- Kempen JH, Gangaputra S, Daniel E, et al. Long-term risk of malignancy among patients treated with immunosuppressive agents for ocular inflammation: a critical assessment of the evidence. *Am J Ophthalmol* 2008;146:802–12.
- Kuroiwa N, Abematsu N, Matsuo Y, et al. [A case of intraocular lymphoma having retinal adverse events associated with intravitreal methotrexate]. *Nippon Ganka Gakkai Zasshi* 2011;115:611–6.
- Klemencic S. Cotton wool spots as an indicator of methotrexate-induced blood dyscrasia. *Optometry* 2010;81:177–80.
- Gorovoy I, Prechanond T, Abia M, et al. Toxic corneal epitheliopathy after intravitreal methotrexate and its treatment with oral folic acid. *Cornea* 2013;32:1171–3.
- Allison AC, Eugui EM. Mycophenolate mofetil and its mechanisms of action. *Immunopharmacology* 2000;47:85–118.
- Zacharias LC, Damico FM, Kenney MC, et al. In vitro evidence for mycophenolic acid dose-related cytotoxicity in human retinal cells. *Retina* 2013;33:2155–61.
- Breedveld FC, Dayer JM. Leflunomide: mode of action in the treatment of rheumatoid arthritis. *Ann Rheum Dis* 2000;59:841–9.
- Barak A, Morse LS, Leflunomide SI. Arava-induced cystoid macular oedema. *Rheumatology* 2004;43:246–8.
- Kahan BD. Cyclosporine. *N Engl J Med* 1989;321:1725–38.
- Siak J, Chee S-P. Cytomegalovirus anterior uveitis following topical cyclosporine A. *Ocul Immunol Inflamm* 2018;26:90–3.
- Apaydin C, Gur B, Yakupoglu G, et al. Ocular and visual side effects of systemic cyclosporine. *Ann Ophthalmol* 1992;24:465–9.
- Nakamura Tet al. Influence of cyclosporin on steroid-induced cataracts after renal transplantation. *Jpn J Ophthalmol* 2003;47:254–9.
- Kötter I, Günaydin I, Batra M, et al. CNS involvement occurs more frequently in patients with Behçet's disease under cyclosporin A (CsA) than under other medications—results of a retrospective analysis of 117 cases'. *Clin Rheumatol* 2006;25:482–6.
- Openshaw H. Eye movement abnormality associated with cyclosporin. *J Neurol Neurosurg Psychiatry* 2001;70:809.
- de Jonge ME, Huitema ADR, Rodenhuis S, et al. Clinical pharmacokinetics of cyclophosphamide. *Clin Pharmacokinet* 2005;44:1135–64.
- Kende G, Sirkin SR, Thomas PRM, et al. Blurring of vision. A previously undescribed complication of cyclophosphamide therapy. *Cancer* 1979;44:69–71.
- Loprinzi CL, Love RR, Garrity JA, et al. Cyclophosphamide, methotrexate, and 5-fluorouracil (CMF)-induced ocular toxicity. *Cancer Invest* 1990;8:459–65.
- Stevens A, Spooner D. Lacrimal duct stenosis and other ocular toxicity associated with adjuvant cyclophosphamide, methotrexate and 5-fluorouracil combination chemotherapy for early stage breast cancer. *Clin Oncol* 2001;13:438–40.
- Lee C-K, Lee EY, Chung SM, et al. Effects of disease-modifying antirheumatic drugs and antiinflammatory cytokines on human osteoclastogenesis through interaction with receptor activator of nuclear factor kappaB, osteoprotegerin, and receptor activator of nuclear factor kappaB ligand. *Arthritis Rheum* 2004;50:3831–43.
- Rodenburg RJ, Ganga A, van Lent PL, et al. The antiinflammatory drug sulfasalazine inhibits tumor necrosis factor alpha expression in macrophages by inducing apoptosis. *Arthritis Rheum* 2000;43:1941–50.
- Santodomingo-Rubido J, Gilmartin B, Wolffsohn JS. Drug-induced bilateral transient myopia with the sulphonamide sulphasalazine. *Opt Phys Optics* 2003;23:567–70.
- Toussiot Éric, Aubin F. Paradoxical reactions under TNF- α blocking agents and other biological agents given for chronic immune-mediated diseases: an analytical and comprehensive overview. *RMD Open* 2016;2:e000239.
- Cordero-Coma M, Sobrin L. Anti-tumor necrosis factor- α therapy in uveitis. *Surv Ophthalmol* 2015;60:575–89.
- Wendling D, Paccou J, Berthelot J-M, et al. New onset of uveitis during anti-tumor necrosis factor treatment for rheumatic diseases. *Semin Arthritis Rheum* 2011;41:503–10.
- Hashkes PJ, Shajrawi I. Sarcoid-related uveitis occurring during etanercept therapy. *Clin Exp Rheumatol* 2003;21:645–6.
- Suzuki J, Goto H. Uveitis associated with sarcoidosis exacerbated by etanercept therapy. *Jpn J Ophthalmol* 2009;53:439–40.
- Dragnev D, Barr D, Kulshrestha M, et al. Sarcoid panuveitis associated with etanercept treatment, resolving with adalimumab. *Case Reports* 2013;2013:bcr2013200552.
- Seve P, Varron L, Broussolle C, et al. Sarcoid-related uveitis occurring during adalimumab therapy. *Ocul Immunol Inflamm* 2012;20:59–60.
- Clementine RR, Lyman J, Zakem J, et al. Tumor necrosis factor-alpha antagonist-induced sarcoidosis. *J Clin Rheumatol* 2010;16:274–9.
- Wladis EJ, Tarasen AJ, Roth ZJ, et al. Orbital sarcoid-like granulomatosis after inhibition of tumor necrosis factor- α . *Ophthalmol Plast Reconstr Surg* 2016;32:e30–2.
- Gaujoux-Viala C, Giampietro C, Gaujoux T, et al. Scleritis: a paradoxical effect of etanercept? Etanercept-associated inflammatory eye disease. *J Rheumatol* 2012;39:233–9.
- Shin I-SJ, Baer AN, Kwon HJ, et al. Guillain-Barré and Miller Fisher syndromes occurring with tumor necrosis factor α antagonist therapy. *Arthritis Rheum* 2006;54:1429–34.
- Theibich A, Dreyer L, Magyari M, et al. Demyelinating neurological disease after treatment with tumor necrosis factor alpha-inhibiting agents in a rheumatological outpatient clinic: description of six cases. *Clin Rheumatol* 2014;33:719–23.
- Ratnarajan G, Thompson A, Dodridge C, et al. Novel variant of Miller Fisher syndrome occurring with tumor necrosis factor α antagonist therapy. *JAMA Neurol* 2015;72:1377–8.
- Simsek I, Erdem H, Pay S, et al. Optic neuritis occurring with anti-tumour necrosis factor therapy. *Ann Rheum Dis* 2007;66:1255–8.

- 53 Winthrop KL, Chen L, Fraunfelder FW, *et al.* Initiation of anti-TNF therapy and the risk of optic neuritis: from the safety assessment of biologic therapy (SABER) study. *Am J Ophthalmol* 2013;155:183–9.
- 54 Clifford LJ, Rossiter JD. Peripheral visual field loss following treatment with etanercept. *Br J Ophthalmol* 2004;88:842.
- 55 Rossman MD, Newman LS, Baughman RP, *et al.* A double-blinded, randomized, placebo-controlled trial of infliximab in subjects with active pulmonary sarcoidosis. *Sarcoidosis Vasc Diffuse Lung Dis* 2006;23:201–8.
- 56 HH D, Mohamed A, Klistorner A, *et al.* Ophthalmic manifestations of demyelination secondary to etanercept. *Clin Exp Ophthalmol* 2008;36:392–4.
- 57 Papadia M, Herbort CP. Infliximab-induced demyelination causes visual disturbance mistaken for recurrence of HLA-B27-related uveitis. *Ocul Immunol Inflamm* 2010;18:482–4.
- 58 Drury J, Hickman SJ. Internuclear ophthalmoplegia associated with anti-TNF α medication. *Strabismus* 2015;23:30–2.
- 59 Marticorena-Álvarez P, Chaparro M, Pérez-Casas A, *et al.* Probable diffuse retinopathy caused by adalimumab in a patient with Crohn's disease. *J Crohns Colitis* 2012;6:950–3.
- 60 Hsu C-K, Cheng C-Y, Hung J-H, *et al.* Central retinal vein occlusion and subsequent neovascular glaucoma after adalimumab treatment for psoriasis. *Clin Exp Dermatol* 2014;39:72–3.
- 61 Matet A, Daruich A, Beydoun T, *et al.* Systemic adalimumab induces peripheral corneal infiltrates: a case report. *BMC Ophthalmol* 2015;15:57.
- 62 Schechet SA, Garff K, Klima K, *et al.* Acute retinal necrosis after administration of adalimumab, a systemic antitumor necrosis factor antibody. *Retin Cases Brief Rep* 2018;12:307–9.
- 63 Roos JCP, René C, Ostor AJK. Necrotizing group A streptococcal periorbital infection following adalimumab therapy for rheumatoid arthritis. *Cutan Ocul Toxicol* 2011;30:160–2.
- 64 Kofoed MS, Fisker N, Christensen AE, *et al.* Sinogenic intracranial complications: is adalimumab a culprit? *Case Reports* 2018;2018:bcr-2017-221449.
- 65 Caramaschi P, Biasi D, Carletto A, *et al.* Orbital myositis in a rheumatoid arthritis patient during etanercept treatment. *Clin Exp Rheumatol* 2003;21:136–7.
- 66 Couderc M, Mathieu S, Tournadre A, *et al.* Acute ocular myositis occurring under etanercept for rheumatoid arthritis. *Joint Bone Spine* 2014;81:445–6.
- 67 Kato T, Noguchi K, Uehara M, *et al.* Angioedema of the periorbital region that developed during treatment with etanercept in a case of refractory adult-onset Still's disease. *Intern Med* 2012;51:2801–4.
- 68 Song WK, Cho AR, Yoon YH. Highly suspected primary intraocular lymphoma in a patient with rheumatoid arthritis treated with etanercept: a case report. *BMC Ophthalmol* 2018;18:156.
- 69 Yakopson VS, Flanagan JC. Postoperative eyelid infection in a patient taking etanercept. *Orbit* 2011;30:303–4.
- 70 Fonollosa A, Artaraz J, Les I, *et al.* Sarcoid intermediate uveitis following etanercept treatment: a case report and review of the literature. *Ocul Immunol Inflamm* 2012;20:44–8.
- 71 Glâtre F, Rousseau E, Bacin F. Uvérite unilatérale avec polymérase chain reaction positive pour HHV6 dans l'humeur aqueuse chez une patiente sous étanercept : propos d'un cas [Unilateral uveitis with HHV6-positive polymerase chain reaction in aqueous humor for an etanercept-treated woman: a case report]. *J Fr Ophtalmol* 2010;33:561–3.
- 72 Arriola-Villalobos P, Díaz-Valle D, Alejandre-Alba N, *et al.* Bilateral Candida chorioretinitis following etanercept treatment for hidradenitis suppurativa. *Eye* 2008;22:599–600.
- 73 Lassoued S, Zabraniecki L, Marin F, *et al.* Toxoplasmic chorioretinitis and antitumor necrosis factor treatment in rheumatoid arthritis. *Semin Arthritis Rheum* 2007;36:262–3.
- 74 Hanafi H, Verdijk RM, Paridaens D. Eyelid Merkel cell carcinoma in a patient treated with golimumab. *Orbit* 2018;37:21–5.
- 75 Puli SR, Benage DD. Retinal vein thrombosis after infliximab (remicade) treatment for Crohn's disease. *Am J Gastroenterol* 2003;98:939–40.
- 76 Veerappan SG, Kennedy M, O'Morain CA, *et al.* Retinal vein thrombosis following infliximab treatment for severe left-sided ulcerative colitis. *Eur J Gastroenterol Hepatol* 2008;20:588–9.
- 77 Vergou T, Moustou AE, Maniataas A, *et al.* Central retinal vein occlusion following infliximab treatment for plaque-type psoriasis. *Int J Dermatol* 2010;49:1215–7.
- 78 Diniz B, Barbosa CP, Regatieri CV, *et al.* Oclusão de ramo venoso da retina associado ao uso de infliximabe: relato de caso [Branch retinal vein occlusion following infliximab treatment: case report]. *Arq Bras Oftalmol* 2011;74:214–6.
- 79 Fasci-Spurio F, Thompson A. Cytomegalovirus retinitis in a patient treated with anti-tumor necrosis factor alpha antibody therapy for rheumatoid arthritis. *Clin Infect Dis* 2004;39:e88–94.
- 80 Madill S, Koay P, Mansfield D, *et al.* Sight-threatening keratopathy complicating anti-TNF therapy in Crohn's disease: a case report. *Inflamm Bowel Dis* 2014;20:E2–3.
- 81 Haerter G, Manfras BJ, de Jong-Hesse Y, *et al.* Cytomegalovirus retinitis in a patient treated with anti-tumor necrosis factor alpha antibody therapy for rheumatoid arthritis. *Clin Infect Dis* 2004;39:e88–94.
- 82 Roos JCP, Ostor AJK. Orbital cellulitis in a patient receiving infliximab for ankylosing spondylitis. *Am J Ophthalmol* 2006;141:767–9.
- 83 Agarwal P, Gallagher M, Murphy E, *et al.* Endogenous endophthalmitis in a rheumatoid patient on tumor necrosis factor alpha blocker. *Indian J Ophthalmol* 2007;55:230–2.
- 84 Yoshida M, Yokokura S, Kunikata H, *et al.* Endophthalmitis associated with Purpureocillium lilacinum during infliximab treatment for surgically induced necrotizing scleritis, successfully treated with 27-gauge vitrectomy. *Int Ophthalmol* 2018;38:841–7.
- 85 Sibley CH, Plass N, Snow J, *et al.* Sustained response and prevention of damage progression in patients with neonatal-onset multisystem inflammatory disease treated with anakinra: a cohort study to determine three- and five-year outcomes. *Arthritis Rheumatism* 2012;64:2375–86.
- 86 Heissigerová J, Callanan D, de Smet MD, *et al.* Efficacy and safety of sarilumab for the treatment of posterior segment noninfectious uveitis (SARIL-NIU): the phase 2 SATURN study. *Ophthalmology* 2018;pii: S0161-6420(18)30474-3.
- 87 Roux C, Breuil V, Albert C, *et al.* Ophthalmic herpes zoster infection in patients with rheumatoid arthritis who were treated with tocilizumab. *J Rheumatol* 2011;38:399.
- 88 Terada Y, Kamoi K, Ohno-Matsui K, *et al.* Treatment of rheumatoid arthritis with biologics may exacerbate HTLV-1-associated conditions. *Medicine* 2017;96:e6021.
- 89 Calvo-Río V, Santos-Gómez M, Calvo I, *et al.* Anti-Interleukin-6 receptor tocilizumab for severe juvenile idiopathic arthritis-associated uveitis refractory to anti-tumor necrosis factor therapy: a multicenter study of twenty-five patients. *Arthritis Rheumatol* 2017;69:668–75.
- 90 Burstzyn L, Levin S, Rotenberg B, *et al.* Fulminant bilateral papilloedema during low-dose steroid taper in a child with systemic idiopathic arthritis treated with tocilizumab. *Clin Exp Rheumatol* 2017;35:149–51.
- 91 Stelara. *Ustekinumab [package insert]*. Bloomington, IN: Janssen Biotech, Inc, 2016.
- 92 Lönnerberg AS, Zachariae C, Skov L. Targeting of interleukin-17 in the treatment of psoriasis. *Clin Cosmet Investig Dermatol* 2014;7:251–9.
- 93 Martinez CE, Allen JB, Davidorf FH, *et al.* Endogenous endophthalmitis and osteomyelitis associated with interleukin 17 inhibitor treatment for psoriasis in a patient with diabetes. *BMJ Case Rep* 2017;56:pii: bcr-2017-219296.
- 94 Weiner GJ. Rituximab: mechanism of action. *Semin Hematol* 2010;47:115–23.
- 95 Schuler S, Brunner M, Bernauer W. Rituximab and acute retinal necrosis in a patient with scleromalacia and rheumatoid arthritis. *Ocul Immunol Inflamm* 2016;24:96–8.
- 96 Dogra M, Bajgai P, Kumar A, *et al.* Progressive outer retinal necrosis after rituximab and cyclophosphamide therapy. *Indian J Ophthalmol* 2018;66:591–3.
- 97 Marinella MA. Bilateral conjunctivitis due to rituximab. *Ann Pharmacother* 2007;41:1318.
- 98 Bussone G, Kaswin G, de Menthon M, *et al.* Macular oedema following rituximab infusion in two patients with Wegener's granulomatosis. *Clin Exp Rheumatol* 2010;28:90–2.
- 99 Chan TSY, Cheung CYM, Yeung IYL, *et al.* Cytomegalovirus retinitis complicating combination therapy with rituximab and fludarabine. *Ann Hematol* 2015;94:1043–7. doi:10.1007/s00277-014-2296-5
- 100 Hashida N, Ohguro N, Nishida K. Efficacy and complications of intravitreal rituximab injection for treating primary vitreoretinal lymphoma. *Transl Vis Sci Technol* 2012;1:1.
- 101 Ruderman EM, Pope RM. Drug insight: abatacept for the treatment of rheumatoid arthritis. *Nat Clin Pract Rheumatol* 2006;2:654–60.
- 102 Tsuboi H, Matsumoto I, Hagiwara S, *et al.* Efficacy and safety of abatacept for patients with Sjögren's syndrome associated with rheumatoid arthritis: rheumatoid arthritis with orenica trial toward Sjögren's syndrome Endocrinopathy (ROSE) trial—an open-label, one-year, prospective study—interim analysis of 32 patients for 24 weeks. *Modern Rheumatology* 2015;25:187–93.

- 103 Hatemi G, Christensen R, Bang D, *et al.* Update of the EULAR recommendations for the management of Behçet's syndrome. *Ann Rheum Dis* 2018;2018:808–18.
- 104 Sullu Y. The results of interferon-alpha treatment in Behçet uveitis. *Ocul Immunol Inflamm* 2019;4:1–7.
- 105 Rentiya ZS, Wells M, Bae J, *et al.* Interferon- α -induced retinopathy in chronic hepatitis C treatment: summary, considerations, and recommendations. *Graefes Arch Clin Exp Ophthalmol* 2019;257:447–52.
- 106 Yang L, Ji S, Wang L, *et al.* Episcleritis in a patient with mucosal melanoma treated with interferon alfa-2b and radiotherapy: a case report. *J Med Case Rep* 2018;12:388.
- 107 Iferkhas S, Elasmri F, Chatioui S, *et al.* [Bilateral non-arteritic ischemic optic neuropathy during treatment of viral hepatitis C with pegylated interferon and ribavirin]. *J Fr Ophthalmol* 2015;38:34–40.
- 108 Mangioni D, Soria A, Brighina L, *et al.* A case of classic neuromyelitis optica (Devic's syndrome) triggered by pegylated-interferon α . *BMC Pharmacol Toxicol* 2014;15:56.
- 109 Sahidit Ortega-Ibarra F, Remes-Troche JM. Retinal thrombosis secondary to the combination therapy of pegylated interferon and ribavirin for chronic hepatitis C virus infection: a rare complication. *Rev. esp. enferm. dig.* 2013;105:291–2.
- 110 Kawazoe T, Araki M, Lin Y, *et al.* New-Onset type 1 diabetes mellitus and anti-aquaporin-4 antibody positive optic neuritis associated with type 1 interferon therapy for chronic hepatitis C. *Intern Med* 2012;51:2625–9.
- 111 Kang HY, Shin MC. Pegylated interferon-associated severe retinopathy in a patient with chronic hepatitis. *Korean J Ophthalmol* 2012;26:147–50.
- 112 Monzon JG, Hammad N, Stevens SD, *et al.* Retinopathy associated with adjuvant high-dose interferon-2b in a patient with resected melanoma: a case report and review of the literature. *Oncologist* 2012;17:384–7.
- 113 Knyazer B, Lifshitz T, Marcus M, *et al.* Anterior ischemic optic neuropathy in a patient with hepatitis C treated with interferon-alpha and ribavirin. *Isr Med Assoc J* 2011;13:251–3.
- 114 Sheth H, Michaelides M, Siriwardena D. Cystoid macular edema and visual loss as sequelae to interferon alpha treatment of systemic hepatitis C. *Indian J Ophthalmol* 2010;58:147–8.
- 115 Lim JH, Lee YN, Kim YS, *et al.* Vogt-Koyanagi-Harada disease occurring during PEGylated interferon- α 2b and ribavirin combination therapy for chronic hepatitis C. *Korean J Hepatol* 2011;17:61–5.
- 116 Narkewicz MR, Rosenthal P, Schwarz KB, *et al.* Ophthalmologic complications in children with chronic hepatitis C treated with pegylated interferon. *J Pediatr Gastroenterol Nutr* 2010;51:183–6.
- 117 Fragoso YD, Paggiaro MSS, Mastromauro R, *et al.* Literature systematic review on the ophthalmological side effects of interferons. *Arq Bras Oftalmol* 2011;74:306–10.
- 118 Novelli FJde, Przysiezny A, Rosa EL, *et al.* Ophthalmologic findings in hepatitis C patients treated with pegylated interferon α -2b and ribavirin. *Arq Bras Oftalmol* 2014;77:178–81.
- 119 Panetta JD, Gilani N. Interferon-Induced retinopathy and its risk in patients with diabetes and hypertension undergoing treatment for chronic hepatitis C virus infection. *Aliment Pharmacol Ther* 2009;30:597–602.
- 120 Rodney AJ, Gombos DS, Pagliaro LC, *et al.* Ischemic optic neuropathy associated with low-dose interferon alfa: report of two cases. *Am J Clin Oncol* 2009;32:86–7.
- 121 Sène D, Touitou V, Bodaghi B, *et al.* Intraocular complications of IFN- α and ribavirin therapy in patients with chronic viral hepatitis C. *WJG* 2007;13:3137–40.
- 122 Oishi A, Miyamoto K, Kashii S, *et al.* Abducens palsy and Sjogren's syndrome induced by pegylated interferon therapy. *Br J Ophthalmol* 2007;91:843–4.
- 123 Zandieh I, Adenwalla M, Cheong-Lee C, *et al.* Retinal vein thrombosis associated with pegylated-interferon and ribavirin combination therapy for chronic hepatitis C. *WJG* 2006;12:4908–10.
- 124 Gonçalves LL, Farias AQ, Gonçalves PL. Branch retinal vein thrombosis and visual loss probably associated with pegylated interferon therapy of chronic hepatitis C. *WJG* 2006;12:4602–3.
- 125 Nakamura A, Tojo K, Takasu K, *et al.* Unilateral oculomotor nerve palsy induced by combination therapy of interferon- α 2b and ribavirin. *Intern Med* 2005;44:682–3.
- 126 Ayaki M. Development of neovascular glaucoma in the course of interferon alfa therapy for hepatitis type C. *Br J Ophthalmol* 1994;78:238.
- 127 Fukumoto Y, Shigemitsu T, Kajii N, *et al.* Abducent nerve paralysis during interferon alpha-2a therapy in a case of chronic active hepatitis C. *Intern. Med.* 1994;33:637–40.
- 128 Kwon YS, Choe YH, Chin HS. Development of glaucoma in the course of interferon alpha therapy for chronic hepatitis B. *Yonsei Med J* 2001;42:134–6.
- 129 KL T, Bowyer J, Schofield K, *et al.* Severe interferon associated retinopathy. *Br J Ophthalmol* 2003;87:247–8.
- 130 Peponis V, Kytтарыс VC, Chalkiadakis SE, *et al.* Review: ocular side effects of anti-rheumatic medications: what a rheumatologist should know. *Lupus* 2010;19:675–82.
- 131 Rubbert-Roth A. Assessing the safety of biologic agents in patients with rheumatoid arthritis. *Rheumatology* 2012;51:v38–47.