



Case report

Metastasis of cervical cancer to breast: A case report and review of literature



Ankit Mangla^{a,*}, Nikki Agarwal^b, Farid Saei Hamedani^c, Jiaxiang Liu^d, Shweta Gupta^a,
Michael R. Mullane^a

^a Department of Internal Medicine, Division of Hematology Oncology, John H. Stroger Jr. Hospital of Cook County, 1901 West Harrison Street, Chicago, IL 60612, United States

^b Division of Hematology/Oncology, John H. Stroger Jr. Hospital of Cook County, 1901 West Harrison Street, Chicago, IL 60612, United States

^c Department of Pathology, Division of Surgical Pathology, John H. Stroger Jr. Hospital of Cook County, University of Illinois at Chicago, 1901 West Harrison Street, Chicago, IL 60612, United States

^d Department of Internal Medicine, John H. Stroger Jr. Hospital of Cook County, 1901 West Harrison Street, Chicago, IL 60612, United States

ARTICLE INFO

Keywords:

Cervical cancer
Breast metastases
Mammogram
Ultrasound
Immunohistochemistry

ABSTRACT

Metastasis to the breast from an extra-mammary malignancy has been documented in literature, however cervical cancer metastasis to the breast is very rare. Thirty-eight cases of metastatic deposit to the breast from cervical cancer have been reported in literature. Though most patients present with a breast lump, it is very difficult to clinically distinguish a primary breast malignancy from a metastatic deposit. Histopathology of the tissue, aided with immune-histochemical staining pattern provides a definitive diagnosis. Our patient, a 51-year old woman presented with breast lump and history of post-menopausal bleeding. Upon further workup, the patient was diagnosed with cervical cancer. The mammogram and ultrasound of the breast showed multiple lumps within the breast. Histopathology of the breast mass showed metastatic deposit in the breast from cervical cancer. The patient was treated with radiation therapy to the cervix along with concurrent chemotherapy for local control of pain. After completion of local treatment, she started systemic chemotherapy, however she developed health-care associated pneumonia and subdural hematoma leading to deterioration in her performance status. The patient opted for hospice care and died 2 months later. In this report, we will review the presentation of the 38 cases reported in literature and the imaging and histopathologic findings of metastatic deposits to the breast.

1. Introduction

Breast cancer metastasizing to different organs is a common phenomenon, however metastasis to the breast from a distant malignancy is quite rare. The first reported case of an extra-mammary organ metastasizing to the breast was published in 1903 (Trevithick, 1903). In a 90-year study of tumor registry from Royal London hospital, only 60 out of nearly 14,000 patients with breast cancer were identified to have metastatic deposit in the breast from a hematological or non-hematological malignancy (Georgiannos et al., 2001). Out of these 60 patients, approximately 30% were identified postmortem (Georgiannos et al., 2001). The cumulative incidence of non-mammary malignancies metastasizing to the breast is nearly 1.7–6.6% based on other post mortem autopsy studies (Bonito et al., 1991). Clinical studies estimate a lower incidence of nearly 0.4–3% (Bonito et al., 1991; Klingen et al., 2009). It is important to distinguish primary breast malignancy from a metastatic

deposit, as it not only changes patient management but also foretells a poor prognosis (Lee, 2007). Histopathology, immunohistochemistry (IHC) and imaging studies play a critical role in evaluation of a breast lump and distinguishing a primary tumor of the breast from a metastatic deposit from an extra mammary malignancy (Lee, 2007). In this case-report, we describe the case of a patient who presented with a breast lump and on further workup was diagnosed with poorly differentiated cervical carcinoma with metastatic deposit to the breast. Here, we will discuss the diagnostic challenges, radiographic features and utility of histopathological studies in differentiating primary breast cancer from metastasis to the breast from an extra-mammary malignancy.

2. Case report

A 50-year old woman with past medical history of congestive heart

E-mail address: ankit.mangla.md@gmail.com (A. Mangla).

Abbreviations: AUC, area under curve; EBRT, external beam radiation therapy; ECOG, European Cooperative Group; GCDFF, gross cystic disease fluid protein 15; HPV, human papilloma virus; IHC, immunohistochemistry; LN, lymph nodes; US, ultrasound

* *Corresponding author.

<http://dx.doi.org/10.1016/j.gore.2017.06.009>

Received 5 May 2017; Received in revised form 7 June 2017; Accepted 10 June 2017

Available online 12 June 2017

2352-5789/ © 2017 The Authors. Published by Elsevier Inc. This is an open access article under the CC BY-NC-ND license (<http://creativecommons.org/licenses/by-nc-nd/4.0/>).

failure, asthma and hypertension presented with a hard, non-tender lump in her right breast which she noticed on breast self-exam. On review of systems she gave history of post-menopausal vaginal bleeding and several incidents of severe pain in the pelvic area for the past 3 months. She also gave history of unprotected sexual intercourse and post-coital bleeding a couple of weeks prior to the presentation. She denied any constitutional symptoms including weight loss, appetite loss or night sweats. Her obstetric and gynecologic history was significant for G6P5015, menarche at the age of 14 years and spontaneous menopause around 20 years ago. The patient denied any workup being done for early menopause and only remembered having hot flashes around that time. She also confirmed having regular pap smears over last 3 decades, which were reported to her as ‘normal’. Her family history was significant for first degree relatives being diagnosed with ovarian and cervical cancer. Physical exam at presentation was significant for a 3 × 2.5 cm mass in the right breast which appeared to be within the subcutaneous fat. The mass was hard, not tender and was not stuck to the chest wall or the skin above the mass. The pelvic exam showed a firm cervix with nodularity of the os from 6’o clock to 8’o clock position. No discrete mass was seen on ectocervix, but induration was noted on endocervix and enterovesical septum. The uterus was nearly 10 weeks in size and firm on palpation.

The endovaginal ultrasound showed 10.6 × 3.8 × 4.1 cm uterus with endometrial stripe of 9.2 mm (no internal vascularity noted within the endometrium). Another 4.8 × 4.4 × 5.1 cm bulky heterogenous hypervascular mass was noted within the cervix. A simple cyst was noted within the right ovary, the left ovary was not visualized. The mammogram with targeted ultrasound showed a grossly well circumscribed 1 cm mass in right breast and a 7 mm nodule in the left upper outer breast (Fig. 1). Targeted ultrasound of right breast showed an ill-

defined oval 2.8 cm mass at 5’o clock position and another ill-defined 8 mm solid mass at 1’o clock position along with multiple enlarged lymph nodes in the right axilla measuring upto 2 cm. Targeted ultrasound of left breast showed a small 7 mm oval, well circumscribed mass in medial upper quadrant (Fig. 1). The CT of the Chest, abdomen and pelvis showed multiple small pulmonary nodules (approximately 7 mm in size), multiple bilateral adrenal nodules and extensive lymphadenopathy (8–12 mm size) including supraclavicular, mediastinal, gastro-hepatic, retroperitoneal and bilateral Illiac and inguinal lymph nodes (LN). The histopathology from the endocervical and endometrial tissue showed poorly differentiated carcinoma (Fig. 2, Panel A). The IHC stains showed that the tumor cells were positive for Cam 5.2, EMA, AE 1/3 and p16 (Fig. 2, Panel B–D). The tumor cells did not stain with CK-7, CK-20, Vimentin, p53, p63, squamous cocktail, HMB-45, chromogranin, synaptophysin and CD-10. Based on the pattern of IHC staining, the patient was diagnosed with poorly differentiated carcinoma favoring cervical origin. The breast mass was also biopsied and the pathology showed metastatic poorly differentiated carcinoma with similar histologic and IHC features when compared with endocervical tissue. The IHC stains were positive for p16, E-cadherin, AE1/3 and Cam 5.2. The IHC stains were negative for CK-7, CK-20, p63, mammaglobin and gross cystic disease fluid protein 15 (GCDFFP). The mammogram was read as BIRADS-6 (Biopsy proven malignancy).

The patient was diagnosed with stage IVB cervical cancer. The patients’ case was discussed in a multidisciplinary meeting and a decision was made to treat her with concurrent chemoradiation to alleviate symptoms and achieve a more durable response. She was treated with palliative external beam radiation therapy (EBRT) (45 Gy delivered over 22 fractions) to the pelvis and concurrent chemotherapy with weekly Cisplatin (40 mg/m²). Restaging CT scans after completion of

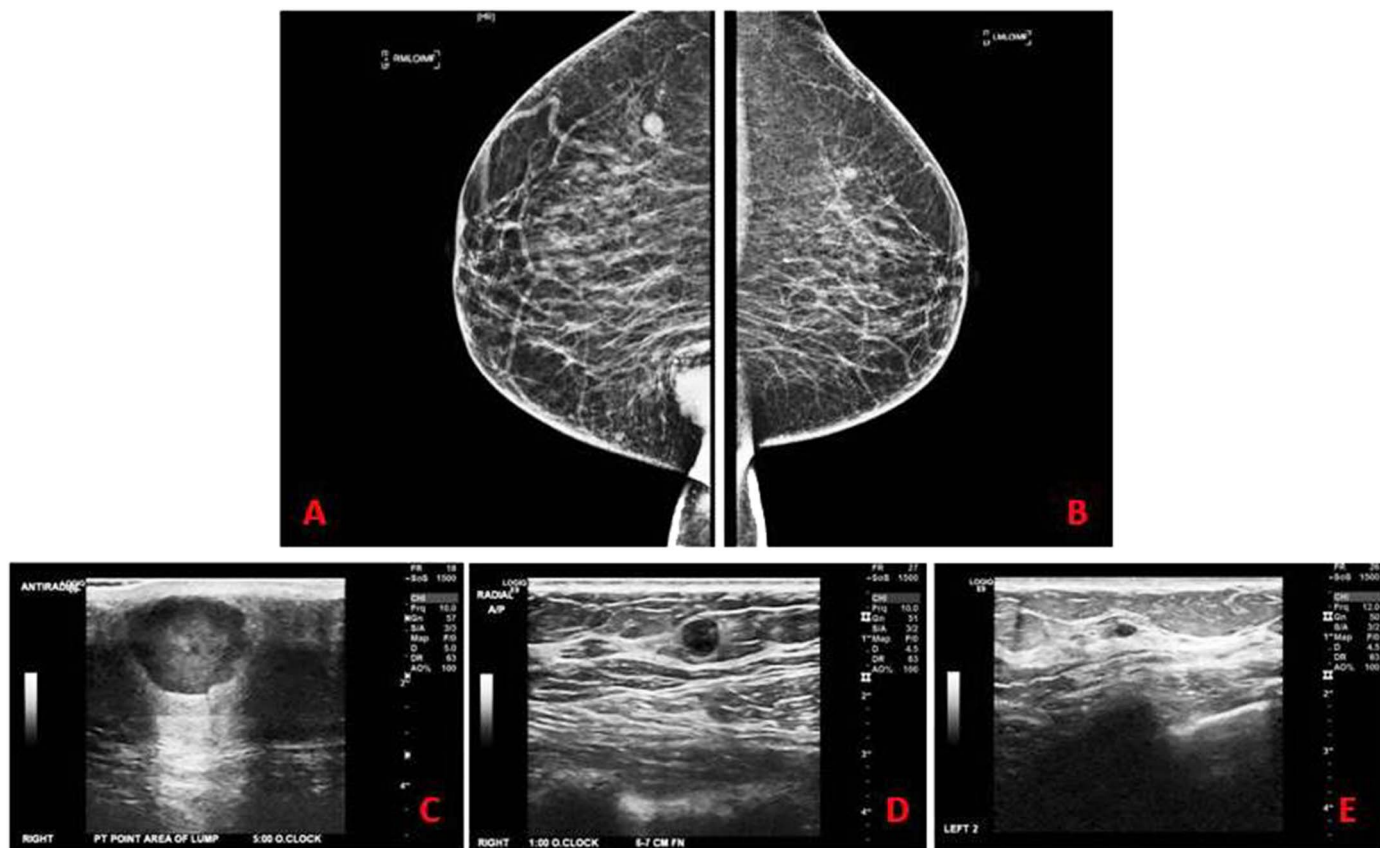


Fig. 1. Panel A: Right breast-shows incompletely included mass in the right infra-mammary central region and 1 cm well circumscribed mass in the right upper inner breast. Panel B: Left breast- shows small sub-centimeter nodule in the left deep upper breast and scattered round micro-calcifications in the left deep outer breast. Panel C: Targeted right US- ill defined 2.8 cm mass at 5’o clock position. Panel D: Targeted right US- Slightly ill defined round 8 mm solid mass. Panel E- small 7 mm oval well circumscribed lesion at 2’o clock.

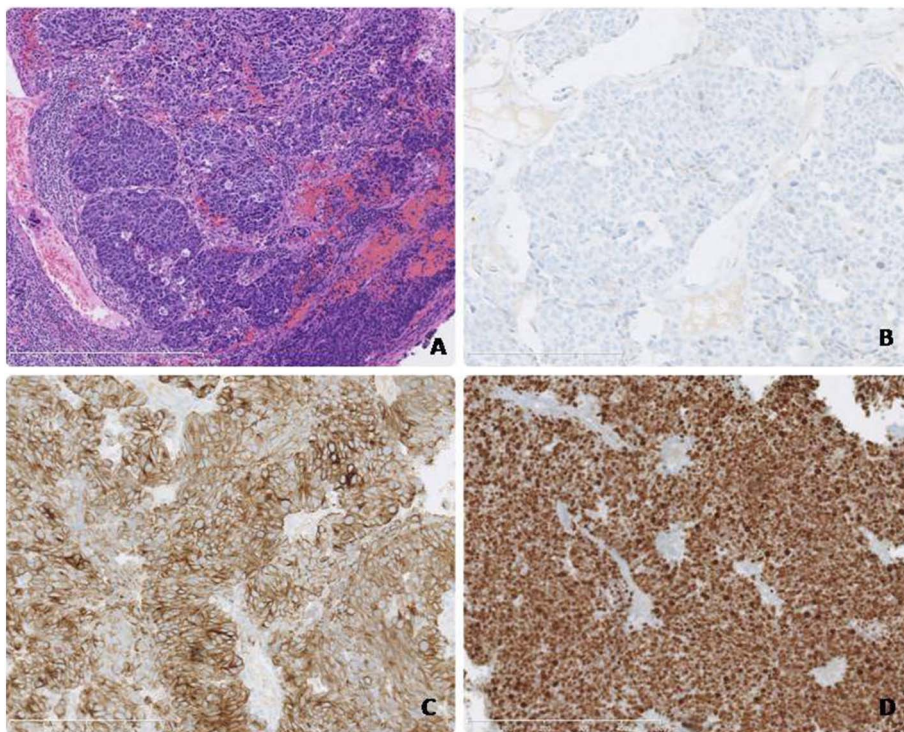


Fig. 2. Panel A: Poorly differentiated carcinoma in the endocervical biopsy (H & E). Panel B: Negative CK7, CK20, p63, CK5/6, Synaptophysin, Chromogranin, MART-1 and S-100 by IHC. Panel C: Positive AE1/AE3 and CK8/18. Panel D: MIB-1 labeling index of almost 100%.

concurrent chemotherapy and EBRT showed improvement in the local disease as well as showed a favorable response in the breast metastasis, which was confirmed by positron emission tomography. After completion of her concurrent chemotherapy and EBRT, the patient was started on systemic therapy with Carboplatin (AUC 5) and Paclitaxel (175 mg/m²). Bevacizumab was eliminated from her treatment as bleeding from vagina remained a major risk factor in her care. After one cycle of chemotherapy the patient was admitted to the hospital with severe generalized pain and fever. She was diagnosed with health care associated pneumonia and was started on broad spectrum antibiotics. During this admission, she also developed dural metastasis and subdural fluid collection. Her performance status declined to Eastern Cooperative Oncology Group (ECOG) status 2–3. The patient declined any further treatment and chose to enroll in hospice care.

3. Discussion

Melanoma, lymphoma, lung cancer, soft tissue sarcoma, ovarian carcinoma, gastro-intestinal and genitourinary malignancies are known to metastasize to the breast (Akçai, 2002). However, the most common metastasis to the breast comes from the opposite breast (McIntosh et al., 1976). Cervical cancer metastasizing to the breast is rare. Almost all patients with metastasis to the breast present with breast lump and it is very difficult to distinguish between a primary breast tumor and a metastasis based solely on clinical presentation (Bartella et al., 2003). The location of the mass in the superficial sub-cutaneous tissue is a clue towards a metastatic deposit, which could be associated with the rich blood supply in the subcutaneous fat and skin when compared with breast parenchyma (Noguera et al., 2007). In a patient with another primary malignancy the presence of one or more palpable masses in breast; or nodules in the sub-cutaneous tissue also raises the suspicion for metastasis to the breast (Sabatier et al., 2012). An inflammatory breast mass is an extremely rare presentation of a metastasis to breast (Sabatier et al., 2012).

In our review of 38 historical cases, more than 50% of patients had SCC of cervix, though few patients also had adenocarcinoma,

adenosquamous carcinoma and the small cell variant of cervical cancer. The metastasis occurred to either breasts, however fewer patients had bilateral deposits. Though the data on presentation of patients was not reported consistently in all studies, very few patients presented with breast lumps and majority of patients presented with symptoms related to cervical cancer. The temporal relation between diagnosis and treatment of cervical cancer and detection of breast lump varied from 0 months to over 9 years. There was no obvious preference in terms of stage of presentation of cervical cancer, as even patients with low stage tumors (Stage I and II) developed metastasis to the breast. Most of the patients were offered palliative chemotherapy, however one patient underwent palliative mastectomy and one patient underwent resection of the involved quadrant. Considering the rarity of such a presentation and the paucity of clinical reports, it would be frivolous to judge one modality of treatment over the other. Since the patient had a bulky cervical mass which was the cause of intense pain and bleeding, we approached the patient with concurrent chemotherapy and radiation first with the intent of alleviating symptoms and controlling local disease. Systemic chemotherapy was planned for offering palliation of her disease at a later stage. Despite of various modalities of treatment offered to patients in different case reports, overall survival after detection of breast metastasis was consistently poor in all reports.

3.1. Role of histopathological studies

Histopathology is a quintessential requirement in differentiating primary breast tumor from metastases (Georgiannos et al., 2001; Klingen et al., 2009). High grade cytological features, lack of differentiation, diffuse growth, absence of ductal or lobular in-situ components, lack of elastosis and sharp transition at the border of the lesion raises the possibility of a metastatic deposit (Georgiannos et al., 2001; Klingen et al., 2009). Though the morphology of the tissue is most important in identifying a tumor, IHC profile plays a pivotal role in reaching the diagnosis (Georgiannos et al., 2001; Klingen et al., 2009; Zaha, 2014). Several IHC markers are used in identifying primary breast cancer (Table 1) (Zaha, 2014). Likewise, many IHC stains are also

Table 1
Immunohistochemical markers used in identifying breast cancer and determining prognosis.

| Marker | Staining pattern | Utility |
|--|--|--|
| <i>Myoepithelial marker</i> | | |
| Smooth muscle actin (SMA) | Cytoplasmic | Differentiates between invasive and benign proliferations with similar morphologic appearance |
| Calponin | Cytoplasmic | |
| p63 | Nuclear | |
| Smooth muscle myosin heavy chain (SMMHC) | Cytoplasmic | |
| <i>Ductal and lobular CIS</i> | | |
| E-Cadherin | Membranous | Ductal CIS is positive for E-Cadherin and peripheral cytoplasmic CK-8 |
| Cytokeratin-8/18 | Peripheral cytoplasmic or perinuclear | |
| <i>Mammary origin in metastatic carcinoma</i> | | |
| Gross cystic disease fluid protein 15 (GCDFFP) | Cytoplasmic | Useful in detecting breast tissue in distant metastasis where morphologic appearance can be misleading |
| Mammoglobin | Cytoplasmic | |
| Carcinoembryonic antigen protein (CEA) | Cytoplasmic | |
| <i>Prognostic markers</i> | | |
| Estrogen receptor (ER) | Nuclear | Useful in directing hormonal therapy in treatment of breast cancer |
| Progesteron receptor (PR) | Nuclear | |
| Human epidermal growth factor (HER-2) | Membranous | |
| Ki-67 (MIB-1) | Nuclear | |
| Factor VIII related antigen | Cytoplasmic | Useful as proliferation index (Ki-67) Markers of angiogenesis |
| Vascular endothelial growth factor | Nuclear membrane, cytoplasmic membrane and cytoplasm | |

useful in distinguishing cervical cancer from benign mimics and other cancers. The p16^{INK4a} is associated with high risk human papilloma virus (HPV) and is not seen in normal cervical epithelium (Nam et al., 2007). In conjunction with MIB1 (or Ki-67) it is useful in detecting small high grade cervical intra-epithelial neoplastic (CIN) lesions (Nam et al., 2007). The panel of Estrogen receptor, progesterone receptor, Vimentin and Monoclonal CEA are used to distinguish ovarian and endometrioid type of ovarian cancer from cervical cancer (McCluggage, 2007). In this patient, the IHC stains were partially positive for p16 and Pan-cytokeratin. Though the cells were poorly differentiated, the above positive panel strongly points towards a carcinoma (Pancycytokeratin positive) and possibility of cervical origin (p16 positive).

3.2. Role of imaging studies

Metastases to the breast either take a lymphangitic route or a hematogenous route (Mun et al., 2014). Where metastasis to the opposite breast occurs most commonly via lymphatic system, distant metastases to the breast occur via hematogenous route (Chung & Oh, 2001). In lymphangitic metastasis, the mammogram shows skin thickening, dense subcutaneous tissue, a thick trabecular pattern along with dense and irregular stroma (Chung & Oh, 2001). In patient with hematogenous metastasis, mammogram shows unilateral or bilateral, solitary or multiple, round masses with circumscribed ill-defined borders (Chung & Oh, 2001). Calcifications are typically absent unless the metastasis is from ovaries, thyroid or mucin producing tumors (Chung & Oh, 2001). On ultrasound hematogenous metastasis are round to oval in shape, well circumscribed (occasionally microlobulated hypochoic masses) without desmoplastic reaction, spiculations, calcifications, architectural distortion or retrotumoral acoustic shadowing (Mun et al., 2014). On the other hand, lymphangitic metastasis show hypochoic masses associated with axillary or internal mammary LN enlargement, diffuse skin thickening, obliteration of subcutaneous fat and lymphatic dilation secondary to mechanical obstruction of draining lymphatics (Mun et al., 2014). MRI are useful for young patients with dense breast parenchyma and CT scans may show multiple bilateral circumscribed masses along with lymphadenopathy (Mun et al., 2014).

4. Conclusion

Any patient presenting with a lump in the breast should always be worked up for a primary breast malignancy first. Though metastasis to

the breast from a non-mammary malignancy is well documented in literature, the incidence is still very low. Unfortunately, it is very difficult to clinically distinguish whether a breast lump is a primary breast cancer or a metastatic deposit. However, in a patient with a second tumor, the physician should keep a high index of suspicion regarding the possibility of a metastatic deposit in the breast. Though imaging tools like mammogram and US may provide with useful clues, the diagnosis is almost always made based on histopathology and IHC profile of the tissue sample. It is imperative to distinguish a primary breast tumor from a metastatic deposit as it not only changes treatment of the patient, but also predicts a poor prognosis.

Statement of funding

This research did not receive any specific grant from funding agencies in the public, commercial, or not-for-profit sectors.

Statement of consent

Informed consent was obtained from the patient and would be provided to the journal upon request.

Acknowledgment

AM and NA wrote the manuscript and prepared the images and tables. AM, NA and LG did research on references and prepared the summary tables. FSH prepared the images, edited the manuscript and provided expert opinion on pathology. SG and MRM provided critique and expert opinion on the manuscript.

References

- Akçai, M.N., 2002. Metastatic disease in the breast. *Breast* 11, 526–528.
- Bartella, L., Kaye, J., Perry, N.M., et al., 2003. Metastases to the breast revisited: radiological histopathological correlation. *Clin. Radiol.* 58, 523–531.
- Bonito, L.D., Luchi, M., Giarelli, L., et al., 1991. Metastatic tumors to the female breast. An autopsy study of 12 cases. *Pathol. Res. Pract.* 187, 432–436.
- Chung, S.Y., Oh, K.K., 2001. Imaging findings of metastatic disease to the breast. *Yonsei Med. J.* 42, 497–502.
- Georgiannos, S.N., Chin, J., Goode, A.W., et al., 2001 Nov 1. Secondary neoplasms of the breast: a survey of the 20th century. *Cancer* 92 (9), 2259–2266.
- Klingen, T.A., Klassen, H., Aas, H., et al., 2009 Oct. Secondary breast cancer: a 5-year population based study with review of literature. *APIMS* 117 (10), 762–767.
- Lee, A.H., 2007. The histological diagnosis of metastases to the breast from extra-mammary malignancies. *J. Clin. Pathol.* 60 (12), 1333–1341.

- McCluggage, W.G., 2007 Feb. Immunohistochemistry as a diagnostic aid in cervical pathology. *Pathology* 39 (1), 97–111.
- McIntosh, I.H., Hooper, A.A., Millis, R.R., Greening, W.P., 1976. Metastatic carcinoma within the breast. *Clin. Oncol.* 2, 393–401.
- Mun, S.H., Ko, E.Y., Han, B.K., et al., 2014. Breast metastases from extramammary malignancies: typical and atypical ultrasound features. *Korean J. Radiol.* 15 (1), 20–28.
- Nam, E.J., Kim, J.W., Kim, S.W., et al., 2007. The expressions of the Rb pathway in cervical intraepithelial neoplasia; predictive and prognostic significance. *Gynecol. Oncol.* 104 (1), 207–211.
- Noguera, J., Martínez-Miravete, P., Idoate, F., et al., 2007. Metastases to the breast: a review of 33 cases. *Australas. Radiol.* 51, 133–138.
- Sabatier, R., Roussin, C., Riviere, J.P., et al., 2012 May. Breast metastasis of a squamous cell carcinoma of the uterine cervix mimicking inflammatory breast cancer. *Case Rep. Oncol.* 5 (2), 464–470.
- Trevithick, E., 1903. A case of chloroma with clinical history and account of post mortem appearances. *Lancet* 2, 158–160.
- Zaha, D.C., 2014 Aug 10. Significance of immunohistochemistry in breast cancer. *World J. Clin. Oncol.* 5 (3), 382–392.