

Magnification endoscopy in esophageal squamous cell carcinoma: a review of the intrapapillary capillary loop classification

Haruhiro Inoue^a, Makoto Kaga^a, Haruo Ikeda^a, Chiaki Sato^a, Hiroki Sato^a, Hitomi Minami^a, Esperanza Grace Santi^a, Bu'Hussain Hayee^b, Nikolas Eleftheriadis^a

Showa University Koto-Toyosu Hospital, Tokyo, Japan; King's College Hospital NHS Foundation Trust, London, UK

Abstract

Recent developments in image-enhancement technology have enabled clear visualization of the microvascular structure of the esophageal mucosa. In particular, intrapapillary capillary loops (IPCLs) are observed as brown loops on magnification endoscopy with narrow-band imaging (NBI). IPCLs demonstrate characteristic morphological changes according to the structural irregularity of esophageal epithelium and cancer infiltration, summarized in the IPCL classification. In this review, the process from the first endoscopic description of IPCLs to the eventual development of the IPCL classification is described and discussed, particularly focusing on early stage squamous cell carcinoma of the esophagus.

Keywords intrapapillary capillary loop classification, narrow-band imaging, magnification endoscopy, endoscopic mucosal resection, endoscopic submucosal dissection

Ann Gastroenterol 2015; 28 (1): 41-48

Introduction

Early detection of esophageal squamous cell carcinoma is directly related to improved prognosis [1,2]. Lesions confined to the mucosal layer can be treated by local endoscopic resection (endoscopic mucosal resection [EMR]/endoscopic submucosal dissection [ESD]) [3-6] and/or endoscopic ablation [7] instead of surgery [8,9], because there is usually no risk of lymph node metastasis [1,2,10,11]. Therefore, a major target of endoscopic screening is to pick up these early, endoscopically resectable lesions [12-14]. A submucosally invasive cancer often demonstrates considerable morphological changes: elevated (0-I) and/or excavation (0-IIc/III) on standard non-magnified imaging [15]. This surface change is accompanied by a destruction of the original mucosal structure [11,15]. By contrast, an intramucosal cancer generally has a flat appearance with minimal impact on the contour of the mucosal surface (0-IIa, IIb, IIc). However, the relationship

of these appearances with the depth of invasion is not always quantitative and clear. An endoscopic diagnosis based solely on this gross, macroscopic appearance of a tumor is therefore of limited value. It definitely needs to be stated that deciding whether a lesion is intramucosal or submucosally invasive (SM) has profound implications of the treatment modality chosen. It is essential, therefore, to have an additional - more accurate - method of determining the depth of invasion. In addition, the differential diagnosis of high- from low-grade intraepithelial neoplasia is also important, because high-grade intraepithelial neoplasia should be treated by endoscopic resection. When Lugol staining is employed, among Lugol-voiding areas a useful endoscopic criterion to detect high-grade intraepithelial neoplasia or intramucosal cancer is the "pink-color" sign [16,17] (Fig. 1A). This is readily identified as the "metallic silver" sign when it is seen with narrow-band imaging (NBI) enhancement [18] (Fig. 1B). However, flat unstained areas smaller than 5 mm are usually not high-grade dysplasia. These can be disregarded during endoscopy in order to save procedural time [19]. While the diagnostic accuracy of these criteria is acceptable, there still remains considerable room for improvement, particularly in the diagnosis of border-line lesions. In this situation, an accurate endoscopic diagnosis with magnification endoscopy is practically more important, considering the inter- and intra-observer variation for histologic assessment and the uncertainty that this generates [20].

NBI is in use as a novel image enhancement technology [21] employing light filters to allow penetration at peak wavelengths of 415 (390-445) nm and 540 (530-550) nm. Light in these "narrow bands" is readily absorbed by hemoglobin, such that blood vessels on the mucosal surface are highlighted brown

^aDigestive Disease Center, Showa University Koto-Toyosu Hospital, Tokyo, Japan (Haruhiro Inoue, Makoto Kaga, Haruo Ikeda, Chiaki Sato, Hiroki Sato, Hitomi Minami, Esperanza Grace Santi, Nikolas Eleftheriadis); ^bDepartment of Gastroenterology, King's College Hospital NHS Foundation Trust, London SE5 9RS, UK

Conflict of Interest: Haruhiro Inoue is an advisor for Olympus

Correspondence to: Haruhiro Inoue, MD, PhD, Digestive Disease Center, Koto-Toyosu Hospital, Tokyo, Japan, Chigasaki Chuo 35-1, Tsuzuki-ku, Yokohama, 224 8503 Japan, Fax: +81 45 949 7263, e-mail: haruinoue777@yahoo.co.jp

Received 26 July 2014; accepted 2 September 2014

with high contrast to background tissue, allowing capillary patterns to be examined in great detail [22].

In a randomized controlled multicenter trial, NBI was able to detect superficial cancer more frequently than white light imaging in both the head and neck region and the esophagus (100% vs. 8%, $P < 0.01$; 97% vs. 55%, $P < 0.01$, respectively) [23]. However, areas highlighted by NBI do not always represent cancer. Borderline lesions [those “indefinite for neoplasia” (Vienna 2) or “intraepithelial neoplasia” (Vienna 3, 4)] are readily detected by this method [20,22], particularly in heavy drinkers and smokers [24]. In these patients, Lugol’s iodine staining of the esophageal mucosa produces a “leopard-print” pattern of stained and unstained areas [16]. On this background, cancer can develop in multiple areas from the pharynx to esophagus, supporting the field-change concept of carcinogenesis by chronic inflammation [25]. In order to interpret tissue atypia in more detail, magnification endoscopy in conjunction with NBI enhancement was employed (termed NBI magnification). This approach creates a highly contrasted and detailed image of the microvascular structure (capillary pattern) in the squamous epithelium [21].

In the glandular epithelium of the stomach, colon and Barrett’s esophagus magnification endoscopy demonstrates both the contours of the mucosal surface and the vascular pattern [26-30]. In the squamous epithelium, however, the micro-vascular pattern of intrapapillary capillary loops (IPCLs) is the only reliable indicator of tissue atypia. IPCLs were firstly identified using white light before the development of NBI and a series of reports were published in peer-reviewed journals [31,32] (Fig. 2, 3). However, microvessel observation using white-light magnification endoscopy is challenging due to the poor contrast to background mucosa. NBI produces a high-contrast image and facilitates ready recognition of IPCLs.

This review focuses on analyzing the initial reports with white light and the articles regarding the utility of magnification endoscopy in the diagnosis of esophageal squamous cell cancer.

Magnification endoscopic findings for superficial vasculature in normal esophageal mucosa (IPCL-I)

Without magnification, branching vessels are identified as a network of green vessels in the horizontal plane (located immediately above the muscularis mucosae) [31]. IPCLs, which rise perpendicularly from the branching vessel network are barely visible. By using a high-definition endoscope, IPCLs in the normal mucosa are identified as red dots under white light and as brown dots with NBI. Magnification with NBI provides a more detailed image of IPCLs as brown loops, in which the flow of red blood cells (RBCs) can sometimes be observed (Fig. 4). As IPCLs are end capillaries which allow the passage of single RBCs, the inner diameter of one IPCL can be surmised to be approximately the diameter of an RBC (7-10 μm). As IPCLs run in the intraepithelial papilla adjacent to basement membrane of the squamous epithelium, they may be affected by alterations in the basal and/or parabasal layer and directly reflect morphological changes of the epithelial papilla.

Esophagitis and reactive change (IPCL-II)

The major cause of esophagitis is gastroesophageal reflux disease, with acid in the esophagus causing erosive change to the squamous mucosa. Erosive lesions have irregular and unclear epithelial margins with characteristic features of IPCLs. IPCL-II is characterized by dilatation and elongation of these capillaries, appearing at the margin of erosions.

Magnification endoscopic diagnosis for tissue atypia of the squamous epithelium

IPCL changes can be first appreciated in inflammatory mucosa, progressing through low- to high-grade dysplasia and

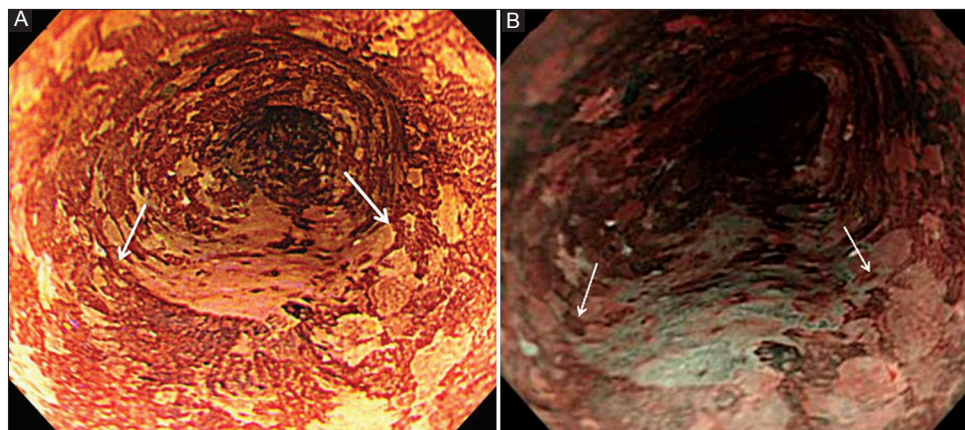


Figure 1 (A) Squamous cell carcinoma developed on esophageal mucosa with multiple Lugol-voiding area. T1-EP (cancer confined with epithelium) (B) With narrow-band imaging, the cancerous area indicated in “A” appears shiny silver. This phenomenon is called “metallic silver sign” Lugol spraying on esophageal mucosa revealed mixture of stained and unstained area. This is called “leopard-print” pattern, often observed in patients with heavy alcohol use. Between the white arrows a “pink” lesion of squamous cell carcinoma was observed. Pink color sign is a valuable indicator to identify high-from low-grade dysplasia on squamous epithelium

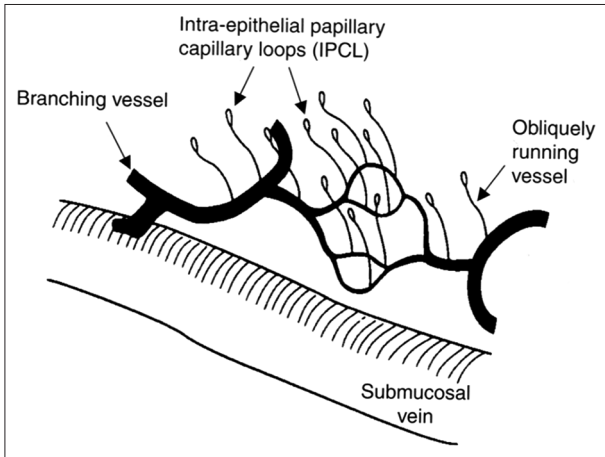


Figure 2 Schematic drawing of magnification endoscopic findings for superficial vascular structure in the squamous esophagus. (Copied from reference 31)

Superficial blood vessels in the esophageal mucosa consist of branching vessels which extend in the horizontal plane and exist immediately above the muscularis mucosae. The intra-epithelial papillary capillary loop (IPCL) originates from a branching vessel, and runs perpendicularly in the lamina propria finally reaching the intra-epithelial papilla. The blood vessel, observed under regular non-magnification endoscopy, is the branching vessel. When esophageal squamous mucosa is magnified up to around 100 times, looping vessels (IPCLs) are observed, as shown in Fig. 2, demonstrated as brown loops under narrow-band imaging-enhanced observation

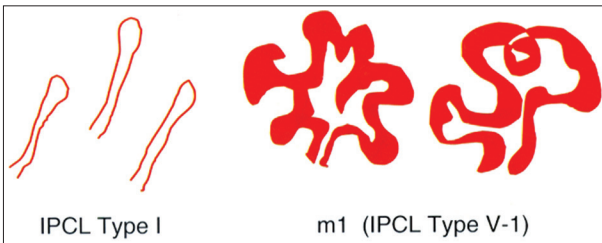


Figure 3 Schematic drawing of typical intrapapillary capillary loop (IPCL) changes from normal to cancerous pattern. (Copied from reference 32)

In normal epithelium, IPCL is observed as a smooth running, small-diameter capillary vessel (IPCL Type I). In carcinoma *in situ* IPCL demonstrates characteristic morphological changes. The abnormal IPCL pattern for m1 lesion (carcinoma *in situ*) is IPCL Type V-1, exhibiting the following four pattern changes: dilatation, meandering, irregular caliber, and form variation

finally to cancer [33]. Consequently, IPCL-I and -II represent normal and inflammatory change, respectively, whilst IPCL-III and a part of IPCL-IV are categorized to “borderline” lesions between benign and malignant tumors. IPCL-III is a feature of atrophic mucosa or low-grade intraepithelial neoplasia (low-grade dysplasia), while IPCL-IV is frequently representative of non-invasive high-grade intraepithelial neoplasia. IPCL- V1 indicates carcinoma *in situ* (Fig. 5).

In squamous cell carcinoma *in situ*, IPCL analysis demonstrates characteristic changes; dilatation, meandering, caliber change and non-uniformity in the appearance of each IPCL which is closely related to structural atypia of the squamous epithelium [32,34] (Fig. 3 and 5). Based on these findings, IPCL classification was reported in 2001 [35,36] (Fig. 5). When changes in microvascular morphology are

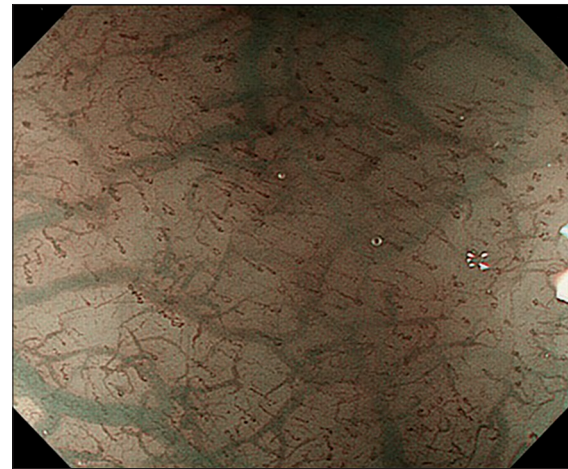


Figure 4 Narrow-band imaging magnification endoscopic view of normal esophageal mucosa

Intrapapillary capillary loop (IPCL) type I

Brown loops are observed at the most superficial layer of the image: IPCLs. Behind them a large green vessel network is observed, the branching vessels. Branching vessel spread on horizontal plane just above the muscularis mucosae, and IPCLs runs perpendicularly from branching vessel network.

discussed, the implication is that the vasculature involved in cancer tissue is abnormal: an assumption strongly supported by microangiographic studies [34,37,38](Fig. 6).

Borderline lesions (IPCL-III and -IV)

Endoscopic diagnosis of tissue atypia in flat mucosal lesions is possible by evaluating the IPCL pattern on magnification NBI. A suspicious lesion is first identified as brownish area with NBI (or a Lugol-voiding area). Once detected in this way, the lesion should be evaluated by magnification endoscopy. If the lesion has less vascular proliferation, the lesion is diagnosed as IPCL-III. IPCL-III is usually regional atrophic mucosa or low grade intraepithelial neoplasia. When vascular proliferation appears increased in the lesion (described in more detail below), it is diagnosed as IPCL-IV. IPCL IV represents high-grade intraepithelial neoplasia.

An IPCL-III lesion must be surveyed every year periodically, while tissue with higher-than-IPCL-IV should be treated by EMR/ESD. Needless to say, the decision to proceed to endoscopic treatment is therefore absolutely dependent on the accurate differentiation of IPCL-III and IPCL-IV. IPCL-IV is characterized by two key factors; increased vessel caliber and elongation of IPCL toward the epithelial surface. Measurement using light microscopy on histopathological specimens demonstrated that the mean vessel caliber in IPCL-IV (5.9 μm) was significantly larger than IPCL-III (4.8 μm) ($P=0.013$). Likewise, the mean distance from the vertex of IPCLs to the basement membrane in IPCL-IV (99.9 μm), is significantly greater than that of IPCL-III (58.8 μm) [39]. Dilatation and elongation of IPCLs are therefore crucial indicators of atypia. It is worth noting that, in this study, the measurement of IPCL caliber was performed using light microscopy on formalin-fixed specimens. Due to the

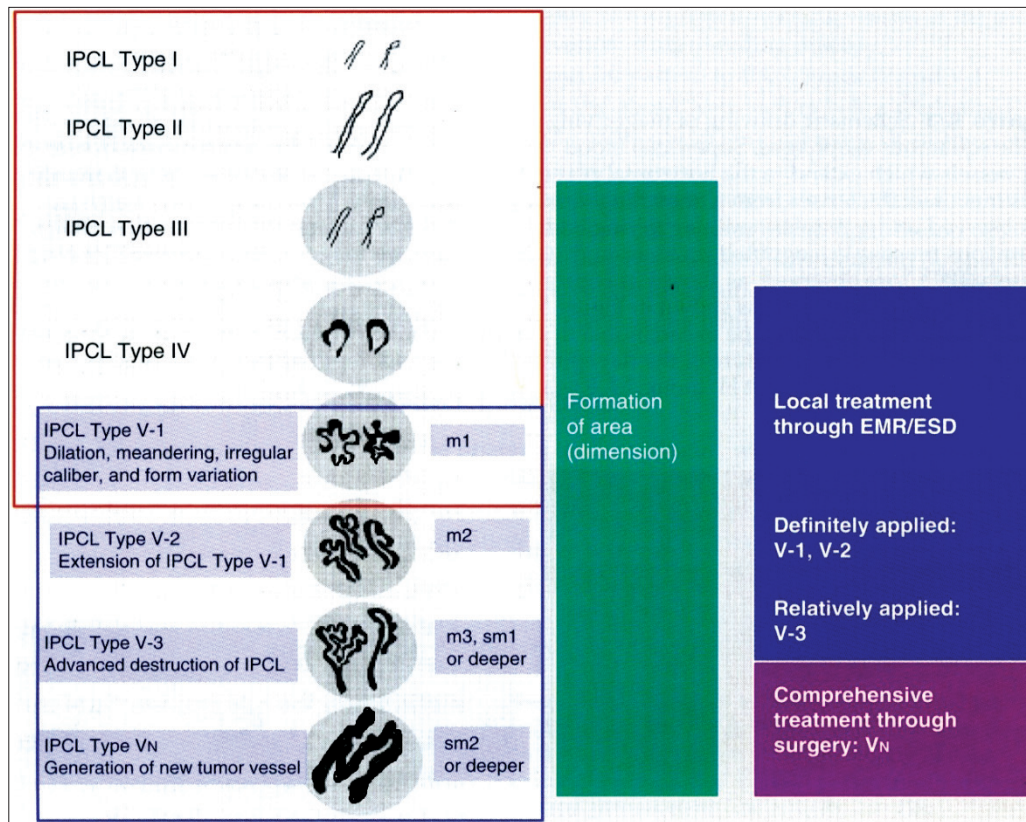


Figure 5 Original intrapapillary capillary loop (IPCL) pattern classification. (Modified from references 35,36)

The IPCL pattern classification includes two sets of diagnostic criteria. IPCL pattern classification from IPCL type I to type V-1 is used for the tissue characterization of flat lesions (red outline). IPCL pattern classification from IPCL type V-1 to type Vn reflects cancer infiltration depth (blue outline). IPCL type III corresponds to borderline lesions which potentially include esophagitis or low-grade intraepithelial neoplasia. IPCL type III should be considered for endoscopic follow up. In IPCL type IV, high-grade intraepithelial neoplasia appears, and then further treatment with endoscopic mucosal resection (EMR) / endoscopic submucosal dissection (ESD) is recommended. EMR/ESD for IPCL types V-1 and V-2 should be also considered as they are definite M1 or M2 lesion with no risk of lymph node metastasis. IPCL type V3 corresponds to an M3 lesion, and diagnostic EMR/ESD should be applied as a “complete biopsy” to decide on a final treatment strategy. IPCL type Vn corresponds to a “new tumor vessel”, often associated with sm2 invasion with significantly increased risk of lymph node metastasis. Surgical treatment should be recommended.

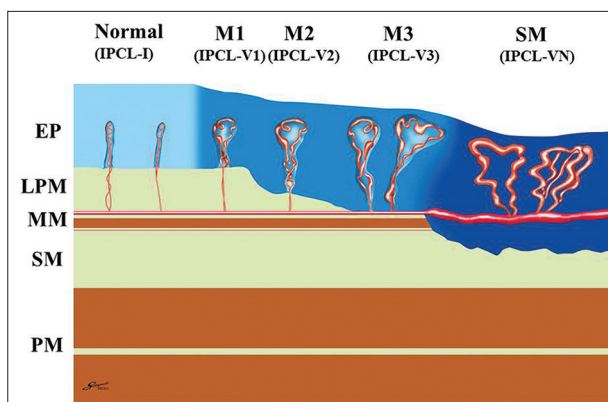


Figure 6 Intrapapillary capillary loop (IPCL) changes followed by cancer infiltration

Vessels involved in cancer tissue demonstrate significant morphological changes according to cancer invasion depth. This illustration is a cross-sectional view of vessels described by the blue outlined box of Fig. 5 (“non-neoplastic” changes are not shown). EP, epithelium; LPM, lamina propria mucosae; MM, muscularis mucosae; SM, submucosa; PM, proper muscle; M1, cancer is limited epithelium; M2, cancer invades LPM but does not reach MM; M3, cancer invasion reaches MM; SM, submucosally invasive cancer

dehydration of tissue inherent in the fixing process, the caliber of vessels *in vivo* would be expected to be much larger. In this way, measurements derived from Microfil injection into surgically resected specimens demonstrate the mean caliber of IPCL I in normal tissue to be 6.9 μm , whilst that of IPCL V (carcinoma *in situ*) was significantly greater (12.9 μm ; $P < 0.0001$) [40].

IPCL-IV indicates a lesion on the borderline to definite carcinoma and during endoscopic examination a number of such areas with incomplete IPCL change, toward carcinoma, may be found. As discussed, this uncertainty is reflected in histologic evaluation, where analysis even by experienced pathologists is subject to intra- and inter-observer variation. For this reason, the Vienna classification advocated the concept of non-invasive high-grade neoplasia (including high-grade dysplasia, non-invasive carcinoma and suspected carcinoma - Vienna category 4). This category improved kappa value of pathologists from 0.04 to 0.75 [19] and can be considered to correspond to IPCL-IV.

Carcinoma *in situ* (IPCL-V1)

In carcinoma *in situ*, or high-grade dysplasia of the squamous epithelium, four characteristic changes of IPCL are found in the brownish area under magnification NBI. These are dilatation, meandering, caliber change, and non-uniformity in the appearance of each IPCL [32,34,37] (Fig. 3, 7).

Ishihara *et al* also reported the significant association in univariate analysis for predictors of squamous high-grade neoplasia, for the factors of brownish epithelium, brownish dots, tortuous IPCL, variety in IPCL shapes and demarcation line [41].

Assessment of invasion depth for superficial squamous cell carcinoma

In standard endoscopy without magnification, the estimation of invasion depth is based on the gross appearance of the lesion (protruberance or excavation) and/or dynamic changes in surface contour with air/gas insufflation. These criteria are evidently insufficient for accurate evaluation of infiltration depth. Magnification endoscopy provides additional, objective information, particularly when dealing with more superficial lesions [41-43]. In the diagnosis of invasion depth by magnification endoscopy, the grade of morphological changes in IPCLs and the appearance of new tumor vessels are key indicators. Destruction of the IPCL structure advances gradually according to cancer invasion from carcinoma *in situ* to SM invasive cancer. Irregular vessels in IPCL-V3, which lose their loop-like configuration, often appear in M2/M3 lesions (Fig. 5). In contrast, IPCL VN (large new tumor vessel) reflects total destruction of the IPCL structure and is characteristic of deeply invasive submucosal carcinoma. The caliber of this tumor vessel is at least three times thicker than IPCL V-3 [36,40].

IPCL-V1 and -V2

IPCL-V1 corresponds to carcinoma *in situ* (M1) with the four characteristic morphological changes: dilatation, meandering, irregular caliber, and non-uniformity between each IPCL [32]. In most cases these morphological changes appear at the vertex of the IPCL. IPCL-V2 adds to the features of IPCL-V1 with an elongation of the vessel in the vertical plane. In IPCL-V1 and -V2, the abnormal IPCLs still run perpendicularly in their original orientation, retaining their basic loop configuration. IPCL-V1 and -V2 relate to M1 and M2 lesions respectively which have no risk of lymph node metastasis and are both best treated by EMR/ESD. Although these changes are also evident in pharyngeal and laryngeal lesions [44-47], in the pharynx the muscularis mucosae is usually lacking, meaning that the evaluation of infiltration depth of squamous carcinoma in this region is not completely equivalent to that of esophageal cancer. This difference requires further clarification.

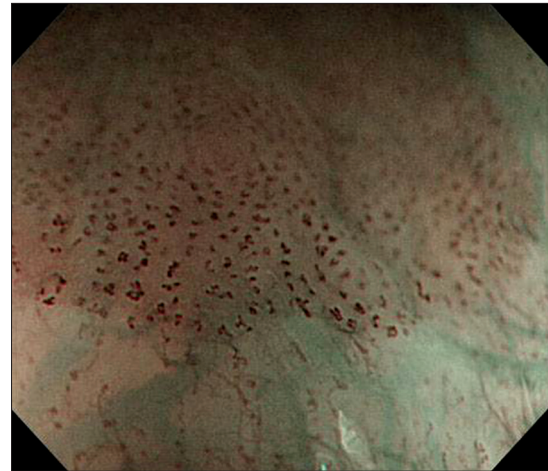


Figure 7 Magnification endoscopy in conjunction with narrow-band imaging enhancement of carcinoma *in situ*

Dilated and irregular shape of intrapapillary capillary loops (IPCLs) is observed at top two thirds of image.

This pattern is called IPCL-V1. IPCL-V1 includes four major characteristic morphological changes of IPCL: dilatation, meandering, irregular caliber, and figure variation.

IPCL-V3

Further changes characterize the progression to IPCLV3. Here, the abnormal vessel loses its loop configuration (Fig. 8) and spreads in a horizontal plane. In some cases, all vessels run on a horizontal plane (IPCL V3a) and others mainly display a perpendicular extension toward deeper mucosal layers (IPCL V3b). In our data, IPCL V3b has relatively higher risk of SM invasion: IPCL-V3a related to M2 60%, M3SM1 40%. IPCL-V3b related to M3SM1 70% and SM2 30% respectively [18].

Arima *et al* reported the utility of interpreting the irregular mucosal surface vascular pattern, particularly focusing on the avascular area (AVA). The AVA reflects invasion, appearing when cancer tissue demonstrates a bulky growth pattern [48]. In our experience, however, the mucosal surface vascular pattern is subject to a great deal of variation and its interpretation is not easily standardized or categorized. We therefore recommend focusing on IPCL morphology and vessel caliber which appear at the margins of the AVA. Vessel caliber can be evaluated more objectively [38,40].

IPCL-VN

The major criterion for differentiating IPCL-V3 and -VN is that of vessel caliber (Fig. 9). IPCL-VN vessels, which appear in massively invasive submucosal carcinoma, have a caliber approximately three times larger than that found in IPCL-V3. IPCL-VN is observed as large green vessels, whereas IPCL-V1, -V2 and -V3 are observed as brown small vessels (Fig. 5). IPCL-VN vessels are only seen when involved in the exposed surface of submucosal cancer tissue [36,40].

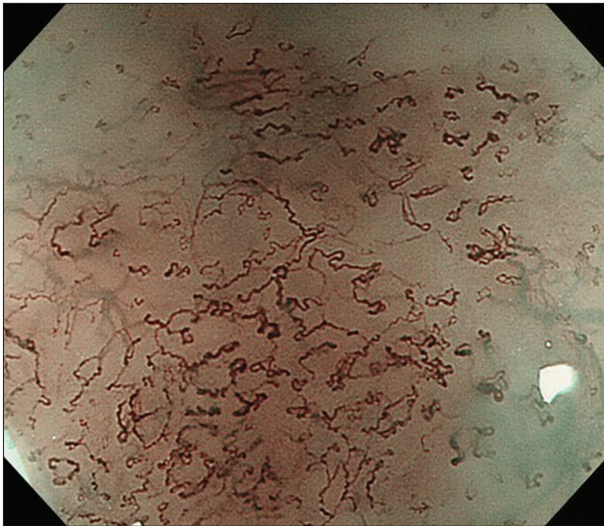


Figure 8 Narrow-band imaging magnification endoscopy image of intramucosal cancer (M3)

Loop-like vessels have already been destroyed in its figure and abnormal vessels are starting to interconnect. Those interconnected vessels spread in horizontal plane. This is typical image of intrapapillary capillary loop (IPCL)-V3. Cancer invasion depth was M3 (muscularis mucosae).

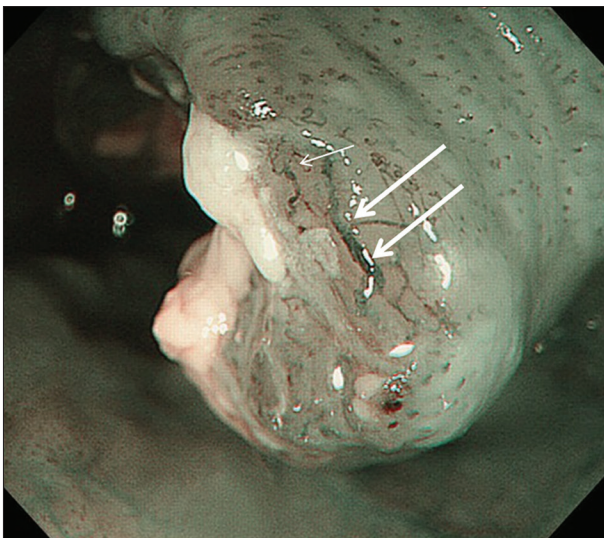

Figure 9 Narrow-band imaging magnification image of "intrapapillary capillary loop (IPCL)-VN" vessel

Large white arrows point to large tumor vessel (IPCL-VN). The striking morphological feature is its extra-large diameter. Note the difference of vessel caliber between IPCL-V3 (small white arrow) and VN (large white arrow).

Evaluation of IPCL classification

We undertook histological correlation of the IPCL classification in 185 superficial lesions. The overall accuracy of IPCL-IV or greater was 80.0% (sensitivity 58.5%, specificity 96%, positive predictive value 92%, negative predictive value 75.4%, and likelihood ratio 14.6) [49]. Goda *et al* reported magnification NBI endoscopy to differentiate intramucosal cancer from submucosal cancer with sensitivity and specificity of 78% and 95% respectively [43]. More studies are required to reinforce these observations.

A novel categorization of the original IPCL classification

The original IPCL classification corresponds to histological grades of atypia which can be categorized into 5 major groups. This five-tier classification is well-matched to histological tissue characterization from normal tissue, inflammation, low-, high-grade dysplasia, and cancer. This type of five-tier classification is a widely accepted model (cf. Papanicolaou, Group and Vienna) [19]. Although the categories of tissue atypia of the squamous epithelium represent a continuous spectrum of change, much of the morphological change has no implication for clinical practice with respect to the diagnosis of cancer (for instance between IPCL I and II).

Any classification system must achieve and maintain clinical relevance and ease of reference for the general user. It is proposed, therefore, that the original categories be combined to form larger (prognostic) groups: Group 1 (non-neoplastic: IPCL I, II), Group 2 (borderline: IPCL III, IV), Group 3 (cancer: IPCL V) (Table 1). This approach has a precedent in another simplified classification [50,51] and this novel categorization of the original IPCL classification is easier to recall and use in terms of relating to the choice of therapy: group 1 lesions require no treatment; group 2 mandates careful follow up or prophylactic therapy; and group 3 definitely demands therapy.

It is then possible to subgroup the three-tier classification to correspond to histological categories for more precise evaluation: Group IA (normal tissue, IPCL I); IB (inflammation, IPCL II); II (low-grade dysplasia, IPCL III, IV); and III (cancer, IPCL V).

Group 3 can then be subdivided into two main subcategories, each according to its characteristic microvascular appearance. Group 3A has both loop-like vessels which correspond to M1 and M2 lesions (IPCL V1/2). In group 3A' the distorted vessel which has already lost loop-like figure (IPCL V3) is usually related both deep mucosal and superficial SM invasion. Group 3B corresponds almost exclusively to submucosal cancer, being characterized by large abnormal vessels (IPCL VN), which are three times the caliber of Group-3A vessels [40].

The detection of IPCL in early squamous cell carcinoma represents a challenge for untrained endoscopists, especially in the western world where the prevalence of squamous cell carcinoma is less than that of Barrett's esophagus-associated esophageal adenocarcinoma. Even though incidence is low, this simplified classification (non-neoplastic, borderline, and cancer) will provide clinicians with an accessible and relevant staging system for pharyngo-esophageal cancer to guide the selection of the most appropriate therapy. Further evaluation of these criteria including inter- and intraobserver variation is expected in the near future.

Concluding remarks

IPCL classification for the squamous epithelium (in the pharynx and esophagus) has been systematically reviewed. Although each category in the classification clearly correlates to histopathological changes in a stepwise fashion, the endoscopic

Table 1 A novel categorization of the original intrapapillary capillary loop (IPCL) classification

Group 1	Non-neoplastic (IPCL-I, -II)
Group 2	Borderline (IPCL-III, -IV)
Group 3	Cancer (IPCL-V)
3A	Intramucosal cancer (IPCL-V1, -V2)
3A'	Deep M or superficial SM cancer (IPCL-V3)
3B	Submucosal cancer (IPCL-VN)

differential diagnosis can be challenging. A simplified re-classification has been presented, for more practical use, to guide future studies.

References

- Endo M, Kawano T. Detection and classification of early squamous cell esophageal cancer. *Dis Esophagus* 1997;**10**:155-158.
- Makuuchi H, Shimada K, Mizutani O, et al. Clinical pathological analysis of surgically resected superficial esophageal carcinoma to determine criteria for deciding on treatment strategy. *Diagn Ther Endosc* 1997;**3**:211-220.
- Makuuchi H. Esophageal endoscopic mucosal resection (EMR) tube. *Surg Laparosc Endosc* 1996;**6**:160-161.
- Inoue H, Endo M. Endoscopic esophageal mucosal resection using a transparent tube. *Surg Endosc* 1990;**4**:198-201.
- Ono H. Early gastric cancer: diagnosis, pathology, treatment techniques and treatment outcomes. *Eur J Gastroenterol Hepatol* 2006;**18**:863-866.
- Oyama T, Tomori A, Hotta K, et al. Endoscopic submucosal dissection of early esophageal cancer. *Clin Gastroenterol Hepatol* 2005;**7**:S67-S70.
- Gondrie JJ, Pouw RE, Sondermeijer CM, et al. Effective treatment of early Barrett's neoplasia with stepwise circumferential and focal ablation using the HALO system. *Endoscopy* 2008;**40**:370-379.
- Endo M, Yoshino K, Kawano T, et al. Clinicopathological analysis of lymph node metastasis in surgically resected superficial cancer of the thoracic esophagus. *Dis Esophagus* 2000;**13**:125-129.
- Luketich JD, Alvelo-Rivera M, Buenaventura PO, et al. Minimally invasive esophagectomy: outcomes in 222 patients. *Ann Surg* 2003;**238**:486-494.
- Ohashi K, Monma K, Yomada Y, et al. Vertical and horizontal growth features of superficial esophageal squamous cell carcinomas: histopathological evaluation of endoscopically resected specimens. *Virchows Arch* 2002;**441**:350-357.
- Lambert R. Endoscopic treatment of esophago-gastric tumors. *Endoscopy* 1994;**26**:28-45.
- Endo M. How can we diagnose the early stage of esophageal cancer? Endoscopic diagnosis. *Endoscopy* 1986;**18**:11-18.
- Dawsey SM, Wang GQ, Weinstein WM, et al. Squamous dysplasia and early esophageal cancer in the Linxian region of China: distinctive endoscopic lesions. *Gastroenterology* 1993;**105**:1333-1340.
- Dawsey SM, Fleischer DE, Wang GQ, et al. Mucosal iodine staining improves endoscopic visualization of squamous dysplasia and squamous cell carcinoma of the esophagus in Linxian, China. *Cancer* 1998;**83**:220-231.
- The Paris endoscopic classification of superficial neoplastic lesions: esophagus, stomach, and colon: November 30 to December 1, 2002. *Gastrointest Endosc* 2003;**58**:S44-S45.
- Inoue H, Rey J, Lightdale C. Lugol chromoendoscopy for esophageal squamous cell cancer. Iodine staining. *Endoscopy* 2001;**33**:75-79.
- Shimizu Y, Omori T, Yokoyama A, et al. Endoscopic diagnosis of early squamous neoplasia of the esophagus with iodine staining: high-grade intraepithelial neoplasia turns pink within a few minutes. *J Gastroenterol Hepatol* 2008;**23**:546-550.
- Inoue H, Kaga M, Sato Y, et al. Magnifying endoscopic diagnosis of tissue atypia and cancer invasion depth in the area of pharyngo-esophageal squamous epithelium by NBI enhanced magnification image: IPCL pattern classification. Advanced digestive endoscopy: Comprehensive atlas of high resolution endoscopy and narrow band imaging. P49-66, edited by Cohen J, Blackwell publishing 2007, USA.
- Hashimoto CL, Iriya K, Baba ER, et al. Lugol's dye spray chromoendoscopy establishes early diagnosis of esophageal cancer in patients with primary head and neck cancer. *Am J Gastroenterol* 2005;**100**:275-282.
- Schlemper RJ, Dawsey SM, Itabashi M, et al. Differences in diagnostic criteria for esophageal squamous cell carcinoma between Japanese and Western pathologists. *Cancer* 2000;**88**:996-1006.
- Gono K, Yamazaki K, Doguchi N, et al. Endoscopic observation of tissue by narrow band illumination. *Opt Rev* 2003;**10**:211-215.
- Yoshida T, Inoue H, Usui S, et al. Narrow-band imaging system with magnifying endoscopy for superficial esophageal lesions. *Gastrointest Endosc* 2004;**59**:288-295.
- Muto M, Minashi K, Yano T, et al. Early detection of superficial squamous cell carcinoma in the head and neck region and esophagus by narrow band imaging: a multicenter randomized controlled trial. *J Clin Oncol* 2010;**28**:1566-1572.
- Yokoyama A, Omori T, Yokoyama T, et al. Risk of metachronous squamous cell carcinoma in the upper aerodigestive tract of Japanese alcoholic men with esophageal squamous cell carcinoma: a long-term endoscopic follow-up study. *Cancer Sci* 2008;**99**:1164-1171.
- Muto M, Nakane m, Hitomi Y, et al. Association between aldehyde dehydrogenase gene polymorphisms and the phenomenon of field cancerization in patients with head and neck cancer. *Carcinogenesis* 2002;**23**:1759-1765.
- Yagi K, Anuga Y, Nakamura A, et al. Regular arrangement of collecting venules (RAC): a characteristic endoscopic feature of Helicobacter pylori-negative normal stomach and its relationship with esophago-gastric adenocarcinoma. *J Gastroenterol* 2005;**40**:443-452.
- Yao K, Oishi T, Matsui T, et al. Novel magnified endoscopic findings of microvascular architecture in intramucosal gastric cancer. *Gastrointest Endosc* 2002;**56**:279-284.
- Kudo S, Kahida H, Tamura T, et al. Colonoscopic diagnosis and management of nonpolypoid early colorectal cancer. *World J Surg* 2000;**24**:1081-1090.
- Tanaka S, Sano Y. Aim to unify the narrow band imaging (NBI) magnifying classification for colorectal tumors: current status in Japan from a summary of the consensus symposium in the 79th annual meeting of the Japan Gastroenterological Endoscopy Society. *Dig Endosc* 2011;**23**:131-139.
- Endo T, Awakawa T, Takahashi H, et al. Classification of Barrett's epithelium by magnifying endoscopy. *Gastrointest Endosc* 2002;**55**:641-647.
- Inoue H, Honda T, Yoshida T, et al. Ultrahigh magnification endoscopy of the normal esophageal mucosa. *Dig Endosc* 1996;**8**:134-138.
- Inoue H, Honda T, Nagai K, et al. Ultrahigh magnification endoscopic observation of carcinoma in situ of the esophagus. *Dig Endosc* 1997;**9**:16-18.
- Hamilton SR, Aaltonen LA, eds. Pathology and genetics of tumors of the digestive system pp11-19, IARC Press, Lyon, France.
- Kumagai Y, Inoue H, Nagai K, et al. Magnifying endoscopy, stereoscopic microscopy, and the microvascular architecture of superficial esophageal carcinoma. *Endoscopy* 2002;**34**:369-375.

35. Inoue H. Magnification endoscopy in the esophagus and stomach. *Dig Endosc* 2001;**13**:40-41.
36. Inoue H. Esophageal cancer: classification of the intrapapillary capillary loop pattern according to Inoue. Grading and staging in gastroenterology. P116 edited by Tytgat GNJ & Tytgat SHAJ, 2009, Thieme, Stuttgart, Germany.
37. Kumagai Y, Toi M, Inoue H, et al. Dynamism of tumour vasculature in the early phase of cancer progression: outcomes from oesophageal cancer research. *Lancet Oncol* 2002;**10**:604-610.
38. Kumagai Y, Toi M, Kawada K, et al. Angiogenesis in superficial esophageal squamous cell carcinoma: magnifying endoscopic observation and molecular analysis. *Dig Endosc* 2010;**22**:259-267.
39. Kaga M, Inoue H, Kudo S, et al. Microvascular architecture of early esophageal neoplasia. *Oncology Reports* 2011;**26**:1063-1067.
40. Santi GE, Inoue H, Ikeda H, et al. Microvascular caliber changes in intramucosal and submucosally invasive esophageal cancer. *Endoscopy* 2013;**45**:585-588.
41. Ishihara R, Inoue T, Uedo N, et al. Significance of each narrow-band imaging finding in diagnosing squamous mucosal high-grade neoplasia of the esophagus. *J Gastroenterol Hepatol* 2010;**25**:1410-1415.
42. Kawahara Y, Uedo N, Fujishiro M, et al. The usefulness of NBI magnification on diagnosis of superficial esophageal squamous cell carcinoma. *Dig Endosc* 2011;**23** (Suppl):79-82.
43. Goda K, Tajiri H, Ikegami M, et al. Magnifying endoscopy with narrow band imaging for predicting the invasion depth of superficial esophageal squamous cell carcinoma. *Dis Esophagus* 2009;**22**:453-460.
44. Takano JH, Yakushiji T, Kamiyama I, et al. Detecting early oral cancer: narrowband imaging system observation of the oral mucosa microvasculature. *Int J Oral Maxillofac Surg* 2010;**39**:208-213.
45. Fujii S, Yamazaki M, Muto M, et al. Microvascular irregularities are associated with composition of squamous epithelial lesions and correlate with subepithelial invasion of superficial-type pharyngeal squamous cell carcinoma. *Histopathology* 2010;**56**:510-522.
46. Yang SW, Lee YS, Chang LC. Use of endoscopy with narrow-band imaging system in evaluating oral leukoplakia. *Head Neck* 2011;**26**:1063-1067.
47. Masaki T, Katada C, Nakayama M, et al. Narrow band imaging in the diagnosis of intraepithelial and invasive laryngeal squamous cell carcinoma: a preliminary report of two cases. *Auris Nasus Larynx* 2009;**36**:712-716.
48. Arima M. Early detection of esophageal neoplasms by magnifying endoscopy. *Gan To Kagaku Ryoho* 2011;**38**:1417-1420.
49. Inoue H, Ishigaki T, Misawa M, et al. NBI magnifying endoscopic diagnosis for superficial esophageal cancer. *Stomach and Intestine* 2011;**46**:664-675 (English abstract).
50. Kiesslich R, Burg J, Vieth M, et al. Confocal laser endoscopy for diagnosing intraepithelial neoplasias and colorectal cancer in vivo. *Gastroenterology* 2004;**127**:706-713.
51. Kudo SE, Wakamura K, Ikehara N, et al. Diagnosis of colorectal lesions with a novel endocytoscopic classification-a pilot study. *Endoscopy* 2011;**43**:869-875.