

Late-Onset Massive Epistaxis due to a Ruptured Traumatic Internal Carotid Artery Aneurysm: A Case Report

Nobuhiko Arai, Akiyoshi Nakamura, Masanao Tabuse, and Hiromichi Miyazaki

A traumatic internal carotid artery (ICA) aneurysm is rare and difficult to treat. Trapping of ICA is commonly performed owing to the difficulty of directly approaching ICA aneurysms. Recently, coiling the aneurysm itself was recommended if possible. However, it is controversial which of methods are best to completely treat aneurysm. We present the case of a 74-year-old man, who had experienced a head injury 8 years previously, with recurrent severe epistaxis. An ICA aneurysm was detected on computed tomography. The trapping and bypass was planned. However, sudden epistaxis occurred, we performed trapping to stop the bleeding and save his life. After the operation, no right ICA or aneurysm was detected. However, severe epistaxis recurred two months after the operation. In the second operation, a ligation of the common -/- external carotid artery and a severance of an ICA portion between the ophthalmic artery and the aneurysm were insufficient to stop the bleeding. This case indicates ICA trapping, even if a trapping portion is below an ophthalmic artery, is insufficient to treat an ICA aneurysm. ICA aneurysms should be suspected when a patient present with recurrent -/- massive epistaxis, who has a head injury history, even if it is far past.

Keywords: internal carotid artery aneurysm; massive epistaxis; collateral artery; trapping; head trauma

Introduction

Intracranial internal carotid artery (ICA) aneurysms manifesting as epistaxis are rare and difficult to treat. Recently endovascular therapy has been indicated in an ICA aneurysm.¹⁻³⁾ In the meantime an open surgery; complete trapping of the patent artery and bypass, has been performed conventionally. It is controversial which of treatment method is better to treat an ICA aneurysm.

Case Presentation

A 74-year-old man with massive epistaxis was admitted to our hospital. To examine the vessels, computed tomography (CT) was performed and detected an ICA aneurysm (Fig. 1). The patient was disoriented; his Glasgow Coma Scale (GCS) score was 14 (G4V4M6), and moderate left hemiparesis was recognized. His medical history included

right ICA stenosis and a serious head injury 8 years previously that had resulted in subarachnoid hemorrhage and bilateral frontal lobe contusion. An aneurysm was not found at that time. The patient was in severe shock status in the emergency room. Due to critically low blood pressure and additionally ICA stenosis, the patient had a sporadic cerebral infarction in the right middle cerebral artery and anterior cerebral artery areas. Therefore, he showed moderate left hemiparesis at the initial examination. The ICA stenosis was detected 2 years before and existed in cervical portion. The stenotic rate was 80% [European Carotid Surgery Trial (ECST)]. There was not an aneurysm at that time (Fig. 2). To detect the bleeding points we performed angiography. The angiography revealed 20 mm aneurysm which had poorly defined neck (Fig. 3). Matas and Allcock test was performed and showed cross flow (no image was recorded). We planned to perform ICA trapping and bypass if necessary. Although an endovascular therapy was considered, we chose the open surgery because of an ICA stenosis existence and our substantial experience of open surgery. Sudden massive epistaxis occurred after admission. As rupture of the ICA aneurysm was suspected, emergency operation was performed. The cervical portion of the ICA was ligated, and the distal portion from the ophthalmic artery of the ICA was clipped to trap the ICA (Fig. 4A). After that, epistaxis stopped. The right cerebrum was severely damaged owing to the frontal contusion and cerebral infarction induced by the ICA stenosis and two times shock episodes. We did not perform the bypass procedure. Postoperative images showed no right ICA or the aneurysm (Fig. 5). However, epistaxis recurred again 2 months later. Recurrence of blood flow into the aneurysm via the ophthalmic artery was suspected. We considered to perform angiography for checking flow via ophthalmic artery. However, the patient's condition was severely critical and emergent. We chose to stop the bleeding instantaneously and rushed to the operation room. In the second surgery, the common -/- external carotid artery were ligated first. And the ICA portion between the ophthalmic artery and the aneurysm was severed. However epistaxis did not stop. Therefore, we decided to approach the aneurysm directly. We performed anterior clinoidectomy and open the cavernous sinus. The neck was located at the extradural site. Finally, a poorly defined neck was found, which highly showed a traumatic aneurysm (Fig. 6). The neck was coagulated and cut. We got the complete cease of the epistaxis. The epistaxis never recurred after the second surgery. The patient was discharged from the hospital on the

Department of Neurological Surgery, Hiratsuka City Hospital, Hiratsuka, Kanagawa, Japan

Received: May 10, 2016; Accepted: July 13, 2016

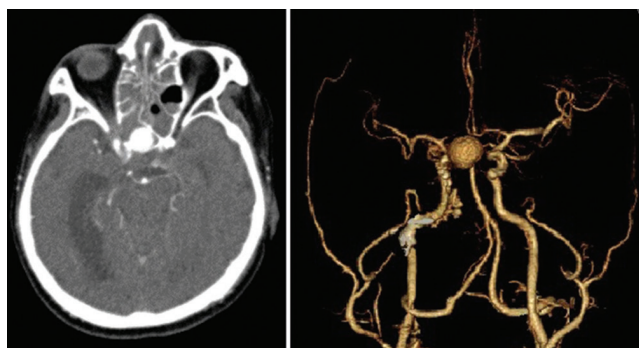


Fig. 1 Computed tomography showing an internal artery aneurysm in the sphenoid sinus.

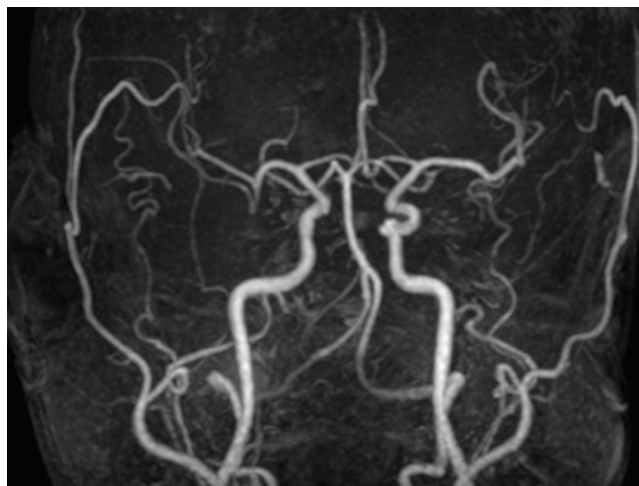


Fig. 2 Magnetic resonance angiography showing no aneurysm at any portions of arteries.

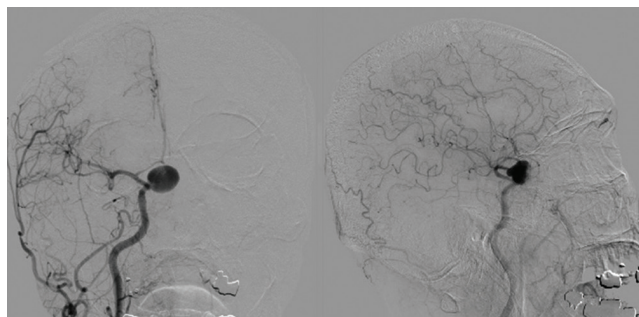


Fig. 3 Angiography showing a right internal artery aneurysm which shows a poorly defined neck.

100th postoperative day, with a modified Rankin scale score of 4 and GCS score of 12 (E3V4M5).

Discussion

We noted two important clinical issues during the treatment of this case. First, trapping of the ICA, i.e., ligating the cervical portion of the ICA and severance of the intracranial ICA below the ophthalmic artery, is an insufficient treatment for a ruptured ICA aneurysm. Second, a traumatic ICA

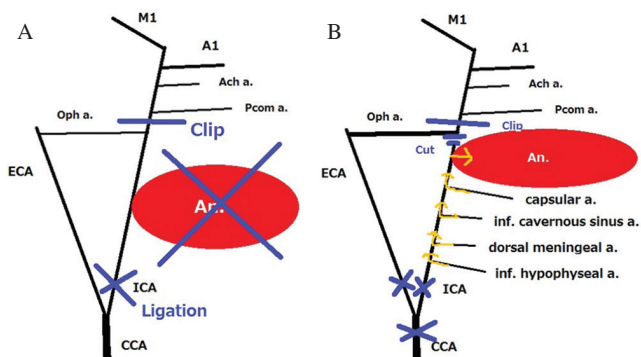


Fig. 4 (A) Diagram showing the arteries in the head and neck after the first operation was performed. (B) Diagram after the second surgery in which the many presumed collateral arteries are depicted.

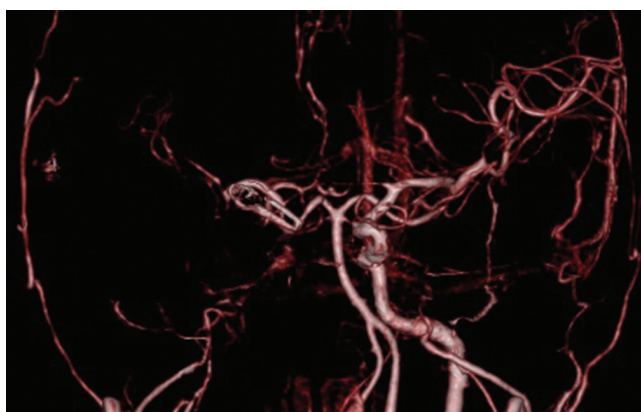


Fig. 5 The computed tomography after the first operation showing no right internal carotid artery and aneurysm.

aneurysm should be included as a possible differential diagnosis for a case of severe epistaxis even when head injury had occurred a long time previously.

Trapping of the ICA, i.e., ligating the cervical portion of the ICA and severance of the intracranial ICA below the ophthalmic artery, is probably an insufficient treatment. An ICA aneurysm below the dural ring is very hard to treat via clipping, and even approaching its neck directly is difficult owing to the cavernous sinus. Trapping and high flow bypass are conventionally indicated in cases like ours. On the contrary endovascular therapy has been introduced recently in this area.¹⁻³ Endovascular embolization or flow-diverter is considered to be one option. However, in cases of traumatic aneurysms, the aneurysm is typically a pseudoaneurysm, which has a thin and fragile vessel wall. A pseudoaneurysm ruptures more easily than a true aneurysm on stimulus with an intravascular device such as a coil or guidewire. Major rupture of an aneurysm inevitably induces parent artery occlusion (PAO). If PAO is performed, the incidence of ischemic complications has been reported to be as high as 41% without bypass.⁴ Therefore PAO sometimes require bypass; open surgery. In our case, epistaxis occurred again 2 months after the trapping of the ICA. It was previously reported that clipping of the proximal portion of ICA from the ophthalmic artery is

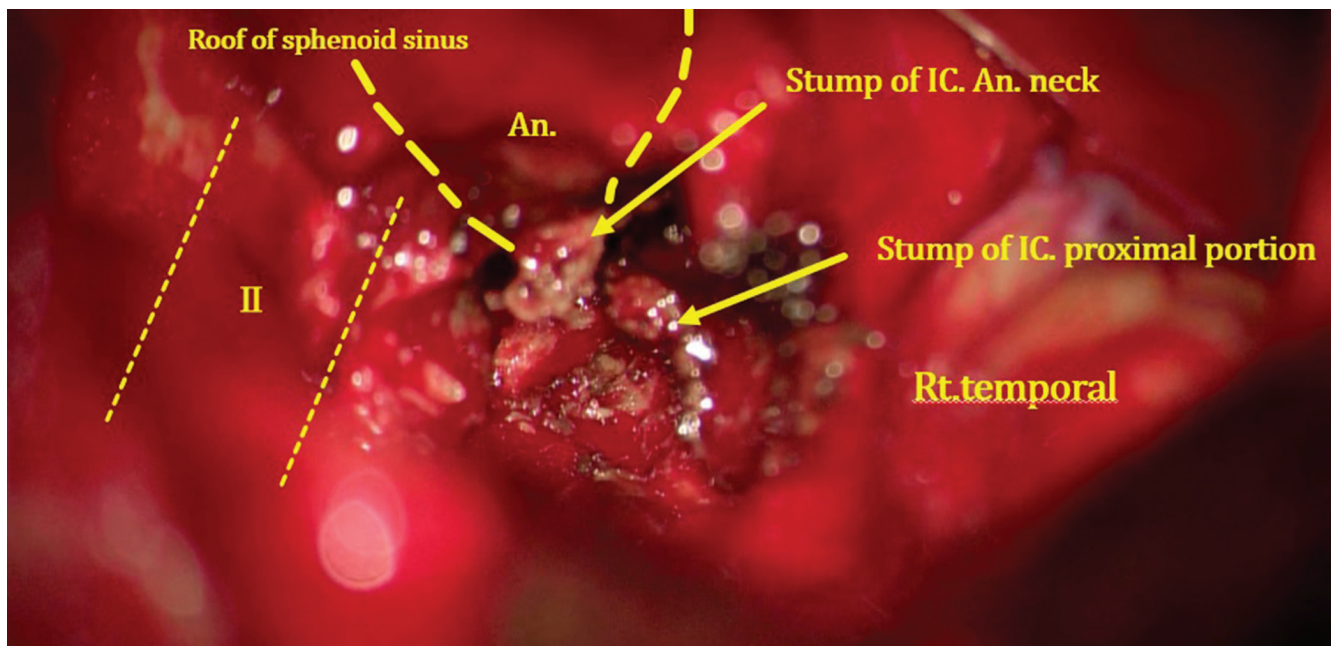


Fig. 6 The operative view showed the stumps of IC and aneurysm which were severed. The neck was poorly defined.

necessary to gain complete loss of backflow via an ophthalmic artery.⁵⁾ However, epistaxis did not stop even after severance of ICA below the ophthalmic artery. This fact is probably induced by collateral vessels from the contralateral ICA or ECA. These vessels; capsular artery, inferior lateral trunk, dorsal meningeal artery, and superior/inferior hypophysial artery (Fig. 4B), were not shown in the angiography. Their vessels were investigated by several articles.^{6,7)} Maybe after the PAO of ICA, remaining flow had grown up those collateral arteries. Some researchers have shown ICA stenosis causes significantly increased collateral flow.^{8,9)} The patient had ICA stenosis and this may contribute the increase of these collateral vessels and caused angiogenesis. To the best of our knowledge, no similar case reports of bleeding via the collateral flow to the ICA shown in Fig. 4B but not the ophthalmic artery were reported. Therefore trapping, especially ligating only two portions of ICA, is probably insufficient to avoid collateral flow and reentry to an aneurysm.

Second, when a patient presents with severe epistaxis and has a notable history of head injury, an intracranial ICA aneurysm should be suspected even if the head injury occurred in the distant past. The incidence of bleeding from intracranial ICA aneurysms is reported to be low; 1.3%.¹⁰⁾ However, traumatic ICA aneurysms results in massive and even fatal epistaxis with an associated 30–50% mortality rate if it occurs.¹¹⁾ Most traumatic aneurysms may rupture within a short period after head injury. About 90% of patients with ruptured ICA aneurysm presented with epistaxis within 3 weeks–6 months after head injury^{12,13)} However, several massive epistaxis has been reported 10 and 30 years after a head injury.^{14,15)} In our case the aneurysm was not examined pathologically. However, considering post severe head injury and surgical view which showed poorly defined neck of the aneurysm, this aneurysm was thought to be traumatic. Additionally, the notable point in

our case is there was no aneurysm when ICA stenosis was detected 2 years before. We speculate because the lesion had only intimal disruption (adventitial integrity was preserved) at first, there had been no aneurysm for at least 6 years. Although no history of severe head injury had been reported for the past 2 years, the patient was a heavy drinker and it is possible that he might hit his head several times and would not visit the hospital or tell us such head injuries, which led to more disruption of injured ICA intimal. Moreover the patient was diagnosed as severe hypertension lately, which might cause the expansion of adventitia; pseudoaneurysm formation.

An ICA aneurysm should be considered when severe epistaxis is observed and a history of head injury is noted, despite occurring many years previously. The trapping of ICA, i.e., ligating the cervical portion of the ICA and severance of the intracranial ICA below the ophthalmic artery, is insufficient to treat an ICA aneurysm because of the collateral vessels. Additionally, examining a patient with massive epistaxis and a head trauma history checking for an ICA aneurysm is important, even if the head injury occurred many years previously.

Conflict of Interest Disclosure

All authors declare no conflict of interest.

References

- 1) Giorgianni A, Pellegrino C, Minotto R, Mercuri A, Baruzzi F, Cantoni A, Cardim LN, Valvassori L: Flow-diverter stenting in post-traumatic pseudoaneurysm of cavernous internal carotid artery with epistaxis. *Interv Neuroradiol* 21: 325–328, 2015
- 2) Tsai YH, Wong HF, Weng HH, Chen YL: Stent-graft treatment of traumatic carotid artery dissecting pseudoaneurysm. *Neuroradiology* 52: 1011–1016, 2010
- 3) Zhang CW, Xie XD, You C, Mao BY, Wang CH, He M, Sun H: Endovascular treatment of traumatic pseudoaneurysm presenting as intracranial epistaxis. *Korean J Radiol* 11: 603–611, 2010

- 4) Regli L, Piepgras DG, Hansen KK. Late patency of long saphenous vein bypass grafts to the anterior and posterior cerebral circulation. *J Neurosurg* 83: 806–811, 1995
- 5) Handa H, Handa J, Iwayama K, Teraura T, Kikuchi H. Traumatic aneurysm of the internal carotid artery, with reference to cases presenting massive epistaxis and its therapy [in Japanese] *No To Shinkei* 19: 1063–1072, 1967
- 6) Tran-Dinh H. Cavernous branches of the internal carotid artery: anatomy and nomenclature. *Neurosurgery* 20: 205–210, 1987
- 7) Jittapiromsak P, Sabuncuoglu H, Deshmukh P, McDougall CG, Spetzler RF, Preul MC. Anatomical relationships of intracavernous internal carotid artery to intracavernous neural structures. *Skull Base* 20: 327–336, 2010
- 8) Hartkamp MJ, van Der Grond J, van Everdingen KJ, Hillen B, Mali WP. Circle of Willis collateral flow investigated by magnetic resonance angiography *Stroke* 30: 2671–2678, 1999
- 9) Drakou AA, Koutsiaris AG, Tachmitzi SV, Roussas N, Tsironi E, Giannoukas AD. The importance of ophthalmic artery hemodynamics in patients with atheromatous carotid artery disease. *Int Angiol* 30: 547–554, 2011
- 10) Kupersmith MJ, Hurst R, Berenstein A, Choi IS, Jafar J, Ransohoff J. The benign course of cavernous carotid artery aneurysms. *J Neurosurg* 77: 690–693, 1992
- 11) Celil G, Engin D, Orhan G, Barbaros C, Hakan K, Adil E. Intractable epistaxis related to cavernous carotid artery pseudoaneurysm: treatment of a case with covered stent. *Auris Nasus Larynx* 31: 275–278, 2004
- 12) Chambers EF, Rosenbaum AE, Normad D, Newton TH. Traumatic aneurysms of cavernous internal carotid artery with secondary epistaxis. *AJNR Am J Neuroradiol* 2: 405–409, 1981
- 13) Ildan F, Uzuneyüpoğlu Z, Boyar B, Bağdatoğlu H, Cetinalp E, Karadayi A. Traumatic giant aneurysm of the intracavernous internal carotid artery causing fatal epistaxis: case report. *J Trauma* 36: 565–567, 1994
- 14) Simpson RK, Harper RL, Bryan RN. Emergency balloon occlusion for massive epistaxis due to traumatic carotid and cavernous aneurysm. *J Neurosurg* 68: 142–144, 1988
- 15) Steinmetz H, Heiss E, Mironov A. Traumatic giant aneurysms of the intracranial carotid artery. *Surg Neurol* 30: 305–310, 1998.

Corresponding author:

Nobuhiko Arai, Department of Neurological Surgery, Hiratsuka City Hospital, Hiratsuka, Kanagawa, Japan.

✉ dobu@i.softbank.jp