

Jeroen de Filette  
Danielle Hasaerts, MD  
Sara Seneca, PhD  
Alexander Gheldof, PhD  
Katrien Stouffs, PhD  
Kathelijn Keymolen, MD  
Brigitte Velkeniers, MD,  
PhD

*Neurol Genet*  
2016;2:e42; doi: 10.1212/  
NXG.0000000000000042

## POLYNEUROPATHY IN A YOUNG BELGIAN PATIENT: A NOVEL HETEROZYGOUS MUTATION IN THE *WNK1/HSN2* GENE

### OPEN

Hereditary sensory autonomic neuropathy (HSAN) is a rare condition, predominantly affecting the peripheral sensory nervous system, although variable motor and dysautonomic symptoms can be present. At least 7 clinical types of HSAN have been described, and different genetic mutations have been identified for each of these. HSAN IIA (OMIM #201300) is characterized by loss of pain and loss of temperature and touch sensation, with onset usually before the first decade. The mode of inheritance is autosomal recessive.<sup>1</sup> The causative gene, *WNK1/HSN2*, is located on locus 12p13.33 and is an isoform of the *WNK1* (lysine deficient protein kinase 1) gene, which contains the *HSN2* exon.<sup>2,3</sup> We describe 2 new heterozygous mutations in the *WNK1/HSN2* gene in a Belgian patient with early-onset sensory polyneuropathy.

**Case report.** The patient is an 18-year-old male with recurrent acral infections due to an inherited sensory neuropathy of unknown cause. No other family members are known to be affected. His parents are not consanguineous (figure, A). At age 3, the patient had frequent ecchymoses of the toes, according to his mother as if “he did not feel his shoes were too small.” At age 6, he sustained a nonpainful traumatic lower arm fracture. At age 10, difficulties with attention and concentration led to the diagnosis of attention deficit disorder with hyperactivity. During this workup, the assessing pediatric neurologist ordered further testing. Nerve conduction study showed absent sensory action potentials in both upper and lower limbs. Motor nerve conduction and electromyography results were within normal limits. Routine blood analysis results were normal. Sural nerve biopsy was not performed. Over the following years he developed recurrent digital osteomyelitis and tenosynovitis of digits III and IV of his left hand, followed by amputations of several distal and medial phalanges (figure, B). He currently complains of episodic postural hypotension, gastroesophageal reflux, and hyperhidrosis of the hands with diffuse purple discoloration when exposed to cold.

Physical examination confirmed the absence of nociception, thermoception, and touch sensation,

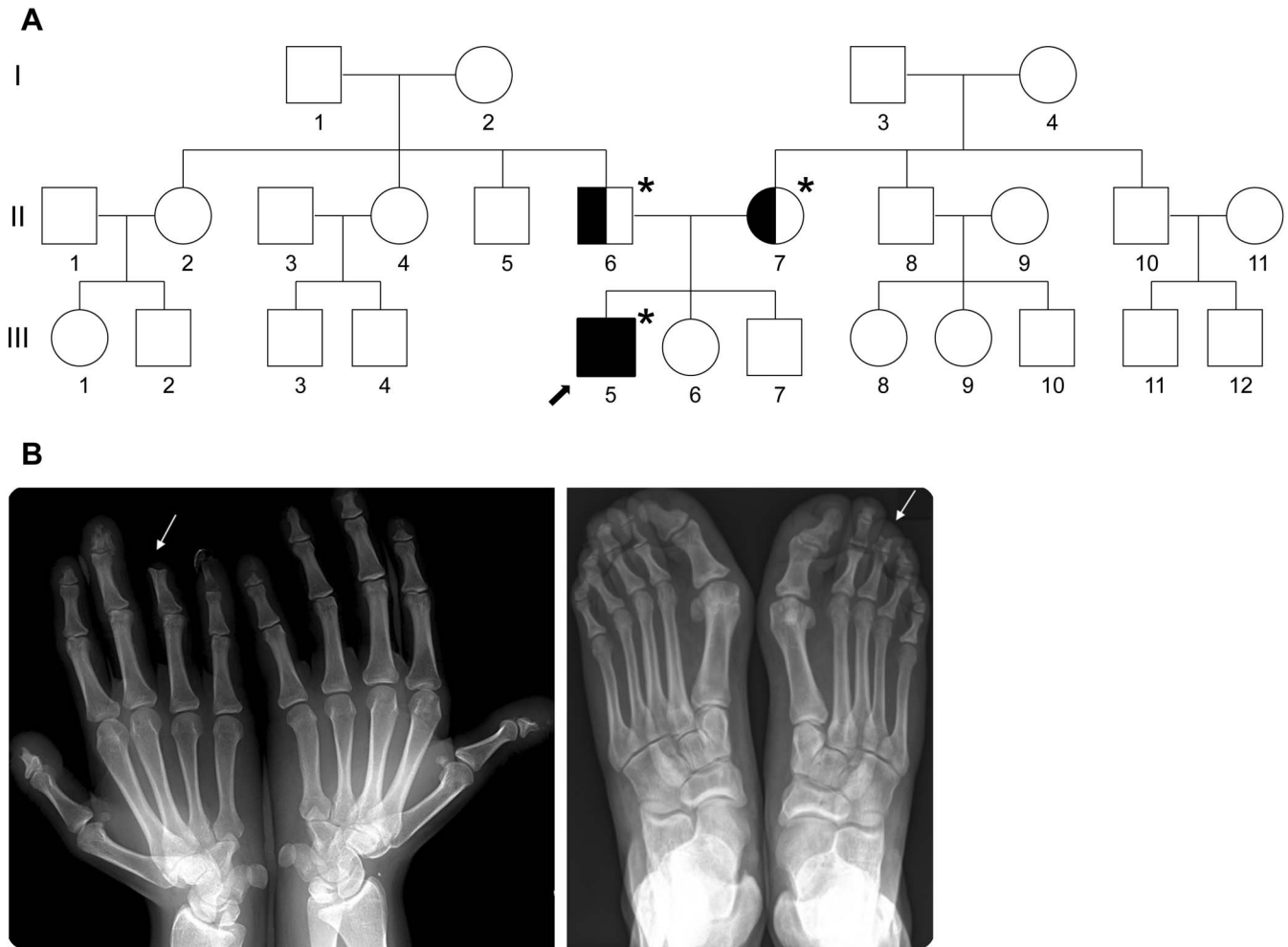
distally from both wrists and ankles (“glove and sock”) with decreased sensation from both elbows and knees downward. The vibration sense was intact. No muscle weakness was observed. The deep tendon reflexes were not present. His gait was normal. His distal extremities showed no signs of ulcerations or arthropathy. His blood pressure was 130/90 mm Hg.

Informed consent was obtained from the patient and his parents prior to blood sample analysis. DNA was extracted from peripheral blood lymphocytes using standard methods. Sanger sequencing of the *HSN2* exon of the *WNK1/HSN2* gene (NM\_213655.2–*HSN2*) unveiled a heterozygous variant with a single base modification c.718A>T resulting in a predicted new stop codon p.(Lys240\*), and a deletion of 5 nucleotides c.1192\_1196del producing a predicted amino acid change from phenylalanine to leucine on position 398, leading to a frameshift and a read-through with a 9 amino acid longer open reading frame p.(Phe398Leufs\*46). Both asymptomatic parents were found to be heterozygous carriers. The mother is a carrier of the c.718A>T mutation; the father is a carrier of the c.1192\_1196del mutation.

**Discussion.** We describe 2 new genetic mutations in the *WNK1/HSN2* gene in a patient with early-onset sensory polyneuropathy. Prior to analysis, the phenotype of this patient was thoroughly investigated and compared with the known clinical features of the different HSAN types. An evaluation of HSAN IIA was preferred given the age at onset of symptoms in early childhood, an evocative sensory deficit with “glove and sock” distribution, unimpaired vibration sense, and absent deep tendon reflexes.<sup>1,4</sup> Dysfunction of the autonomic nervous system is possible in HSAN II<sup>1,4</sup> and could explain the postural hypotension, gastroesophageal reflux, and hyperhidrosis with reactivity to cold. Excessive hand sweating also occurred in a French patient with a heterozygous mutation in the *WNK1/HSN2* gene and exon 6 of the *WNK1* gene.<sup>3</sup>

Genetic analysis is essential for definitive diagnosis and counseling and should be guided by careful clinical evaluation. Testing of unaffected relatives and prenatal counseling (if appropriate) could be

**Figure** Clinical and genetic features of a Belgian patient with HSAN IIA



(A) Three-generation pedigree of a family with HSAN IIA in the index patient (arrow). Black filled symbol = affected patient; half-filled symbol = heterozygote carrier; open symbol = unaffected individual. Asterisks indicate genetically analyzed individuals. (B) Plain radiography of both hands and feet, demonstrating amputations of distal and medial phalanges (digitus IV left hand and digitus III right foot, white arrows) and bone resorption in several phalanges.

proposed if wished for, in order to prevent new cases, which has already been successful in HSAN III.<sup>5</sup>

Treatment is challenging. The sensory deficit causes neuropathic ulcerations, osteomyelitis, and arthropathy leading to progressive amputations. The consequences in this patient were relatively mild, although progressive mutilations are likely to be expected. Preventive care, early detection, and treatment of infection are crucial.<sup>1,4</sup>

*From the Vrije Universiteit Brussel (J.d.F.); Pediatric Neurology Unit (D.H.), Department of Pediatrics, Universitair Ziekenhuis Brussel; Centre for Medical Genetics/Research Centre Reproduction and Genetics (S.S., A.G., K.S., K.K.), Universitair Ziekenhuis Brussel, Vrije Universiteit Brussel; and Department of Endocrinology and General Internal Medicine (B.V.), Universitair Ziekenhuis Brussel, Vrije Universiteit Brussel, Brussels, Belgium.*

*Author contributions: Jeroen de Filette: drafting/revising the manuscript for content, study concept, analysis, and interpretation of data. Danielle Hasaerts: revising the manuscript for content, study concept. Sara Seneca: drafting/revising the manuscript for content, analysis, and interpretation of data. Alexander Gheldof: drafting/revising the*

*manuscript for content, analysis, and interpretation of data. Katrien Stouffs: drafting/revising the manuscript for content, analysis, and interpretation of data. Kathelijnn Keymolen: revising the manuscript for content, analysis, and interpretation of data. Brigitte Velkeniers: drafting/revising the manuscript for content, study concept, study supervision.*

*Acknowledgment: The authors thank the patient and his family for their participation and acknowledge the contribution of the Academisch Medisch Centrum—Laboratorium voor Neurogenetica, to the genetic analyses. They also thank Dr. J. Belkhouribchia for his encouraging advice.*

*Study funding: No sponsorship or government funding was obtained for this study. Genetic analysis was funded by Universitair Ziekenhuis Brussel.*

*Disclosure: The authors report no disclosures. Go to Neurology.org/ng for full disclosures. The Article Processing Charge was paid by the authors.*

*This is an open access article distributed under the terms of the Creative Commons Attribution-NonCommercial-NoDerivatives License 4.0 (CC BY-NC-ND), which permits downloading and sharing the work provided it is properly cited. The work cannot be changed in any way or used commercially.*

*Received October 1, 2015. Accepted in final form November 20, 2015.*

*Correspondence to Dr. de Filette: jdefilet@vub.ac.be*

1. Axelrod FB, Gold-von Simson G. Hereditary sensory and autonomic neuropathies: types II, III, and IV. *Orphanet J Rare Dis* 2007;2:39.
2. Lafrenière RG, MacDonald ML, Dubé MP, et al. Identification of a novel gene (*HSN2*) causing hereditary sensory and autonomic neuropathy type II through the Study of Canadian Genetic Isolates. *Am J Hum Genet* 2004;74:1064–1073.
3. Shekarabi M, Girard N, Rivière JB, et al. Mutations in the nervous system–specific *HSN2* exon of *WNK1* cause hereditary sensory neuropathy type II. *J Clin Invest* 2008;118:2496–2505.
4. Rotthier A, Baets J, Timmerman V, Janssens K. Mechanisms of disease in hereditary sensory and autonomic neuropathies. *Nat Rev Neurol* 2012;8:73–85.
5. Couzin-Frankel J. Chasing a disease to the vanishing point. *Science* 2010;328:298–300.