

INTERACTIVE WORKSHOP 5: PANCREAS

Saturday 6 October 2012, 11:30–13:00

The incidental cystic pancreas mass: a practical approach

**Richard M. Gore, Daniel R. Wenzke, Kiran H. Thakrar, Geraldine M. Newmark,
Uday K. Mehta, Jonathan W. Berlin**

*Department of Radiology, North Shore University Health System, University of Chicago,
Pritzker School of Medicine, Evanston, IL, USA*

*Corresponding address: Richard M. Gore, MD, Department of Radiology, Evanston Hospital, 2650 Ridge Ave,
Evanston, IL 60201, USA.*

Email: rgore@uchicago.edu

Abstract

Technical advances in cross-sectional imaging have led to the discovery of incidental cystic pancreatic lesions in the oncology and non-oncology population that in the past remained undetected. These lesions have created a diagnostic and management dilemma for both clinicians and radiologists: should these lesions be ignored, watched, aspirated, or removed? In this review, recommendations concerning the assessment of the more common pancreatic cystic incidental lesions are presented.

Keywords: *Incidentaloma; IPMN; pancreatic serous cystadenoma; pancreatic mucinous cystadenoma; pancreatic mucinous cystadenocarcinoma.*

The problem

The discovery of small cystic pancreatic incidentalomas is a daily occurrence in the practice of abdominal radiology due to technical advances in multidetector computed tomography (MDCT), magnetic resonance imaging (MRI), and ultrasonography. These previously undetected cystic lesions are found on 1.2–2.6% of abdominal MDCT examinations and 13.5–19.9% of abdominal MRI studies^[1–4]. Pancreatic incidentalomas are unexpected, asymptomatic abnormalities that are discovered serendipitously while screening for other diseases (Fig. 1) or actively searching for other pathology. These lesions have created a management dilemma for both clinicians and radiologists: should these small cystic structures be ignored or followed up? How and when should they be followed up? When should they be aspirated or removed^[5,6]? Strategies for optimizing patient management of these lesions are only beginning to emerge^[7–9]. Since cystic pancreatic lesions are seen in up to 25% of autopsies^[10], their discovery will become increasingly

common as the population ages and imaging technology improves.

The odds

In the past, most pancreatic cysts were believed to be pseudocysts. Improvements in cross-sectional imaging techniques over the past 15 years, however, have shown that serous cystadenoma (SC), mucinous cystic neoplasm (MCN), and intraductal papillary mucinous neoplasm (IPMN) now account for most of the pancreatic cysts found in asymptomatic individuals^[11,12]. As a rule, cystic pancreatic tumors are most often benign or low-grade indolent neoplasms. However, if the cyst is mucinous, it does have a real, albeit small, malignant potential. In a review of 166 cases that went to surgery, the most common type of tumors were: IPMN (46%), MCN (30%), and SC (23%)^[13]. These data are from a surgical series and probably do not reflect the true distribution of cystic pancreatic incidentalomas in the general population as benign appearing, small lesions typically are not surgically resected.

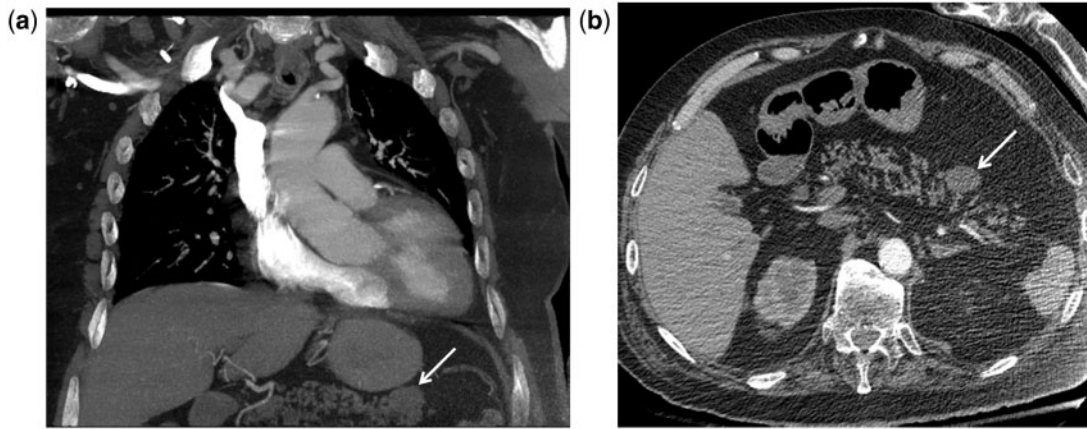


Figure 1 Cystic pancreatic incidentaloma on an MDCT pulmonary embolism study of an 84-year-old man with shortness of breath. Coronal (a) and axial (b) images show an asymptomatic 1.8-cm cystic lesion (arrow) along the anterior aspect of the pancreatic tail. In view of the patient's age and significant cardiac and pulmonary co-morbidities, it was elected not to follow-up this probably side-branch IPMN.

Patient demographics are quite useful in suggesting the likely cause of the cystic pancreatic incidentaloma. MCN is found almost exclusively in women of childbearing age in the 4th and 5th decade and has been called the mother tumor. SC occurs predominantly in women with a mean and median age of 68 years and has been called the grandmother tumor. IPMN afflicts an older population, most often in the seventh and eight decades and shows a slight male predominance and has been called the grandfather tumor^[14–18].

The foregoing discussion does not apply to high-risk individuals in whom asymptomatic pancreatic lesions are found on pancreatic screening studies in 14% of patients younger than 50 years of age, 34% of patients aged 50–59 years, and 53% of individuals between 60 and 69 years of age^[19]. Risk factors for the development of pancreatic carcinoma include: pancreatic cancer in a first-degree relative, Peutz-Jeghers syndrome, hereditary pancreatitis, familial atypical multiple mole melanoma, hereditary nonpolyposis colorectal cancer (Lynch syndrome), and BRCA 1 and BRCA 2 germline mutations^[20]. Accordingly, a higher index of suspicion is appropriate for these high-risk individuals.

The players

Pancreatic pseudocysts

Although pancreatic pseudocysts represent the majority of cystic pancreatic lesions in patients with a history of acute or chronic pancreatitis or risk factors for these diseases, they represent a minority of incidentally found lesions in the general population^[15]. The cyst wall is formed by inflammatory and fibrous tissue devoid of an epithelial cell lining. Usually, the preceding classic history and radiological features help in diagnosing a pseudocyst. On computed tomography (CT), pseudocysts are round or oval and have a thin (1–2 mm) enhancing

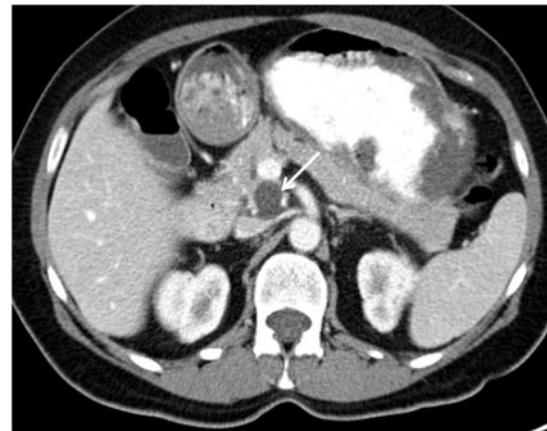

Figure 2 Cystic pancreatic incidentaloma on an MDCT scan performed to rule out appendicitis in a 45-year-old woman. There is a 1.8-cm cystic lesion with a density of 9 HU in the uncinus process of the pancreas. This probable mucinous cystadenoma has remained stable for 4 years. The patient has declined endoscopic ultrasonography and surgery.

fibrous capsule. They contain fluid that has a density <20 HU; higher attenuation values of 40–60 HU indicate intracystic hemorrhage. These vary significantly in size and may communicate with the pancreatic duct. On MRI they appear as loculated fluid signal intensity collections that may communicate with the pancreatic duct. When radiological features are uncharacteristic, and when there is no history of clinical pancreatitis, the diagnosis becomes more problematic^[21].

Mucinous cystic tumors

MCNs are characterized by large multilocular cysts lined by mucin-producing columnar epithelium, resting on a

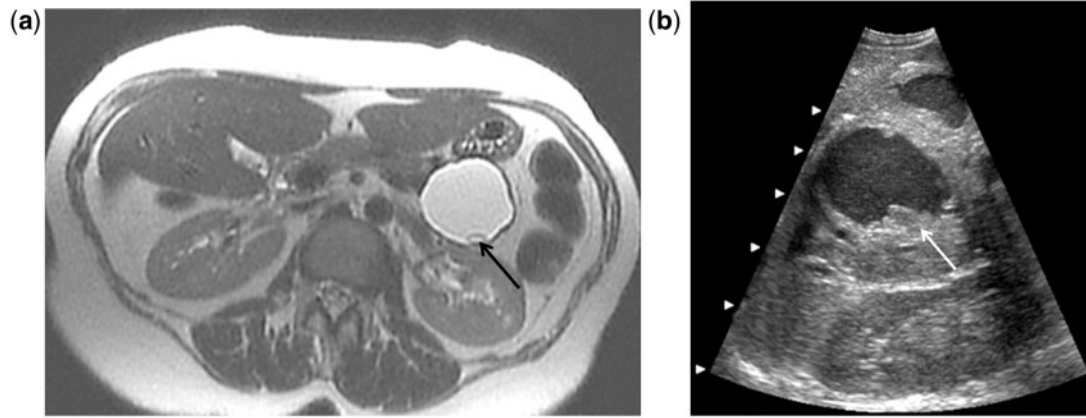


Figure 3 Cystic pancreatic incidentaloma found in a 50-year-old woman on an MR study performed to evaluate abnormal liver function tests. (a) T2-weighted axial MR image shows a 3.2 cm cystic lesion with a mural nodule (arrow) in the pancreatic tail. (b) EUS was performed and demonstrates multiple nodules (arrow) and debris within this mucinous adenocarcinoma. The patient underwent a distal pancreatectomy.

fibrous ovarian-type stroma. They represent a spectrum of neoplasms of widely different malignant potential: benign mucinous cystadenomas (Fig. 2); borderline tumors with malignant potential, or malignant (carcinoma in situ or invasive carcinoma). Most (70–90%) of MCNs arise in the body or tail of the pancreas, with only 10–30% being located in the head of the pancreas. They are usually large; the mean diameter ranges from 7 to 10 cm. MCNs usually contain several cystic areas that are 1–2 cm in diameter, but can also present as a single macrocystic lesion. The cyst wall is typically 1–2 mm thick and contains calcification in up to 30%. The presence of tumoral calcification, septation, and mural thickening has a statistically significant association with malignancy (Figs. 3 and 4). Although mucinous cystic neoplasms do not communicate with the pancreatic duct, when sufficiently large, they can cause partial ductal obstruction^[22–26].

Serous cystadenomas

SCs are benign cystic tumors that arise from the acinar cells of the pancreas. The average rate of growth of an SC is approximately 5–6 mm per year. Fifty percent of these lesions are located within the head of the pancreas and tumors range between 1 and 20 cm in size with a mean of 6 cm. They lesions are typically microcystic (Fig. 5) and have a simple cuboidal epithelial lining on histology. These lesions have been described as a lobulated micro-lacunar mass with septations and a calcified central scar. An increasing number, however, are found to be larger and oligocystic (Fig. 6)^[27,28].

Intraductal papillary mucinous neoplasms

IPMN (Figs. 7 and 8) is a neoplastic proliferation of mucin-producing cells lining the main or secondary branch pancreatic ducts. Main-duct IPMNs involve the main pancreatic duct with or without concurrent involvement of the branch ducts (combined IPMNs).

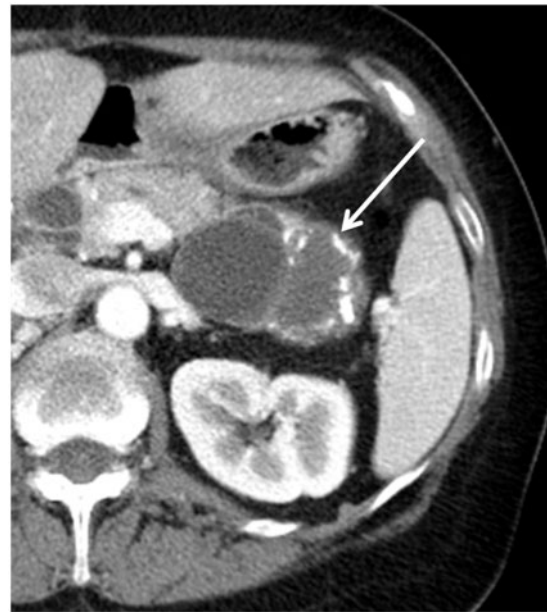


Figure 4 Cystic pancreatic incidentaloma on an MDCT scan performed to evaluate hematuria in a 51-year-old woman. CT shows several septations, areas of minimal mural thickening, and curvilinear calcification within a mass in the pancreatic tail (arrow). A mucinous cystadenocarcinoma was found pathologically.

These neoplasms can produce considerable amounts of mucin, which distend the local ductal system, causing ductal ectasia, and can create a multiloculated cystic mass. Branch-duct IPMNs involve the side branches of the pancreatic ductal system and manifest as cystic lesions communicating with a nondilated main pancreatic duct. Main-duct IPMNs are typically (75%) located in the proximal portion of the pancreas and tend to spread to the remaining main pancreatic duct. Branch-duct IPMNs can be found in the uncinate process, head, neck, or distal pancreas. Quite often there is

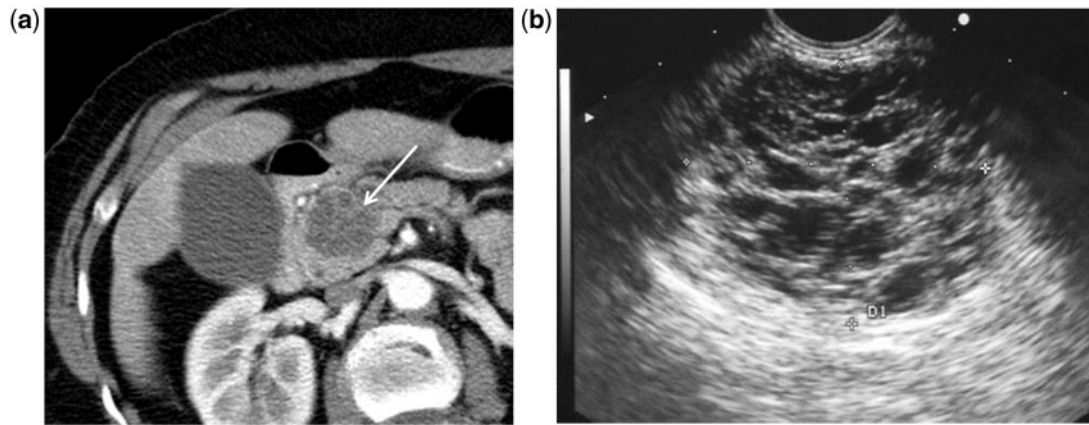


Figure 5 Cystic pancreatic incidentaloma in a 71-year-old woman who presented with pain in the left lower quadrant. (a) MDCT shows a sponge-like, multiseptated cystic mass in the pancreatic head without biliary or pancreatic ductal obstruction. Despite this classic CT appearance of a serous cystadenoma, the patient and her physician were concerned and endoscopy ultrasonography (b) was performed. This study confirms the innumerable microcystic structures comprising this tumor.

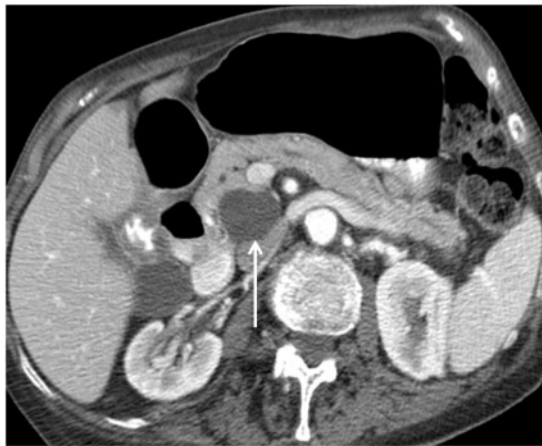

Figure 6 Cystic pancreatic incidentaloma in a 75-year-old woman with hematuria. MDCT depicts a unilocular 2.7 cm cystic mass (arrow) with a density of 19 HU in the uncinate process of the pancreas. This lesion was aspirated and proved to be an oligocystic serous cystadenoma.

multifocal involvement of the pancreas with two or more branch-duct IPMNs. The malignancy rate of main-duct IPMNs has been found to be significantly higher than that of branch-duct IPMNs. Further predictors of malignancy include: main pancreatic duct dilation, larger tumor size (>1 cm), a thick cyst wall, proximal location, mural nodules, protruding lesions in dilated branch ducts and mucin leakage from a patulous ampulla^[29–32].

Morphological clues

Based on morphologic features such as location, status of the main pancreatic duct, the presence or absence of septae, loculations, and calcifications, cystic pancreatic

incidentalomas can be classified into four major types: (1) unilocular or oligolocular (pseudocyst, IPMN, SC, MCN); (2) microcystic (SC); (3) macrocystic (MCN, SC, IPMN); and (4) cyst with a solid component (IPMN, MCN)^[33].

Unilocular or oligolocular cysts

Unilocular cysts are probably the most difficult to manage because they are frequently small and consist of a broad spectrum of benign to potentially malignant pathologies, including pseudocyst, MCN, IPMN, and SC. A unilocular cyst in a patient with a clinical history of pancreatitis is almost always a pseudocyst. Although accurate characterization of unilocular cysts is challenging, CT findings, including the location in the pancreatic head, lobulated contour, absence of wall enhancement, and lack of mural nodule, in an elderly woman are specific for the diagnosis of SC. The presence of peripheral tumoral calcification has a significant association with MCN^[14,15,33].

Multilocular cystic lesions

Multilocular cystic lesions can be divided into three categories: (a) lobulated; (b) pleomorphic, (c) smooth shape with septation(s). A lobulated shape is defined as the shape of a simple closed curve not conforming to a simple sphere, with or without internal septations and is typically seen with oligocystic SCs. A pleomorphic shape is defined as one containing three or more cysts, including more than one oval or tubular cyst, and is typical of branch-duct-type IPMNs. A smooth shape with septation is defined as a simple closed curve with the borders of the same circle, and this is a typical finding of MCNs^[16,17,33].

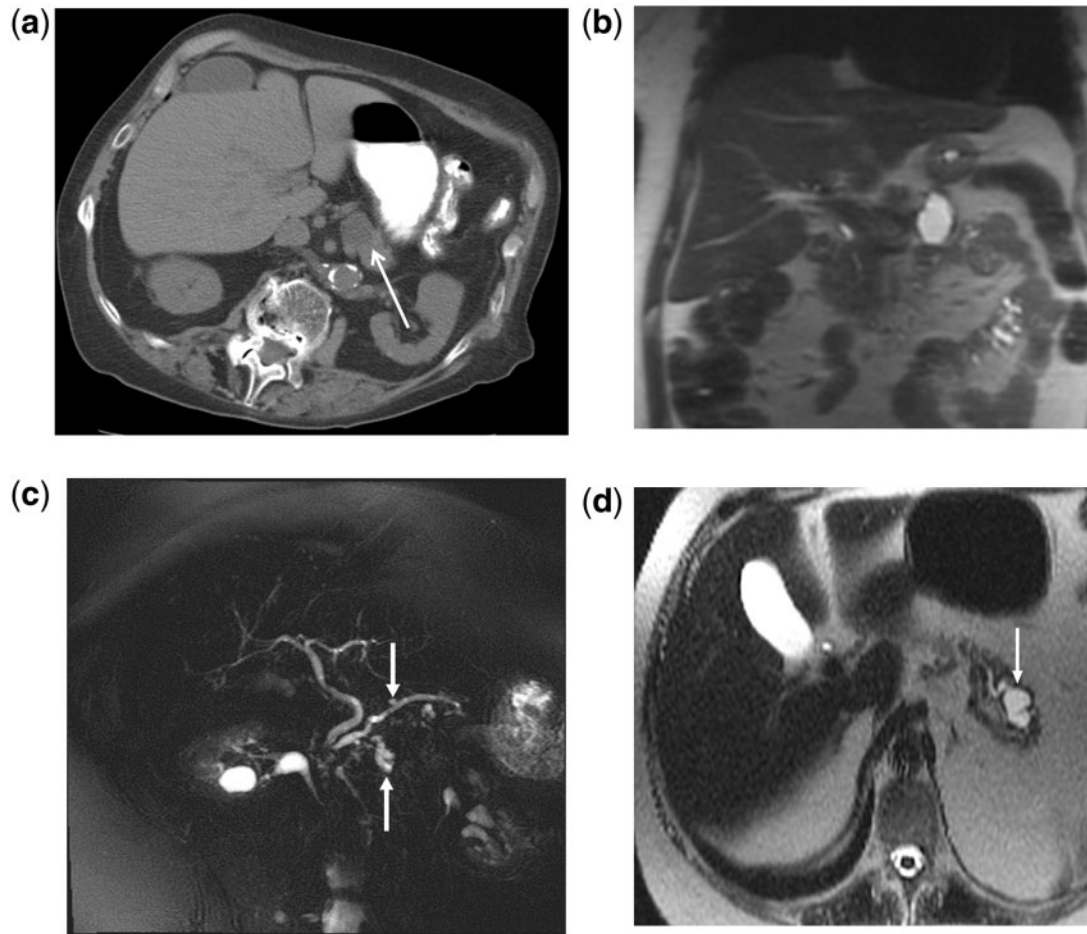


Figure 7 Incidental side-branch IPMNs that can be safely watched. Axial magnetic resonance cholangiopancreatography (MRCP) (a) and coronal MRCP (b) images show a 2.6-cm cystic lesion (arrow) in the pancreatic body that shows no mural thickening or septations. There is no dilation of the pancreatic duct. MRCP images (c,d) from two different patients demonstrate side-branch cystic tumors (arrows) that are not associated with pancreatic duct dilation.

The cystic tumors in this category are also difficult to characterize because of their overlapping morphology. The differentiation of oligocystic SC from MCN is important because of the malignant potential of mucinous tumors. Oligocystic SC appears as a multicystic or lobulated cystic lesion with septation, while MCN shows a smooth shape, with or without septations. Calcification in SCs is typically central within the fibrous stroma, whereas MCN may have a peripheral eggshell calcification^[11,12,33].

Microcystic lesion

SC is the only cystic lesion included in this category. The typical CT appearance of this tumor is similar to that of a sponge or honeycomb with innumerable tiny cystic spaces separated by thin septa. The septa may coalesce into a characteristic central stellate scar that may calcify, which is considered to be pathognomonic for SC and found in about 20% of tumors. The small size of the cysts and the innumerable enhancing septa may cause the mass to appear solid on CT. Microcysts may be

seen as numerous discrete foci with bright signal intensity on T2-weighted MR images, and have little free fluid in the locules on endoscopic ultrasonography^[27,28,33].

Cysts with a solid component

This category includes MCNs and IPMNs that have undergone malignant degeneration as well as solid neoplasms associated with a cystic component or cystic degeneration. Solid tumors associated with a cystic component include cystic pancreatic endocrine tumor, solid pseudopapillary tumor, cystic change in ductal carcinoma, and metastasis. Incidentalomas with this appearance need to be aggressively investigated^[33].

Endoscopic ultrasonography

Because of its ability to obtain fluid for chemical, cytological, and genetic evaluation and due to its exquisite spatial resolution, endoscopic ultrasonography with fine-needle aspiration is considered the most accurate

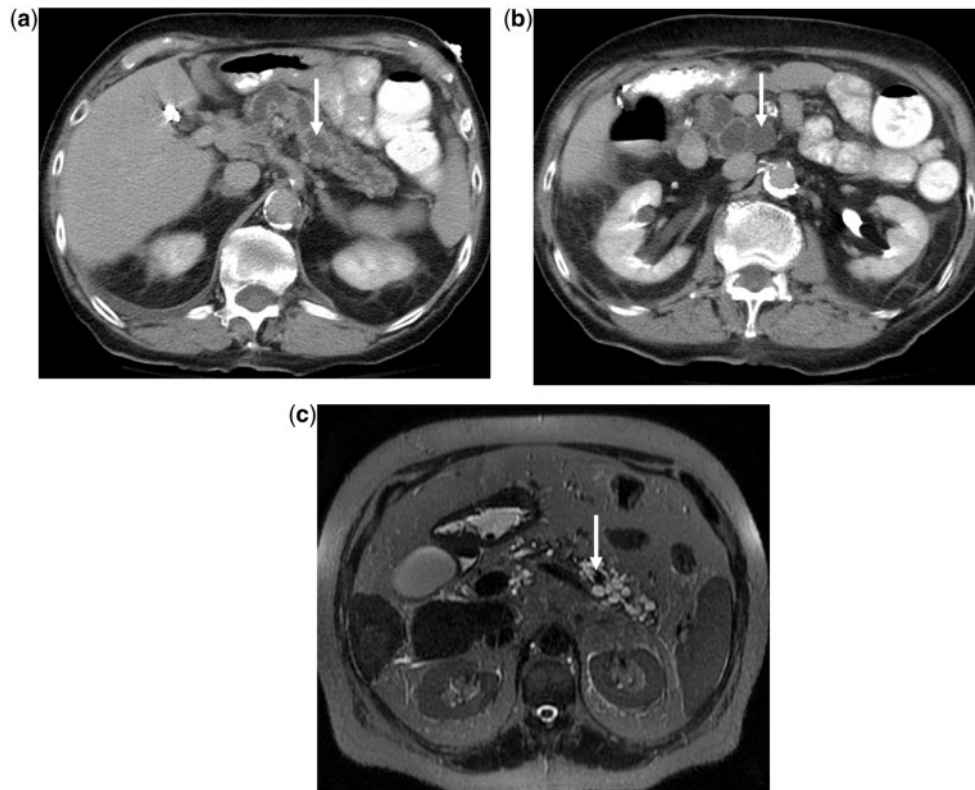


Figure 8 Incidental main-duct IPMNs that need immediate further evaluation. Two axial MDCT images (a,b) show distention of the entire pancreatic duct. There is no pancreatic head mass or biliary dilation. (c) MRCP image in a different patient shows a nodule in the main pancreatic duct as well as multiple side-branch IPMNs.

but most invasive means of evaluating a cystic pancreatic mass. Cyst size is the primary determinate of successful aspiration. A carcinoembryonic antigen level in the aspirate >192 ng/ml has a high specificity for discriminating mucinous from nonmucinous cysts, with an accuracy surpassing cyst morphology. Amylase levels <250 U/l exclude a pseudocyst. Cytologic evaluation can also be performed to search for frankly malignant cells. In addition, genetic analysis of the material to search for *k-ras*, *n-ras*, and other mutations should also be considered. Endoscopic ultrasonography is also superb in detecting morphologic features that suggest malignant transformation: focal cyst wall thickening or irregularity, septal thickening, mural nodules, intracystic solid components, dilation of the main pancreatic duct, adenopathy, invasion of adjacent fat or organs, and the presence of collateral vessels^[34–36].

Conclusions and recommendations

Asymptomatic cystic lesions that are <3 cm in size, without mural thickening, mural nodularity, solid components, or dilation of the main pancreatic duct are usually benign and can be safely watched. The minority that have a malignant potential are usually slow growing and there is a large body of evidence that they

Table 1 Recommendations for managing an incidental pancreatic cysts

1. Surgery should be considered for patients with cysts larger than 3 cm
2. If the lesion is a serous cystadenoma, surgery is deferred until the cyst is >4 cm
3. Patients with simple cysts <3 cm can be followed up, but attempts to characterize the cysts >2 cm should be made at detection; if this cannot be done on the available imaging study, MRI is the preferred procedure
4. Cysts <1 cm cannot be further characterized by imaging, but can be followed less frequently than cysts >3 cm; in elderly patients (>80 years of age), these cysts likely will not require further investigation
5. Aspiration is strongly advised to exclude a pseudocyst before any surgery is performed
6. Patients must remain asymptomatic during the follow-up period

can be safely watched if they meet the criteria listed above^[37–41].

The American College of Radiology (ACR) guidelines recommend a single follow-up in 1 year for lesions smaller than 2 cm; a follow-up of every 6 months for 2 years and then yearly for lesions 2–3 cm; and for lesions larger than 3 cm, resection unless they are SCs or proven to be pseudocyst through aspiration. These recommendations are summarized in Table 1 and an algorithmic approach is shown in Fig. 9. Nonoperative candidates

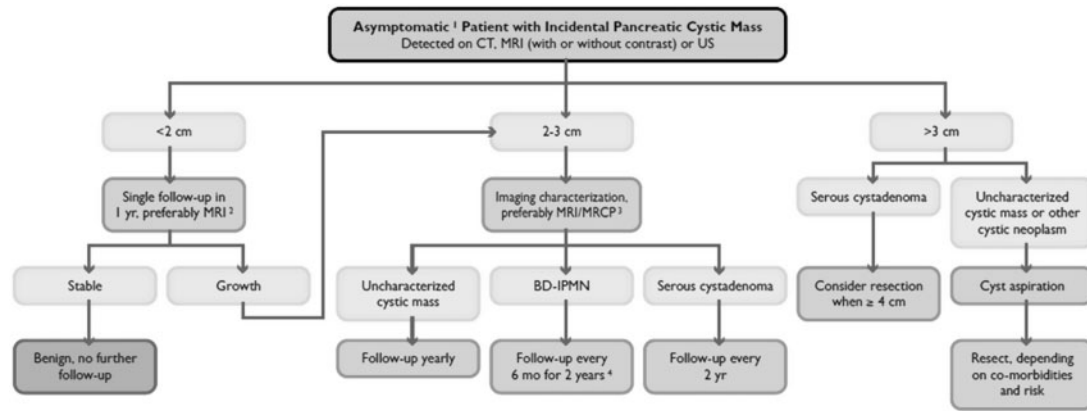


Figure 9 Flowchart for imaging workup of incidental pancreatic masses in asymptomatic patients. As with all guidelines, these are not meant to be a rigid set of rules, but rather a starting point for clinically relevant decision making. BD-IPMN, branch-duct intraductal papillary mucinous neoplasm; US, ultrasonography. (1) Signs and symptoms include hyperamylasemia, recent onset diabetes, severe epigastric pain, weight loss, steatorrhea, or jaundice. (2) Consider decreasing interval if younger, omitting with limited life expectancy. Recommend limited T2-weighted MRI for routine follow-ups. (3) Recommend pancreas-dedicated MRI with MRCP. (4) If no growth after 2 years, follow yearly. If growth or suspicious features develop, consider resection.

do not need to be followed. The management should be altered if there is any increase in cyst size or the development of suspicious imaging features or clinical symptoms^[7].

The ACR subcommittee on incidental pancreatic lesions recommends MRI as the preferred follow-up examination because of its superior contrast resolution making the detection of septa, nodules, and main pancreatic duct communication easiest to recognize. Irrespective of the follow-up examination, care must be taken to ensure that measurements are made carefully and consistently. Growth alone may not be sufficient to recommend surgery and the cyst content should be aspirated before surgical excision is performed^[7].

These recommendations are not offered as standard of care guidelines. Individual patient factors must be incorporated into the clinical decision-making process. This approach however will help guide the radiologist and clinician in analyzing most cystic pancreatic incidentalomas.

Conflict of interest

The authors have no conflicts of interest to declare.

References

- [1] Spinelli KS, Fromwiller TE, Daniel RA, et al. Cystic pancreatic neoplasms: observe or operate. *Ann Surg* 2004; 239: 651–657; discussion 657–659. doi:10.1097/01.sla.0000124299.57430.ce. PMID:15082969.
- [2] Laffan TA, Horton KM, Klein AP, et al. Prevalence of unsuspected cysts on MDCT. *AJR* 2008; 191: 802–807. doi:10.2214/AJR.07.3340. PMID:18716113.
- [3] Zhang XM, Mitchell DG, Dohke M, et al. Pancreatic cysts: depiction on single-shot fast spin-echo MR images. *Radiology* 2002; 223: 547–553. doi:10.1148/radiol.2232010815. PMID:11997566.
- [4] Lee KS, Sekhar A, Rofsky NM, et al. Prevalence of incidental pancreatic cysts in the adult population on MR imaging. *Am J Gastroenterol* 2010; 105: 2079–2084. doi:10.1038/ajg.2010.122. PMID:20354507.
- [5] Macari M, Megibow AJ. Focal cystic pancreatic lesions: variability in radiologists' recommendations for follow-up imaging. *Radiology* 2011; 259: 20–23. doi:10.1148/radiol.11102437. PMID:21436094.
- [6] Megibow A, Baker ME, Gore RM, Taylor AJ. The incidental pancreatic cyst. *Radiol Clin North Am* 2011; 49: 439–459.
- [7] Berland LL, Silverman SG, Gore RM, et al. Managing incidental findings on abdominal CT: white paper of the ACR incidental findings committee. *J Am Coll Radiol* 2010; 7: 754–773. doi:10.1016/j.jacr.2010.06.013. PMID:20889105.
- [8] Tanaka M. Controversies in the management of pancreatic IPMN. *Nat Rev Gastroenterol Hepatol* 2011; 8: 56–60. doi:10.1038/nrgastro.2010.193. PMID:21212775.
- [9] Sahani DV, Lin DJ, Venkatesan AM. Multidisciplinary approach to diagnosis and management of intraductal papillary mucinous neoplasms of the pancreas. *Clin Gastroenterol Hepatol* 2009; 7: 259–269. doi:10.1016/j.cgh.2008.11.008.
- [10] Hruban RH, Pitman MB, Klimstra DS. Atlas of tumor pathology: tumors of the pancreas. 4th ed. Washington, DC: American Registry of Pathology and Armed Forces Institute of Pathology; 2007. PMID:22898932.
- [11] Adsay NV. Cystic neoplasia of the pancreas: pathology and biology. *J Gastrointest Surg* 2008; 12: 401–404. doi:10.1007/s11605-007-0348-z. PMID:17957438.
- [12] Parra-Harran CE, Garcia MT, Herrera L, et al. Cystic lesions of the pancreas: clinical and pathologic review of in a five year period. *JOP* 2010; 11: 358–364.
- [13] Lee CJ, Scheiman J, Anderson MA, et al. Risk of malignancy in resected cystic tumors of the pancreas < or = 3 cm in size: is it safe to observe asymptomatic patients? *J Gastrointest Surg* 2008; 12: 234–242. doi:10.1007/s11605-007-0381-y. PMID:18040749.
- [14] Bartosch-Härlid A, Andersson R, Werner JB. Cystic pancreatic lesions: current evidence for diagnosis and treatment. *Scand J Gastroenterol* 2011; 46: 773–788.

- [15] Sakorafas GH, Smyrniotis V, Reid-Lombardo KM, Sarr MG. Primary pancreatic cystic neoplasms revisited. Part II: mucinous cystic neoplasms. *Surg Oncol* 2011; 20: 93–101.
- [16] Sakorafas GH, Smyrniotis V, Reid-Lombardo KM, Sarr MG. Primary pancreatic cystic neoplasms revisited. Part I: serous cystic neoplasms. *Surg Oncol* 2011; 20: 84–92.
- [17] Testini M, Gurrado A, Lissidini G, et al. Management of mucinous cystic neoplasms of the pancreas. *World J Gastroenterol* 2010; 16: 5682–5692. doi:10.3748/wjg.v16.i45.5682. PMID:21128317.
- [18] Roggin KK, Chennat J, Oto A, et al. Pancreatic cystic neoplasm. *Curr Probl Surg* 2010; 47: 459–510. doi:10.1067/j.cpsurg.2010.02.002. PMID:20451023.
- [19] Canto MI, Hruban RH, Fishman EK, et al. Frequent detection of pancreatic lesions in asymptomatic high risk individuals. *Gastroenterology* 2012; 142: 796–804. doi:10.1053/j.gastro.2012.01.005. PMID:22245846.
- [20] Matsubayashi H. Familial pancreatic cancer and hereditary syndromes: screening strategy for high-risk individuals. *J Gastroenterol* 2011; 46: 1249–1259. doi:10.1007/s00535-011-0457-z. PMID:21847571.
- [21] Kim DH, Pickhardt PJ. Radiologic assessment of acute and chronic pancreatitis. *Surg Clin North Am* 2007; 87: 1341–1358. doi:10.1016/j.suc.2007.08.005. PMID:18053835.
- [22] Pitman MB, Lewandrowski K, Shen J, et al. Pancreatic cysts: preoperative diagnosis and clinical management. *Cancer Cytopathol* 2010; 118: 1–13. doi:10.1002/cncy.20059. PMID:20043327.
- [23] Sawhney MS, Al-Bashir S, Cury MS, et al. International consensus guidelines for surgical resection of mucinous neoplasms cannot be applied to all cystic lesions of the pancreas. *Clin Gastroenterol Hepatol* 2009; 7: 1373–1376. doi:10.1016/j.cgh.2009.06.026. PMID:19577006.
- [24] Buerke B, Heindel W, Wessling J. Differential diagnosis and radiological management of cystic pancreatic lesions. *Rofo* 201; 182: 852–860. doi:10.1055/s-0029-1245502.
- [25] Carpizo DR, Allen PJ, Brennan MF. Current management of cystic neoplasms of the pancreas. *Surgeon* 2008; 6: 298–307. doi:10.1016/S1479-666X(08)80055-8. PMID:18939378.
- [26] Fasanella KE, McGrath K. Cystic lesions and intraductal neoplasms of the pancreas. *Best Pract Res Clin Gastroenterol* 2009; 23: 35–48. doi:10.1016/j.bpg.2008.11.011. PMID:19258185.
- [27] Wargo JA, Fernandez-del-Castillo C, Warshaw AL. Management of pancreatic serous cystadenomas. *Adv Surg* 2009; 43: 23–34. doi:10.1016/j.yasu.2009.03.001. PMID:19845167.
- [28] Sahara S, Kawai N. Differentiation of pancreatic serous cystadenoma from endocrine tumor and intraductal papillary mucinous neoplasm based on washout pattern on multiphase CT. *J Comput Assist Tomogr* 2012; 36: 231–236. doi:10.1097/RCT.0b013e3182483bb7. PMID:22446365.
- [29] Grützmann R, Post S, Saeger HD, Niedergethmann M. Intraductal papillary mucinous neoplasia (IPMN) of the pancreas: its diagnosis, treatment, and prognosis. *Dtsch Arztebl Int* 2011; 108: 788–794.
- [30] Dongbin L, Fei L, Werner B, et al. Intraductal papillary mucinous neoplasms of the pancreas: diagnosis and management. *Eur J Gastroenterol Hepatol* 2010; 22: 1029–1038. doi:10.1097/MEG.0b013e32833b00f9. PMID:20520560.
- [31] Augustin T, Vandermeer TJ. Intraductal papillary mucinous neoplasm: a clinicopathologic review. *Surg Clin North Am* 2010; 90: 377–398. doi:10.1016/j.suc.2009.12.008. PMID:20362793.
- [32] Perez-Johnston R, Lin J D. Management of intraductal papillary mucinous neoplasms of the pancreas. *Minerva Chir* 2009; 64: 477–487. PMID:19859038.
- [33] Cho H-W, Choi J-Y, Kim M-J, et al. Pancreatic tumors: emphasis on CT findings and pathologic classification. *Korean J Radiol* 2011; 12: 731–739. doi:10.3348/kjr.2011.12.6.731. PMID:22043156.
- [34] Okabe Y, Kaji R, Ishida Y, et al. The management of the pancreatic cystic neoplasm: the role of the EUS in Japan. *Dig Endosc* 2011; 23(Suppl 1): 39–42. doi:10.1111/j.1443-1661.2011.01143.x. PMID:21535199.
- [35] Hong SM, Park JY, Hruban RH, Goggins M. Molecular signatures of pancreatic cancer. *Arch Pathol Lab Med* 2011; 135: 716–727. PMID:21631264.
- [36] Al-Haddad M, El Hajj II, Eloubeidi MA. Endoscopic ultrasound for the evaluation of cystic lesions of the pancreas. *JOP* 2010; 11: 299–309. PMID:20601798.
- [37] Salvia R, Crippa S, Partelli S, et al. Pancreatic cystic tumours: when to resect, when to observe. *Eur Rev Med Pharmacol Sci* 2010; 14: 395–406. PMID:20496554.
- [38] Sachs T, Pratt WB, Callery MP, Vollmer CM. Jr. The incidental asymptomatic pancreatic lesion: nuisance or threat? *J Gastrointest Surg* 2009; 13: 405–415. doi:10.1007/s11605-008-0788-0. PMID:19130153.
- [39] Walsh RM, Vogt DP, Henderson JM, et al. Management of suspected pancreatic cystic neoplasms based on cyst size. *Surgery* 2008; 144: 677–684. doi:10.1016/j.surg.2008.06.013. PMID:18847654.
- [40] Ip IK, Morteale KJ, Prevedello LM, Khorasani R. Focal cystic pancreatic lesions: assessing variation in radiologists' management recommendations. *Radiology* 2011; 259: 136–141. doi:10.1148/radiol.10100970. PMID:21292867.
- [41] Hanrich SJ, Hough DM, Fletcher JG, Sarr MG. The natural history of the incidentally discovered small simple pancreatic cyst: long-term follow-up and clinical implications. *AJR* 2005; 184: 20–23.