

Cystadenofibroma of the rete ovarii: a case report with review of literature

Manisha Ram,¹ Abdel Abdulla,¹ Khalil Razvi,¹ Ivilina Pandeva,¹ Awatif Al-Nafussi²

¹Department of Cellular Pathology, Basildon Hospital, Basildon & Thurrock University Hospitals NHS Foundation Trust, Basildon, UK; ²Department of Cellular Pathology, Royal Infirmary of Edinburgh, Edinburgh, Scotland, UK

Introduction

The rete ovarii (RO), the homolog of the rete testis (RT), is present in the hilus of all ovaries.¹ It is composed of irregularly anastomosing tubules lined by flat, cuboidal or columnar non-ciliated cells with scanty eosinophilic or clear cytoplasm. Some authors state that the RO contains ciliated cells.¹ The tubules generally lack a basement membrane, as judged by the absence of PAS staining beneath the epithelial lining. The histological description of RO in humans is generally similar to that of the mouse, including a network of irregular tubules, sometimes communicating with mesonephric tubules in the mesovarium, and lined by epithelium varying from flattened to columnar and occasionally ciliated.² However, in contrast to the apparent commonness of cysts and tumors of the RO in mice, these lesions are described rarely in humans.² Lesions of the human RO have been infrequently described, with the largest series to date comprising under 20 cases.³ Similarly, there are only a few reports of benign epithelial tumors of the RT.⁴ We describe another rare lesion of the RO: "cystadenofibroma" of the RO in a 75-year old female, along with a literature review.

Case Report

A 75-year old patient presented with sudden onset of severe abdominal pain. Her past medical and surgical history was unremarkable. The physical examination revealed a distended abdomen and the presence of a tender, round, mobile right sided pelvic mass, measuring approximately 20 cm in size. Her blood results were within normal limits. A Computerized Tomography (CT) scan of the abdomen and pelvis showed a large, complex mass with solid and cystic areas, occupying the entire pelvis. There was a moderate amount of free fluid in

the abdomen. There was no lymphadenopathy. The CA-125 was raised to 933 u/mL. She was subsequently taken in for surgery. At laparotomy, the findings were of a large cystic mass with smooth external surface, originating from the right ovary and extending to the upper abdomen. There were no adhesions to surrounding organs. The rest of the pelvis and abdominal cavity were normal. The ovarian mass was sent for frozen section, which suggested a borderline tumor. In view of this, a staging laparotomy with total abdominal hysterectomy, bilateral salpingo-oophorectomy, infracolic omentectomy and right pelvic lymph node dissection was performed. Macroscopically, a circumscribed whitish spongy mass occupied the whole right ovary, which weighed 500 grams and measured 18x12x8 cm. The cut surface revealed "honey-comb" like solid cystic areas, with the cysts ranging in size from 0.2 cm to 2.5 cm and containing clear fluid (Figure 1). Microscopically, there was diffuse replacement of the ovarian parenchyma, from hilus to cortex, by a cellular proliferation of epithelial and stromal cells (Figure 2). The epithelial cells were arranged as tubular and slit-like spaces (Figure 3), with numerous variably sized cystic spaces having an irregular outline. The tubules had an irregular branching configuration reminiscent of an "antler-horn" pattern. The areas of prominent cystic change had scattered tiny papillae, projecting into the cysts (Figures 4 and 5). The cyst lumens contained amorphous, granular, proteinaceous, eosinophilic material along with occasional foamy

Correspondence: Manisha Ram, Department of Cellular Pathology, Basildon Hospital, Basildon & Thurrock University Hospitals NHS Foundation Trust, Nethermayne, Basildon, SS16 5NL, United Kingdom
E-mail: pathologist.manisha@gmail.com

Key words: ovary, rete ovarii, cystadenofibroma, rete testis, immunohistochemistry.

Acknowledgments: we would like to thank Kerry Hughes for her assistance in typing this manuscript.

Contributions: MR, AAI-N, conception, design, acquisition of data, analysis and interpretation of data, drafting article and revising critically for important intellectual content, final approval of version to be published; AA, interpretation of data, revising critically for important intellectual content, final approval of version to be published; KR, revising critically for important intellectual content, final approval of version to be published; IP, acquisition of data, final approval of version to be published.

Conflict of interest: the authors reported no potential conflict of interests.

Received for publication: 22 July 2009.

Accepted for publication: 23 July 2009.

This work is licensed under a Creative Commons Attribution 3.0 License (by-nc 3.0)

©Copyright M. Ram et al., 2009
Rare Tumors 2009; 1:e24
doi:10.4081/rt.2009.e24

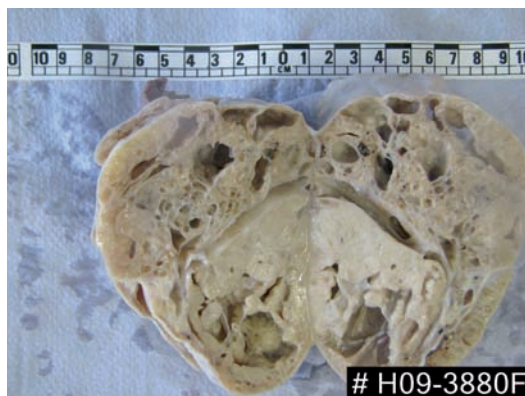

Figure 1. Gross photograph showing bi-valved specimen depicting solid-cystic appearance.

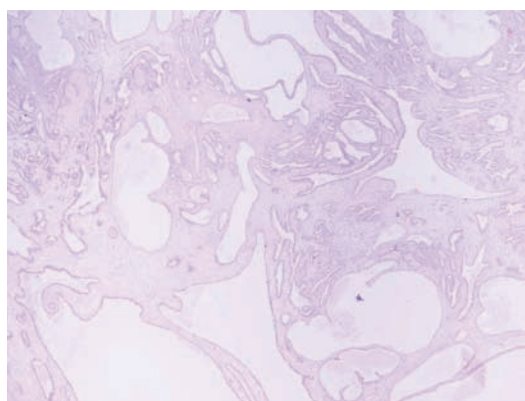


Figure 2. Microphotograph showing diffuse replacement of ovary by epithelial and stromal proliferation (H&E X 40).

macrophages. The lining throughout was bland, monolayered, non-ciliated cuboidal to columnar, with moderate amount of pale eosinophilic cytoplasm (Figure 6). Nuclei were basally orientated, monomorphic, round to oval, containing dispersed chromatin and small nucleoli. Focally, especially in areas with marked cystic dilatation, the lining cells were flat. The cores of the papillae and intertubular stroma consisted of fibrovascular tissue, containing spindle-shaped cells with monomorphic elongated nuclei (Figure 7). Smooth muscle fibers were very occasional in the stroma (Figure 8). There were no Leydig-like cells in the stroma, which was further confirmed by negative immunostaining for Inhibin. Neither nuclear atypia nor conspicuous mitotic figures were seen in the epithelial or stromal cells. Necrosis was not evident. Normal background ovarian parenchyma was not seen (in spite of embedding the whole specimen). The labyrinthine channels, slit-like spaces and mature fibrous mesenchymal type of stroma, were all very reminiscent of RO. On immunohistochemistry, mesothelial markers (CK5/6, Calretinin, WT-1, thrombomodulin) were negative. The epithelial lining cells were positive for CK7, ER, PR, Vimentin and CD10 (Figures 9-12). Considering the glandular and stromal pattern and the immunohistochemistry results, a diagnosis of cystadenofibroma of the RO was made. The uterus showed a benign intramural leiomyoma along with cystic atrophy of the endometrium. The left ovary and omentum were histologically unremarkable. The right common iliac, external iliac, internal iliac and right obturator lymph nodes showed reactive hyperplasia only, with no evidence of metastasis.

Discussion

There is considerable debate regarding the histogenesis of the RO. Most investigators consider the RO to be of mesonephric origin.^{1,5-7} Upadhyay *et al.*⁸ favor a mesonephric origin in mice, but Nogales *et al.*⁸ state that these results may not be transferable to humans because of the considerable differences in gonadal development between species. Nogales⁵ suggested that the RO represents a structure intermediate between the mesonephric duct and ovarian sex cords. Satoh⁹ elaborated how, during embryogenesis, remnants of primordial sex cords in the basal portion of the ovary give rise to the rete. "Coelomic-epithelial" and "gonadal blastemal" origins have also been advanced.¹ Amidst all this argument, Nogales *et al.*⁸ state that the RO and RT are anatomical structures of uncertain histogenesis. The position of the RO varies between species. It is found most com-

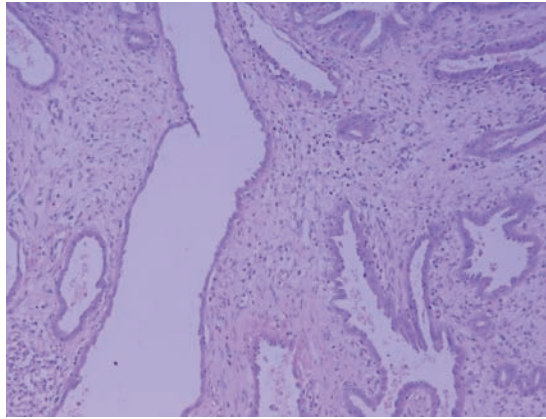


Figure 3. Microphotograph showing variably sized irregular slit-like spaces lined by monolayered bland cuboidal epithelium and intervening mature fibrotic stroma (H&E X200).

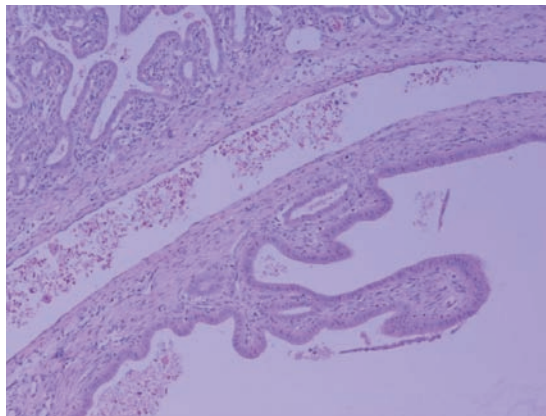


Figure 4. Microphotograph showing a markedly dilated cyst with papillae projecting into the cyst lumen (H&E X200).

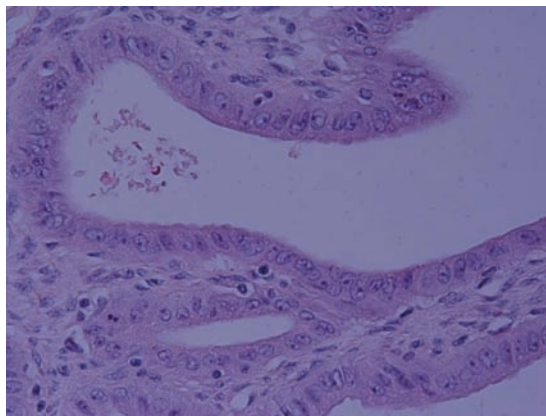


Figure 5. Microphotograph showing high power view of bland cuboidal lining of papillae (H&E X400).

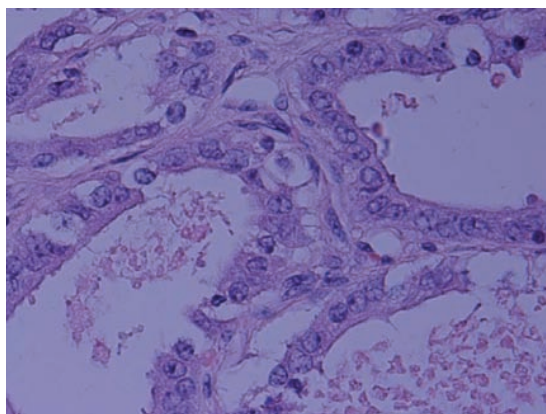


Figure 6. Microphotograph showing bland cuboidal lining of tubules with occasional ciliated cells (H&E X600).

monly in the hilus of the ovary, but may be represented by tubules or cords extending through the medulla, or may be completely outside the ovary, in the mesovarium, adjacent to the hilus.⁷ Age-related changes have been described in the RO. In the human fetus, the RO enlarges and a columnar network of tubules extends along the length of the ovary in the hilar regions, so that at birth, the RO is described as strongly developed.⁷ The so-called urogenital union between the rete and the mesonephric tubules (transverse ductules in the female, homologous with the efferent ductules in the male) which was lost during the morphogenesis of the gonad is regained in the male to form the excretory pathway. Hence, in males, the RT is fully developed and functional. On the other hand, the reunion in the female may not occur or is imperfect,⁷ hence the RO is said to be a vestigial structure of unknown function.^{8,10} The RO seems to play an important role in early gonadal embryogenesis, being related to primitive sex cord formation.¹⁰ From birth through puberty, the RO comes to occupy less of the volume of the ovary. The rete tubules become more separated by increasing amounts of connective tissue. In adults, the RO is described to be variable in its appearance, from almost lacking to abundant. Though the RO is usually found within the ovary, the position is variable and it may be found almost completely outside in the mesovarium. With advancing age, it tends to become more atrophic and may become solid, adenomatous, cystic or polycystic.⁷ Tumors of the RO proper are most unusual.^{1,10,11} In the literature, only one report has dealt with cysts, adenomas and carcinomas of this structure.¹ Khan *et al.*¹¹ have tried to explain the reason of the comparative rarity of benign and malignant tumors arising in this structure, as compared to other sites in the female genital tract (FGT). They found lower levels of estrogen receptor (ER) and progesterone receptor (PR) in the rete, suggesting a lesser degree of responsiveness to hormone stimulation in this structure, which consequently explains the low proliferation rate in the RO. This low proliferation rate, detected using antibody to Ki-67, suggests a lower growth rate in this tissue than in other tissues of the FGT. They advance the theory that this low proliferation is responsible for the rarity of RO tumors. The major importance to recognize the RO and its lesions is that they can be confused with other conditions such as endometriosis.⁶ A detailed description and characterization of this unique structure (RO) may help in difficult differential diagnoses between benign and malignant ovarian lesions, analogous to testicular lesions.¹² Recognition of benign lesions is important so that unnecessary and potentially morbid therapies are avoided.¹³ The majority of the rete cysts are thought to repre-

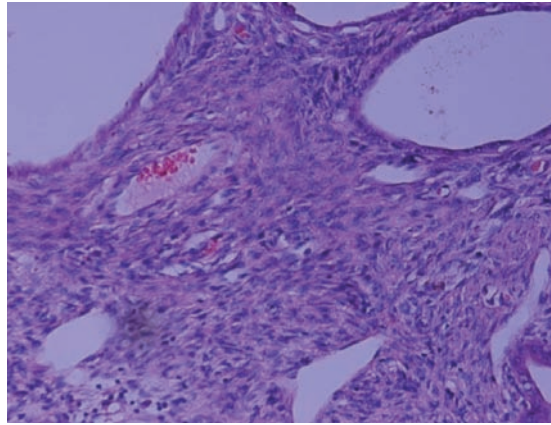


Figure 7. Microphotograph showing cellular fibrotic stroma, reminiscent of rete ovarii (H&E X200).

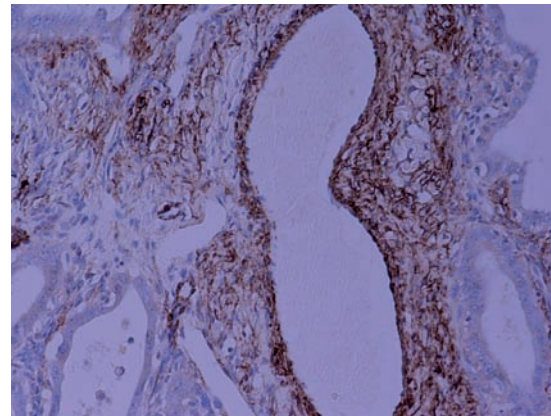


Figure 8. Microphotograph showing focal smooth muscle fibers (highlighted by SMA immunostaining) in the stroma (H&E X200).

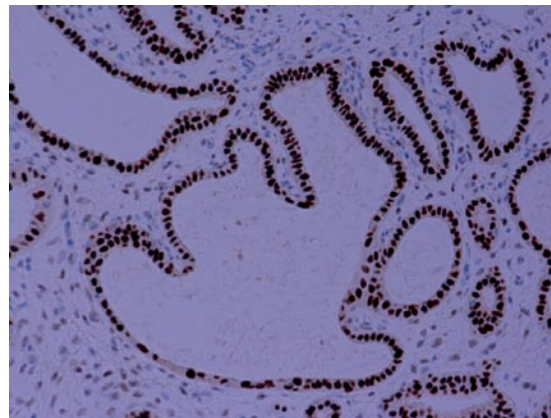


Figure 9. Microphotograph showing intense and diffuse ER positivity in epithelial cells (H & DAB X 200).

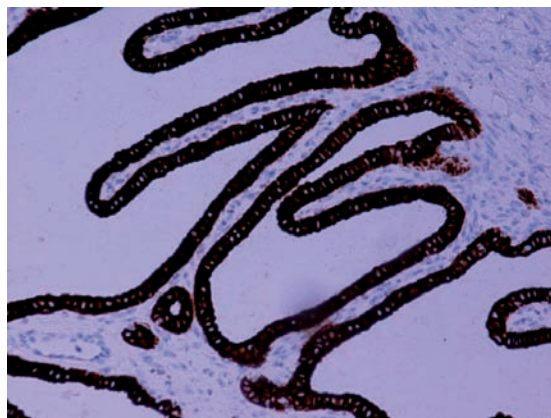


Figure 10. Microphotograph showing intense and diffuse CK7 positivity in epithelial cells (H & DAB X200).

sent non-neoplastic dilatations, since they are lined by a single layer of bland epithelium and appear to be exaggerations of microscopic rete dilatations.¹ Rutgers and Scully¹ state that although rete cysts have been rarely described in the literature, they are not that uncommon. They found 16 cases of RO cysts (cystadenomas), 7 of which were found in a retrospective review of 126 ovarian cysts. Rete cyst formation is more common in older than younger women.¹ The age range in the 16 cases described by Rutgers and Scully¹ was from 23-80 years, (mean age 59 years), most of whom were post-menopausal. Similarly, our case is also that of a 75-year old post-menopausal patient. A plethora of RT lesions have been described,^{4,14} including:

1. non-neoplastic and developmental abnormalities, which include rete hyperplasia, nodular proliferation of calcifying connective tissue, cystic dysplasia, acquired or secondary cystic changes in the rete, rete changes in cryptorchidism;
2. benign neoplasms, which include cystadenoma of usual type and sertoliform cystadenoma;
3. adenocarcinoma of the rete.

Strict criteria⁴ have been proposed in diagnosing a primary tumor of the RT, which include:

1. absence of histologically similar extra-scrotal tumor;
2. tumor centered on the testicular hilus;
3. morphology incompatible with any other type of testicular or paratesticular tumour;
4. demonstration of a transition between the unaffected RT and the tumor;
5. a predominantly solid appearance.

The last criterion should not be applied too rigidly, since although most cystic "carcinomas of the rete" are compatible with a serous tumor, RT carcinomas with cystic growth pattern have also been encountered. Similarly, a transition with the unaffected RT may be difficult to demonstrate, but if all other criteria are met, a diagnosis of a primary RT tumor is acceptable. Although there are no such criteria for diagnosing a primary tumor of the RO, certain distinguishing features of RO tumors have been described.^{1,2}

They include:

1. apparent location in the hilus of the ovary;
2. occasional ciliated cells;
3. crevice formation of the inner surface (of the tubules/glands) which recapitulates the irregular outlines of the normal rete;
4. other resemblance to the normal rete;
5. normal rete adjacent to some lesions;
6. a wall of fibromuscular connective tissue.

Most of the previously reported cases have involved the hilus alone or the hilus and part of the medulla.¹ In our case, the ovarian involvement was diffuse and extensive, from the hilus to the cortex. Although the definite

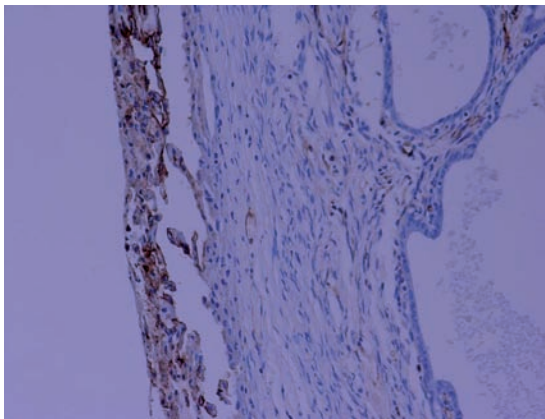


Figure 11. Microphotograph showing no staining in epithelial cells for thrombomodulin (right), whereas the normal ovarian surface epithelial lining (left) is positive for it, acting as an internal control (H & E X200).

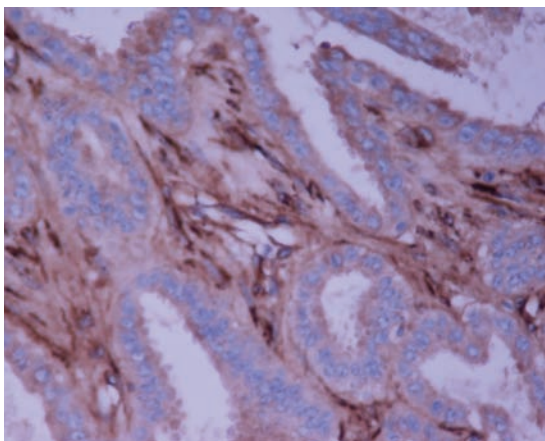


Figure 12. Microphotograph showing lack of a distinct basement membrane, highlighted by negative staining for laminin (H & DAB X400).

Table 1. Antibodies used in the study.

Antibodies	Source	Dilution	Type	Pre-treatment	Result in our case
CK5/6	Leica	Pre-dilute	Monoclonal	ER2, 10 min	- ve
ER	Leica	Pre-dilute	Monoclonal	ER2, 20 min	+ ve
PR	Novastra	1/200	Monoclonal	ER1, 20 min	Patchy + ve
SMA	Leica	Pre-dilute	Monoclonal	No pre-treatment	Focal + ve
Desmin	Leica	Pre-dilute	Monoclonal	ER2, 20 min	Focal + ve
S100	Biogenix	1/400	Monoclonal	ENZ 1, 10 min	- ve
CA-125	Nocacastra	1/100	Monoclonal	ER2, 20 min	+ ve
Cam 5.2	BD Bioscience	1/20	Monoclonal	ENZ 1, 10 min	+ ve
EMA	Dako	1/400	Monoclonal	ER2, 20 min	+ ve
CEA	Dako	1/25	Monoclonal	ENZ 1, 10 min	- ve
CK7	Leica	Pre-dilute	Monoclonal	ER2, 20 min	+ ve
CK20	Dako	1/50	Monoclonal	ER1, 20 min	- ve
E-cadherin	Dako	1/50	Monoclonal	ER2, 20 min	+ ve
Vimentin	Dako	1/200	Monoclonal	ER1, 20 min	+ ve
MNF-116	Dako	1/200	Monoclonal	ENZ 1, 10 min	+ ve
Ber-EP4	Dako	1/100	Monoclonal	ENZ 1, 10 min	+ ve
CK19	Dako	1/200	Monoclonal	ER2, 20 min	+ ve
Ki-67	Dako	1/200	Monoclonal	ER2, 20 min	< 2% cells + ve
PLAP	Dako	1/50	Monoclonal	ER2, 20 min	- ve
CD10	Leica	Pre-dilute	Monoclonal	ER2, 20 min	+ ve
Thrombomodulin	Dako	1/10	Monoclonal	No pre-treatment	- ve
Inhibin	Dako	1/100	Monoclonal	ER2, 20 min	- ve
Laminin	Dako	1/40	Polyclonal	ENZ1, 10 min	- ve
WT-1	Dako	1/1000	Monoclonal	ER2, 20 min	- ve
AFP	Dako	Pre-dilute	Monoclonal	ER1, 10 min	- ve

ER1, enzyme retrieval (low pH); ER2, enzyme retrieval (high pH); ENZ1, enzyme 1 (BondMax); ENZ2, enzyme 2 (BondMax); CK, cytokeratin; WT, Wilms' Tumour; ER, oestrogen receptor; PR, progesterone receptor; SMA, smooth muscle actin; EMA, epithelial membrane antigen; CEA, carcinoembryonic antigen; PLAP, placental alkaline phosphatase; AFP, alpha feto protein.

relation to the hilus was obscured, the cyst walls were composed of fibrovascular tissue with few irregularly arranged fascicles of smooth muscle. The intervening stroma was cellular and in places very much reminiscent of RO. Normal ovarian tissue was not seen, in spite of embedding and examining the whole specimen. Similar absence of ovarian tissue has been noted in large rete cysts of CD-1 mice.² The possible explanations put forth by Long² are that ovarian tissue could have atrophied secondary to compression, or could have had amyloidosis or other degenerative changes not directly associated with the formation of the cyst. Another postulated explanation is that of minimal remaining ovarian tissue, which could be missed due to limited sectioning of the sample. But the complete sectioning of our sample abolishes this possibility. Mesonephric and rete remnants have been described in the vicinity of the lesions in 2 cases.⁸ Our case also showed rete remnants in the vicinity of the main tumor and also admixed with it. Tumors of the RO often exhibit stromal luteinization or Leydig-like cells in the stroma, reproducing the normal relations between hilar epithelial vestiges and steroid-producing cells of the hilum.^{1,8,10} However, in our case, there was neither stromal luteinization nor Leydig-like cells, making the diagnosis quite difficult. Nogales *et al.*¹⁰ concluded that the retiform structures of Uterine Tumor Resembling Ovarian Sex Cord Tumor (UTROSCT) have a similar, if not identical immunophenotype to that of the RO and the Wolffian Adnexal Tumor (WAT). They have been regarded as different from Ovarian Retiform Sertoli Leydig Cell Tumor (ORSLCT), probably since these ovarian tumors seem to recapitulate early embryogenesis reproducing the early RO and its connection with the primitive sex cords.¹⁰ Probably, they have an immature phenotype with a different antigen expression. In our case, a number of differential diagnoses were entertained. Inclusion cysts could not be a possibility, since firstly, they would not be so extensive so as to replace and involve the whole ovarian parenchyma. Secondly, they were not stained by WT-1, which normally stains ovarian surface epithelium and ovarian inclusion cysts.¹⁵ Rete hyperplasia, on low power examination, reveals a proliferation of irregularly sized anastomosing channels and glands within the rete, which do not form a circumscribed mass. The proliferation is often vaguely lobular with smaller glands surrounding larger cystic and elongated forms.⁴ Adenomatous hyperplasia of the rete testis (AHRT) is a benign lesion characterized by solid/ glandular, papillary or cribriform proliferation of the epithelium with self-limited growth. It can appear at any time during life.¹⁴ Mesothelioma may have elongated slit-like tubules with papillary growth. But

the absence of localization within the rete, or continuity with the RO epithelium are findings that indicate a diagnosis of mesothelioma, rather than RO carcinoma.⁴ Our case had very bland epithelium, which was negative for mesothelial markers (calretinin, thrombomodulin, WT-1, CK5/ 6) and positive for epithelial markers (Cam5.2, MNF-116, BerEP4). Metastatic adenocarcinoma is another differential for RO carcinomas, though not in our case. Bilaterality, multifocality and microscopic evidence of an interstitial growth pattern with lymphatic or vascular permeation are good clues that one may be dealing with a metastasis.⁴ Cystic dilatation/ transformation of the RT has been described,^{4,12} but no such entity has been described for the RO. ORSLCT has Leydig cells (inhibin and calretinin positive) in the stroma. Positivity for inhibin and calretinin, along with negativity for EMA and CK7 favors the diagnosis of ORSLCT. However, the findings in our case were the reverse: EMA positive, inhibin and calretinin negative. Moreover, there were no Leydig cells in the stroma. Even clinically, there were no hormonal manifestations in the patient. Yolk sac tumors are known for their retiform architecture.¹⁶ However, the complete absence of α fetoprotein (AFP) in our case and the lack of placental alkaline phosphatase (PLAP), which occurs in about 50% of yolk sac tumors,¹⁵ makes a diagnosis of the latter most unlikely. An ovarian adenomatoid tumor also has to be considered in the differential diagnosis because of some morphological features. However, in the absence of CK5/6, calretinin and thrombomodulin expression, such a diagnosis cannot be entertained. Female adnexal tumor of probable Wolffian origin (FATWO) is characterized by prominent tubule formation and peritubular basement membranes.¹⁷ Laminin immunostaining accentuates a prominent peritubular basement membrane, and often unmasks a tubular pattern in what may appear to be a solid proliferation.⁵ A retiform pattern may also be seen in FATWO or WAT.⁹ These rare tumors are also positive for keratins, inhibin and vimentin, with variable ER/PR positivity. Inhibin positivity has been reported in 68%⁹ and 90%⁵ of FATWO, but it is patchy and weak. They are often non-reactive for EMA.⁵ Although our case was positive for vimentin, keratins and EMA, inhibin was characteristically negative. RO has been shown to have focal positivity for CK7, patchy and weak staining for inhibin, 8% of cases being positive for ER and PR.⁵ Our case was diffusely positive for CK7, ER and PR, while being negative for inhibin. EMA has been found to be negative,⁵ whereas our case was diffusely positive for EMA. Retiform uterine tumor resembling ovarian sex cord tumor (RUTROSCT) is another differential. But this was not entertained in our case, since the

uterus did not show any such features. However, RUTROSCT has been shown to have consistent positivity for Cam5.2, CK7, vimentin, calretinin, PR and apical CD10. CD56 and inhibin positivity has been found in half of the cases. EMA, desmin, SMA and calponin have been found to be negative.¹⁰ RO and its tumors have been found to be positive for EMA, CA- 125^{6,8,10} CK7, calretinin (cytoplasmic), CD56 (membranous), CD10 (apical).¹⁰ They have been found to be focally positive for vimentin and negative for CA19.9, CEA, S-100 and PR.⁸ However, our case was positive for EMA, CA-125, vimentin, CK7, ER, PR, CD10, Cam5.2, MNF-116, BerEP4, CK-19, ECadherin and CD56. Our case was negative for WT-1, CK5/6, calretinin, inhibin, CEA, AFP, S-100, thrombomodulin and PLAP. Focal smooth muscle in the stroma was positive for desmin and SMA. Thus, on the basis of the histological and immunohistochemical features of the ovarian tumor reported here, and after exclusion of other differential diagnoses, the diagnosis of a cystadenofibroma of the RO can be established in this case. To summarize, to the best of our knowledge, this is a rare case of cystadenofibroma of the rete ovarii in a 75-year old woman.

References

1. Rutgers JL, Scully RE. Cysts (cystadenomas) and tumours of rete ovarii. *Int J Gynec Pathol* 1988;7:330-42.
2. Long GG. Apparent mesonephric duct (rete anlage) origin for cysts and proliferative epithelial lesions in the mouse ovary. *Toxic Pathol* 2002;3:592-8.
3. Heatley MK. Adenomatous hyperplasia of the rete ovarii. *Histopathol* 2000;36:383-4.
4. Jones EC, Murray SK, Young RH. Cysts and epithelial proliferations of the testicular collecting system (including rete testis). *Semin Diagn Pathol* 2000;17:270-93.
5. Devouassoux-Shisheboran M, Silver SA, Tavassoli FA. Wolffian Adnexal Tumor, so called female adnexal tumour of probable Wolffian origin (FATWO): immunohistochemical evidence in support of a Wolffian origin. *Hum Pathol* 1999;30:856-63.
6. Woolnough E, Russol L, Khan MS, Heatley MK. An immunohistochemical study of the rete ovarii and epoophoron. *Pathol* 2000; 32:77-83.
7. Wenzel JGW, Odend'hal S. The mammalian rete ovarii: a literature review. *Cornell Vet* 1985;75:411-25.
8. Nogales FF, Carvia RE, Donné C, et al. Adenomas of the rete ovarii. *Hum Pathol* 1997;28:1428-33.
9. Mooney EE, Nogales FF, Bergeron C, et al. Retiform Sertoli-Leydig cell tumours: clin-

- ical, morphological and immunohistochemical findings. *Histopath* 2002;41:110-7.
10. Nogales FF, Stolnicu S, Harilal KR, et al. Retiform uterine tumours resembling ovarian sex cord tumours. A comparative immunohistochemical study with retiform structures of the female genital tract. *Histopath* 2009;54:471-7.
 11. Khan MS, Dodson AR, Heatley MK. Ki-67, oestrogen receptor and progesterone receptor proteins in the human rete ovarii and in endometriosis. *J Clin Pathol* 1999;52:517-20.
 12. Fridman E, Skarda J, Moravsky EO, et al. Complex multilocular cystic lesion of rete testis, accompanied by smooth muscle hyperplasia, mimicking intratesticular Leydig cell neoplasm. *Virchows Arch* 2005;447:768-71.
 13. Hartwick RWJ, Ro JY, Srigley JR, et al. Adenomatous hyperplasia of the rete testis. A clinicopathologic study of nine cases. *Am J Surg Pathol* 1991;15:350-7.
 14. Nistal M, Castillo MC, Regadera J, et al. Adenomatous hyperplasia of the rete testis. A review and report of new cases. *Histol Histopathol* 2003;18:741-52.
 15. O'Neil CJ, Deavers MT, Malpic A, et al. An immunohistochemical comparison between low grade and high grade ovarian serous carcinomas: significantly higher expression of p53, MIB-1, Bcl-2, Her2/neu, and C-KIT in high grade neoplasms. *Am J Surg Pathol* 2005;29:1034-41.
 16. Rosai J. Rosai and Ackerman's Surgical Pathology, 9th ed. India, Elsevier; 2004. Chapter 19, Ovary; pp 1649-736.
 17. Young RH, Scully RE. Ovarian tumours of probable Wolffian origin. A report of 11 cases. *Am J Surg Pathol* 1983;7:125-35.