

# Mini-slings – an option in stress urinary incontinence treatment. Case studies

Mariusz Blewniewski, Michał Markowski, Rafał Kliś, Waldemar Różański

*2<sup>nd</sup> Department of Urology, Medical University of Łódź, Poland*

**Citation:** Blewniewski M, Markowski M, Kliś R, Różański W. Mini-slings – an option in stress urinary incontinence treatment. Case studies. Cent European J Urol. 2015; 68: 68-71.

## Article history

Submitted: April 14, 2014

Accepted: Aug. 26, 2014

Published on-line:

March 13, 2015

## Corresponding author

Mariusz Blewniewski

2<sup>nd</sup> Department

of Urology

Medical University of Łódź

62, Pabianicka Street

93–513 Łódź, Poland

phone: +48 42 689 52 11

urologia@poczta.onet.pl

**Introduction** Stress urinary incontinence (SUI) is a social disease caused by numerous contributing factors such as natural childbirth, obesity, hormonal deficiencies and changes in collagen fibers, to name a few. Currently, mini-slings, among all the surgical treatment methods, have gained significance. The aim of this study was to establish the effectiveness of this method.

**Material and methods** From 2008 to 2012, one hundred sixty women suffering from SUI underwent surgical procedures to implant mini-slings under the middle part of the urethra and 140 (87.5%) of them remained under observation. In 65 cases, Johnson & Johnson's TVT-Secur was used; in 70 cases, BARD's Adjust mini-sling was used; and in 5 cases, AMS Mini-Arc mini-sling was used. The average period of hospitalization was 3 days per admission, operation and discharge day.

**Results** In 82 cases, patients urinated well after the removal of the catheter, and had full urine continence. Fourteen patients showed great improvement, and in four cases temporary urine retention was observed. In two cases vaginal bleeding was observed, yet there was no need for wound revision. Evaluation of the 'quality of life improvement' was done using the Visual Analog Scale (VAS).

**Conclusions** The obtained results allowed the conclusion that the implantation of mini-slings is a low invasive, relatively safe and effective procedure for the treatment of SUI even in cases of recurrence. Almost full recovery was achieved in all the cases of this study. The mini-sling has become an important element in modern urogynecology.

**Key Words:** stress urinary incontinence <> mini-sling <> surgical treatment

## INTRODUCTION

Stress urinary incontinence (SUI) is a social disease caused by numerous contributing factors such as natural childbirth obesity, hormonal deficiencies and changes in collagen fibers, to name a few. As a result of these causes, the renal pelvis and urethra sag. Inadequate activity of the external urethral sphincter is the additional factor [1]. There are various methods of treatment for SUI depending on how advanced the condition is [2]. At present, the implantation of mini-slings is gaining recognition as a method of treating SUI [3, 4]. The objective of this study was to assess the effectiveness of this method using specific materials in the treatment of SUI.

## MATERIAL AND METHODS

In the years 2007 to 2011, there were 160 women surgically treated for SUI, and 140 (87.5%) of them remained under observation. The average age of the patients was 62 years (36–85); the average body mass index was 28 (25–33); the average amount of births was of 2.5 per patient (0–4), and 75% of them were post-menopausal. Their treatment consisted of the implantation of mini-slings under the mid-section of the urethra. In the pre-surgical prep stage, various physical tests were done, such as the urinary stress test, and abdominal USG to determine the residual urine after urination; in addition to a urodynamic exam and urine culture tests. The pre-surgical USG

did not reveal any residual urine after urination, and excluded other bladder conditions while the urodynamic exam excluded an overactive bladder condition. In 40 cases, first degree SUI was diagnosed; in 70 cases, second degree; in 30 cases, third degree, and in 30 cases there were mixed symptoms of SUI. In 20 patients it was noted that second degree SUI had returned after earlier surgical treatment: six patients had undergone the Burch colposuspension; seven, the Pereyra needle suspension procedure; seven, intravaginal slingplasty (IVS). Those patients having mixed symptoms had been treated with 5 or 10 mg of solifenacin for 4 weeks before qualifying for surgical treatment. In the case of first degree SUI, all patients were first referred to rehab and physical therapy; however, without satisfying effect. Among patients treated with mini-slings Johnson & Johnson's TVT-Secur tape was implanted in 65 cases; Bard's Adjust mini-sling in 70 cases; and AMS's Mini-Arc in just 5 cases. The TVT-Secur is a mesh tape secured to tissue on the rear surface of the descending branch of the pubic bone (Figure 1). When Adjust tape is implanted, the tape is anchored in the obturator foramen. (Figure 2). The Mini-Arc is anchored to the obturator internus muscle (Figure 3). The surgical procedure was carried out under short intravenous anesthesia. The average hospital stay was three days. The urinary catheter was left in place for 24 hours after the procedure. Patients

assessed their improvement on a VAS scale, in addition to gynecological and urinary stress tests. All patients reported to the 2<sup>nd</sup> Department of Urology in Łódź for 1 month, 3 month, 6 month and 1 year check-ups after the surgical procedure.

## RESULTS

There was major improvement in all the women after the surgical procedure. The effectiveness of the procedure was assessed on the basis of the urinary stress test and the VAS. After the removal of the catheter, 115 patients were able to urinate properly and were fully able to retain their urine during a gynecological examination and urinary stress test. In the case of 25 patients, there was a major improvement with significant reduction of SUI symptoms rated on the basis of interviews and the VAS. In 9 cases, temporary urine retention occurred and confirmed by USG examination (5 with TVT-Secur tape, 3 with Adjust tape, 1 with Mini-Arc tape). For these cases, Foley catheters were inserted into the bladder for a period of 5 to 7 days. In one case, as a result of chronic urine retention, the patient was discharged home with the catheter in place (a TVT-Secur recipient). The catheter was removed 14 days later at our department. During this time the patient passed urine normally. In 4 cases post-operative vaginal bleeding was observed, but surgical intervention or post-opera-

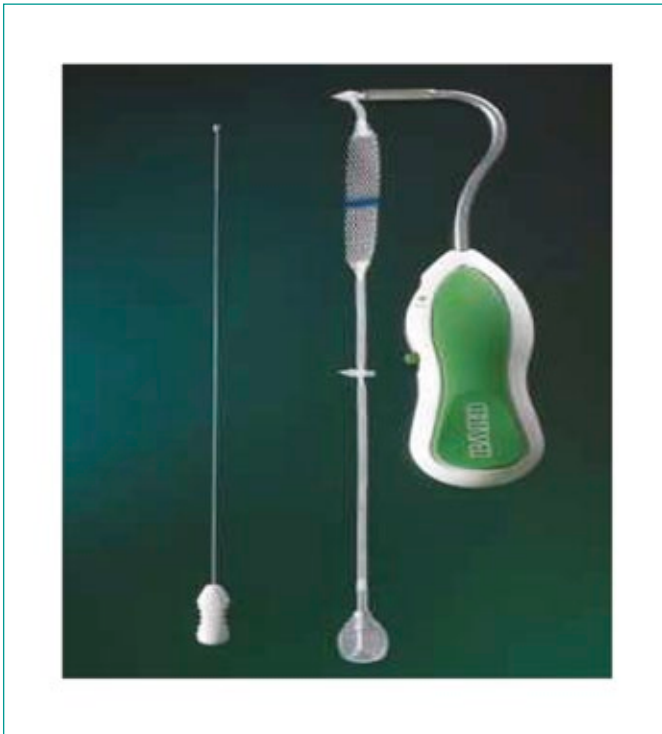

Figure 1. A-Just.



Figure 2. Mini Arc.




Figure 3. TVT Secur.

Table 1. Cumulative results of mini-sling procedures for SUI of different authors compared to own results

Author	TVT–Secur	Mini–Arc	Adjust	Full recovery/partial (%)
Blewniewski	65	5	70	86.15/13.85 60/40 92.86/7.14
Moor, et al.		61		91.4
Debodiance, et al.		72		69.1/20.6
Meschia, et al.	91			78
Khandwala, et al.	141			82/11
Abdel–Fattah, M et al.			90	80

tive revision was unnecessary (2 with Adjust tape, 2 with TVT–Secur tape). Assessing the improvement of life quality was done with the use of the VAS. The Visual Analogue Scale (VAS) is a common form of response option in health outcome studies and is generally presented as a single line of 100 mm with anchor words at either end. The average rating before the surgical procedure was 3, whereas the rating increased to an average of 8.5 after the implantation of the mini-slings. During the following 12 months of monitoring, the VAS ratings were not changed by the patients, nor were there any recurrences of the condition (Table 1).

## DISCUSSION

In our study 3 out of 5 (60%) fully recovered when treated with the Mini–Arc sling.

Moor and his associates observed full recovery after the Mini–Arc implantation in 91.4% of patients suffering from SUI [5]: there were no recorded intra or postoperative complications, nor complaints of strong pain or observed urinary retention.

Debodiance and Delporte utilized Mini–Arc tape for 72 patients [6]. The average period for monitoring those patients was 12 months. Full recovery was observed in 69.1%, while partial recovery was observed in 20.6% of patients who underwent the procedure. For 10.3% of the patients, no improvement was gained. The authors noted one incident of urinary infection after the procedure and one incident of urinary incontinence de novo.

In operations with the usage of TVT–Secur there was shown that 56 out of 65 (86.15%) patients gained full recovery. In the work of Meschia and associates, full recovery was noted in 78% of cases after surgical treatment using the TVT–Secur system [7]. The postoperative rating was a subjective patient assessment, which noted minor complications after surgery including disorders in urination, urinary infection and urinary incontinence de novo. In Khandwala and associates' study, 141 women suffering with SUI took part in the study where TVT–Secur tape was the chosen material for implantation [8]. Full recovery was noted in 82% of the cases, while partial recovery in 11%, and no improvement in 7%. The authors did not note any complications.

Results of our study show that 65 out of 70 (92.86%) treated with Adjust tape gained full recovery. According to M. Abdel–Fattah and associates, in their prospective multicenter study there was determined the effectiveness and safety of the Adjust method was determined [9]. In the post–procedure 12 month monitoring period, improvement was noted in 80% of the patients. The authors also undertook further study to determine results concerning the use of local anesthesia *vs.* general anesthesia for the procedure. They found that there was less blood loss and fewer problems with urination, percentage wise, when the procedure was performed under local anesthesia. The percentage difference was statistically significant.

Among early complications noted were vaginal bleeding (4 patients) which did not require surgical intervention or blood transfusions; and temporary urine retention in 10 patients. During the procedures, there was no damage done to the bladder, urethra, large blood vessels or nerves.

## CONCLUSIONS

Presented results allow us to draw the following conclusions: implantation of mini-slings is an effective,

minimally invasive and relatively safe method of SUI treatment. In almost all cases full recovery was noted, especially in the group where SUI had reoccurred in patients having previous procedures once rated

as 'gold standard' performed. Mini-slings may become an important fixture in modern urogynecology and may possibly be named the 'gold standard' in treating SUI.

## References

1. Reynolds WS, Dmochowski RR, Penson DF. Epidemiology of stress urinary incontinence in women. *Curr Urol Rep.* 2011; 12: 370–376.
2. Blewniewski M, Róžański W, Markowski M. Evaluation of effectiveness of intravaginal slingplasty (IVS) in women with urinary incontinence. Four-year follow-up. *Urol Pol.* 2007; 60: 125–128.
3. Meschia M, Barbacini P, Baccichet R, Buonaguidi A, Maffiolini M, Ricci L, et al. Short-term outcomes with the Adjust system: a new single incision sling for the treatment of stress urinary incontinence. *Int Urogynecol J.* 2011; 22: 177–182.
4. De Ridder D, Berkens J, Deprest J, Verguts J, Ost D, Hamid D, Van der Aa F. Single incision mini-sling versus transobturator sling: a comparative study on MiniArc and Monarc slings. *Int Urogynecol J.* 2010; 21: 773–778.
5. Moore RD, Mitchell GK, Miklos JR. Single-center retrospective study of the technique, safety, and 12-month efficacy of the MiniArc single-incision sling: a new minimally invasive procedure for treatment of female SUI. *Surg Technol Int.* 2009; 18: 175–181.
6. Debodiance P, Delporte P. Miniarc: prospective study and follow up at one year about 72 patients. *J Gynecol Obstet Biol Reprod.* 2010; 39: 25–29.
7. Meschia M, Barbacini P, Ambrogi V, Pifarotti P, Ricci L, Spreafico L. TVT-secur: a minimally invasive procedure for the treatment of primary stress urinary incontinence. One year data from a multi-centre prospective trial. *Int Urogynecol J Pelvic Floor Dysfunct.* 2009; 20: 313–317.
8. Khandwala S, Jayachandran C, Sengstock D. Experience with TVT-SECUR sling for stress urinary incontinence: a 141-case analysis. *Int Urogynecol J.* 2010; 21: 767–772.
9. Abdel-Fattah M, Agur W, Abdel-All M, Guerrero K, Allam M, Mackintosh A, et al. Prospective multi-centre study of adjustable single-incision mini-sling (Ajust®) in the management of stress urinary incontinence in women: 1-year follow-up study. *BJU Int.* 2012; 109: 880–886. ■