



OPEN ACCESS

Case report

HHV-8-negative multicentric Castleman disease presenting as a crescentic immune complexes membranoproliferative glomerulonephritis

Maria Brito Nunes,¹ Samuel Rotman,² Francois-Regis Duss,¹ Matthieu Halfon³

¹Internal Medicine, Centre Hospitalier Universitaire Vaudois, Lausanne, Switzerland

²Institute of Pathology, Centre Hospitalier Universitaire Vaudois, Lausanne, Switzerland

³Nephrology, Centre Hospitalier Universitaire Vaudois, Lausanne, Switzerland

Correspondence to

Dr Maria Brito Nunes;
lucilia.b.nunes@gmail.com

Accepted 18 November 2019

SUMMARY

Multicentric Castleman disease is a rare polyclonal lymphoproliferative disorder mainly associated with two renal manifestations: thrombotic microangiopathy and amyloidosis. Nevertheless, we report here a case of human herpes virus-8 negative multicentric Castleman disease with membranous proliferative glomerulonephritis and extracapillary proliferation. A patient was successfully treated with corticosteroids, anti-CD20 and cyclophosphamide therapy.

BACKGROUND

Castleman disease is a rare^{1,2} polyclonal lymphoproliferative disorder characterised by three histological patterns: hyaline vascular, plasma cell and plasmablastic.² Clinical presentation is heterogeneous² and classified into unicentric or multicentric disease.^{1,2} Unicentric Castleman disease is the most frequent type.³ It involves a single lymph nodal region, and symptoms are mainly due to local lymph node enlargement.³ Its surgical resection is curative.³ By contrast, multicentric Castleman disease involves multiple lymph node areas.⁴⁻⁶ It is subclassified into the human herpes virus-8 (HHV-8) related or not.⁵⁻⁷ Multicentric Castleman disease is a severe multisystemic disease, with non-specific symptoms such as lymphadenopathy, fever, weight loss, fatigue, oedema and ascites.^{3,8} The high level of cytokines production, notably interleukin-6 (IL-6),⁷ can affect each system and eventually lead to multiorgan failure.⁶ IL-6 pathway is the therapeutic target.^{3,5,9,10} Nevertheless, recurrence is frequent and prognosis poor.¹⁰ Renal involvement is also common¹¹ and various histological patterns have been described. A membranous proliferative glomerulonephritis has been previously reported, nevertheless extracapillary proliferation has not been described yet.

CASE PRESENTATION

A 48-year-old man from the Middle East presented to our hospital because of night sweats, lower extremity oedema and a weight loss of 12 kg in 3 months.

He had a medical history of dyslipidaemia, severe obesity (body mass index of 35 kg/m²) and 25 pack-year of previous smoking. 2.5 months before admission, he was admitted to another hospital because of an acute left limb pain. A multisegmental artery

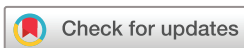occlusion of the limb was then diagnosed which justified an anticoagulation by vitamin K antagonist.

The patient had no other complaints. Except for increased blood pressure and bilateral pitting oedema, clinical examination was normal.

INVESTIGATIONS

Blood test showed acute kidney injury (creatinemia 200 µmol/L) with hypoalbuminaemia (26 g/L), an elevated sedimentation rate (>100 mm/hour) and elevated CRP (90 mg/L). Urinalysis showed erythrocytes cast. Twenty-four hour urine protein excretion was 9.24 g/day. Finally, a kidney ultrasound with Doppler showed no anomaly. Because of the nephritic syndrome, a renal biopsy was performed. On microscopic examination (23 glomeruli), we observed a membranous proliferative pattern with the presence of a crescent (figures 1 and 2). Immunofluorescence was positive for IgA (+/-, rare deposits), IgG (++), IgM (+/-), C3 (+++), C1q (++) and C5b9 (+/-) deposits (full house), but kappa and lambda light chains were negative (figures 3 and 4). The electron microscopy disclosed the presence of subendothelial and subepithelial deposits. We estimated between 20% and 30% of fibrosis. At this stage, a crescentic immune complex glomerulonephritis with a membranoproliferative pattern was suspected.

The immunological workup was negative: absence of monoclonal spike but a polyclonal hypergammaglobulinaemia on the immunofixation; negative antinuclear antibodies and antineutrophil cytoplasmic antibody, normal C3 and C4 as well as the absence of cryoglobulinaemia and antiphospholipid antibodies. An exhaustive infectious workup was also done with negative polymerase chain reaction (PCR) for cytomegalovirus (CMV), Epstein-Barr virus (EBV), hepatitis B, C, HIV and HHV-8, negative bacterial serologies for leptospirosis, *Brucella* spp, *Borrelia burgdorferi*, *Coxiella burnetii*, *Bartonella henselae*, syphilis, as well as toxoplasma. Finally, interferon-gamma release assay was negative as well as urine culture for mycobacteria. Blood culture was also sterile; beta-D-glucan in the blood was negative. Although, a high level of IL-6 (18.5 µg/L, n<1 µg/L) prompted us to search for an inflammatory process. A 2-fludeoxyglucose (2-FDG) positron emission tomography scan revealed supra and subdiaphragmatic hypercaptative adenopathies, a mediastinal mass hypercaption,



© BMJ Publishing Group Limited 2020. Re-use permitted under CC BY-NC. No commercial re-use. See rights and permissions. Published by BMJ.

To cite: Nunes MB, Rotman S, Duss F-R, et al. *BMJ Case Rep* 2020;**13**:e231844. doi:10.1136/bcr-2019-231844

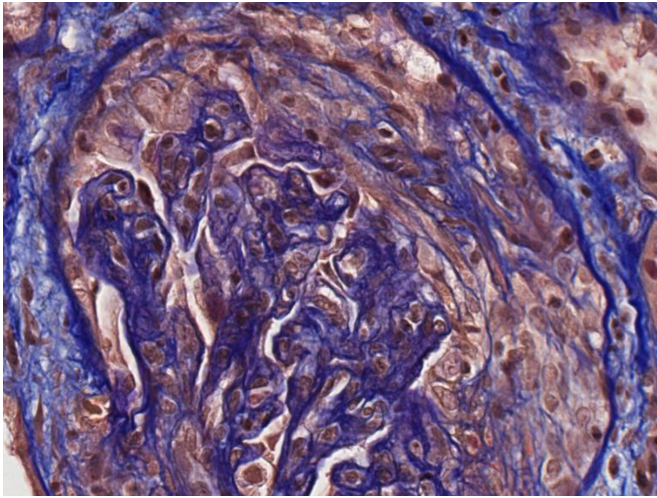


Figure 1 Renal biopsy showed an extracapillary proliferation with cellular crescents (FAOG, ×400). FAOG, femtosecond amplifying optical gate.

and a splenic abnormal FDG uptake. A left axillary lymph node resection was performed. Pathology determined a Castleman-like pattern with hyperplastic adenopathy, associated with follicular hyperplasia, interfollicular expansion and significant polyclonal plasma cells and circularly capillary penetrated some germinal centres. There was no evidence of lymphoma. HHV-8 and EBV immunohistochemistry were negative. Moreover, fewer than 10% of plasma cells were IgG4 positive.

DIFFERENTIAL DIAGNOSIS

We concluded that this patient suffered from HHV-8 negative multicentric Castleman's disease. Treatment was initiated with corticosteroids, anti-CD 20 therapy with rituximab and cyclophosphamide.

In our case, due to the absence of monotypic deposits, a monoclonal gammopathy of renal significance is easily excluded. In the absence of a predominant C3 deposits, a C3 glomerulopathy seems unlikely. The full-house pattern points to two hypotheses: lupus nephritis or an infectious glomerulonephritis.

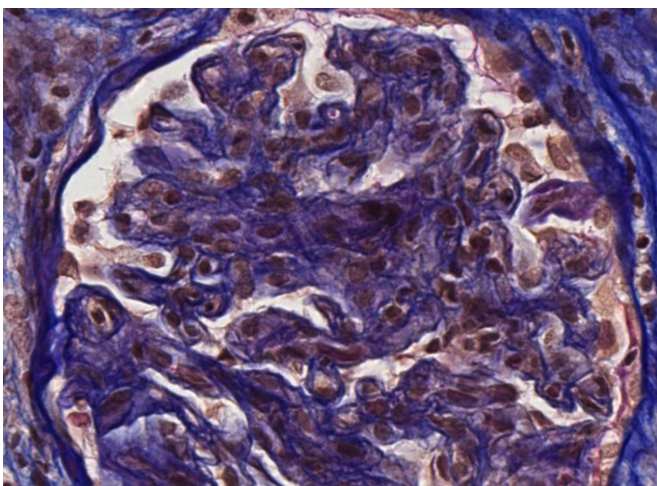


Figure 2 Renal biopsy showed a membranoproliferative glomerulonephritis pattern: flocculi are lobulated with a duplication of the membrane. Endocapillary and extracapillary proliferations were also observed.

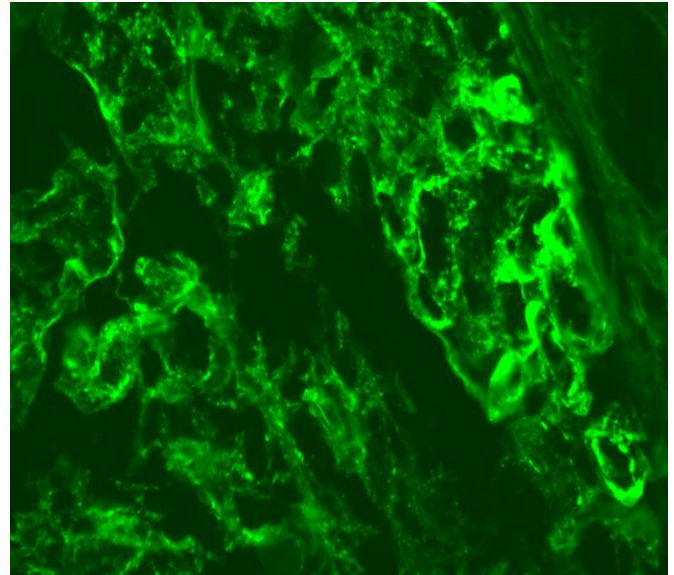


Figure 3 Immunofluorescence: IgG deposits were observed within mesangium and membranes of glomeruli (×400).

In the absence of signs or symptoms of lupus and antinuclear antibodies, a diagnosis of lupus nephritis is excluded. Finally, an infection-related glomerulonephritis is unlikely because of the negativity of the full infectious workup. Moreover, improvement of the clinical status under a strong immunosuppressive therapy does not suggest an infectious process and supports that Castleman disease is the only possible aetiology.

Therefore, we concluded that the crescentic immune complex glomerulonephritis with a membranoproliferative pattern was secondary to multicentric Castleman disease.

OUTCOME AND FOLLOW-UP

The patient quickly improved: a few days after corticoids administration the fever and inflammatory markers decreased. A 2-FDG positron emission tomography scan was repeated 3 months later, which showed regression of the lymphadenopathies without hypercapitation. In parallel, proteinuria level decreased completely.

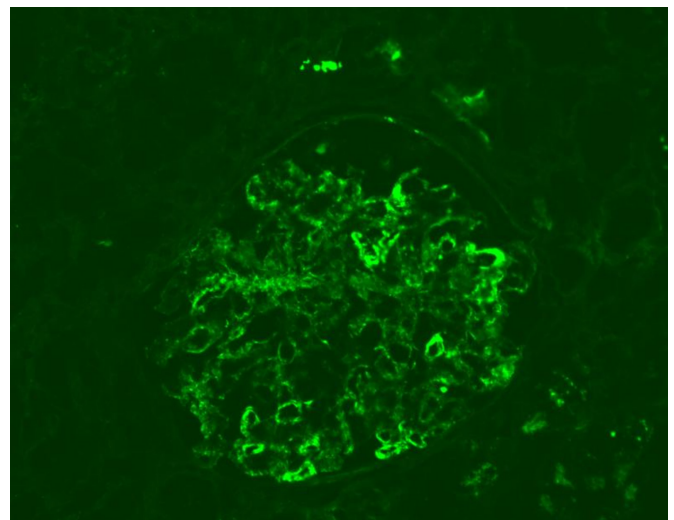


Figure 4 Immunofluorescence: C3 deposits were observed within mesangium and membranes of glomeruli (×200).

after 2 months and renal function improved slowly. One year later, creatinaemia was 144 µmol/L.

DISCUSSION

Clinicians investigating membranoproliferative glomerulonephritis must do a comprehensive search to find the right aetiology and the nature of the immune deposit is the principal clue.

Up to 54% of multisystemic Castleman disease, mostly in plasma cell or mixed cellular type, are associated with nephropathy, defined as haematuria, proteinuria or renal insufficiency.^{11–14} The two main histological patterns are thrombotic microangiopathy (60%) and amyloidosis (20%).^{15 16} Those histological patterns could be explained by the dysregulation of IL-6 production and vascular endothelial growth factors in the lymph node mantle.^{15 17–19} Indeed, IL-6 proinflammatory cytokine stimulates the precursor of the AA protein and vascular endothelial growth factors, leading to thrombotic microangiopathy.^{20 21}

Nevertheless, our patient had proliferative immune complex glomerulonephritis. We hypothesised that the high level of IL-6 promoted B cell activation, which in turn induced immune complexes. Those immune complexes get ‘trapped’ in the subendothelial space of the glomeruli and lead to a proliferative glomerulonephritis.

In the recent years, new treatments for HHV-8-negative/idiopathic multicentric Castleman disease (iMCD) have been developed, such as anti-IL-6 monoclonal antibody (anti-IL-6 mAb) siltuximab or tocilizumab.^{9 22} They are now considered as preferred first-line therapy,²² sometimes in association with corticosteroid.²² Anti-CD20 mAb (rituximab) is an alternative to anti-IL-6 mAb in the case of non-severe iMCD (defined as a good performance status without organ dysfunction), however, with a lower proportion of complete responses and progression-free survival compared with siltuximab.²³

Patient's perspective

The experience of sickness, the lose of strength, especially when you are a man of 48 years old, is hard to accept. I did not understand what was wrong with my body. I was afraid to die. During hospitalisation doctors had to performed a lot of tests to find out why I was losing weight and why my kidneys were failing. Then, I was shocked to learn that I had a rare disease called Castleman disease. I asked myself several times : why me? With the help of the medical team I understood better my disease and I started a treatment. At the end, I feel lucky because the treatment improved my condition and my kidneys function, and I have the support of my family. Currently I have almost a normal life.

Learning points

- ▶ Castleman disease is a rare non-neoplastic lymphoproliferative disorder characterised by various renal manifestations with two main histological patterns: thrombotic microangiopathy and amyloidosis.
- ▶ Castleman disease is also a possible aetiology for a proliferative immune complex glomerulonephritis after exclusion of other frequent causes such as infection-related glomerulonephritis.
- ▶ The anti-interleukin-6 monoclonal antibody, siltuximab or tocilizumab are considered as first-line treatment for human herpes virus-8-negative/idiopathic multicentric Castleman disease.

Contributors MBN and F-RD conceived the design of the article, the background and clinical presentation; SR described and analysed the biopsy findings and selected the pictures. MH wrote the differential diagnosis and follow-up. All the authors participated to the discussion. SR, F-RD and MH revised the article.

Funding The authors have not declared a specific grant for this research from any funding agency in the public, commercial or not-for-profit sectors.

Competing interests None declared.

Patient consent for publication Obtained.

Provenance and peer review Not commissioned; externally peer reviewed.

Open access This is an open access article distributed in accordance with the Creative Commons Attribution Non Commercial (CC BY-NC 4.0) license, which permits others to distribute, remix, adapt, build upon this work non-commercially, and license their derivative works on different terms, provided the original work is properly cited and the use is non-commercial. See: <http://creativecommons.org/licenses/by-nc/4.0/>.

REFERENCES

- 1 Blute ML, Abramson JS, Cronin KC, *et al*. Case 5-2017. A 19-year-old man with hematuria and a retroperitoneal mass. *N Engl J Med* 2017;376:684–92.
- 2 Jiang JP, Shen XF, JF D, *et al*. A retrospective study of 34 patients with unicentric and multicentric Castleman's disease: experience from a single institution. *Oncol Lett* 2018;15:2407–12.
- 3 van Rhee F, Stone K, Szmania S, *et al*. Castleman disease in the 21st century: an update on diagnosis, assessment, and therapy. *Clin Adv Hematol Oncol* 2010;8:486–98.
- 4 Oksenhendler E, Boutboul D, Fajgenbaum D, *et al*. The full spectrum of Castleman disease: 273 patients studied over 20 years. *Br J Haematol* 2018;180:206–16.
- 5 Fajgenbaum DC, Ruth JR, Kelleher D, *et al*. The collaborative network approach: a new framework to accelerate Castleman's disease and other rare disease research. *The Lancet Haematology* 2016;3:e150–2.
- 6 Fajgenbaum DC, Uldrick TS, Bagg A, *et al*. International, evidence-based consensus diagnostic criteria for HHV-8–negative/idiopathic multicentric Castleman disease. *Blood* 2017;129:1646–57.
- 7 Fajgenbaum DC, Shilling D. Castleman disease pathogenesis. *Hematol Oncol Clin North Am* 2018;32:11–21.
- 8 Liu AY, Nabel CS, Finkelman BS, *et al*. Idiopathic multicentric Castleman's disease: a systematic literature review. *Lancet Haematol* 2016;3:e163–75.
- 9 van Rhee F, Wong RS, Munshi N, *et al*. Siltuximab for multicentric Castleman's disease: a randomised, double-blind, placebo-controlled trial. *Lancet Oncol* 2014;15:966–74.
- 10 Dispenzieri A, Armitage JO, Loe MJ, *et al*. The clinical spectrum of Castleman's disease. *Am J Hematol* 2012;87:997–1002.
- 11 El Karoui K, Vuiblet V, Dion D, *et al*. Renal involvement in Castleman disease. *Nephrol Dial Transplant* 2011;26:599–609.
- 12 Xu D, Lv J, Dong Y, *et al*. Renal involvement in a large cohort of Chinese patients with Castleman disease. *Nephrol Dial Transplant* 2012;27:iii119–25.
- 13 Nakamori A, Akagaki F, Yamaguchi Y, *et al*. Nephrotic syndrome with thrombocytopenia, lymphadenopathy, systemic inflammation, and splenomegaly. *Intern. Med.* 2018;57:1123–9.
- 14 Yuan X-G, Hu W, Chen F-F, *et al*. Renal complications of Castleman's disease: report of two cases and analysis of 75 cases. *Clin Exp Nephrol* 2011;15:921–6.
- 15 Seida A, Wada J, Morita Y, *et al*. Multicentric Castleman's disease associated with glomerular microangiopathy and MPGN-like lesion: does vascular endothelial cell-derived growth factor play causative or protective roles in renal injury? *Am J Kidney Dis* 2004;43:e1.1–e1.7.

- 16 Mizuno H, Sekine A, Oguro M, *et al.* Renal histology in a patient with TAFRO syndrome: a case report. *Hum Pathol* 2018;82:258–63.
- 17 Nishimoto N, Kanakura Y, Aozasa K, *et al.* Humanized anti–interleukin-6 receptor antibody treatment of multicentric Castleman disease. *Blood* 2005;106:2627–32.
- 18 Yoshizaki K, Murayama S, Ito H, *et al.* The role of interleukin-6 in Castleman disease. *Hematol Oncol Clin North Am* 2018;32:23–36.
- 19 Sui Y, Zhao D. Report of six kidney disease-associated Castleman’s disease cases. *Clin Nephrol* 2015;84:344–52.
- 20 Perfetti V, Bellotti V, Maggi A, *et al.* Reversal of nephrotic syndrome due to reactive amyloidosis (AA-type) after excision of localized Castleman’s disease. *Am J Hematol* 1994;46:189–93.
- 21 Ikeda S, Chisuwa H, Kawasaki S, *et al.* Systemic reactive amyloidosis associated with Castleman’s disease: serial changes of the concentrations of acute phase serum amyloid A and interleukin 6 in serum. *J Clin Pathol* 1997;50:965–7.
- 22 van Rhee F, Voorhees P, Dispenzieri A, *et al.* International, evidence-based consensus treatment guidelines for idiopathic multicentric Castleman disease. *Blood* 2018;132:2115–24.
- 23 Yu L, Tu M, Cortes J, *et al.* Clinical and pathological characteristics of HIV- and HHV-8–negative Castleman disease. *Blood* 2017;129:1658–68.

Copyright 2020 BMJ Publishing Group. All rights reserved. For permission to reuse any of this content visit <https://www.bmj.com/company/products-services/rights-and-licensing/permissions/>
BMJ Case Report Fellows may re-use this article for personal use and teaching without any further permission.

Become a Fellow of BMJ Case Reports today and you can:

- ▶ Submit as many cases as you like
- ▶ Enjoy fast sympathetic peer review and rapid publication of accepted articles
- ▶ Access all the published articles
- ▶ Re-use any of the published material for personal use and teaching without further permission

Customer Service

If you have any further queries about your subscription, please contact our customer services team on +44 (0) 207111 1105 or via email at support@bmj.com.

Visit casereports.bmj.com for more articles like this and to become a Fellow