

High-Flow Bypass with Radial Artery Graft for Cavernous Carotid Aneurysms: A Case Series

Abstract

Background: The incidence of cavernous carotid aneurysms (CCAs) of intracranial aneurysms is low. Majority of cases presented as incidental findings with benign natural progression. The most common presenting symptoms are multiple cranial neuropathies among symptomatic patients. The treatment modalities for symptomatic patients include direct surgical clipping, endovascular coil embolization, or placement of flow diverter, or indirect procedures such as occlusion of parent artery with and without revascularization techniques. The advancement in the microsurgical treatments and endovascular devices have enable a high success rate in the treatment of patients with CCAs with low morbidity and mortality rates. **Objective:** To study the surgical outcomes of patients with cavernous aneurysm who underwent high-flow bypass between 2015 and 2020 in our institution. **Materials and Methods:** A total of six patients in a single institution presented with CCAs who were treated with high-flow bypass surgery were included in this case-series. A single-case illustration was presented focusing on the details of surgical case management of CCA. The intraoperative middle cerebral artery (MCA) pressure monitoring during bypass surgery was also described. **Results:** All five female patients and one male patient who were diagnosed with cavernous carotid aneurysms were studied. The mean age was 68.8 years old (range: 24-84 years old) and the mean size of the aneurysm was 19.6mm (range: 9.7 – 30mm). There were successfully treated with high flow bypasses using radial artery graft without any neurological sequelae. **Conclusion:** The surgical treatments of cavernous carotid aneurysms should be limited to experienced neurosurgeons in view of significant risk of morbidity and mortality. Endovascular procedures may be the main stay of treatments. The success shown in this case series with parent artery occlusion and bypass surgery may provide an safe alternative to the endovascular treatment.

Keywords: Cavernous carotid aneurysms, high-flow bypass surgery, outcome

Introduction

Cavernous carotid aneurysms (CCAs) account for 2%–9% of all intracranial (IC) aneurysms.^[1,2] Bilateral CCAs are even more rare.^[3,4] It has a relatively benign natural history and most patients are often asymptomatic.^[5] However, there are those patients presented with multiple cranial neuropathies due to the mass effect. CCAs can rupture and resulting in direct cavernous-carotid fistula (CCF). This classified as Type A, direct high-flow CCF.^[5] They may also rupture into the subarachnoid space, which is considered one of the transitional variant causes of subarachnoid hemorrhage. It may also ruptures into the sphenoid air sinuses.^[5] Thromboembolic event from CCAs may be indication to treat small CCAs.^[6]

In the literature, the risk of 5-year rupture rates for CCAs is depending on their sizes. For CCA <13 mm, the risk of 5-year rupture rate is 0%, between 13 and 24 mm is 3% while those above 25 mm is 6.4%.^[7] The incidence of CCAs is higher in females than males.^[8] The possible etiologies include traumatic (the most common), infectious, or idiopathic.^[5,8] The risk factors for idiopathic CCAs include hypertension, cigarette smoking, genetics, and connective tissue diseases.^[5]

Non-contrasted computed tomography (CT) scan of the brain allows detecting of hemorrhage from CCA.^[5] The preferred neuroimaging in CCAs include three-dimensional (3D) reconstruction CT angiogram (CTA). The advantages of this imaging are measuring aneurysm

Riki Tanaka,
Boon Seng Liew,
Kento Sasaki,
Kyosuke Miyatani,
Tsukasa Kawase,
Yasuhiro Yamada,
Yoko Kato,
Akihiko Horiguchi¹

Department of Neurosurgery,
Fujita Health University
Bantane Hospital, ¹Department
of Gastroenterological Surgery,
Fujita Health University School
of Medicine, Bantane Hospital,
Nagoya, Japan

Address for correspondence:
Dr. Boon Seng Liew,
Department of Neurosurgery,
Fujita Health University
Bantane Hospital, Nagoya,
Japan.
E-mail: liew_bs@yahoo.com

Access this article online

Website: www.asianjns.org

DOI: 10.4103/ajns.AJNS_289_20

Quick Response Code:



This is an open access journal, and articles are distributed under the terms of the Creative Commons Attribution-NonCommercial-ShareAlike 4.0 License, which allows others to remix, tweak, and build upon the work non-commercially, as long as appropriate credit is given and the new creations are licensed under the identical terms.

For reprints contact: WKHLRPMedknow_reprints@wolterskluwer.com

How to cite this article: Tanaka R, Liew BS, Sasaki K, Miyatani K, Kawase T, Yamada Y, *et al.* High-flow bypass with radial artery graft for cavernous carotid aneurysms: A case series. Asian J Neurosurg 2020;15:863-9.

Submitted: 12-Jun-2020

Revised: 27-Jun-2020

Accepted: 29-Jul-2020

Published: 21-Dec-2020

dome dimensions, ostium size, and its relationship with the surrounding bony structures to look for any bone erosion.^[5] Magnetic resonance angiography (MRA) reduces the imaging artifacts from surrounding osseous structures. Hence, a higher accurate 3D images of the aneurysm can be reconstructed.^[5] The gold standard remains at digital subtraction angiogram (DSA) with temporal acquisition, and some with advanced rotational or 3D-DSA.^[5]

Treatment is indicated in all symptomatic CCAs. Treatments are also warranted in asymptomatic patients who presented with transitional variant with intradural component, extension into sphenoid sinus, origin from anterior genu of cavernous internal carotid artery (ICA) or if serial radiographic studies showing evidence of enlargement of the CCA on follow-up.^[8] The treatment options are shown in Table 1. The objective of this study is to evaluate the surgical outcomes of patients with cavernous aneurysm who underwent high-flow bypass between 2015 and 2020 in our institution.

Anatomical considerations

The cavernous segment of ICA giving rise to few arterial branches namely meningo-hypophyseal trunk, the inferolateral trunk, and capsular arteries of Mc Connell. The meningo-hypophyseal trunk consisting of inferior hypophyseal artery, tentorial artery (Bernasconi-Cassinari), and clival branches. The inferolateral trunk consisting of arteries branches that supply the cranial nerves (CN) of the cavernous sinus (CN VI in the sinus proper, and CN II and IV, ophthalmic [V1], and maxillary [V2] divisions of CN V in the lateral dural wall of cavernous sinus), the gasserian ganglion, and cavernous sinus dura. The capsular arteries of Mc Connell supply pituitary gland.^[5] Hence, consideration to the branches from cavernous segment of ICA when decided for the treatment of CCA.

Extracranial-IC (EC-IC) bypass surgery was first reported by Yasargil in 1969.^[9] High-flow EC-IC cerebral revascularization may be needed in the management of complex IC aneurysms.^[10] High-flow bypass followed by ICA ligation can achieve good clinical outcomes.^[11] The choice either to use a low-flow or high-flow bypass is determined by the availability of a supply source from the collateral supply and the anticipated cerebral blood flow needed.^[10]

Table 1: Treatment option for cavernous carotid aneurysms

Surgical	Endovascular
Parent vessel ligation	Endovascular occlusion of parent vessel
Parent vessel ligation with bypass	Coiling with or without stenting
Clipping	Flow diverters
Trapping	

Subjects and Methods

The surgical outcomes of six patients with cavernous aneurysm who underwent high-flow bypass since the past 5 years in our institution were presented in this case series. We have one case illustration describing in details of surgical steps in bypass surgery and trapping of the CCA. The intraoperative middle cerebral artery (MCA) pressure monitoring during bypass surgery was also described in details as an illustrative case.

Results

Case illustration

An 83-year-old female presented to the Fujita Health University Bantane Hospital, Nagoya, Japan, with the past medical history of chronic hypertension. She first presented in January 2020 with gradual worsening of double vision for the past few months. She did not suffer from any headache or blurring of vision. CTA was performed and left cavernous carotid aneurysm measuring 11.7 mm was detected. The decision was made for the surgical intervention due to its proximity to the anterior genu of the cavernous ICA.

She underwent left carotid-MCA high-flow bypass with radial artery graft (RAG) and trapping of the left ICA in March 2020. Postoperative follow-up in 3 months found that her double vision has improved. Postoperative MRA revealed complete resolution of the CCA and good flow within the bypass and left MCA circulation.

Below are the preoperative 3D-CT angiogram of cerebral circulation [Figure 1].

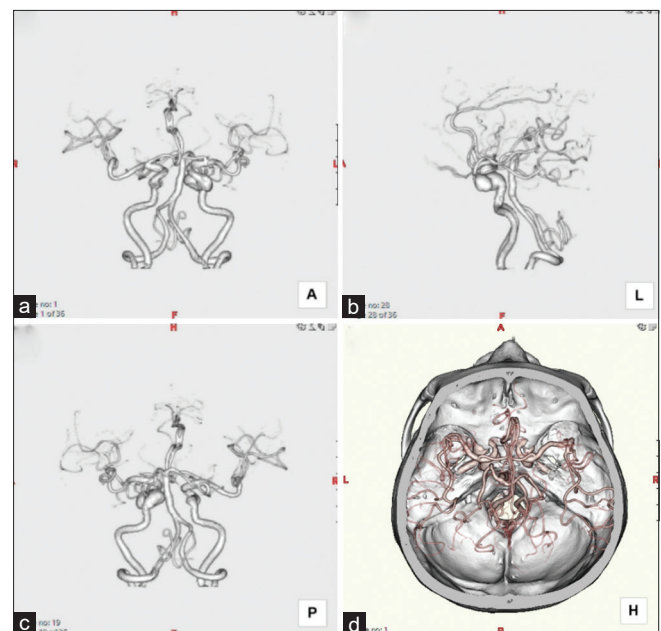


Figure 1: Preoperative three-dimensional computed tomography angiogram of the left internal carotid artery with cavernous carotid aneurysms (a: Anterior view; b: Left lateral view; c: Posterior view; d: Head view with bone window)



Figure 2: Illustration showing the positioning and skin markings (a) Minimal hair shaving with marking of the left frontotemporal scalp marking; (b) Skin marking of the neck skin incision along the skin crest and marking of the angle of the left mandible; (c) Skin marking on the left forearm of the underneath location of the radial artery localized by ultrasound Doppler

The surgical plans include the M3 segment of left MCA to superficial temporal artery (STA) end-side bypass, M2 segment of left MCA to left common carotid artery bypass using RAG; and trapping of the left CCA.

Surgical techniques

Positioning and incision, the patient was positioned in supine with the head rotated to the right about 45° with the head fixed with 3-pin head clamp and sandbag below the left shoulder. Minimal hair shaving along the intended incision site of the left frontotemporal skin flap [Figure 2].

Surgical steps: (i) superficial temporal artery-middle cerebral artery anastomosis (low-flow bypass)

The skin flap was elevated with careful separation of the anterior branch of the left STA from the scalp. The temporary clip was applied near the proximal end of STA (near the bifurcation of the main trunk) and the distal end of STA was cut and flushed with heparin saline. The dissection of the sylvian fissure with exposing the M3 segment of the left MCA. The preparation of the donor end of the STA with “fish mouth” incision was performed. The left MCA M3 arteriotomy done for the recipient site. STA-MCA anastomosis was performed with 10-0 monofilament nylon. The patency of the bypass was checked with indocyanine green (ICG) angiography and Doppler sonography [Figure 3].

Surgical steps: (ii) External carotid artery-middle cerebral artery anastomosis (high-flow bypass)

The neck linear skin incision along the skin crest across the junction of the left common carotid artery was performed. The distal left common carotid artery with proximal left external and internal carotid arteries were exposed. Skin incision along the ventral aspect of the left forearm exposing the left radial artery. DSA study was carried out earlier to check the adequate collateral blood supply by the ulnar artery. The harvested RAG with length at least 18 cm was flushed then with heparin saline [Figure 4].

A silicon tube was tunneled from the periauricular position through a passage of posterior part of the zygoma created by a drill toward the apex of cervical skin incision. The harvested radial artery was tunneled in the opposite direction within the silicon tube (for protection of the graft) toward cranial part. The preparation of the donor

site of the RAG on both ends with “fish mouth” incision was performed. The M2 segment of MCA was identified and M2 arteriotomy was performed. End to side RAG-M2 anastomosis was then performed with 10-0 monofilament nylon. The left external carotid arteriotomy was done for the recipient site. End to side RAG-external carotid artery (ECA) anastomosis was performed [Figure 4]. The patency of both bypasses was checked using ICG and Doppler sonography [Figure 5].

Surgical steps (iii) Intraoperative middle cerebral artery pressure monitoring

The assessment of intraoperative MCA pressure is important to ensure adequate brain perfusion especially in the MCA territory after the bypasses and occlusion of the ICA.

Table 2 shows illustrative case with the comparison of the systolic, diastolic, and mean arterial pressure between peripheral readings with the readings from the pressure transducer placed at the branch STA near to the M3. Ligation of proximal ICA with two 1.0 silk threads when the surgeon was satisfied with the patency of both bypasses and the MCA pressure at the baseline readings following temporary occlusion of ICA [Figure 6].

Intraoperative and postoperatively were uneventful. The patient was subsequently extubated without any immediate neurological deficits. Although the parent vessel was not ligated distally, the postoperative MRA showed disappearance of the thrombosed aneurysm and the proximal Left ICA with patency of STA-M3 and ECA-RA-M2 bypasses [Figure 7]. On follow-up on 3 and 6 months, no delayed neurological deficits or ischemic changes from the follow-up magnetic resonance imaging.

The illustrated case above was one of the six cases of cavernous aneurysm with high-flow bypass since the past 5 years in our institution [Table 3].

Discussion

The treatment options of CCAs are varies. These include direct treatment of the CCA itself, or indirect treatment options.^[12] The direct treatments include clipping of the aneurysm or endovascular coil embolization. Careful patient selection is crucial for optimal outcome with acceptable rates of morbidity. The indirect treatment options include

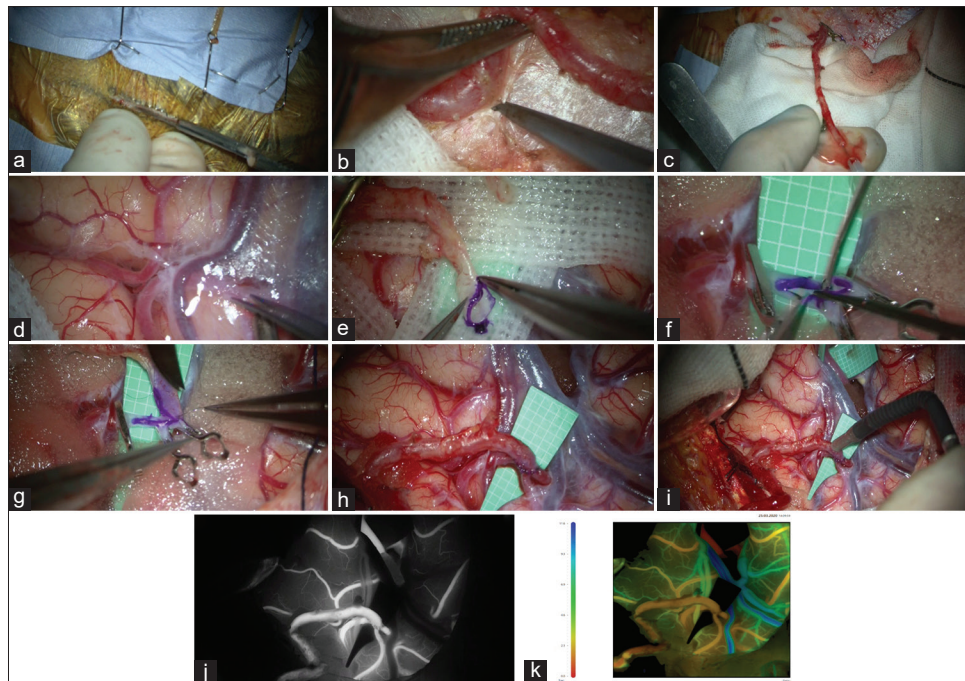


Figure 3: Superficial temporal artery-M3 anastomosis (a) Scalp incision; (b) Harvesting superficial temporal artery; (c) Harvested anterior branch of the superficial temporal artery with the main trunk; (d) Sylvian fissure dissection; (e) Preparation of donor end of the superficial temporal artery for anastomosis; (f) Left middle cerebral artery M3 arteriotomy; (g and h) superficial temporal artery-M3 end to side anastomosis; (i) Checking flow using micro-Doppler; (j) indocyanide green showing good superficial temporal artery-M3 blood flow; (k) Postsuperficial temporal artery-M3 bypass FLOW 800 analysis demonstrates yellow color indicating good artery blood flow

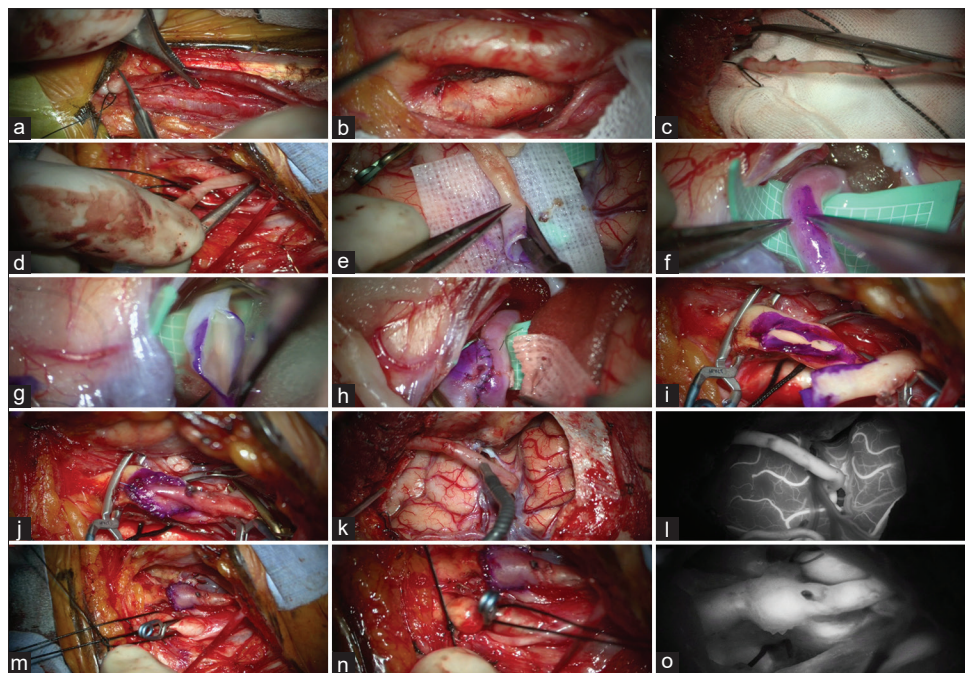


Figure 4: External carotid artery-radial artery graft-M2 bypass (a) harvesting left radial artery graft; (b) Exposing the distal left cavernous carotid aneurysms, proximal left external carotid artery and internal carotid artery; (c) and (d) Tunneling of the radial artery graft from cranial to neck; (e) Preparation of donor site of the radial artery graft; (f) Marking of M2 for arteriotomy; (g) Left middle cerebral artery M2 arteriotomy; (h) radial artery graft-M2 anastomosis; (i) Left external carotid arteriotomy; (j) End to side radial artery graft-external carotid artery anastomosis; (k) Checking the blood flow from radial artery graft to M2 using micro Doppler; (l) indocyanine green showing good flow from radial artery graft to the M2; (m and n) Double ligations of the proximal internal carotid artery; (o) indocyanine green showing blood flow within external carotid artery and external carotid artery - radial artery graft bypass with no flow in the internal carotid artery

Hunterian strategies (parent artery occlusion) with or without revascularization procedures.^[5] Asymptomatic

CCAs may be follow-up with expectant management unless sufficient evidence to suggest growth of the aneurysm.

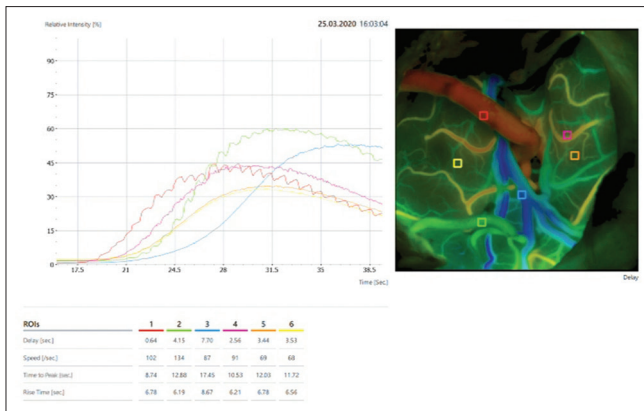


Figure 5: Intraoperative imaging of indocyanine green using Flow 800 showing radial artery graft-M2 blood flow in red color indicating good flow

Endovascular procedure with ICA trapping using detachable coils or stent-assisted coil embolization are an effective treatment modality in patients with CCAs.^[12,13] However, those with extremely tortuous course of ICA and the diameter of perianeurysmal ICA is more than 5.25 mm, then surgical option may be preferred.^[12] Endovascular treatment with pipeline embolization device (PED) is used for complex and broad-based CCAs.^[12] The main disadvantage of PED is the need to maintain antiplatelet and anticoagulation daily. The compliance and financial burden may be the hindrance for such procedure. Those patients with a history of idiopathic thrombocytopenic purpura, aspirin allergy, or a hypercoagulable state are contraindicated for PED.^[12]

Open surgery with clipping of the aneurysm is also usually performed if endovascular procedures failed. However, due to its proximity to CN, microsurgical reconstructive strategies for CCAs become difficult.^[5] The Hunterian strategies involving occlusion of ICA.^[5,14] This strategy is chosen when CAAs cannot be treated simply by direct neck clipping or endovascular coiling.^[15] The decision to utilize a low-flow or high-flow bypass or both is decided based on the anticipated degree of reduction of cerebral blood flow following ICA occlusion.^[16]

Balloon occlusion test (BOT) is needed to determine the adequacy of contralateral ICA (collateral cerebral circulation) without revascularization. Revascularization is needed if failed BOT.^[15,17] Those with incomplete Circle of Willis have higher chance of failure in BOT. Failure in BOT can be determined by xenon blood flow tomography when cerebral blood flow <30 ml/100 g/min, or when the patient develops neurological deficit during a 20-min parent artery occlusion.^[17] Balloon test occlusion should be performed with hypotensive challenge and acetazolamide challenge.^[18,19] Those surgical cases in this series have been selected for bypass surgery after failed BOT. The revascularization may be limited to only low-flow bypass or with high-flow bypass. Only low flow STA-MCA bypass is performed with successful BOT. The flow rate of

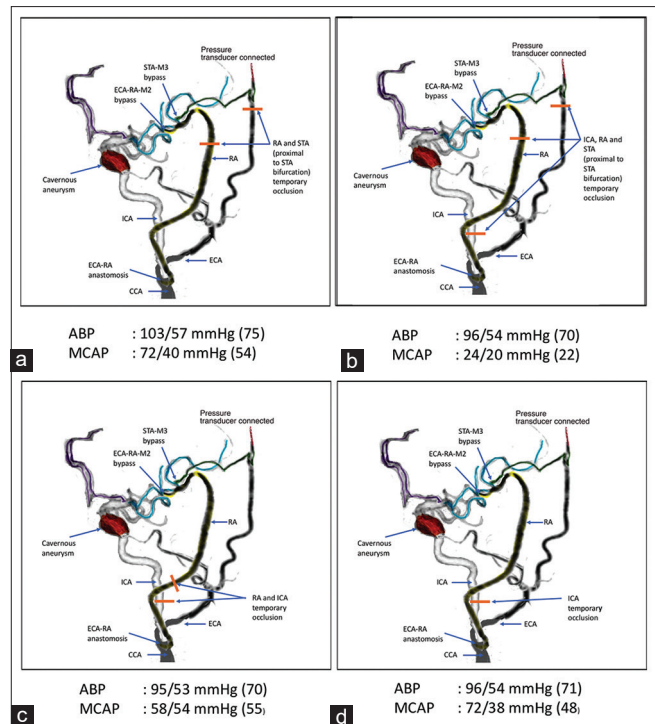


Figure 6: Illustrative case showing the comparison between peripheral arterial blood pressure with middle cerebral artery pressure. Without bypass. (a) Before internal carotid artery occlusion; (b) After internal carotid artery occlusion. (c) With superficial temporal artery-M3 flow but external carotid artery - radial artery graft-M2 occlusion; (d) with superficial temporal artery-M3 and external carotid artery - radial artery graft-M2 flow AND internal carotid artery occlusion

STA-MCA bypass is limited to <50 ml/min. Those failed BOT, high-flow bypass is necessary.^[19]

These deconstructive strategies are deployed when reconstructive or endovascular procedures are not feasible. The high-flow bypass is performed using RAG. In cases, where RAG cannot be used due to the poor collateral blood supply in the upper limbs or the caliber of RAG is too small, great saphenous vein (GSV) can be used. However, the use of GSV is not preferred than radial artery due to high flow rate in GSV which may cause flow disturbance when anastomosed to the branch of MCA with is <2 mm in diameter.^[17] In patients with connective tissue disorder such as Ehlers–Danlos syndrome may have abnormal radial artery which may not be suitable as a vascular graft.^[4] Propofol or pentobarbital is used as brain protection during temporary arterial occlusion.^[19] Vasospasm of the RAG which may lead to total occlusion can be prevented using pressure distention technique.^[16] The STA-M3 anastomosis is performed prior to ECA-RA-M2 anastomosis to reduce the risk of ischemic complications during the temporary occlusion.^[8] Intraoperative use of 4000–5000 units of heparin is administered intravenously is limited to high flow.^[19]

The occlusion of the ICA can be done by clipping or endovascular occlusion. The ICA occlusion rate with

Table 2: Illustrative case showing the comparison between peripheral arterial blood pressure and middle cerebral artery pressure at different intraoperative intervals

Steps	Peripheral Arterial blood pressure (mmHg) (MAP)	Middle cerebral artery pressure (mmHg) (MAP)
Before ICA occlusion	103/57 (75)	72/40 (54)
After ICA occlusion	96/54 (70)	24/20 (22)
Supply from low-flow bypass (STA-M3)	95/53 (70)	58/54 (55)
Supplies from both high-flow and low-flow bypasses (ECA-RA-M2 and STA-M3)	96/54 (71)	72/38 (48)

MAP – Mean arterial pressure; ICA – Internal carotid artery; MAP – Mean arterial pressure; ICA – Internal carotid artery; STA-M3 - Superficial Temporal Artery to the M3 segment of Middle Cerebral Artery end-side bypass; ECA-RA-M2 - External carotid artery to radial artery graft to M2 segment of Middle Cerebral Artery end-side bypasses

Table 3: Demographic data of the case series

Age	Sex	Diagnosis	Size (mm)	Types of bypass	Vascular graft	Neurological sequelae
79	Male	IC Giant An	22	High-flow bypass	Radial artery	None
77	Female	IC-Cavernous An	24.4	High-flow bypass	Radial artery	None
84	Female	IC-Cavernous An	20	High-flow bypass	Radial artery	None
66	Female	IC-Cavernous An	9.7	High-flow bypass	Radial artery	None
24	Female	IC-Cavernous An	30	High-flow bypass	Radial artery	None
83	Female	IC-Cavernous An	11.7	High-flow bypass	Radial artery	None

IC – Internal carotid; An – Aneurysm

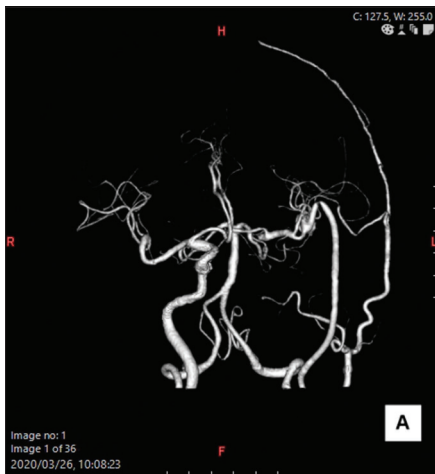

Figure 7: Postoperative magnetic resonance angiography showing arterial blood flow from external carotid artery - radial artery graft-M2 and superficial temporal artery-M3 bypasses

endovascular treatment is ranging from 17% to 47%.^[20] Endovascular internal trapping is performed in cases with retrograde dome filling from collateral flow observed during BOT or if the aneurysm is extended to the bifurcation of the ophthalmic artery. In other cases, proximal ICA ligation is preferred.^[3] The pressure within the aneurysm sac is diminished which promotes thrombosis following Hunterian ligation or balloon occlusion of the proximal vessel.^[19]

The EC-IC bypass surgery is also a great option for giant IC aneurysm when surgical clipping may not be feasible and higher risk of failure with endovascular procedures.^[17] Endovascular stenting of giant aneurysm often leads to treatment failure due to recanalization.^[17] ICG video angiography, motor-evoked potentials, and Doppler

are used to check the patency before ligation of ICA.^[18] Symptomatic bilateral CCAs can also be treated successfully with high-flow bypass and parent artery occlusion. The treatment for the contralateral CCA can be considered when symptomatic during follow-up period after the first treatment.^[3]

A direct aneurysmal CCF was successfully treated by high-flow bypass using a RAG and ICA trapping in one case report.^[20] Another study also found that high-flow bypass with aneurysm trapping is the appropriate surgical treatment to obliterate the fistula immediately in cases of CCA presented with direct CCF.^[21]

Complications to be expected from both endovascular procedures, microsurgical clipping and bypass procedure include CN deficits, intracerebral bleed, and ischemic strokes. Stent migration and gastrointestinal bleedings due to the use of anticoagulant may occur in endovascular procedures.^[12] Meticulous dissection and tissue handlings with importance to maintain hemostasis during surgery help to reduce to immediate postoperative complications.^[19] All except one patients in this surgical cohort were elderly. The high success rate in high-flow bypass surgery among elderly patients with CCAs also been reported.^[18] Successful high-flow bypass using RAG with insurance STA-MCA bypass prior to ICA ligation does not adversely affect postoperative cognitive function in a study of eight cavernous segment aneurysm cases.^[11] Another rare complication from a high-flow bypass surgery was anastomotic aneurysms as reported by a case report. It was due to possible intraoperative intimal damage during handling of RAG and postoperative hemodynamic stress to the RAG.^[22]

Conclusion

Despite the natural history of most CCAs is quite benign and majority are asymptomatic, those with growing aneurysm, thrombus formation, or causing significant bony erosion may require treatments. The surgical treatments should be limited to experienced neurosurgeons in view of significant risk of morbidity and mortality. Endovascular procedures may be the main stay of treatments, however, the success shown in this case series with parent artery occlusion and bypass surgery and many other reports may provide alternative to endovascular treatments. Endovascular procedures may not be the choice if there are limitations in the vascular anatomical architectures, poor medication compliance, young patients, and patient's preference for immediate obliteration. Follow-up with expectant management may be good treatment strategies in some of the asymptomatic group with minimal risk of the growth or CCAs.

Declaration of patient consent

The authors certify that they have obtained all appropriate patient consent forms. In the form the patient(s) has/have given his/her/their consent for his/her/their images and other clinical information to be reported in the journal. The patients understand that their names and initials will not be published and due efforts will be made to conceal their identity, but anonymity cannot be guaranteed.

Financial support and sponsorship

Nil.

Conflicts of interest

There are no conflicts of interest.

References

- Sudhoff H, Stark T, Knorz S, Luckhaupt H, Borkowski G. Massive epistaxis after rupture of intracavernous carotid artery aneurysm. Case report. *Ann Otol Rhinol Laryngol* 2000;109:776-8.
- Surdell DL, Hage ZA, Eddleman CS, Gupta DK, Bendok BR, Batjer HH. Revascularization for complex intracranial aneurysms. *Neurosurg Focus* 2008;24:E21.
- Uozumi Y, Okamoto S, Araki Y, Izumi T, Matsubara N, Yokoyama K, *et al.* Treatment of symptomatic bilateral cavernous carotid aneurysms: Long-term results of 6 cases. *J Stroke Cerebrovasc Dis* 2015;24:1013-8.
- Miyatani K, Korde P, Yamada Y, Kawase T, Takizawa K, Kato Y. Atypical symptomatic bilateral spontaneous cavernous carotid aneurysm with systemic vessel wall pathology in young female: A rare case report. *Asian J Neurosurg* 2019;14:1245-8.
- Bendok BR, Batjer HH. Cavernous carotid aneurysms: To treat or not to treat? *Neurosurg Focus* 2009;26:E4.
- Vasconcellos LP, Flores JA, Veiga JC, Conti ML, Shiozawa P. Presentation and treatment of carotid cavernous aneurysms. *Arq Neuropsiquiatr* 2008;66:189-93.
- Wiebers DO, Whisnant JP, Huston J III, Meissner I, Brown RD Jr., Piepgras DG, *et al.* Unruptured intracranial aneurysms: Natural history, clinical outcome, and risks of surgical and endovascular treatment. *Lancet* 2003;362:103-10.
- Kumar A, Kutty RK, Yamada Y, Tanaka R, Ravisankar V, Musara A, *et al.* A retrospective analysis of treatment outcomes of 40 incidental cavernous carotid aneurysms. *World Neurosurg* 2019;130:e1034-40.
- Yasargil GM. Anastomosis between the superficial temporal artery and a branch of the middle cerebral artery. In: *Microsurgery Applied to Neuro-surgery*. Stuttgart: Georg Thieme; 1969. p. 105-15.
- Sia SF, Morgan MK. High flow extracranial-to-intracranial brain bypass surgery. *J Clin Neurosci* 2013;20:1-5.
- Ono H, Inoue T, Tanishima T, Tamura A, Saito I, Saito N. High-flow bypass with radial artery graft followed by internal carotid artery ligation for large or giant aneurysms of cavernous or cervical portion: Clinical results and cognitive performance. *Neurosurg Rev* 2018;41:655-65.
- Kim LJ, Tariq F, Levitt M, Barber J, Ghodke B, Hallam DK, *et al.* Multimodality treatment of complex unruptured cavernous and paraclinoid aneurysms. *Neurosurgery* 2014;74:51-61.
- Kai Y, Hamada J, Mizuno T, Todaka T, Morioka M, Ushio Y. Treatment for giant aneurysms in the cavernous portion of the internal carotid artery using detachable coils. *Interv Neuroradiol* 2000;6 Suppl 1:103-6.
- Dolenc VV. Extradural approach to intracavernous ICA aneurysms. *Acta Neurochir Suppl (Wien)* 1999;72:99-106.
- Jin SC, Kwon DH, Song Y, Kim HJ, Ahn JS, Kwun BD. Multimodal treatment for complex intracranial aneurysms: Clinical research. *J Korean Neurosurg Soc* 2008;44:314-9.
- Matmusaev M, Duschanov T, Yamada Y, Takizawa K, Kawase T, Tanaka R, *et al.* High flow bypass for cavernous carotid aneurysms. *Rom Neurosurg* 2018;32:262-71.
- Gobble RM, Hoang H, Jafar J, Adelman M. Extracranial-intracranial bypass: Resurrection of a nearly extinct operation. *J Vasc Surg* 2012;56:1303-7.
- Murai Y, Mizunari T, Umeoka K, Tateyama K, Kobayashi S, Teramoto A. Radial artery grafts for symptomatic cavernous carotid aneurysms in elderly patients. *Neurol India* 2011;59:537-41.
- Menon G, Jayanand S, Krishnakumar K, Nair S. EC-IC bypass for cavernous carotid aneurysms: An initial experience with twelve patients. *Asian J Neurosurg* 2014;9:82-8.
- Nakagawa S, Murai Y, Wada T, Tateyama K. 4D flow preliminary investigation of a direct carotid cavernous fistula due to a ruptured intracavernous aneurysm. *BMJ Case Rep* 2015;2015:bcr2014206084.
- Sriamornrattanakul K, Sakarunchai I, Yamashiro K, Yamada Y, Suyama D, Kawase T, *et al.* Surgical treatment of large and giant cavernous carotid aneurysms. *Asian J Neurosurg* 2017;12:382-8.
- Uchida T, Yoshino M, Ito S, Hara T. Anastomotic aneurysm formation after high flow bypass surgery: A case report with histopathological study. *NMC Case Rep J* 2017;4:111-3.