

## Case Report

# Spinal cord edema with contrast enhancement mimicking intramedullary tumor in patient with cervical myelopathy: A case report and a brief literature review

Grigorios Gkardaris, Danai Chourmouzi<sup>1</sup>, Apostolos Karagiannidis, Stylianos KapetanakisSpine Department and Deformities, <sup>1</sup>Radiology Department, Interbalkan European Medical Center, Thessaloniki, GreeceE-mail: Grigorios Gkardaris - [grgkardaris@gmail.com](mailto:grgkardaris@gmail.com); Danai Chourmouzi - [dchourmouzi@gmail.com](mailto:dchourmouzi@gmail.com); Apostolos Karagiannidis - [apokaragian@yahoo.gr](mailto:apokaragian@yahoo.gr);\*Stylianos Kapetanakis - [stkapetanakis@yahoo.gr](mailto:stkapetanakis@yahoo.gr)

\*Corresponding author

Received: 30 March 17 Accepted: 06 May 17 Published: 13 June 17

## Abstract

**Background:** Cervical myelopathy (CM) is a clinical diagnosis that may be associated with hyperintense areas on T2-weighted magnetic resonance imaging (MRI) scan. The use of contrast enhancement in such areas to differentiate between neoplastic and degenerative disease has rarely been described.

**Case Description:** We present a 41-year-old female with a 5-month course of progressive CM. The cervical MRI revealed spinal cord swelling, stenosis, and a hyperintense signal at the C5–C6 and C5–C7 levels. Both the neurologic and radiologic examinations were consistent with an intramedullary cervical cord tumor. To decompress the spinal canal, an anterior cervical discectomy and fusion was performed from C5 to C7 level. This resulted in immediate and significant improvement of the myelopathy. Postoperatively, over 1.5 years, the hyperintense, enhancing intramedullary lesion gradually regressed on multiple postoperative MRI scans.

**Conclusion:** Spinal cord edema is occasionally seen on MR studies of the cervical spine in patients with degenerative CM. Contrast-enhanced MR studies may help differentiate hyperintense cord signals due to edema vs. atypical intramedullary tumors. Routine successive postoperative MRI evaluations are crucial to confirm the diagnosis of degenerative vs. neoplastic disease.

**Key Words:** Cervical myelopathy, cervical spondylosis, contrast enhancement, intramedullary lesion, spinal cord edema, spinal cord swelling, spinal tumors

### Access this article online

**Website:**[www.surgicalneurologyint.com](http://www.surgicalneurologyint.com)**DOI:**

10.4103/sni.sni\_125\_17

**Quick Response Code:**

## INTRODUCTION

Several non-neoplastic intramedullary pathologies can mimic intramedullary tumors; these include edema due to myelopathy, demyelination, granulomatous disease, infections, radiation myelopathy, vascular lesions, and syringomyelia.<sup>[3]</sup> Hyperintense T2-weighted lesions may reflect focal spinal cord edema and may enhance with gadolinium at the site of maximal cord compression (e.g., chronic cervical compression and spondylotic changes).<sup>[3,7]</sup> However, intramedullary contrast

This is an open access article distributed under the terms of the Creative Commons Attribution-NonCommercial-ShareAlike 3.0 License, which allows others to remix, tweak, and build upon the work non-commercially, as long as the author is credited and the new creations are licensed under the identical terms.

**For reprints contact:** [reprints@medknow.com](mailto:reprints@medknow.com)

**How to cite this article:** Gkardaris G, Chourmouzi D, Karagiannidis A, Kapetanakis S. Spinal cord edema with contrast enhancement mimicking intramedullary tumor in patient with cervical myelopathy: A case report and a brief literature review. *Surg Neurol Int* 2017;8:111.

<http://surgicalneurologyint.com/Spinal-cord-edema-with-contrast-enhancement-mimicking-intramedullary-tumor-in-patient-with-cervical-myelopathy:-A-case-report-and-a-brief-literature-review/>

enhancement of the spinal cord may also indicate the presence of an infectious or neoplastic process.<sup>[1,2,8]</sup>

Here, we report the case of a 41-year-old female with cervical spondylosis at the C5–C6 level whose MRI scan revealed spinal cord swelling, atypical enlargement, and hyperintensity of the cord on the T2-weighted image and contrast enhancement with gadolinium (T1-weighted) [Table 1]. This article highlights the significance of hyperintense signals in the cervical cord and emphasizes how preoperative noncontrast/contrast-enhanced MR scans should be utilized to help differentiate spondylotic compressive myelopathy (degenerative disease) from intramedullary tumors. Furthermore, successive postoperative MR studies help confirm the correct diagnosis of a compressive myelopathy.

## CASE REPORT

### Medical history and examination

A 41-year-old female, who had not sustained any trauma, initially presented with weakness/numbness involving all four extremities and progressive sphincter dysfunction over the last 2 months. When the cervical noncontrast MRI showed a hyperintense intramedullary cord signal, the differential diagnoses included cervical spondylotic myelopathy and tumor. She was referred for an open biopsy of the cervical spinal cord to document the pathology of the tumor. At the time of her transfer, her severe spastic quadriparesis was markedly greater in the upper than in the lower extremities. The follow-up MRI revealed cervical spondylosis with C5–C6 and C6–C7 cord compression associated with an extensive intramedullary high cord signal and cord enlargement on the T2-weighted sagittal images

extending from C5 to C7 [Figure 1a], whereas the axial images confirmed the intramedullary signal abnormality. The T1-weighted MRI sagittal scan showed the lesion enhanced with contrast at the C5–C6 level [Figure 1b].

### Operation and postoperative evaluation

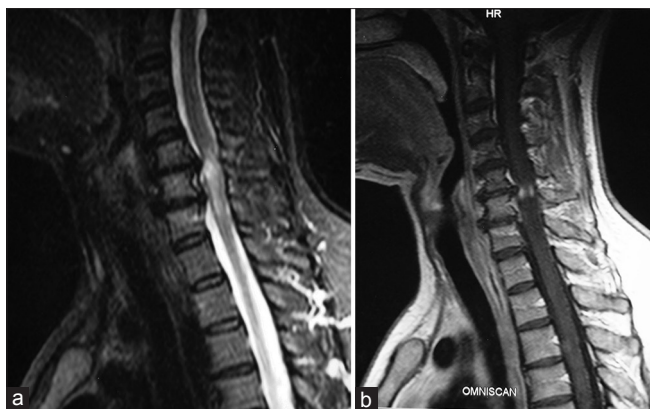
The patient underwent an anterior cervical discectomy and fusion from C5 to C7 using PEEK (PolyEtherEtherKetone) intervertebral cages. No histopathologic evidence was finally taken. There was significant postoperative motor/sensory improvement in her spastic quadriparesis and she retained normal bladder function. The cervical MRI performed 1 month later demonstrated no significant changes in the intramedullary lesion [Figure 2]. She continued to neurologically improve over the first postoperative year, but then her improvement plateaued. At 18 postoperative months, the intramedullary hyperintense signal on the T2-weighted MRI showed that the spinal cord enlargement had significantly regressed, whereas the enhanced MR revealed diminution of the overall size of the lesion at C5–C6 level. Finally, 2 years postoperatively, only mild atrophy could be seen.

## DISCUSSION

Sasamori *et al.* reported non-neoplastic lesions mimicking intramedullary tumors on T2-weighted MRI; patients with spondylotic disease may also demonstrate hyperintensity attributed to spinal cord swelling while also showing some gadolinium enhancement.<sup>[7]</sup> Takahashi *et al.* studied MRI scans of 668 patients with spondylotic cervical myelopathy (CM); only 1 patient displayed contrast enhancement due to cervical herniated disc and spondylosis at C3–C4 level.<sup>[8]</sup> Lee *et al.* presented

**Table 1: Cases of spinal cord swelling with Gd-enhancement in cervical degenerative disorders**

First author	Title	Cases	Year	Clinical presentation	Treatment	Follow-up (MRI findings)
Takahashi <sup>[9]</sup>	Chronic cervical cord compression: Clinical significance of increased signal intensity on MR images	1	1989	Mild weakness and hypoesthesia	Not stated	Not stated
Lee <sup>[5]</sup>	Spinal cord edema: Unusual magnetic resonance imaging findings in cervical spondylosis	6	2003	Upper extremity numbness and mild quadriparesis	Laminoplasty or anterior fusion	T2 hyperintensity and contrast enhancement persisted for several (not precisely stated) months postoperatively
Boet <sup>[1]</sup>	Contrast enhancement of the spinal cord in a patient with cervical spondylotic myelopathy	1	2004	Upper extremity numbness and mild quadriparesis	Discectomy and anterior fusion with cage	T2 hyperintensity and contrast enhancement diminished 12 months postoperatively
Cabraja <sup>[2]</sup>	Atypical cervical spondylotic myelopathy mimicking intramedullary tumor	1	2008	Cervicobrachialgia, unsteady gait and bladder dysfunction	Biopsy and spinal fusion	T2 hyperintensity and contrast enhancement persisted for 3 months postoperatively
Sasamori <sup>[7]</sup>	Spinal cord swelling with abnormal gadolinium-enhancement mimicking intramedullary tumors in cervical spondylosis patients: Three case reports and review of the literature	3	2010	Upper extremity numbness and mild quadriparesis	Laminoplasty	T2 hyperintensity and contrast enhancement diminished gradually during the 12 months after surgery



**Figure 1: Preoperative MRI (a) T2-weighted MRI sagittal scan with extensive intramedullary high intensity from C5 to C7. (b) T1-weighted MRI sagittal scan with contrast enhancement at level C5 –C6. Contrast enhancement is at the point of greatest spinal cord compression**

6 patients with spondylotic CM whose postoperative MRI revealed spinal cord swelling with abnormal gadolinium enhancement.<sup>[5]</sup> Boet *et al.* described a patient who underwent an anterior cervical discectomy and improved after surgery.<sup>[1]</sup> A smaller intramedullary enhanced lesion was still noted on the 1-year postoperative follow-up. Cabraja *et al.* also reported a similar case in which the lesion was felt to be neoplastic and was biopsied.<sup>[2]</sup>

Most patients presented with MR-documented hyperintense intramedullary lesions with cord enlargement opposite to levels of maximal compression. In our case, the edema of the spinal cord was larger than it should be, extending the point of maximum compression at C5–C6; and the contrast enhancement was localized directly at the site of the greatest narrowing of the spinal canal. After surgery, patients with degenerative pathology demonstrated extensive clinical improvement, however, MR resolution of cord edema/swelling lagged (e.g., in this case by 18 months).

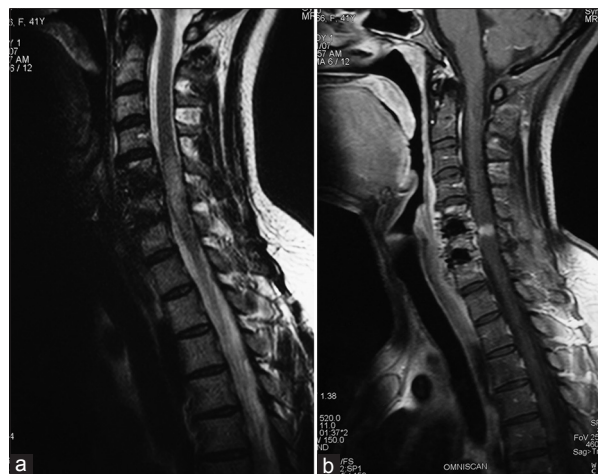
Surgical decompression may be performed by an anterior or posterior approach depending on the type/location of pathology.<sup>[4]</sup> Certainly, performing an intramedullary cord biopsy is not the treatment choice.

### Magnetic resonance diagnosis of pathology

MRI, particularly the hyperintense intramedullary cord signals with/without gadolinium, best helps differentiate between spinal stenosis/spondylosis/CM and an intramedullary spinal cord tumor. It may reflect whether someone is suffering from CM or tumor. New techniques that use advanced MRI are emerging and providing exciting new tools for assessing the spinal cord in patients with degenerative CM.<sup>[6]</sup>

### CONCLUSION

Spinal cord edema is occasionally seen with cervical spondylosis/CSM (cervical spondylotic myelopathy).



**Figure 2: Postoperative MRI. (a) One month after surgery, sagittal MRI demonstrated slight decrease of the intramedullary high intensity on T2-weighted images. The high-intensity signal is still atypically extended beyond the point of compression. (b) T1-weighted MRI sagittal scan with persisting contrast enhancement at level C5–C6 1 month after surgery**

When an intramedullary hyperintense lesion is seen that enhances with gadolinium, differentiating between CSM and tumor may be difficult. In cases where there is rapid clinical deterioration, an initial decompression/fusion should be considered. Successive postoperative MR studies with/without enhancement may then be used to further differentiate between CSM and tumor.

### Financial support and sponsorship

Nil.

### Conflicts of interest

There are no conflicts of interest.

### REFERENCES

- Boet R, Chan Y-L, King A, Mok CT, Poon WS. Contrast enhancement of the spinal cord in a patient with cervical spondylotic myelopathy. *J Clin Neurosci* 2004;11:512-4.
- Cabraja M, Abbushi A, Costa-Blechs Schmidt C, van Landeghem FK, Hoffmann KT, Woiciechowsky C, *et al.* Atypical cervical spondylotic myelopathy mimicking intramedullary tumor. *Spine (Phila Pa 1976)* 2008;33:E183-7.
- Hida K, Iwasaki Y. Surgical approach for nonneoplastic intramedullary lesions. *Rinsho Shinkeigaku* 2002;42:1105-6.
- Joaquim AF, Ghizoni E, Tedeschi H, Hsu WK, Patel AA. Management of degenerative cervical myelopathy—An update. *Rev Assoc Med Bras* 2016;62:886-94.
- Lee J, Koyanagi I, Hida K, Seki T, Iwasaki Y, Mitsumori K. Spinal cord edema: Unusual magnetic resonance imaging findings in cervical spondylosis. *J Neurosurg* 2003;99(Suppl):8-13.
- Nouri A, Martin AR, Mikulis D, Fehlings MG. Magnetic resonance imaging assessment of degenerative cervical myelopathy: A review of structural changes and measurement techniques. *Neurosurg Focus* 2016;40:E5.
- Sasamori T, Hida K, Yano S, Takeshi A, Iwasaki Y. Spinal cord swelling with abnormal gadolinium-enhancement mimicking intramedullary tumors in cervical spondylosis patients: Three case reports and review of the literature. *Asian J Neurosurg* 2010;5:1-9.
- Takahashi M, Yamashita Y, Sakamoto Y, Kojima R. Chronic cervical cord compression: Clinical significance of increased signal intensity on MR images. *Radiology* 1989;173:219-24.