


# Intracerebral haemorrhage: from clinical settings to animal models

Qian Bai <sup>1</sup>, Zhaofu Sheng,<sup>1</sup> Yang Liu,<sup>1</sup> Ruiyi Zhang,<sup>1</sup> Voon Wee Yong,<sup>2</sup> Mengzhou Xue<sup>1</sup>

**To cite:** Bai Q, Sheng Z, Liu Y, *et al.* Intracerebral haemorrhage: from clinical settings to animal models. *Stroke & Vascular Neurology* 2020;**5**: e000334. doi:10.1136/svn-2020-000334

QB and ZS contributed equally.

Received 13 January 2020

Revised 21 February 2020

Accepted 27 February 2020

Published Online First

26 March 2020

## ABSTRACT

Spontaneous intracerebral haemorrhage (ICH) is a devastating type of stroke with high mortality and morbidity and for which no effective treatments are available to date. Much experimental and clinical research have been performed to explore its mechanisms regard the subsequent inflammatory cascade and to seek the potential therapeutic strategies. The aim of this review is to discuss insights from clinical settings that have led to the development of numerous animal models of ICH. Some of the current and future challenges for clinicians to understand ICH are also surveyed.

## INTRODUCTION AND DEFINITIONS

Acute spontaneous intracerebral haemorrhage (ICH) (non-traumatic) affects approximately 2 million people each year in the world, and it is the most serious and least treatable form of stroke.<sup>1</sup> Stroke was also the second most common cause of disability-adjusted life years, and according to a report from the Global Burden of Disease 2016 Lifetime Risk of Stroke Collaborators, the estimated global lifetime risk of stroke in 2016 for those aged 25 years or older was 24.9%.<sup>2</sup>

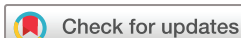ICH indicates that blood has deposited in the brain parenchyma<sup>3</sup> and may extend into the ventricles. Blood components, including leucocytes, haemoglobin, thrombin, plasmin, complement, plasma and fibrin degradation products appear in the brain tissues.<sup>4</sup> An inflammatory response and brain cell death take place subsequently, which may involve enzyme activation, cytokine release, leucocyte migration and brain tissue breakdown and repair.<sup>5</sup> Forty per cent of patients die within the first 30 days,<sup>6</sup> the mortality rate at the first month is 43%–51%, and the survivors have irreversible consequences dependent on the injured location.<sup>6</sup> The most common neurological deficit is hemiplegia or anaesthesia.<sup>7</sup> There can be dysphasia,<sup>8</sup> cognitive deficits,<sup>9</sup> emotional difficulties,<sup>10</sup> daily living problems and pain.<sup>11</sup> In addition, numbness or tingling is also a common deficit. ICH in the brain stem may influence vision, swallowing, breathing, balance and consciousness.<sup>12</sup>

The amount of research on ICH lacks that of ischaemic stroke. The mechanisms of delayed clinical deterioration after ICH still remain unclear. This review is mainly focused on summing ICH occurring in the clinical setting and in different animal models, and describes progress in pathophysiology of brain damage after ICH.

## ICH IN THE CLINICAL SETTING

The worldwide annual incidence of spontaneous ICH is 12–35 per 100 000 population, which accounts for approximately 15% of cerebral strokes; it has a higher mortality rate compared with that of cerebral ischaemia.<sup>13</sup> The major high-risk factors for ICH are an elderly population,<sup>14</sup> male sex,<sup>15</sup> current smoking,<sup>16</sup> excessive alcohol consumption,<sup>17</sup> low total cholesterol level,<sup>18</sup> long sleep duration,<sup>19</sup> illicit drug use,<sup>20</sup> Asians ethnic origin<sup>21</sup> and genetic factors.<sup>22</sup> Other clinical disease can cause ICH, including hypertension,<sup>23</sup> coagulopathy,<sup>24</sup> cerebral amyloid angiopathy (CAA),<sup>25</sup> cerebral tumours,<sup>26</sup> intracranial arterial aneurysm,<sup>27</sup> vascular anomalies,<sup>28</sup> brain trauma,<sup>29</sup> premature birth,<sup>30</sup> haemorrhagic conversion of stroke,<sup>31</sup> posterior reversible encephalopathy syndrome,<sup>32</sup> vasculitis,<sup>33</sup> infective endocarditis,<sup>34</sup> dural arteriovenous fistula,<sup>35</sup> brain arteriovenous malformation,<sup>36</sup> cavernous malformation<sup>37</sup> and intracranial venous thrombosis<sup>38</sup> (figure 1). ICH associated with hypertension remains the most common form of ICH.<sup>23</sup> The importance of CAA is growing due to ageing population.<sup>25</sup> Besides, drug-related ICH, particularly anticoagulants, is also a major cause of ICH.<sup>39</sup>

Effective treatment for ICH is still scarce.<sup>40</sup> However, clinical therapeutic strategies includes medication and surgery.<sup>41</sup> Drug therapy is the most common treatment for ICH. This includes prevention of ICH based on treating an individual's underlying risk factors, for example, control of hypertension.<sup>42</sup> Hyperglycaemia in diabetics is common after stroke; managing glucose level may reduce the stroke size.<sup>43</sup> Oxygen



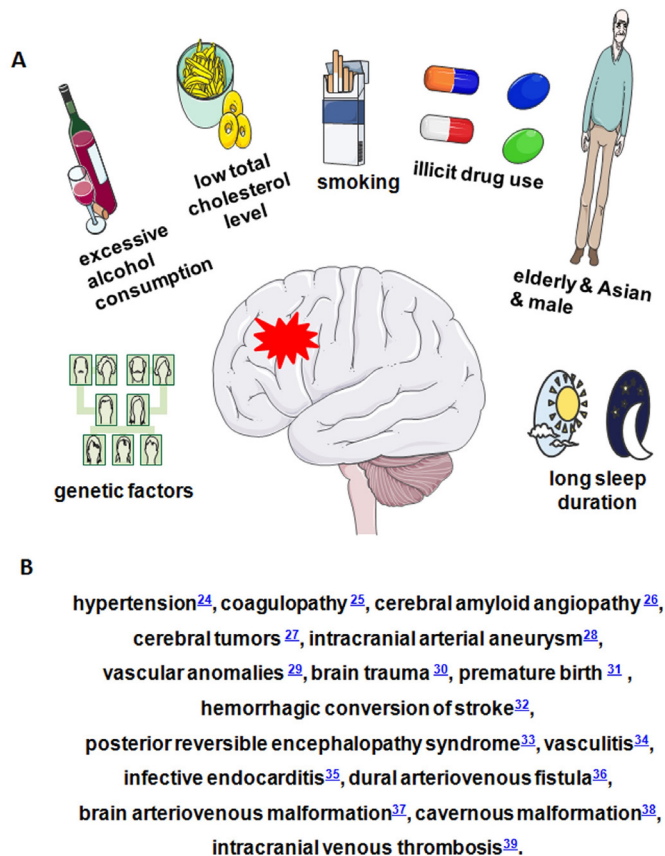
© Author(s) (or their employer(s)) 2020. Re-use permitted under CC BY-NC. No commercial re-use. See rights and permissions. Published by BMJ.

<sup>1</sup>The Departments of Cerebrovascular Diseases; Henan Medical Key Laboratory of Translational Cerebrovascular Diseases, The Second Affiliated Hospital of Zhengzhou University, Zhengzhou, China

<sup>2</sup>Hotchkiss Brain Institute and Department of Clinical Neurosciences, University of Calgary, Calgary, Alberta, Canada

## Correspondence to

Dr Mengzhou Xue; xuemengzhou@zzu.edu.cn



**Figure 1** Risk factors of ICH. (A) Risk factors of ICH. (B) Some clinical diseases that can cause ICH. ICH, intracerebral haemorrhage.

is given as needed. Surgery can be used to prevent ICH by repairing vascular damage or malformations in and around the brain, or to treat acute ICH by evacuating the haematoma; however, the benefit of surgical treatment is still controversial<sup>44</sup> due to very few controlled randomised trials. Rehabilitation may help overcome disabilities that result from ICH damage.<sup>45</sup>

### ANIMAL MODELS OF ICH

Animal models of ICH may help us to understand its pathogenesis and explore preventive or therapeutic approaches. Experimental ICH models have been studied in several species including mouse,<sup>46</sup> rat,<sup>47–49</sup> rabbit,<sup>50 51</sup> cat,<sup>52</sup> pig<sup>53</sup> and primate.<sup>54</sup> The ICH model should be selected carefully to fit study aims (table 1).

### MICROBALLOON INSERTION MODELS

An acute expanding lesion model using a mechanical microballoon to simulate the space-occupying effect of ICH was developed by Sinar in the adult rat in 1987 (although this model lacks the effects of blood components).<sup>55</sup> The microballoon system consists of an embolisation balloon mounted on a 20-gauge venous cannula using its own previously blunted guide. The microballoon is then inflated with saline in a syringe. After balloon

inflation in the caudate nucleus of rats, intracranial pressure (ICP) increases significantly and cerebral blood flow (CBF) decreases subsequently in ipsilateral frontal cortex and caudate nucleus.<sup>56</sup> Microballoons (25 mL and 50 mL in volume) that mimic lesion size in man cause little change in ICP. However, a larger volume (100 mL) increases ICP.<sup>57</sup> The volume of ischaemic damage in the ipsilateral caudate nucleus for inflation group was reported to be 10-fold more than that for sham-treated group.<sup>55</sup> Compared with transient inflation groups, amounts of injured neurons in permanent groups was significantly higher.<sup>58</sup> Deflation of balloon after 10 min was shown to improve clinical outcome and reduced CBF abnormalities in rats.<sup>59</sup> Therefore, to defend the development of irreversible neurological deficits and death in this model, evacuation of expanding haematoma-like mass is necessary within a proper time window. Similarly, a microballoon inserted into the ventral posterolateral nucleus of the thalamus in cat caused a rapid reduction in CBF following gradual balloon inflation.<sup>60</sup>

### AUTOLOGOUS WHOLE BLOOD INJECTION MODELS

Anatomically localised haematomas may be realised by this method without artificial agents.<sup>48 49 61</sup> Except for needle insertion, autologous blood injection may closely mimic clinical ICH. The autologous blood extracted from tail or femoral artery of animal is directly injected into particular brain regions. Several studies employ this model to survey brain injury mechanisms. Hydrocephalus, cell death, inflammation and behavioural disorders may be induced by autologous blood injection in rats.<sup>47–49 62–64</sup> Studies in the dog have shown that despite a prominent increase in ICP and mean arterial pressure after ICH, ischaemic penumbra in the first 5 hours after ICH was not demonstrated.<sup>65</sup> Increased ICP as well as compromised CBF and metabolism following ICH have been shown<sup>66</sup> in the cats, rabbits, monkeys and pigs. Pigs have been frequently studied for clot evacuation.<sup>67 68</sup> For instance, a tPA (tissue Plasminogen Activator)-induced clot lysis study showed that reduction in clot size was significantly greater than mechanical aspiration alone. In the rabbit model,<sup>69</sup> urokinase treated animals showed 86% of clot lysis compared with injection of saline into clot (23%). Effects of blood components, including leucocyte fractions, erythrocytes, plasma, serum, thrombin and plasmin, were demonstrated separately in rats.<sup>49 70</sup> Leucocytes, activated leucocytes, thrombin and plasminogen caused brain oedema, inflammation and brain cell death when they were injected into the brain.<sup>47</sup> Components of the coagulation system can modulate inflammation.<sup>71</sup> Activation of the complement system<sup>72</sup> and injections of haemoglobin as well as erythrocytes into the brain may lead to brain oedema.<sup>61 70</sup>

### COLLAGENASE ANIMAL MODEL OF ICH

This model was developed by Rosenberg's group. Bacterial collagenases, which may destroy capillary basal lamina, are

**Table 1** Animal models of ICH

Mediators of injury	Advantages	Disadvantages	Citation
Microballoon	Microballoon model successfully in producing an effective brain lesion with reduction in cerebral blood flow and an increase in intracranial pressure at the site of damage.	Fails to address the potential effects of blood and subsequent substances released by the clot formation.	55–60
Autologous whole blood	The autologous blood injection model provides a sterile system without exogenous proteins, a good way to investigate the natural coagulation and inflammation pathways after ICH.	The amount of blood injected into the brain is significantly higher than other mediators, there is always a risk of blood disruption in the subarachnoid and ventricular spaces.	47–49 61–72
Collagenase	Collagenase injection model offers an easier procedure and a highly reproducible haemorrhage.	The bacterial collagenase can introduce a significant inflammatory reaction to affect investigation of innate inflammatory responses; Disrupted BBB could unnaturally facilitate drug access to the brain during pharmacological (eg, neuroprotection) experiments.	62 64 73–77
Thrombin	This model has been used to study the mechanisms of thrombin toxicity that cause neuroinflammation and cell death	This model provides minimal utility beyond thrombin toxicity research.	47 78–80
Hypertensive stroke models	This model has been used to study the mechanisms of thrombin toxicity to study the mechanism of brain injury following hypertensive ICH.	The disadvantage of this model is that brain lesions are unpredictable with regard to size and location.	81–83
Periventricular /intraventricular haemorrhage (PVH/IVH)	This model mimics the hydrocephalus following PVH/IVH in prematurely born infants, it provides an opportunity to study mechanisms of cellular injury after PVH/IVH.	This model provides minimal utility other than PVH/IVH.	30 46 84–92

BBB, blood brain barrier.

injected into basal ganglia to induce ICH.<sup>73 74</sup> Reproducible haemorrhage without significant blood leakage along the needle track mimics spontaneous ICH. Following ICH induced by collagenase in rats, behavioural improvement is rapid but incomplete at 3 weeks, accompanied by resolution of the oedema.<sup>62</sup> This model is also used to study treatment following ICH.<sup>73–77</sup> Compared with autologous blood injection model and venous haemorrhage model by avulsion of cerebral surface vessels, collagenase model introduces exogenous protein that may cause more inflammatory reactions.<sup>64</sup> Addition of heparin to collagenase injection enhances the inflammation in rat brain.<sup>62</sup> From an anatomical perspective, the extent of brain injury is more consistent for collagenase than other models. However, from a biological perspective, it is the most artificial. In addition, compared with other models, inflammation and cell death begin earlier. Collagenase induces a haematoma, and may cause cell damage directly and rapidly. Thus, the model has distinct differences from ICH in the clinical setting and the autologous blood injection model.

### THROMBIN MODEL OF ICH

Thrombin toxicity activates microglia and promotes cytokine production that causes neuroinflammation and cell death. Thrombin released from haematoma is a main contributor to secondary brain damage in acute

ICH.<sup>47 78</sup> Intraventricular injection of thrombin causes significant hydrocephalus, ventricular wall damage and periventricular blood–brain barrier (BBB) disruption.<sup>79</sup> Intrastriatal thrombin injection that impairs neurogenesis and spatial memory function is partly mediated by inflammation, which is characterised by the activation of CD68 positive microglia/macrophages.<sup>80</sup> This model has been used to study the mechanisms of thrombin toxicity that cause neuroinflammation and cell death.<sup>78 80</sup> A disadvantage of this model is that it provides minimal utility beyond thrombin toxicity research.

### HYPERTENSIVE STROKE MODELS

Hypertension is the most common risk factor for ICH. Hypertension also induces changes in the walls of small vessels in the brain leading to rupture, which make the blood bleed into the brain parenchyma. To understand the effect of hypertension induced haemorrhage and to develop treatment for it, several animal models have been developed.<sup>81</sup> Renovascular hypertension may be induced by renal artery constriction. By means of ring-shaped silver clips, roots of both renal arteries are constricted.<sup>82</sup> The rate of stable hypertension was 100% and the incidence of spontaneous stroke including ICH and brain infarct was 61.8% at 40 weeks after renal artery constriction.<sup>82</sup> Furthermore, the induced hypertension is not dependent on renin, brain angiotensin and perhaps circulating



vasopressin.<sup>81</sup> Stroke prone spontaneously hypertensive rats may also develop cerebral haemorrhage as well as cerebral infarct.<sup>83</sup> The brain lesions in this model include old and fresh cerebral haemorrhage and infarcts with or without subarachnoid effusion. These models simulate hypertensive ICH in humans and offer the chance to study the mechanism of brain injury following hypertensive ICH. The disadvantage is that brain lesions are unpredictable with regard to size and location.

### MODELS OF NEONATAL PERIVENTRICULAR/INTRAVENTRICULAR HAEMORRHAGE

Periventricular/intraventricular haemorrhage (PVH/IVH) occurs most commonly in premature infants of 24–30 weeks gestation.<sup>30</sup> The mechanisms of germinal matrix (GM) haemorrhage have been illustrated in immature animals, including cats, dogs, rabbits and sheep. Fluctuations in arterial and venous blood pressure can cause PVH.<sup>84</sup> In prematurely born rabbits (27–30 days gestation), IVH may be induced by glycerol to create intracranial hypotension.<sup>85 86</sup> In a newborn beagle model, injection of phenylephrine hydrochloride intravenously induces hypertension which can cause IVH.<sup>87</sup> Intraventricular injection of blood in dog has been employed to explore the influence of acute ventricular expansion on adjacent blood flow patterns.<sup>88</sup> Dog models may be employed to survey risk factors for PVH/IVH.<sup>84</sup> Unlike those seen in humans, superficial foci of bleeding may be induced in neonatal hypoxia mouse model.<sup>89</sup> However, these researches are related to physiological and anatomical characteristics that allow occurrence of PVH/IVH, but not the tissue reactions. By injection of autologous whole blood into periventricular tissue including GM and striatum, we developed a novel PVH/IVH model in newborn mice.<sup>46</sup> Haematoma expanded into the ventricles in most mice, which mimics GM haemorrhage in humans at 24–28 weeks gestation age. Therefore, according to imaging research in premature human infants, this model mimics grade III/IV PVH/IVH.<sup>90</sup> This model provides an opportunity to study mechanisms of cellular injury after PVH/IVH. By injection of blood into the ventricles of the 7-day-old rats, posthaemorrhagic hydrocephalus may be induced.<sup>91</sup> It mimics the hydrocephalus following PVH/IVH in prematurely born infants.<sup>92</sup>

### OTHER ANIMAL MODELS OF ICH

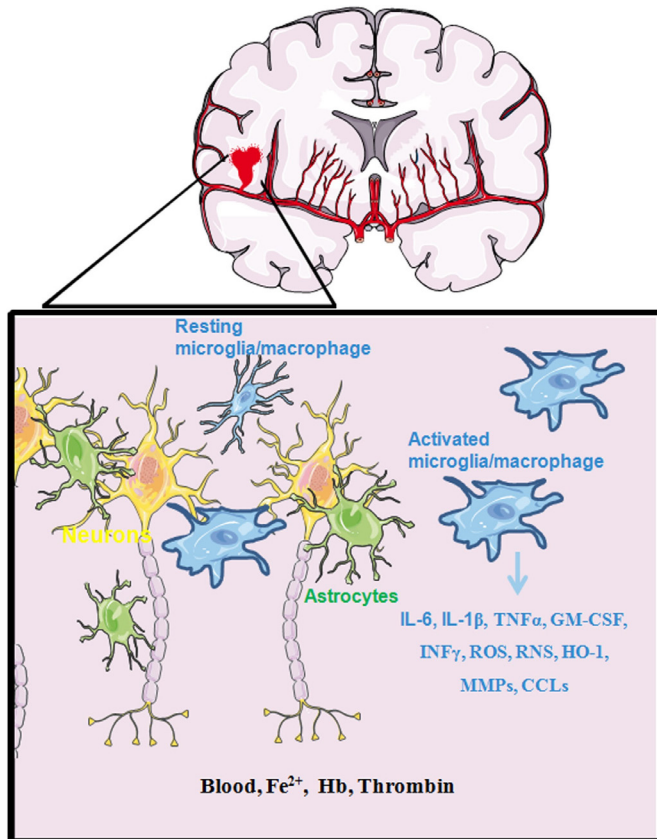
In addition to the above-mentioned ICH animal models, others have also been developed. Cortical vessel avulsion by tearing the pia can cause mixed brain damage including ischaemic and haemorrhagic.<sup>64</sup> Cortical vessel avulsion causes ischaemic infarction and haemorrhage. Therefore, it is not a simple ischaemic stroke model,<sup>93 94</sup> but an ischaemia and haemorrhagic mixed model just like traumatic cortical laceration. Additionally, haemorrhage related to shaking injury in the 6-day-old rats has been studied as a model of child abuse.<sup>95</sup> Some forms of traumatic brain injury also cause bleeding into the brain

parenchyma.<sup>96–98</sup> None of the above-mentioned ICH models completely reproduce the brain injury response following human ICH. However, these models have significantly contributed to the overall knowledge of the pathophysiology of human ICH including oedema, inflammation, cell death, brain damage, compromised CBF and metabolism as well as pathogenesis.

### PATHOPHYSIOLOGY OF BRAIN DAMAGE AFTER ICH

ICH causes brain damage through multiple mechanisms.

1. Mechanical injury of brain: Mechanical injury of brain tissue may be induced by the expanding haematoma,<sup>29 56</sup> and mechanical and chemical factors may reduce local CBF around the haematoma.<sup>56</sup> Raised ICP and distortion of the microvasculature contribute to oedema and secondary brain damage.<sup>56</sup> As cerebral oedema develops, ICP increases and cerebral perfusion pressure declines.<sup>56</sup> In this regard, ICH has similarities to ischaemic stroke particularly in the penumbra region that surrounds the haematoma.<sup>99 100</sup> If the haematoma is large and secondary infarction follows, the surrounding tissue may become necrotic.<sup>101</sup>
2. Complex immune and inflammatory cascades: Thrombin and plasmin are potentially toxic in the first day following ICH.<sup>102</sup> Local ischaemia, release of toxins by blood breakdown products, release of iron,<sup>103</sup> proteolytic enzymes or inflammation involving chemokines, cytokines and leucocytes all contribute to delayed damage.<sup>47 62–64 70 75 102 104 105</sup> Degenerating erythrocytes and fragmented nuclear debris may be observed after 24 hours. Two to three days after ICH, erythrocytes begin to break down, and haemoglobin is released. Hemosiderin is evident in macrophages as early as 3 days after the bleed.<sup>106</sup> Iron-dependent formation of oxidising agents results in brain damage.<sup>70 107</sup> Damaged brain cells, reactive microglia/macrophages and neutrophils produce reactive oxygen species (ROS) that cause brain cell damage following ICH.<sup>29 108</sup> Moreover, chemotactic factors, including thrombin, are released from blood clot and damaged brain after ICH.<sup>109</sup> The transit of leucocytes from blood vessels into the insulted brain may be prompted by thrombin.<sup>110</sup> Neutrophil infiltration and reactive glial changes including astrocyte activation and microglia reaction in the brain adjacent to the haematoma are obvious at 2–3 days after ICH.<sup>108 111–113</sup> Secondary brain damage may be caused by activated leukocytes through liberating cytokines, ROS, NO, matrix metalloproteinases (MMPs) and other proteases.<sup>114 115</sup> Large clots degrade very slowly because the macrophage ingestion of debris takes place only in the periphery of haematoma. For months after clot resolution, residual hemosiderin and mineralisation may be detected along the haematoma cavity. In IVH, blood debris may obstruct the cerebral aqueduct and cause hydrocephalus.<sup>41 116</sup> The transition of proteolytic enzymes from plasma into the brain parenchyma, including thrombin, plasmin and complement



**Figure 2** In the earliest stage of ICH, the primary injury causes blood products ( $\text{Fe}^{2+}$ , Hb, thrombin) to leak into the damage area to activate microglia/macrophages to express high levels of IL-6, IL-1 $\beta$ , TNF $\alpha$ , GM-CSF, INF $\gamma$ , ROS, RNS, CCLs, HO-1 and MMPs. These changes extend the brain damage such as brain oedema, cell death, blood–brain barrier disruption and neurological deficits. CCLs, chemokines subfamilies; GM-CSF, granulocyte-macrophage colony stimulating factor; Hb, haemoglobin; HO-1, heme oxygenase-1; INF $\gamma$ , interferon- $\gamma$ ; MMPs, matrix metalloproteinases; RNS, reactive nitrogen species; ROS, reactive oxygen species; TNF $\alpha$ , tumour necrosis factor $\alpha$ .

proteins, may exacerbate ICH injury.<sup>117</sup> MMPs are proteolytic enzymes with relative specificity for components of the extracellular matrix. Following brain injury MMPs, such as MMP-3 and MMP-9, are produced by infiltrating inflammatory cells, microglia and astrocytes.<sup>118</sup> Plasmin can promote the activity of MMPs.<sup>119–120</sup> MMPs may injure directly by processing death molecules (eg, FasL), disrupting myelin and perpetuating inflammation<sup>119–120</sup> (figure 2). This could also occur after ischaemia because large molecular weight proteins, including plasminogen and prothrombin, may penetrate the BBB.<sup>121–124</sup> They may contribute to brain oedema<sup>102–125</sup> (eg, albumin), cellular necrosis (eg, thrombin and plasmin) and inflammation<sup>47</sup> (eg, complement).

3. Beneficial factors: The proinflammatory microglia/macrophages play an important role in the early stages after ICH. However, increasing evidence indicates that the regulatory microglia/macrophages with potential

reparative and anti-inflammatory roles in the later phase of ICH can resorb haematoma and resolve oedema, contributing to improved white matter integrity, repair and functional recovery.<sup>126–127</sup> A recent study proves astrocytic-derived humanin could act as a beneficial factor in promoting a phagocytic/reparative phenotype.<sup>128</sup>

## CONCLUSION

Despite great advances in ischaemia stroke, no prominent improvement in the morbidity and mortality after ICH have been realised. The current understanding of ICH is still limited, and the models do not completely mirror the human condition. Novel effective modelling is required to mimic spontaneous ICH in humans and allow for effective studies on mechanisms and treatment of haematoma expansion and secondary brain injury.

**Contributors** QB and ZS wrote the first manuscript and QB drew the images; YL and RZ searched and organised the papers; WWY edited the manuscript; MX supervised the project.

**Funding** The authors acknowledge operating grant support from the National Natural Science Foundation of China (grants no: 81870942, 81471174 and 81520108011), National Key Research and Development Program Programme of China (grant no: 2018YFC1312200) and Innovation Scientists and Technicians Troop Construction Projects of Henan Province of China (for MX); and from the Canadian Institutes of Health Sciences (WWY).

**Competing interests** None declared.

**Patient consent for publication** Not required.

**Provenance and peer review** Commissioned; externally peer reviewed.

**Open access** This is an open access article distributed in accordance with the Creative Commons Attribution Non Commercial (CC BY-NC 4.0) license, which permits others to distribute, remix, adapt, build upon this work non-commercially, and license their derivative works on different terms, provided the original work is properly cited, appropriate credit is given, any changes made indicated, and the use is non-commercial. See: <http://creativecommons.org/licenses/by-nc/4.0/>.

## ORCID iD

Qian Bai <http://orcid.org/0000-0002-0196-8131>

## REFERENCES

- Cordonnier C, Demchuk A, Ziai W, *et al*. Intracerebral haemorrhage: current approaches to acute management. *Lancet* 2018;392:1257–68.
- Gorelick PB. The global burden of stroke: persistent and disabling. *Lancet Neurology* 2019;18:417–8.
- Tao C, Hu X, Li H, *et al*. White matter injury after intracerebral hemorrhage: pathophysiology and therapeutic strategies. *Front Hum Neurosci* 2017;11:422.
- Keep RF, Zhou N, Xiang J, *et al*. Vascular disruption and blood–brain barrier dysfunction in intracerebral hemorrhage. *Fluids Barriers CNS* 2014;11:18.
- Bai Q, Xue M, Yong VW. Microglia and macrophage phenotypes in intracerebral haemorrhage injury: therapeutic opportunities. *Brain* 2020;143:1297–1314. doi:10.1093/brain/awz393.
- An SJ, Kim TJ, Yoon B-W. Epidemiology, risk factors, and clinical features of intracerebral hemorrhage: an update. *J Stroke* 2017;19:3–10.
- Wilson D, Adams ME, Robertson F, *et al*. Investigating intracerebral haemorrhage. *BMJ* 2015;350:h2484.
- Joundi RA, Martino R, Saposnik G, *et al*. Dysphagia screening after intracerebral hemorrhage. *Stroke* 2017;1747493017729265.
- Planton M, Raposo N, Danet L, *et al*. Impact of spontaneous intracerebral hemorrhage on cognitive functioning: an update. *Rev Neurol* 2017;173:481–9.
- Stern-Nezer S, Eynhorn I, Mlynash M, *et al*. Depression one year after hemorrhagic stroke is associated with late worsening of outcomes. *NeuroRehabilitation* 2017;41:179–87.

- 11 Ghougassian DF, Beran RG. Facial pain as a presenting feature of intracerebral haemorrhage. *Journal of Clinical Neuroscience* 2000;7:343–5.
- 12 Raison JS, Bourbotte G, Baum TP, et al. [Primary brain stem hemorrhage: retrospective study of 25 cases]. *Rev Neurol* 2008;164:225–32.
- 13 Mayo NE, Neville D, Kirkland S, et al. Hospitalization and case-fatality rates for stroke in Canada from 1982 through 1991. The Canadian Collaborative Study group of stroke hospitalizations. *Stroke* 1996;27:1215–20.
- 14 Charidimou A, Morotti A, Valenti R, et al. Journal Club: time trends in incidence, case fatality, and mortality of intracerebral hemorrhage: table. *Neurology* 2016;86:e206–9.
- 15 Roquer J, Rodríguez-Campello A, Jiménez-Conde J, et al. Sex-Related differences in primary intracerebral hemorrhage. *Neurology* 2016;87:257–62.
- 16 Chen C-J, Ding D, Ironside N, et al. Cigarette smoking history and functional outcomes after spontaneous intracerebral hemorrhage. *Stroke* 2019;50:588–94.
- 17 Chen C-J, Brown WM, Moomaw CJ, et al. Alcohol use and risk of intracerebral hemorrhage. *Neurology* 2017;88:2043–51.
- 18 Mustanoja S, Strbian D, Putaala J, et al. Association of prestroke statin use and lipid levels with outcome of intracerebral hemorrhage. *Stroke* 2013;44:2330–2.
- 19 Kim TJ, Kim CK, Kim Y, et al. Prolonged sleep increases the risk of intracerebral haemorrhage: a nationwide case–control study. *Eur J Neurol* 2016;23:1036–43.
- 20 Almaghrabi TS, McDonald MM, Cai C, et al. Cocaine use is associated with more rapid clot formation and weaker clot strength in acute stroke patients. *Int J Cerebrovasc Dis Stroke* 2019;2.
- 21 van Asch CJJ, Luitse MJA, Rinkel GJE, et al. Incidence, case fatality, and functional outcome of intracerebral haemorrhage over time, according to age, sex, and ethnic origin: a systematic review and meta-analysis. *Lancet Neurol* 2010;9:167–76.
- 22 Carpenter AM, Singh IP, Gandhi CD, et al. Genetic risk factors for spontaneous intracerebral haemorrhage. *Nat Rev Neurol* 2016;12:40–9.
- 23 Li W, Jin C, Vaidya A, et al. Blood pressure trajectories and the risk of intracerebral hemorrhage and cerebral infarction. *Hypertension* 2017;70:508–14.
- 24 Bertram M, Bonsanto M, Hacke W, et al. Managing the therapeutic dilemma: patients with spontaneous intracerebral hemorrhage and urgent need for anticoagulation. *J Neurol* 2000;247:209–14.
- 25 Tomonaga M. Cerebral amyloid angiopathy in the elderly. *J Am Geriatr Soc* 1981;29:151–7.
- 26 Aygun N, Masaryk TJ. Diagnostic imaging for intracerebral hemorrhage. *Neurosurg Clin N Am* 2002;13:313–34.
- 27 Navratil O, Duris K, Juran V, et al. Middle cerebral artery aneurysms with intracerebral hematoma—the impact of side and volume on final outcome. *Acta Neurochir* 2017;159:543–7.
- 28 Woo D, Broderick JP. Spontaneous intracerebral hemorrhage: epidemiology and clinical presentation. *Neurosurg Clin N Am* 2002;13:265–79.
- 29 Garcia JH, Ho KL, Caccamo DV. Intracerebral hemorrhage: pathology of selected topics.. In: Kase CS, Caplan LR, eds. *Intracerebral hemorrhage*. Boston: Butterworth-Heinemann, 1994: 45–72.
- 30 Volpe JJ. *Neurology of the newborn*. 4th edn. Philadelphia: W.B. Saunders, 2001.
- 31 Marsh EB, Llinas RH, Hillis AE, et al. Hemorrhagic transformation in patients with acute ischaemic stroke and an indication for anticoagulation. *Eur J Neurol* 2013;20:962–7.
- 32 Sharma A, Whitesell RT, Moran KJ. Imaging pattern of intracranial hemorrhage in the setting of posterior reversible encephalopathy syndrome. *Neuroradiology* 2010;52:855–63.
- 33 Esfahani NZ, Anderson DM, Pieper C, et al. Intracerebral hemorrhage after IV tPA for stroke as early symptom of ANCA-associated vasculitis. *eNeurologicalSci* 2017;9:1–2.
- 34 Salaun E, Touil A, Hubert S, et al. Intracranial haemorrhage in infective endocarditis. *Arch Cardiovasc Dis* 2018;111:712–21.
- 35 Murthy SB, Merkler AE, Omran SS, et al. Outcomes after intracerebral hemorrhage from arteriovenous malformations. *Neurology* 2017;88:1882–8.
- 36 Kim H, Nelson J, Krings T, et al. Hemorrhage rates from brain arteriovenous malformation in patients with hereditary hemorrhagic telangiectasia. *Stroke* 2015;46:1362–4.
- 37 Flemming KD, Brown RD, Link MJ. Seasonal variation in hemorrhage and focal neurologic deficit due to intracerebral cavernous malformations. *J Clin Neurosci* 2015;22:969–71.
- 38 Shakibajahromi B, Borhani-Haghighi A, Ghaedian M, et al. Early, delayed, and expanded intracranial hemorrhage in cerebral venous thrombosis. *Acta Neurol Scand* 2019;140:435–42.
- 39 Gulati S, Solheim O, Carlsen SM, et al. Risk of intracranial hemorrhage (rich) in users of oral antithrombotic drugs: nationwide pharmacoepidemiological study. *PLoS One* 2018;13:e0202575.
- 40 Qureshi AI, Tuhim S, Broderick JP, et al. Spontaneous intracerebral hemorrhage. *N Engl J Med* 2001;344:1450–60.
- 41 Dastur CK, Yu W. Current management of spontaneous intracerebral haemorrhage. *BMJ* 2017;2:21–9.
- 42 Appleton JP, Sprigg N, Bath PM. Blood pressure management in acute stroke. *BMJ* 2016;1:72–82.
- 43 Lindsberg PJ, Roine RO. Hyperglycemia in acute stroke. *Stroke* 2004;35:363–4.
- 44 Fernandes HM, Gregson B, Siddique S, et al. Surgery in intracerebral hemorrhage. The uncertainty continues. *Stroke* 2000;31:2511–6.
- 45 Kelly PJ, Furie KL, Shafiqat S, et al. Functional recovery following rehabilitation after hemorrhagic and ischemic stroke. *Arch Phys Med Rehabil* 2003;84:968–72.
- 46 Xue M, Balasubramaniam J, Buist RJ, et al. Periventricular/Intraventricular hemorrhage in neonatal mouse cerebrum. *J Neuropathol Exp Neurol* 2003;62:1154–65.
- 47 Xue M, Del Bigio MR. Acute tissue damage after injections of thrombin and plasmin into rat striatum. *Stroke* 2001;32:2164–9.
- 48 Xue M, Del Bigio MR. Intracerebral injection of autologous whole blood in rats: time course of inflammation and cell death. *Neurosci Lett* 2000;283:230–2.
- 49 Xue M, Del Bigio MR. Intracortical hemorrhage injury in rats : relationship between blood fractions and brain cell death. *Stroke* 2000;31:1721–7.
- 50 Kagan A, Harris BR, Winkelstein W, et al. Epidemiologic studies of coronary heart disease and stroke in Japanese men living in Japan, Hawaii and California: demographic, physical, dietary and biochemical characteristics. *J Chronic Dis* 1974;27:345–64.
- 51 Kaufman HH, Pruessner JL, Bernstein DP, et al. A rabbit model of intracerebral hematoma. *Acta Neuropathol* 1985;65:318–21.
- 52 Kobari M, Gotoh F, Tomita M, et al. Bilateral hemispheric reduction of cerebral blood volume and blood flow immediately after experimental cerebral hemorrhage in cats. *Stroke* 1988;19:991–6.
- 53 Wagner KR, Xi G, Hua Y, et al. Ultra-early clot aspiration after lysis with tissue plasminogen activator in a porcine model of intracerebral hemorrhage: edema reduction and blood-brain barrier protection. *J Neurosurg* 1999;90:491–8.
- 54 Bullock R, Brock-Utne J, van Dellen J, et al. Intracerebral hemorrhage in a primate model: effect on regional cerebral blood flow. *Surg Neurol* 1988;29:101–7.
- 55 Sinar EJ, Mendelow AD, Graham DI, et al. Experimental intracerebral hemorrhage: effects of a temporary mass lesion. *J Neurosurg* 1987;66:568–76.
- 56 Kingman TA, Mendelow AD, Graham DI, et al. Experimental intracerebral mass: time-related effects on local cerebral blood flow. *J Neurosurg* 1987;67:732–8.
- 57 Kingman TA, Mendelow AD, Graham DI, et al. Experimental intracerebral mass: description of model, intracranial pressure changes and neuropathology. *J Neuropathol Exp Neurol* 1988;47:128–37.
- 58 Lopez Valdes E, Hernandez Lain A, Calandre L, et al. Time window for clinical effectiveness of mass evacuation in a rat balloon model mimicking an intraparenchymatous hematoma. *J Neurol Sci* 2000;174:40–6.
- 59 Nehls DG, Mendelow DA, Graham DI, et al. Experimental intracerebral hemorrhage: early removal of a spontaneous mass lesion improves late outcome. *Neurosurgery* 1990;27:674–82.
- 60 Ichimi K, Kuchiwaki H, Inao S, et al. Responses of cerebral blood flow regulation to activation of the primary somatosensory cortex during electrical stimulation of the forearm. *Acta Neurochir Suppl* 1997;70:291–2.
- 61 Xi G, Wagner KR, Keep RF, et al. Role of blood clot formation on early edema development after experimental intracerebral hemorrhage. *Stroke* 1998;29:2580–6.
- 62 Del Bigio MR, Yan HJ, Buist R, et al. Experimental intracerebral hemorrhage in rats. magnetic resonance imaging and histopathological correlates. *Stroke* 1996;27:2312–20.
- 63 Xue M, Balasubramaniam J, Bigio M. Brain inflammation following intracerebral hemorrhage. *Current Neuropharmacology* 2003;1:325–32.
- 64 Xue M, Del Bigio MR. Comparison of brain cell death and inflammatory reaction in three models of intracerebral hemorrhage in adult rats. *J Stroke Cerebrovasc Dis* 2003;12:152–9.



- 65 Qureshi AI, Wilson DA, Hanley DF, *et al.* No evidence for an ischemic penumbra in massive experimental intracerebral hemorrhage. *Neurology* 1999;52:266–72.
- 66 Andaluz N, Zuccarello M, Wagner KR. Experimental animal models of intracerebral hemorrhage. *Neurosurg Clin N Am* 2002;13:385–93.
- 67 Wagner KR, Xi GH, Hua Y, *et al.* Lobar intracerebral hemorrhage model in pigs: rapid edema development in perihematomal white matter. *Stroke* 1996;27:490–7.
- 68 Wagner KR, Xi G, Hua Y, *et al.* Early metabolic alterations in edematous perihematomal brain regions following experimental intracerebral hemorrhage. *J Neurosurg* 1998;88:1058–65.
- 69 Narayan RK, Narayan TM, Katz DA, *et al.* Lysis of intracranial hematomas with urokinase in a rabbit model. *J Neurosurg* 1985;62:580–6.
- 70 Xi G, Keep RF, Hoff JT. Erythrocytes and delayed brain edema formation following intracerebral hemorrhage in rats. *J Neurosurg* 1998;89:991–6.
- 71 Altieri DC. Interface between inflammation and coagulation. In: Ley K, ed. *Physiology of inflammation*. New York: Oxford University Press, 2001: 402–22.
- 72 Hua Y, Xi G, Keep RF, *et al.* Complement activation in the brain after experimental intracerebral hemorrhage. *J Neurosurg* 2000;92:1016–22.
- 73 Rosenberg GA, Estrada E, Kelley RO, *et al.* Bacterial collagenase disrupts extracellular matrix and opens blood-brain barrier in rat. *Neurosci Lett* 1993;160:117–9.
- 74 Rosenberg GA, Mun-Bryce S, Wesley M, *et al.* Collagenase-Induced intracerebral hemorrhage in rats. *Stroke* 1990;21:801–7.
- 75 Rosenberg GA, Navratil M. Metalloproteinase inhibition blocks edema in intracerebral hemorrhage in the rat. *Neurology* 1997;48:921–6.
- 76 Rosenberg GA, Kornfeld M, Estrada E, *et al.* Timp-2 reduces proteolytic opening of blood-brain barrier by type IV collagenase. *Brain Res* 1992;576:203–7.
- 77 Rosenberg GA, Estrada EY. Atrial natriuretic peptide blocks hemorrhagic brain edema after 4-hour delay in rats. *Stroke* 1995;26:874–7.
- 78 Xue M, Bigio MR. Injections of blood, thrombin, and plasminogen more severely damage neonatal mouse brain than mature mouse brain. *Brain Pathol* 2005;15:273–80.
- 79 Gao F, Liu F, Chen Z, *et al.* Hydrocephalus after intraventricular hemorrhage: the role of thrombin. *J Cereb Blood Flow Metab* 2014;34:489–94.
- 80 Yang Y, Zhang M, Kang X, *et al.* Thrombin-Induced microglial activation impairs hippocampal neurogenesis and spatial memory ability in mice. *Behav Brain Funct* 2015;11:30.
- 81 Liard JF, Cowley AW, McCaa RE, *et al.* Renin, aldosterone, body fluid volumes, and the baroreceptor reflex in the development and reversal of Goldblatt hypertension in conscious dogs. *Circ Res* 1974;34:549–60.
- 82 Zeng J, Zhang Y, Mo J, *et al.* Two-Kidney, two clip renovascular hypertensive rats can be used as stroke-prone rats. *Stroke* 1998;29:1708–14.
- 83 Okamoto K, Yamori Y, Nagaoka A. Establishment of the stroke-prone spontaneously hypertensive rat. *Circ Res* 1974;35:143–53.
- 84 Goddard-Finegold J. Experimental models of intraventricular hemorrhage. In: Pape KE, Wigglesworth JS, eds. *Perinatal brain lesions*. Boston MA: Blackwell Scientific, 1989: 115–33.
- 85 Conner ES, Lorenzo AV, Welch K, *et al.* The role of intracranial hypotension in neonatal intraventricular hemorrhage. *J Neurosurg* 1983;58:204–9.
- 86 Lorenzo AV, Welch K, Conner S. Spontaneous germinal matrix and intraventricular hemorrhage in prematurely born rabbits. *J Neurosurg* 1982;56:404–10.
- 87 Goddard J, Lewis RM, Armstrong DL, *et al.* Moderate, rapidly induced hypertension as a cause of intraventricular hemorrhage in the newborn beagle model. *J Pediatr* 1980;96:1057–60.
- 88 Batton DG, Nardis EE. The effect of intraventricular blood on cerebral blood flow in newborn dogs. *Pediatr Res* 1987;21:511–5.
- 89 Yoshioka H, Iino S, Sato N, *et al.* New model of hemorrhagic hypoxic-ischemic encephalopathy in newborn mice. *Pediatr Neurol* 1989;5:221–5.
- 90 Papile L-A, Burstein J, Burstein R, *et al.* Incidence and evolution of subependymal and intraventricular hemorrhage: a study of infants with birth weights less than 1,500 GM. *J Pediatr* 1978;92:529–34.
- 91 Cherian SS, Love S, Silver IA, *et al.* Posthemorrhagic ventricular dilation in the neonate: development and characterization of a rat model. *J Neuropathol Exp Neurol* 2003;62:292–303.
- 92 Hudgins RJ. Posthemorrhagic hydrocephalus of infancy. *Neurosurg Clin N Am* 2001;12:743–51.
- 93 Funnell WRJ, Maysinger D, Cuello AC. Three-Dimensional reconstruction and quantitative evaluation of devascularizing cortical lesions in the rat. *J Neurosci Methods* 1990;35:147–56.
- 94 Herrera DG, Cuello AC. Glial fibrillary acidic protein immunoreactivity following cortical devascularizing lesion. *Neuroscience* 1992;49:781–91.
- 95 Smith SL, Andrus PK, Gleason DD, *et al.* Infant rat model of the Shaken baby syndrome: preliminary characterization and evidence for the role of free radicals in cortical hemorrhaging and progressive neuronal degeneration. *J Neurotrauma* 1998;15:693–705.
- 96 Morganti-Kossmann MC, Rancan M, Otto VI, *et al.* Role of cerebral inflammation after traumatic brain injury: a revisited concept. *Shock* 2001;16:165–77.
- 97 Morganti-Kossmann MC, Rancan M, Stahel PF, *et al.* Inflammatory response in acute traumatic brain injury: a double-edged sword. *Curr Opin Crit Care* 2002;8:101–5.
- 98 Ghirnikar RS, Lee YL, Eng LF. Inflammation in traumatic brain injury: role of cytokines and chemokines. *Neurochem Res* 1998;23:329–40.
- 99 Baron J-C. Mapping the ischaemic penumbra with PET: implications for acute stroke treatment. *Cerebrovasc Dis* 1999;9:193–201.
- 100 Obrenovitch TP. The ischaemic penumbra: twenty years on. *Cerebrovasc Brain Metabol Rev* 1995;7:297–323.
- 101 Towbin A. Cerebral intraventricular hemorrhage and subependymal matrix infarction in the fetus and premature newborn. *Am J Pathol* 1968;52:121–40.
- 102 Lee KR, Betz AL, Kim S, *et al.* The role of the coagulation cascade in brain edema formation after intracerebral hemorrhage. *Acta Neurochir* 1996;138:396–401.
- 103 Wan J, Ren H, Wang J. Iron toxicity, lipid peroxidation and ferroptosis after intracerebral haemorrhage. *Stroke Vasc Neurol* 2019;4:93–5.
- 104 Mendelow AD. Mechanisms of ischemic brain damage with intracerebral hemorrhage. *Stroke* 1993;24:115–7.
- 105 Lee KR, Kawai N, Kim S, *et al.* Mechanisms of edema formation after intracerebral hemorrhage: effects of thrombin on cerebral blood flow, blood-brain barrier permeability, and cell survival in a rat model. *J Neurosurg* 1997;86:272–8.
- 106 Leech RW, Kohlen P. Subependymal and intraventricular hemorrhages in the newborn. *Am J Pathol* 1974;77:465–75.
- 107 Regan RF, Guo Y. Toxic effect of hemoglobin on spinal cord neurons in culture. *J Neurotrauma* 1998;15:645–53.
- 108 Chang C-F, Massey J, Oshero A, *et al.* Bexarotene enhances macrophage erythrophagocytosis and hematoma clearance in experimental intracerebral hemorrhage. *Stroke* 2020;51:612–8.
- 109 Narayanan S. Multifunctional roles of thrombin. *Ann Clin Lab Sci* 1999;29:275–80.
- 110 Murphy P. *The neutrophil*. New York: Plenum Medical Book Co, 1976.
- 111 Gong Y, Xi G, Wan S, *et al.* Effects of aging on complement activation and neutrophil infiltration after intracerebral hemorrhage. *Acta Neurochir Suppl* 2008;105:67–70.
- 112 Ziai WC. Hematology and inflammatory signaling of intracerebral hemorrhage. *Stroke* 2013;44:S74–8.
- 113 Zhou Y, Wang Y, Wang J, *et al.* Inflammation in intracerebral hemorrhage: from mechanisms to clinical translation. *Prog Neurobiol* 2014;115:25–44.
- 114 Johnson KJ, Varani J, Smolen JE. Neutrophil activation and function in health and disease. In: Coffey RG, ed. *Granulocyte responses to cytokines*. New York: Marcel Dekker Inc, 1992: 1–46.
- 115 Shiga Y, Onodera H, Kogure K, *et al.* Neutrophil as a mediator of ischemic edema formation in the brain. *Neurosci Lett* 1991;125:110–2.
- 116 Huttner HB, Kuramatsu JB. [Current treatment concepts in intracerebral hemorrhage]. *Med Klin Intensivmed Notfmed* 2017;112:695–702.
- 117 Nishino A, Suzuki M, Ohtani H, *et al.* Thrombin may contribute to the pathophysiology of central nervous system injury. *J Neurotrauma* 1993;10:167–79.
- 118 Rosenberg GA. Matrix metalloproteinases in brain injury. *J Neurotrauma* 1995;12:833–42.
- 119 Yong VW, Power C, Forsyth P, *et al.* Metalloproteinases in biology and pathology of the nervous system. *Nat Rev Neurosci* 2001;2:502–11.
- 120 Rosenberg GA. Matrix metalloproteinases in neuroinflammation. *Glia* 2002;39:279–91.
- 121 Pfefferkorn T, Wiessner C, Allegrini PR, *et al.* Plasminogen activation in experimental permanent focal cerebral ischemia. *Brain Res* 2000;882:19–25.

- 122 Pfefferkorn T, Stauffer B, Liebetrau M, *et al.* Plasminogen activation in focal cerebral ischemia and reperfusion. *J Cereb Blood Flow Metab* 2000;20:337–42.
- 123 van Beek J, Elward K, Gasque P. Activation of complement in the central nervous system: roles in neurodegeneration and neuroprotection. *Ann N Y Acad Sci* 2003;992:56–71.
- 124 Xi G, Reiser G, Keep RF. The role of thrombin and thrombin receptors in ischemic, hemorrhagic and traumatic brain injury: deleterious or protective? *J Neurochem* 2003;84:3–9.
- 125 Lee KR, Colon GP, Betz AL, *et al.* Edema from intracerebral hemorrhage: the role of thrombin. *J Neurosurg* 1996;84:91–6.
- 126 Sheng Z, Liu Y, Li H, *et al.* Efficacy of minocycline in acute ischemic stroke: a systematic review and meta-analysis of rodent and clinical studies. *Front Neurol* 2018;9:1103.
- 127 Tschöe C, Bushnell CD, Duncan PW, *et al.* Neuroinflammation after intracerebral hemorrhage and potential therapeutic targets. *J Stroke* 2020;22:29–46.
- 128 Eun Jung J, Sun G, Bautista Garrido J, *et al.* The mitochondria-derived peptide humanin improves recovery from intracerebral hemorrhage: implication of mitochondria transfer and microglia phenotype change. *J Neurosci* 2020:2212–9.