



Scrotal liposarcoma – a rare extratesticular tumour

Nimesh G Patel • Ananth Rajagopalan • Nitin S Shrotri

Department of Urology, Kent and Canterbury Hospital, Canterbury, Kent, UK

Correspondence to: Nimesh G Patel. Email: dr.nimeshpatel1@gmail.com

Any painless, echogenic, avascular mass on ultrasound scanning should arouse suspicion of a liposarcoma or other similar tumours.

DECLARATIONS

Competing interests

None declared

Funding

None

Ethical approval

Written informed consent to publication was obtained from the patient or next of kin

Guarantor

NSS

Contributorship

All authors contributed equally

Acknowledgements

None

Reviewer

Muhammad Khan

Introduction

Scrotal and inguinal masses are common patient complaints that prove diagnostically challenging due to the multiple anatomic structures found in the confined space of the scrotum.¹

History and adequate examination is the cornerstone in diagnosing scrotal pathology. Ultrasonography is the principle radiologic study used to evaluate scrotal masses. This can locate the site of a mass, and differentiate between solid and cystic lesions. The Doppler feature can also be used to evaluate blood flow. Occasionally CT or MRI is used if ultrasound is inconclusive, and usually precedes scrotal exploration.¹

Scrotal masses can be testicular or paratesticular. Paratesticular masses are usually benign, with adenomatoid tumours being the most common, representing 30% of paratesticular masses and 77% of benign tumours arising from the epididymis.² They usually occur in the 20–40-year age group but can present at any age, are 0.5–5 cm in size, and slow-growing. Papillary cystadenomas and leiomyomas account for most of the other benign solid tumours.²

Primary malignancies of the epididymis or paratesticular structures are extremely rare in adults. These are adenocarcinomas, and sarcomas including rhabdomyosarcoma, leiomyosarcomas and liposarcomas.³

Liposarcoma is the second most common soft tissue tumour in adults, with an incidence ranging from 9.8–16.0%.⁴ According to the 2002 World Health Organization (WHO) histological classification of tumours, liposarcoma can be

divided into five categories: atypical lipomatous tumour/well-differentiated; dedifferentiated; myxoid; pleomorphic; and mixed-type liposarcoma. Liposarcoma of the spermatic cord is however a rare condition, representing about 7% of paratesticular sarcomas.⁵

Case report

A 53-year-old man presented to the outpatient department with an eight-month history of a painless right-sided scrotal swelling which exacerbated on exertion. An ultrasound scan carried out at the time had suggested an inguinal hernia to be the cause. Clinically, however, the swelling was not typical of an inguinal hernia so an MRI scan was performed (Figure 1). The findings were interpreted as an inguinal hernia containing omentum protruding into the scrotum. There was no suspicion of malignancy to be the cause at the time.

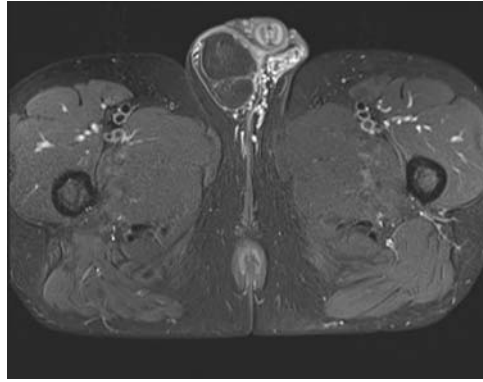
The patient went on to have elective surgery as part of his treatment. During surgery a lipomatous mass was found, that was separate from the right spermatic cord. The size of the mass was 100 x 85 x 45 mm, and this was primarily excised and sent to the pathology laboratory. Histology revealed a small lesion within this mass typical of a well-differentiated liposarcoma, with clear margins.

Tertiary centre advice was sought, and a staging CT scan of the chest, abdomen and pelvis was undertaken. This did not show any evidence of metastasis, thus active surveillance was suggested with no further intervention necessary.

Discussion

The scrotum contains the epididymis, spermatic cord and fascia that accompany the testis during the embryologic journey from pelvis into the

Figure 1
MRI image of right scrotal liposarcoma



scrotum. The majority of tumours arising from these extratesticular structures are benign and arise from the spermatic cord, lipoma being the commonest.⁶ Lipomas can be unilateral or bilateral, and often present as an asymptomatic fullness of the spermatic cord. They can usually be distinguished from inguinal hernias by noting an intact external inguinal ring on examination.

More than 50% of the spermatic cord tumours are malignant, if lipomas are excluded.⁷ The most common malignant tumours are sarcomas; rhabdomyosarcoma in children and liposarcoma in adults.⁸ The majority of these sarcomas arise just inferior to the superficial inguinal ring, hence they present mainly as a scrotal rather than as an abdominal mass.⁹

Liposarcoma is a solid, bulky lipomatous tumour with heterogeneous architecture, often containing areas of calcification and appear yellow on gross appearance.⁸ They occur in the middle-aged and elderly,¹⁰ and represent 10–20% of all malignant extratesticular tumours.¹⁰ The round cell type is poorly differentiated and is highly metastatic.

Ultrasound appearance is variable and non-specific but the presence of a lipomatous matrix can raise suspicion.⁷ It can also show areas of heterogeneous echogenicity corresponding to a non-lipomatous component. CT and MR imaging are more specific, as they can easily recognize fatty components and differentiate these areas from other soft tissue components.¹⁰

An association of scrotal liposarcoma has been reported with multiple liposarcoma of the

retroperitoneum in a case of multicentric liposarcoma.⁹ This association makes scrutiny of the entire abdomen mandatory in such cases.

Other non-lipomatous malignant tumours that are included in the differential diagnosis include lymphoma, malignant fibrous histiocytoma and mesothelioma.⁹ Mesothelioma is often associated with a hydrocoele and lymphoma may be indicated by other tell-tale symptoms and signs.

The majority of liposarcoma arising from the spermatic cord are well-differentiated, and the treatment of choice is hemiscrotectomy with wide excision of the inguinal soft tissues and lymph nodes, especially if the tumour margins are ill-defined, to prevent tumour recurrences.⁷ Recurrences are seen in one-quarter of patients and metastases are seen in one-tenth of patients with spermatic cord liposarcoma through lymphatic or hematogenous spread.² If a sufficient tumour-free margin cannot be achieved, adjuvant radiotherapy covering the inguinal region and scrotum should be considered.⁷

Though most extratesticular tumours are benign, any painless echogenic mass with heterogeneous architecture on ultrasound and a relatively low vascularity, should arouse the suspicion of a liposarcoma.^{7,8} CT and MR imaging can be used as an additional problem solving tool in difficult cases by adding more confidence in recognizing fat and other soft tissue components separately, while simultaneously ruling out true lipoma and omental herniae.^{7,8}

When evaluating a scrotal mass, a careful history and inguinoscrotal examination is necessary. Malignant scrotal wall, paratesticular and spermatic cord tumours are rare, but all masses deserve a formal work-up with serum tumour markers, a scrotal ultrasound scan and specialist consultation as required for further staging and intervention. Scrotal masses in children are much rarer, and should always be evaluated by a urologist.

References

- 1 Montgomery JS, Bloom DA. The diagnosis and management of scrotal masses. *Med Clin North Am* 2011;**95**:235–44
- 2 Rypens F, Garel L, Franc-Guimond J, *et al.* Paratesticular rhabdomyosarcoma presenting as thickening of the tunica vaginalis. *Pediatr Radiol* 2009;**39**:1010–12
- 3 Hashimoto H, Enjoi M. Liposarcoma: a clinicopathologic subtyping of 52 cases. *Acta Pathol Jpn* 1982;**32**:933

- 4 Sogani PC, Grabstald H, Withmore WJ. Spermatic cord sarcoma in adults. *J Urol* 1978;**120**:301
- 5 Beccia DJ, Krane RJ, Olsson CA. Clinical management of non-testicular intrascrotal tumours. *J Urol* 1976;**116**:476–9
- 6 Maximilian B, Joachim T, Sebastian M. Liposarcoma of the spermatic cord: Report of two cases and review of the literature. *Internet Journal of Urology* 2005;**3**:1
- 7 Cardenosa G, Papanicolaou N, Fung CY, *et al.* Spermatic cord sarcomas: sonographic and CT features. *Urol Radiol* 1990;**12**:163–7
- 8 Bostwick DG. Spermatic cord testicular adnexa. In: Bostwick DG, Eble JN, eds. *Urologic surgical pathology*. St Louis, MO: Mosby, 1997:647–74
- 9 Thanakit V, Nelson SD, Udomsawaengsup S. Round cell liposarcoma of scrotum with indolent course in young adult. *J Med Assoc Thai* 2005;**88**:1302–7
- 10 Michihiko H, Nobutaka K, Toshiyuk N, Naohiko K, Wataru A, Jun A. Liposarcoma Situated in the Scrotum to Retroperitoneum: A Case Report. *J Jpn Surg Assoc* 2002;**63**:1279–82

© 2011 Royal Society of Medicine Press

This is an open-access article distributed under the terms of the Creative Commons Attribution License (<http://creativecommons.org/licenses/by-nc/2.0/>), which permits non-commercial use, distribution and reproduction in any medium, provided the original work is properly cited.