

C1–C2 pedicle screw fixation for adolescent with os odontoideum associated atlantoaxial dislocation and a compound reduction technique for irreducible atlantoaxial dislocation

Jia Liu¹, Ling-Jun Zhu¹, En-Ze Jiang¹, Xiao-Gang Bao¹, Bo Hu², Dong-Yang Niu¹, Guo-Hua Xu¹

¹Department of Orthopaedic Surgery, Spine Center, Changzheng Hospital, Second Military Medical University, Shanghai 200003, China;

²Jiangxi Province Hospital of Integrated Chinese & Western Medicine, Nanchang, Jiangxi 330000, China.

To the Editor: Os odontoideum (OO) is a rare congenital anomaly of the second cervical vertebra that is defined as occurring when an independent ossicle is separated from the base of the odontoid process.^[1] In general, it requires surgeries for the patients who suffer from OO-associated atlantoaxial dislocation (AAD), especially for young patients due to their immature bones and the unavoidable tumbles and physical impacts in their daily lives.^[2] In clinical practice, the use of posterior screw-rod fixation systems enables unique three-dimensional fixation. The use of these systems can provide effective correction and bone fusion for OO-associated AAD.^[3] For the treatment of irreducible atlantoaxial dislocation (IrAAD), posterior stabilization, and the use of additional transoral decompression were thought to be necessary, as reported in the literature.^[4] To our knowledge, few procedures have been proven to be simple and effective treatments for IrAAD. In our study, we enrolled 15 adolescents with OO-associated AAD that was treated with modified C1–C2 pedicle screw fixation, and for the patients who failed to benefit from pre-operation skull traction, we administered a direct posterior compound reduction technique.

The medical records of 15 adolescent patients (11–18 years old, mean age 13 years; nine males, six females) diagnosed as having OO-associated AAD who were treated in our department between January 2014 and September 2016 were retrospectively reviewed. The clinical signs and symptoms were measured as neck disability index (NDI) and Japanese Orthopedic Association scores (JOA). All patients underwent X-rays, computerized tomography (CT) scanning, and magnetic resonance imaging (MRI) before surgery. Attention was paid to bone anatomy and the course of the vertebral artery. Six radiographic parameters were measured through the lateral films or midline tomograms of the upper cervical spine with the

neck in a neutral position, flexion, or extension. The inner diameter of the atlantal ring (D_{atl}) was measured from the OO to the posterior atlantal arch. The smallest diameter of the spinal canal (D_{min}) and maximum distance (D_{max}) were measured as the distance between the posterior border of the body of C2 and the posterior atlantal arch during the flexion or extension of the neck. The atlantodens interval (ADI) was measured as the distance between the posterior border of the body of C1 and the anterior border of the OO. The instability index^[5] was calculated thusly:
$$\text{Instability index} = \frac{D_{max} - D_{min}}{D_{max}} \times 100\%.$$
 The cervicomedullary angle (CMA) reflects the degree of the compression of the cervical spinal cord.^[6] All patients underwent skull traction (3–5 kg for 1–2 weeks) before surgery, and radiographs were obtained to evaluate the reduction of C1–C2 joints during the process. A total of 11 patients achieved the satisfactory reduction, and four patients exhibited no reduction in C1–C2 dislocation after traction.

Under general anesthesia, the patient was placed prone with persistent skull traction (1/12 of the body weight). Then a standard posterior midline incision of the occiput-C3 junction was made. The local lateral capsule of the atlantoaxial facet joint was released, scars and osteophytes were removed using a high-speed burr until the mobility between C1 and C2 could be felt. The C1 and C2 pedicle screws were implanted as described by Harm *et al.*^[3] For OO with IrAAD, the rod was first tightened over the C2 screw head. Then C1 and C2 screws were detracted to loosen the joint, and the base of the C2 spinous process was pushed ventrally. The C2 vertebral body was pulled forward and downward using the lever principle. In the presence of rotational dislocation that prevented the correction of antero-posterior movement in the C1–C2 joint, the rotational component was corrected by applying differential force on right and left sides to loosen the joint

Access this article online

Quick Response Code:



Website:
www.cmj.org

DOI:
10.1097/CM9.0000000000000224

Correspondence to: Dr. Guo-Hua Xu, Department of Orthopaedic Surgery, Spine Center, Changzheng Hospital, Second Military Medical University, No. 415 Feng Yang Road, Shanghai 200003, China
E-Mail: xuguohuamail@smmu.edu.cn

Copyright © 2019 The Chinese Medical Association, produced by Wolters Kluwer, Inc. under the CC-BY-NC-ND license. This is an open access article distributed under the terms of the Creative Commons Attribution-Non Commercial-No Derivatives License 4.0 (CCBY-NC-ND), where it is permissible to download and share the work provided it is properly cited. The work cannot be changed in any way or used commercially without permission from the journal.

Chinese Medical Journal 2019;132(10)

Received: 15-11-2018 Edited by: Yuan-Yuan Ji

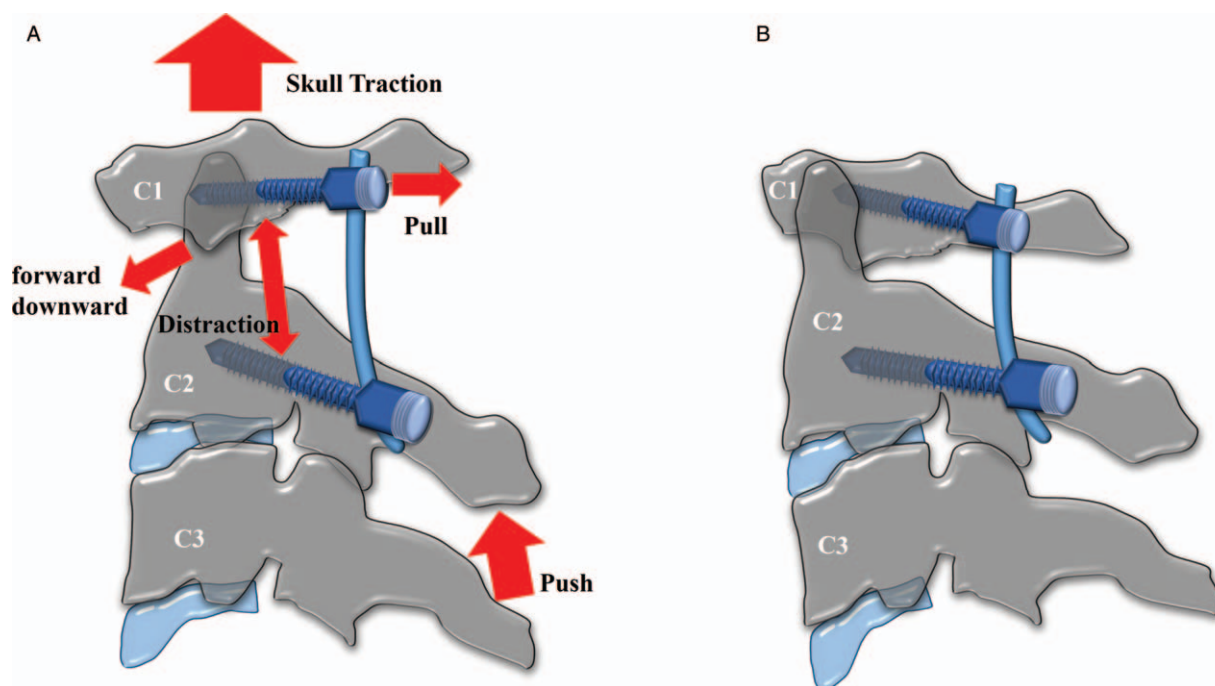


Figure 1: Steps of direct compound reduction technique. (A) and (B) illustrate the steps of the direct compound reduction technique. Under skull traction, the rod was first fastened over C2 screw heads. The base of the C2 spinous process was pushed by finger, and the C1 and C2 screws were detracted to loosen the joint enough. Then the C1 screw was pulled up using a squeeze-down device depending on the direction of shear force. Next, the C1 screw was tightened to its final position when the proper antero-posterior realignment of the C1 and C2 vertebrae was achieved.

enough. Following this, the rod was fastened in its final position and C1 screws were simultaneously pulled up using a squeeze-down device. Next, depending on the direction of shear force, the proper antero-posterior realignment of the C1 and C2 vertebrae was attempted and the C1 screws were retightened. The steps used in the novel direct compound reduction technique are illustrated in Figure 1. All operations were performed under intra-operative neurophysiological monitoring. Following reduction and fixation, an H-shaped autologous iliac crest graft was placed between the posterior arches of the C1 and C2 vertebrae.

The data were analyzed using SPSS software, version 19.0 (IBM, Armonk, NY, USA). The data points were compared using the paired *t* test with statistical significance set at $P < 0.05$.

A total of 15 patients got a satisfied reduction of C1–C2 dislocation after surgery. A total of four patients exhibited irreducibility of C1–C2 dislocation after traction, so the direct posterior compound reduction technique was used to achieve satisfactory C1–C2 realignment. The pre-operative instability index of the 15 patients ranged from 39% to 88.5% (mean $51.2 \pm 13.3\%$). There were no complications like infection, cerebrospinal fluid (CSF) leakage, neurological injury, vascular injury, or re-dislocation. One case is shown in Figure 2.

For the 15 patients with adequate clinical follow-ups, radiographs were obtained over the following 24 to 48 months. Post-operation cervical X-rays showed that the mean time of C1–C2 bony fusion was 3.6 months. The

X-rays showed a significant statistical change of cervical alignment between pre-operation and the last follow-up (the mean C2–C7 Cobb angle changed from $25.3^\circ \pm 12.2^\circ$ to $16.7^\circ \pm 7.5^\circ$) ($P < 0.05$). Post-operative CT scans indicated that all pedicle screws were satisfactorily placed, and post-operative MRI demonstrated that mean CMA values improved from $134.6^\circ \pm 8.2^\circ$ to $152.1^\circ \pm 7.2^\circ$ ($P < 0.05$), indicating that sufficient decompression of the spinal cord was achieved. ADI changed from 1.39 ± 0.70 to 1.38 ± 0.69 ($P = 0.956$) post-operatively. The D_{atl} changed from 16.8 ± 2.2 pre-operatively to 16.97 ± 2.49 ($P = 0.592$) post-operatively. Significant statistical differences between pre-operative and post-operative D_{min} values were identified. The values changed from 9.84 ± 5.03 to 15.45 ± 2.19 ($P < 0.05$) [Supplementary Table 1, <http://links.lww.com/CM9/A32>].

All patients showed clinical improvement. Statistical analyses of all cases revealed that the mean JOA scores improved from 10.9 ± 2.0 pre-operatively (range 6–14) to 14.5 ± 2.0 post-operatively (range 10–17). The mean NDI scores changed from 17.0 ± 7.5 to 9.6 ± 3.9 .

Adolescents are more prone than adults to unavoidable physical impacts in exercise and daily life. Neck pain, torticollis, or neurological symptoms can occur after repeated spinal cord injury. Thus, adolescent patients should undergo C1–C2 fusion concerning the long-term natural course. Although child and adolescent patients present a unique challenge to surgeons due to their small osseous structures and immature bones, the craniovertebral region usually reaches adult size and configuration at approximately 8 to 10 years of age, which provides the

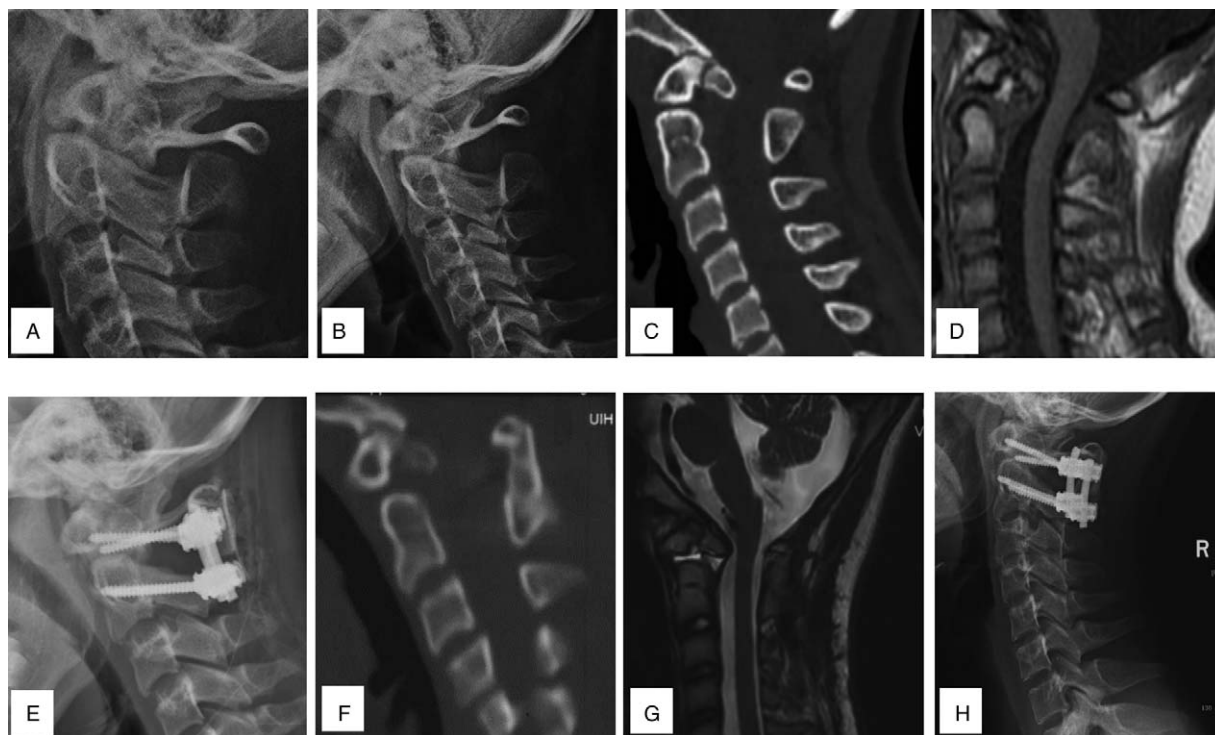


Figure 2: A case of os odontoideum-associated atlantoaxial dislocation. A 13-year-old female presented with obstructed neck movement for 1 year. (A) and (B) Lateral cervical X-ray and in a neutral position and flexion position showed OO-associated AAD. (C) The preoperative CT showed the backward atlantoaxial dislocation with OO (the instability index was 50%). (D) Pre-operative MRI showed ventral compression of the cervical spinal cord (CMA = 130°). (E) Postoperative X-ray showed the realignment of the C1 and C2 vertebrae. (F) Postoperative sagittal CT showed good and realignment of C1 and C2 joints and the longer trajectory of C2 pedicle screw. (G) Posterior MRI showed complete decompression of spinal cord (CMA = 144°). (H) At the 2-year follow-up, there no kyphosis or crankshaft phenomenon were identified in this patient. CMA: Cervicomedullary angle; CT: Computerized tomography; MRI: Magnetic resonance imaging; OO: Os odontoideum.

possibility of using C1–C2 screw-rod constructs in young patients with OO-associated AAD.^[7] A study has proven that posterior C1–C2 screw fixation does not significantly limit the atlantoaxial growth of children over 6 years of age.^[8]

Some adolescent with OO and IrAAD have circumambient scars, osteophytes, and adhesions of the soft tissues and contractures of ligament around the atlantoaxial joint, resulting in the irreducibility of the C1–C2 through skull traction. The transoral approach is routinely used to decompress the cervicomedullary junction before posterior fusion and stabilization, but the disadvantages of the transoral procedure should be paid attention to, including the risk of oral infection, pharyngeal edema, and increased hospitalization costs. With the development of surgical instruments and techniques, the recent trend has shifted from traditional transoral decompression and posterior fusion to the direct posterior release of facets and the reduction of dislocation. Yin *et al*^[9] described effective techniques for dealing with the realignment of irreducible C1–C2 dislocation by directly posteriorly releasing the facets and then reducing them. A total of 26 patients who were diagnosed as having IrAAD, including five with OO and IrAAD, have got effective realignment through Yin *et al*'s technique. Salunke *et al*^[10] supposed that irreducible dislocation might occur in not only the vertical plane but also the lateral or rotational plane. Realignment can be achieved by correcting dislocation in all planes.

Adolescent cervical muscles and articular capsules are loose and adhesions of soft tissue and bony fusions are not so hard that they cannot be released using the posterior approach, realignment could achieve by multiple planes and suitable strength. Therefore, we found that the irreducibility of the C1–C2 shift after skull traction is not an absolute criterion for transoral decompression. We devised our novel method by combining the above techniques in a simple but effective manner that combines continuing intra-operation skull traction, detracting the C1–C2 pedicle screw, and simultaneously pushing the C2 spinous process and pulling up the C1 pedicle screw. In this process, we detracted the C1–C2 screw to provide enough space for the next reduction. Then we reduced the C1 and C2 simultaneously. We set the insertion point of the C2 screw as the pivot point and pushed the C2 spinous process upward so that the C2 vertebral body was pulled forward and downward using the lever principle, in addition to pulling up the C1 pedicle screws. In this study, all four patients with IrAAD received satisfactory realignments through this technique.

It was demonstrated that C1–C2 pedicle screw fixation was used to achieve effective and satisfactory results for the adolescent patients in this study with OO-associated AAD. Furthermore, this direct compound reduction technique was found to achieve satisfactory results for most of the adolescent with OO-associated IrAAD.

Conflicts of interest

None.

References

1. Spierings EL, Braakman R. The management of os odontoideum. Analysis of 37 cases. *J Bone Joint Surg Br* 1982;64:422–428. doi: 10.1302/0301-620X.64B4.7096415.
2. Wang X, Fan CY, Liu ZH. The single transoral approach for Os odontoideum with irreducible atlantoaxial dislocation. *Eur Spine J* 2010;19 Suppl 2:S91–95. doi: 10.1007/s00586-009-1088-4.
3. Harms J, Melcher RP. Posterior C1-C2 fusion with polyaxial screw and rod fixation. *Spine* 2001;26:2467–2471. doi: 10.1097/00007632-200111150-00014.
4. Wu X, Wood KB, Gao Y, Li S, Wang J, Ge T, *et al*. Surgical strategies for the treatment of os odontoideum with atlantoaxial dislocation. *J Neurosurg Spine* 2018;28:131–139. doi: 10.3171/2017.5.SPINE161211.
5. Watanabe M, Toyama Y, Fujimura Y. Atlantoaxial instability in os odontoideum with myelopathy. *Spine* 1996;21:1435–1439. doi: 10.1097/00007632-199606150-00007.
6. Wang S, Wang C, Passias PG, Li G, Yan M, Zhou H. Interobserver and intraobserver reliability of the cervicomedullary angle in a normal adult population. *Eur Spine J* 2009;18:1349–1354. doi: 10.1007/s00586-009-1112-8.
7. Bailey DK. The normal cervical spine in infants and children. *Radiology* 1952;59:712–719. doi: 10.1148/59.5.712.
8. Ma X, Yin Q, Xia H, Wu Z, Yang J, Liu J, *et al*. The application of atlantoaxial screw and rod fixation in revision operations for postoperative re-dislocation in children. *Arch Orthop Trauma Surg* 2015;135:313–319. doi: 10.1007/s00402-014-2150-1.
9. Yin YH, Qiao GY, Yu XG, Tong HY, Zhang YZ. Posterior realignment of irreducible atlantoaxial dislocation with C1-C2 screw and rod system: a technique of direct reduction and fixation. *Spine J* 2013;13:1864–1871. doi: 10.1016/j.spinee.2013.08.014.
10. Salunke P, Sahoo S, Khandelwal NK, Ghuman MS. Technique for direct posterior reduction in irreducible atlantoaxial dislocation: multi-planar realignment of C1-2. *Clin Neurol Neurosurg* 2015; 131:47–53. doi: 10.1016/j.clineuro.2015.01.025.

How to cite this article: Liu J, Zhu LJ, Jiang EZ, Bao XG, Hu B, Niu DY, Xu GH. C1–C2 pedicle screw fixation for adolescent with os odontoideum associated atlantoaxial dislocation and a compound reduction technique for irreducible atlantoaxial dislocation. *Chin Med J* 2019;132:1253–1256. doi:10.1097/CM9.0000000000000224