

Available online at www.sciencedirect.com

ScienceDirect

Biomedical Journal

journal homepage: www.elsevier.com/locate/bj

Original Article

Fracture of cobalt chrome, fully-coat beaded femoral revision long stem, a clinical outcomes study



Chih-Hsiang Chang^{a,b,c,1}, Po-Chun Lin^{d,1}, Cheng-Min Shih^{e,f,1},
Chun-Chieh Chen^{a,b,c}, Pang-Hsin Hsieh^{a,b,c}, Hsin-Nung Shih^{a,b,c,*}

^a Department of Orthopedic Surgery, Chang Gung Memorial Hospital, Linkou, Taiwan

^b College of Medicine, Chang Gung University, Taoyuan, Taiwan

^c Bone and Joint Research Center, Chang Gung Memorial Hospital, Linkou, Taiwan

^d Department of Orthopedic Surgery, Chang Gung Memorial Hospital, Kaohsiung, Taiwan

^e Department of Orthopedic Surgery, Taichung Veterans General Hospital, Taichung City, Taiwan

^f Department of Biological Science and Technology, National Chiao Tung University, Hsinchu, Taiwan

ARTICLE INFO

Article history:

Received 17 February 2017

Accepted 5 February 2018

Available online 30 March 2018

Keywords:

Fractured stem

Revision total hip arthroplasty

Fully-coat beaded long stem

Cobalt chrome stem

ABSTRACT

Background: Femoral bone loss during revision total hip arthroplasty poses a challenging problem. Bypass fixation over the diaphysis has achieved clinical success in cases of proximal femoral bone loss. Fracture of cementless, fully bead-coated femoral stem is an uncommon complication. The purpose of this study is to analyze the patients with and without fracture stem and find out the possible risk factors.

Methods: From 2006 to 2012, a total of 251 revision long stems (Zimmer, Warsaw, IN) were implanted. In the same period, 17 broken stems that underwent treatment were included for analysis. Patients' demographic data, pattern of femoral bone loss, stem size, medial calcar support in the proximal region of the stem, and the timing of stem breakage were collected and analyzed.

Results: The stem size in patients with a broken stem was smaller ($p < 0.001$), and medial calcar defect was 12.4% and 100% ($p < 0.001$), respectively. The bone defect was greater in broken group ($p = 0.024$). The mean duration between revision surgery and stem breakage was 58.07 ± 36.98 months. Smaller stem size, greater bone defect, and inadequate medial calcar bone support were major risk factors for stem breakage.

Conclusions: Bypass fixation in the distal diaphysis with a long stem prosthesis without adequate bone support over medial calcar area may cause stress concentration in the long stem and a fatigue fracture. Use of a smaller prosthesis is the major risk of stem broken. It is essential to repair the proximal femoral bone deficiency and implant selection for better metaphyseal engagement to prevent further stem complications.

Level of evidence: Level III, case control study.

* Corresponding author. Department of Orthopedic Surgery, Chang Gung Memorial Hospital, Linkou. 5, Fusing St, Gueishan, Taoyuan 333, Taiwan.

E-mail address: aronc@adm.cgmh.org.tw (H.-N. Shih).

Peer review under responsibility of Chang Gung University.

¹ Chih-Hsiang Chang, Po-Chun Lin, and Cheng-Min Shih contributed equally to this article.

<https://doi.org/10.1016/j.bj.2018.02.001>

2319-4170/© 2018 Chang Gung University. Publishing services by Elsevier B.V. This is an open access article under the CC BY-NC-ND license (<http://creativecommons.org/licenses/by-nc-nd/4.0/>).

At a glance commentary

Scientific background on the subject

Bypass fixation over the diaphysis has achieved clinical success in cases of proximal femoral bone loss. Fracture of cementless, fully bead-coated femoral stem is an uncommon complication. The purpose of this study is to find out the possible risk factors.

What this study adds to the field

Fatigue fracture of diaphysis engaged long stem prosthesis may happen if there were inadequate medial calcar bone support or smaller stem size. Repairing the proximal femoral bone deficiency and choose better metaphyseal engagement could prevent this kind of stem complications.

Femoral bone loss during revision total hip arthroplasty (THA) poses a challenging problem. Bypass fixation over the diaphysis has achieved clinical success in cases of proximal femoral bone loss [1]. Extensively porous-coated femoral

stems allow adequate bone ingrowth in addition to having the advantage of achieving diaphyseal fixation. Satisfactory outcomes have been reported with the use of these revision long stems [2–7].

Fracture of the femoral stem over stem body was first reported in 1970 by Muller et al. [8]. Most of the reported stem fractures involved cemented prostheses and occurred probably because proximal cement loosening and a distally well-fixed stem allows for cantilever bending forces on the stem over subtrochanteric level [8–14]. Fracture of cementless, fully porous-coated femoral stems is a rare complication that causes catastrophic failure of a previously well-functioning prosthesis. Review of the literature revealed that 14 cases of femoral stem breakage at subtrochanteric level involving extensively porous-coated stems have been reported [15–18].

Multiple factors may result in stem fracture, and the etiological factors that have been studied include inadequate support for the implant in the proximal femur, increased patient weight, small-sized femoral stem, and nonunion of the osteotomy site [15–19]. However, firm conclusions regarding its etiology have not been drawn due to the small number of cases studied. We hypothesized that gender, BMI, implanted stem size, severity of femoral bone defect, and calcar support may contribute to breakage of long stem.

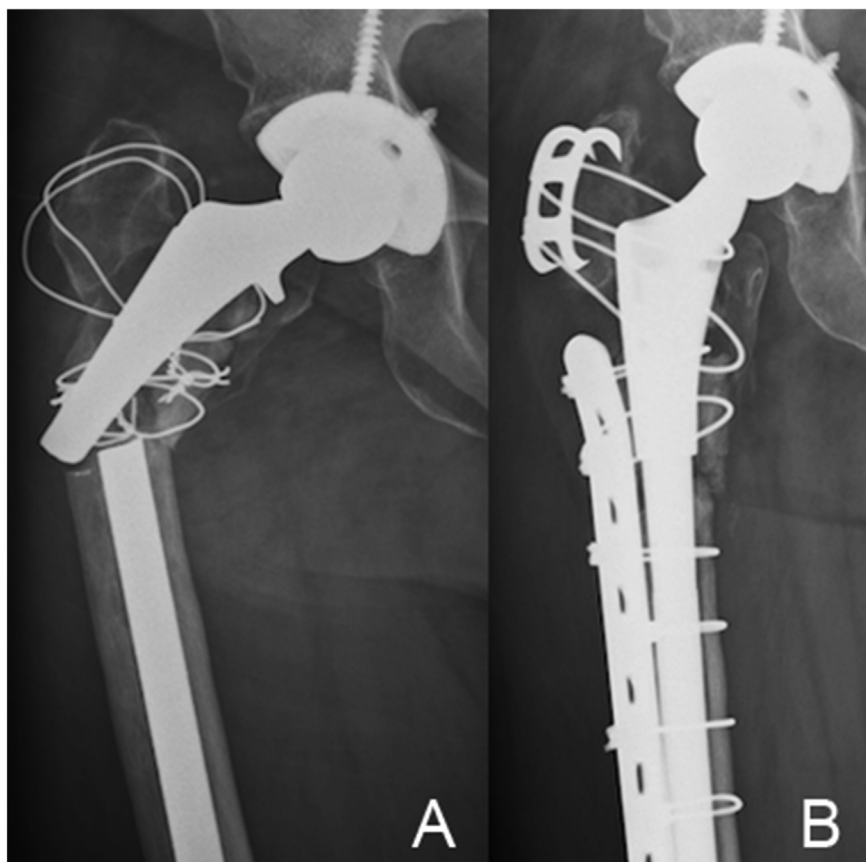


Fig. 1 (A) A 76-year-old woman who had previously undergone noncemented revision THA in 2010 due to insert wear with massive proximal femur osteolysis. The femoral component was revised with a 12-mm diameter long stem. 30 months after the revision, the patient presented with thigh pain of sudden onset that occurred during daily activity. (B) An anterior femoral cortical window was made to remove distal well-fixed prosthetic segment, and revision stem with ZMR (Zimmer, Warsaw, IN) was done. A cable plate and grip were used for fracture and osteotomy site fixation.

Table 1 Demographic data of patients.

	Nonbroken (N = 251)	Broken (N = 17)	268
Gender			
Male	159	8	167
Female	92	9	101
Revision diagnosis			
Aseptic loosening	123	10	
Femoral periprosthetic fracture	27		
Periprosthetic joint infection	69	1	
Polyethylene wear	11	6	
Instability	5		
Others	16		
Femoral bone defect			
II	169	7	176
IIIA	80	9	89
IIIB	2	1	3
Stem size			
11	8	9	17
12	39	7	46
13	51		51
14	58		58
15	56	1	57
16	21		21
17	18		18

The purposes of this study were 1. To analyze the cases that had revision stem fracture, 2. To compare the risk factors between patients with intact or broken revision long-stem. 3. To check the risk factors that previous studies had showed. 4. To analyze the differences between subgroups of patients with broken stems.

Material and methods

This was a retrospective comparative study. From 2006 to 2012, a total of 344 revision long stems were implanted, including primary revision or secondary revision. The revision long stem used in this study was cobalt chrome, fully-coat beaded femoral revision long stem (Zimmer, Warsaw, IN). In the same period, 17 broken stems that underwent treatment were included for analysis. Most of the patients with broken stem were receiving long stem implantation at outside hospital, and was referred to our hospital after stem broken (14/17). After obtaining approval from the institutional review board (No. 102-0019B), clinical records were retrieved from the electronic database. Age, sex, pattern of femoral bone loss, stem size, body mass index (BMI), indications for revision

surgery, prosthesis age, and medial calcar support in the proximal region of the stem after revision surgery were collected and analyzed. We excluded patients who were lost of follow up (72 hips), periprosthetic joint infection receiving two-stage exchange arthroplasty (16 hips), aseptic loosening receiving revision surgery (4 hips). In total, there were 251 hips in 241 patients with intact revision long stem (Zimmer, Warsaw, VerSys) and 17 hips in 17 patients with broken revision long stem (Zimmer, Warsaw, VerSys) were included for final analysis.

A comparison of these variables was carried out in patients with and without a fractured stem. Deficiency of the proximal femoral bone stock was graded according to the Paprosky classification [20]. The deficiency of proximal femoral bone was by two-view x-ray, including AP and lateral view. The loss of the medial calcar support was also by AP plain film. The broken stem group was further summarized according to the revision reason, duration from revision to stem broken, bone loss grade, re-revision stem type, and complications.

Student's t-test, analysis of variance, and chi-square test were used for data analysis among the non-fractured stem group and fractured stem group. A p-value of <0.05 was considered as statistically significant. All data was analyzed using SPSS (version 22.0, SPSS Inc, Chicago, IL, USA).

Results

Detailed patient characteristics were given in Table 1. There were no differences in most data between the two groups; however, the BMI and sex ratio were a little different between the groups but without statistically significant ($p = 0.272$, 0.607). The average stem size in the intact group was 14.01 (11–17) mm, and in the broken group was 11.61 (11–15) mm, with a statistical difference ($p < 0.001$). Bone loss had no statistical difference between the intact group and the broken group ($p = 0.795$). In all cases of the broken stem group, there was no medial calcar support in the proximal region of the stem, and it was 12.4% (31/251) in the intact stem group ($p < 0.001$). There were two main risk factors remained, the stem size ($p = 0.002$, Odds ratio: 54.96) and the medial calcar support ($p < 0.001$, Odds ratio: 164.89). Higher BMI and Paprosky score had higher risk of stem broken (odds ratio: 1.7; 1.25), but without statistical significance ($p = 0.272$; 0.795) (Table 2).

The mean time from implantation to stem breakage was 58.1 ± 37.0 months (95% confidence interval). In these patients with stem breakage, there were only two cases of extensive

Table 2 Comparison between patients with nonbroken and broken stem.

	Nonbroken (N = 251)	Broken (N = 17)	p (Chi-square)	Odds ratio
Age	60.83 ± 24.86	58.94 ± 29.22	0.55	1.035
Gender (M, F)	1.73:1 (159,92)	0.89:1 (8,9)	0.181	1.664
Stem size	14.01 (11–17)	11.61 (11, 12, 15)	<0.001*	54.962
Height	160.44 ± 17.4	159.19 ± 19.54	0.576	0.866
Weight	66.28 ± 26.43	71.43 ± 53.27	0.157	1.218
BMI	25.67 ± 8.70	27.63 ± 14.89	0.093	1.7
Paprosky	2.32	2.58	0.028*	1.25
No medial calcar support	31 (12.4%)	17 (100%)	<0.001*	164.891

Table 3 Details of patients with broken stem.

Stem broken (17)	
Revision reason	Impending loosening (7), Loosening (9), Infection (1)
Duration from revision to broken	58.1 ± 37.0 (month)
Bone loss (Paprosky)	2 (7), 3a (10)
Previous osteotomy	None(9), ETO (2), Transverse (6)
Re-Revision stem type	Same type stem (3), Longer stem (14)
Complications	Periprosthetic fracture over stem tip (2), using the same type stem

ETO: extensive trochanteric osteotomy.

trochanteric osteotomy (ETO), six cases of transverse osteotomy, and three cases of massive trochanteric bone loss regarding as transverse osteotomy. There were six cases with Paprosky type 2 bone loss, without previous osteotomy (either ETO or transverse). All the broken stems were removed with the use of an anterior cortical window or extended trochanter osteotomy, and reconstruction with a larger stem, with or without plate augmentation, were performed (Fig. 1). There were two cases using the same type revision stem, with loss of initial reduction and re-operation with single or double plate fixation (Fig. 2). All the patients were able to walk independently at the final follow-up (Table 3).

Discussion

For treating massive femoral bone loss during revision THA, cementless long stems were used for bypass fixation over the diaphysis with acceptable clinical success [1,20]. However, breakage of extensively porous-coated femoral stems was seen during regular follow-up. Previous studies focusing on stem fracture had found some risk factors, including inadequate implant support in the proximal femur, previous extensive

trochanteric osteotomy (ETO), high body weight, and a small-sized stem. However, the results were inconclusive due to the small number of cases studied [15–19]. To better understand the risk factors for stem fracture, we analyzed the cases that had experienced stem breakage and underwent surgical treatment at our hospital. We found that stem size ($p < 0.001$), bone defect (Paprosky, $p = 0.028$), and medial calcar support ($p < 0.001$) had significant difference between nonbroken and broken groups. Two risk factors revealed in previous papers were not seen including ETO and high body weight (BMI, $p = 0.093$).

Femoral stem fracture has been reported as a rare complication. The first study to report on femoral stem fractures was conducted in 1975 by Muller et al. [8]. However, most of these fractures were reported in cemented prostheses, probably because proximal loosening in a distally well-fixed stem allows for cantilever bending forces on the stem [8–14]. Fracture of cementless, fully porous-coated femoral stems is a rare complication that may cause catastrophic failure of a previously well-functioning prosthesis.

Extensive porous coating of revision femoral long stem provides a large surface area for bone ingrowth and good initial diaphyseal fixation. Previous clinical studies have reported satisfactory clinical outcomes with fully porous-coated long stems [2–7,21]. Even in the presence of massive trochanteric bone loss, cementless femoral stems used for revision demonstrated good clinical results at the 2–12 year follow-up in a previous study [22]. The reoperation rate for femoral stem loosening was 0% at the 10-year follow-up in a previous study [5]. Review of the literature revealed that 14 cases of femoral stem breakage involving extensively porous-coated stems have been reported. Soteracaeous et al. reported this in two Anatomic Medullary Locking stems used for revision in 122 hips (1.6%) (DePuy, Warsaw, IN) [15]. Busch et al. reported five stem fractures in a series of 219 revision procedures (2.3%), with two Solution (DePuy) and three Echelon (Smith & Nephew) stems [16]. Landa et al. reported three fractures of Echelon femoral stems in 175 hips (1.7%) [17].

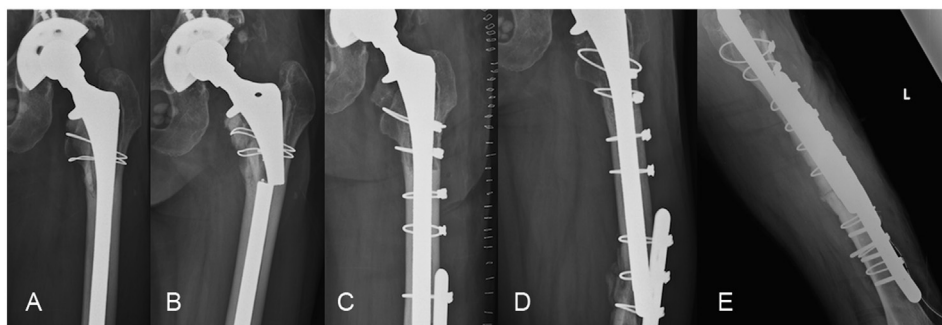


Fig. 2 (A) The patient was a 50-year-old woman who previously undergone second stage noncemented revision THA in 2002 due to periprosthetic joint infection status post first stage Girdlestone operation and antibiotic cement spacer implantation. There was minor bone loss in the trochanteric area. (B) After 121 months following the revision, the patient presented with thigh pain of sudden onset that occurred during daily activity. Radiographs revealed a stem that had fractured transversely at the subtrochanteric level. (C) An anterior femoral cortical window was made to remove the distal well-fixed prosthetic segment, and revision surgery using a larger Versys long-stem was performed. A cable plate and wire were used for fixation of the osteotomy site. (D) During F/U, periprosthetic fracture over stem tip was noticed 4 weeks later. (E) Open reduction and internal fixation was performed with double plate. The fracture healed 6 months later after 3 months protected weight bearing.

Recently, a high fracture rate of up to 9.8% was reported for VerSys fully-coated femoral stems (Zimmer, Warsaw, IN) [18]. Bone defect was not clearly defined in previous study. By analyzing the bone defect classification in our study, the classification category of bone loss in the broken stem group was 2.58, which was greater than that in the intact group (2.32), with statistical difference ($p < 0.001$).

The risk factors that contributed to stem breakage included the stem size. The stem size in the broken group was 11.61 (11–15) mm, which on average was smaller than that in the intact group, with a statistical difference ($p < 0.001$). Most of the broken stems in our study were 11 mm and 12 mm in size (94.1%, 16/17), which was in agreement with a previous study that reported that stems smaller than 13.5 mm are at a higher risk of stem breakage [16,18]. However, with inadequate medial calcar bone support, even a larger stem, 15 mm in size, may eventually break (126 months). The average patient age was similar in two groups, without statistically significant ($p = 0.55$). Compared to a previous study, younger age was not found to be a risk factor for stem breakage. BMI >30 was a risk factor for stem breakage, according to a previous study [16]. In Lu's study, half of the broken stems were in patients with BMI >30 (50%, 2/4) [18]. In our series, most of the patients had a BMI <30 (66.7%, 10/15, $27.6 \pm 7.6 \text{ Kg/m}^2$), and average of the BMI in the broken stem group was $27.63 \pm 14.89 \text{ (Kg/m}^2\text{)}$, which was slightly higher than that in the intact group ($25.67 \pm 8.70 \text{ Kg/m}^2$), without a statistical difference ($p = 0.093$).

For removing the previous well-fixed stem, ETO was performed or a cortical window was made. In a previous report, extensive trochanteric osteotomy was also considered to be a risk factor for stem breakage. Crowninshield et al. used finite element analysis to evaluate the difference in stress passing through the stems with varying degrees of proximal femoral bone loss, revealing that stress passing through stem was doubled in unhealed transverse femoral osteotomy [19]. In our opinion, the major reason for stem breakage was the inadequate medial calcar support, that the cantilever effects cause the femoral stem fracture. All cases with broken stems had no medial calcar support ($p < 0.001$). Without medial calcar support, the loading strength were bypass to distal well-fixed stem site, with cantilever effect just above the bony fixed stem, and eventually break at this level. The cases without medial calcar support over the stem in the intact stem group still required a close follow-up.

In stem broken group, two types of re-revision stem type were used, the same type stem with larger diameter (3) or longer stem (14) with larger diameter that bypass the osteotomy site (Table 3). There were two periprosthetic fractures over previous distal osteotomy site, with complication rate 66.6% using the same type stem (2/3). Open reduction and internal fixation with double plate were performed, and fracture united 6 months later with protected weight bearing for 3 months. In treating this kind of patients, longer revision stem to bypass osteotomy site that was used to remove broken stem was suggested to prevent possibility of further periprosthetic fracture.

The stem material that affects the stiffness could contribute to stress shielding and thigh pain [23,24]. The clinical and radiographic results of stems made from

Titanium and cobalt-chrome (Co-Cr) alloy but of the same shape did not show any significant differences; however, the femoral component made of Ti alloy retained greater peri-prosthetic bone as compared with the femoral component made of Co-Cr alloy [25]. Beaded porous coating was also known to weaken femoral prostheses [26]. In our series, all the broken stems were the Zimmer VerSys long stems, which were extensively bead-coated femoral stems made of Co-Cr. Theoretically, stability of the long stem implants was achieved with diaphyseal fixation, but with inadequate medial calcar support and stiffness of the stem with a high stress shielding effect, the stem eventually broke in the sub-trochanteric region.

However, there are some limitations to this study. First, most of the broken stem cases (14/17) were referred to our hospital, with the previous revision surgery performed elsewhere; it was therefore not possible to carry out a perfect case control study. Second, due to referring, the previous x-ray before revision surgery or stem breakage was not available, so the femoral bone defect was clarified by x-ray after breakage and intra-operative finding. The femoral bone defect may be over estimated. Third, because all of the broken stems in this study were from the same company (Zimmer, Warsaw, IN), we couldn't compare the design of stem that contributes to stem breakage. However, we enrolled the same revision stem for analysis to minimize the bias. As this is a rare surgically related complication in cementless femoral long stem, we used a limited database to address unanswered questions and identify the factors that would prevent occurrence of this complication in the future.

In conclusion, bypass fixation in the distal diaphysis with long stem prosthesis without adequate bone support around over medial calcar area, may cause stress concentration in the long stem and a fatigue fracture. Use of a smaller prosthesis is the major risk of stem broken. It is essential to reconstruct the proximal femoral bone deficiency and implant selection for better medial calcar engagement to prevent further stem complications.

Conflicts of interest

The authors have no conflicts of interest to declare.

Acknowledgments

The authors would like to thank Chang Gung Memorial Hospital Grant (CORPG3G0531) for financially supporting this research. The staff of the Research Services Center For Health Information, Chang Gung University, Taoyuan, Taiwan, are appreciated for their technical assistance for statistic analysis.

Appendix A. Supplementary data

Supplementary data related to this article can be found at <https://doi.org/10.1016/j.bj.2018.02.001>.

REFERENCES

- [1] Higuera CA, Capello W, Barsoum WK. Algorithmic approach for reconstruction of proximal femoral bone loss in revision total hip arthroplasty. *Orthopedics* 2009;32:674–8.
- [2] Paprosky WG, Greidanus NV, Antoniou J. Minimum 10-year results of extensively porous-coated stems in revision hip arthroplasty. *Clin Orthop Relat Res* 1999;369:230–42.
- [3] Sporer SM, Paprosky WG. Revision total hip arthroplasty: the limits of fully coated stems. *Clin Orthop Relat Res* 2003;417:203–9.
- [4] Moreland JR, Moreno MA. Cementless femoral revision arthroplasty of the hip: minimum 5 years followup. *Clin Orthop Relat Res* 2001;393:194–201.
- [5] Takenaga RK, Callaghan JJ, Bedard NA, Liu SS, Klaassen AL, Pedersen DR. Cementless total hip arthroplasty in patients fifty years of age or younger: a minimum ten-year follow-up. *J Bone Joint Surg Am* 2012;94:2153–9.
- [6] Engh Jr CA, Ellis TJ, Koralewicz LM, McAuley JP, Engh Sr CA. Extensively porous-coated femoral revision for severe femoral bone loss: minimum 10-year follow-up. *J Arthroplasty* 2002;17:955–60.
- [7] Hamilton WG, McAuley JP, Tabaraee E, Engh Sr CA. The outcome of rerevision of an extensively porous-coated stem with another extensively porous-coated stem. *J Arthroplasty* 2008;23:170–4.
- [8] Muller ME. Total hip prostheses. *Clin Orthop Relat Res* 1970;72:46–68.
- [9] Woolson ST, Milbauer JP, Bobyn JD, Yue S, Maloney WJ. Fatigue fracture of a forged cobalt-chromium-molybdenum femoral component inserted with cement. A report of ten cases. *J Bone Joint Surg Am* 1997;79:1842–8.
- [10] Jazrawi LM, Della Valle CJ, Kummer FJ, Adler EM, Di Cesare PE. Catastrophic failure of a cemented, collarless, polished, tapered cobalt-chromium femoral stem used with impaction bone-grafting. A report of two cases. *J Bone Joint Surg Am* 1999;81:844–7.
- [11] Charnley J. Fracture of femoral prostheses in total hip replacement. A clinical study. *Clin Orthop Relat Res* 1975;111:105–20.
- [12] Chao EY, Coventry MB. Fracture of the femoral component after total hip replacement. An analysis of fifty-eight cases. *J Bone Joint Surg Am* 1981;63:1078–94.
- [13] Andriacchi TP, Galante JO, Belytschko TB, Hampton S. A stress analysis of the femoral stem in total hip prostheses. *J Bone Joint Surg Am* 1976;58:618–24.
- [14] Galante JO, Rostoker W, Doyle JM. Failed femoral stems in total hip prostheses. A report of six cases. *J Bone Joint Surg Am* 1975;57:230–6.
- [15] Sotereanos NG, Engh CA, Glassman AH, Macalino GE, Engh Jr CA. Cementless femoral components should be made from cobalt chrome. *Clin Orthop Relat Res* 1995;313:146–53.
- [16] Busch CA, Charles MN, Haydon CM, Bourne RB, Rorabeck CH, Macdonald SJ, et al. Fractures of distally-fixed femoral stems after revision arthroplasty. *J Bone Joint Surg Br* 2005;87:1333–6.
- [17] Landa J, Benke M, Dayan A, Pereira G, Di Cesare PE. Fracture of fully coated echelon femoral stems in revision total hip arthroplasty. *J Arthroplasty* 2009;24:322e13–e18.
- [18] Lu HC, Lin CL, Chang CW, Lai KA. Fracture of VerSys fully bead-coated long femoral stems: report on four fractures in 41 hips. *Kaohsiung J Med Sci* 2012;28:345–9.
- [19] Crowninshield RD, Maloney WJ, Wentz DH, Levine DL. The role of proximal femoral support in stress development within hip prostheses. *Clin Orthop Relat Res* 2004;420:176–80.
- [20] Valle CJ, Paprosky WG. Classification and an algorithmic approach to the reconstruction of femoral deficiency in revision total hip arthroplasty. *J Bone Joint Surg Am* 2003;85-A(Suppl. 4):1–6.
- [21] Moreland JR, Marder R, Anspach Jr WE. The window technique for the removal of broken femoral stems in total hip replacement. *Clin Orthop Relat Res* 1986;212:245–9.
- [22] Nadaud MC, Griffin WL, Fehring TK, Mason JB, Tabor Jr OB, Odum S, et al. Cementless revision total hip arthroplasty without allograft in severe proximal femoral defects. *J Arthroplasty* 2005;20:738–44.
- [23] Healy WL, Tilzey JF, Iorio R, Specht LM, Sharma S. Prospective, randomized comparison of cobalt-chrome and titanium trilock femoral stems. *J Arthroplasty* 2009;24:831–6.
- [24] Engh CA. Mechanical consequences of bone ingrowth in a hip prosthesis inserted without cement. *J Bone Joint Surg Am* 1996;78:312–3.
- [25] Kim YH. Titanium and cobalt-chrome cementless femoral stems of identical shape produce equal results. *Clin Orthop Relat Res* 2004;427:148–56.
- [26] Ong A, Wong KL, Lai M, Garino JP, Steinberg ME. Early failure of precoated femoral components in primary total hip arthroplasty. *J Bone Joint Surg Am* 2002;84-A:786–92.