

## Case Report

# Acute renal failure, systemic lupus erythematosus and thrombotic microangiopathy following treatment with beta-interferon for multiple sclerosis: case report and review of the literature

Thomas Hansen<sup>1</sup>, David New<sup>1</sup>, Roy Reeve<sup>2</sup>, Rosemary Donne<sup>1</sup> and William Stephens<sup>3</sup>

<sup>1</sup>Renal Unit, <sup>2</sup>Department of Pathology, Salford Royal NHS Foundation Trust, Salford, Greater Manchester and <sup>3</sup>Department of Internal Medicine, Trafford Healthcare NHS Trust, UK

Correspondence and offprint requests to: Thomas Hansen; E-mail: thomas.hansen@student.manchester.ac.uk

## Abstract

We report a man with type 1 diabetes mellitus, autoimmune hypothyroidism and a tentative diagnosis of multiple sclerosis. Following treatment with beta interferon, he developed systemic lupus erythematosus with pericarditis, pleural effusions, cerebral infarction associated with anti-phospholipid antibody and acute renal failure due to thrombotic microangiopathy. He responded well to immunosuppression and anticoagulation. These complications may represent the most severe autoimmune reaction to beta interferon reported to date.

**Keywords:** acute renal failure; anti-phospholipid syndrome; beta-interferon; multiple sclerosis; systemic lupus erythematosus

## Introduction

Beta-interferon (IFN- $\beta$ ) is an immune-modulating agent that has proved useful in the treatment of conditions such as multiple sclerosis (MS). It is known to be a cause of autoimmune phenomena such as thyrotoxicosis and lupus syndromes. The possible mechanism for IFN- $\beta$  causing autoimmune disease includes modulation of the activities of dendritic cells and T cells. This case report details a severe set of autoimmune phenomena that developed in a young man already suffering from autoimmune diabetes mellitus, hypothyroidism and possibly also MS. A florid systemic lupus erythematosus, comprising pericarditis, pleurisy, cerebral infarctions in association with anti-phospholipid antibody syndrome, and acute renal failure due to thrombotic microangiopathy were observed.

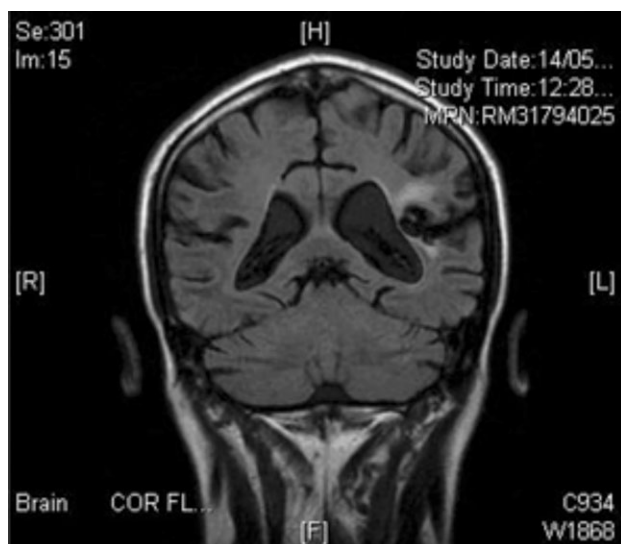
## Case history

A 41-year-old information technology consultant presented in 2005 with a pericardial rub and bilateral pleural effusions.

He had been diagnosed with type 1 diabetes in 1998. From 1999, recurrent neurological events which varied in position and time began. Initially, there were sensory symptoms in the right leg although at that time clinical examination and visual evoked responses were normal. He later developed optic neuritis, left-sided sensory loss and upper motor neurone signs. MR scan was normal, but visual evoked potentials were reduced in the left eye. During a subsequent episode, there was spasticity of both legs, bladder disturbance and a lower thoracic sensory level. MR scan of the brain showed left pericallosal hyperintensity, and intrinsic high signal at thoracic levels 5–6 and 9–10 was suggestive of demyelination. These events prompted a diagnosis of MS. Treatment with corticosteroids and IFN- $\beta$  (Rebif 22 mcg three times a week) was commenced, but several months later a further relapse occurred with right optic neuritis that prompted re-introduction of corticosteroids and IFN- $\beta$  (increased to 44 mcg three times a week). At this time, blood tests showed normal kidney function. In 2004, he developed right-sided deafness, unsteadiness of gait and expressive dysphasia. Examination revealed bilateral optic atrophy, horizontal nystagmus and upper motor neuron signs in both legs. A further course of corticosteroids was administered.

Admission in 2005 was prompted by pain between the shoulder blades. A pericardial rub was present, and there were bilateral pleural effusions. Laboratory investigations showed haemoglobin 7.8 g/dL, creatinine 117 mmol/L and raised C-reactive protein at 138 mg/L. Chest x-ray demonstrated cardiomegaly, and CT thorax showed a pericardial effusion and thickened pericardium. Antinuclear antibodies were positive ( $>1:1600$ ), as were anti-double-stranded DNA antibodies (172 U/mL, normal  $<7.0$  U/mL). IgG anti-phospholipid antibodies were positive (40 GPLU/mL, normal  $<15$  GPLU/mL). ANCA fluorescence was obscured by the presence of antinuclear factor, although MPO and PR3 antibodies were negative.

IFN- $\beta$  was discontinued, and he was treated with pulsed methylprednisolone and diclofenac for pericardial pain. He

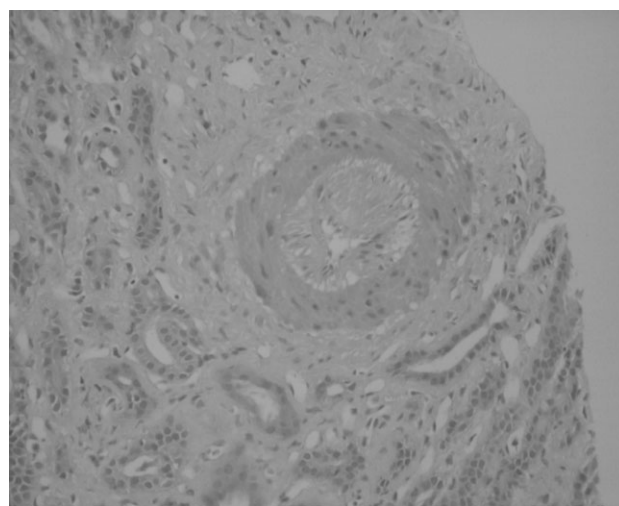


**Fig. 1.** Magnetic resonance scan showing focal areas of infarction in the left parietal region and right occipital lobe peripherally. There is no evidence to suggest multiple sclerosis.

subsequently developed acute kidney injury; serum creatinine increased to 240  $\mu\text{mol/L}$  and there was presence of blood and protein on urinalysis. The platelet count was  $60 \times 10^9/\text{L}$ , and red cell fragments were observed. There was normal prothrombin time but prolonged activated partial thromboplastin time (APPT). Seizures occurred. MR imaging of the brain showed patchy widespread signal change, an old infarct in the left temporal-parietal area, and other areas of signal change within the cerebellum and brain stem. There were few features to suggest demyelination although appearances were consistent with small infarcts (Figure 1). CSF analysis was normal and was negative for oligoclonal bands. He was treated with pulsed IV cyclophosphamide and prednisolone 60 mg/day. A renal biopsy, performed after recovery of platelet count, showed florid thrombotic microangiopathy, with almost complete occlusion of some small arteries due to myxoid intimal thickening. Glomeruli showed ischaemic changes (Figure 2). He received seven plasma exchanges over 2 weeks and was anti-coagulated with warfarin. Three intravenous boluses of cyclophosphamide were administered prior to conversion to mycophenolate. The prednisolone dose has been reduced gradually. His condition has remained stable with no new neurological phenomena. Anti-phospholipid antibodies disappeared and have remained negative. Kidney function has substantially recovered with current eGFR 64 mL/min.

## Discussion

MS, systemic lupus erythematosus (SLE) and anti-phospholipid syndrome (APS) can look identical on MR scan and clinical presentation [1]. It is possible that the neurological features were due to cerebral lupus with APS; however, there is no record of autoimmune screening or CSF tests prior to 2005. Multifocal white matter lesions are relatively frequent in APS patients, and myelopathy



**Fig. 2.** Renal biopsy. The arteries showed almost complete occlusion by fibrointimal thickening consistent with a microangiopathy.

(0.4%) and optic neuropathy (1%) were reported in the Euro-Phospholipid Project cohort of 1000 European APS patients (primary and secondary) [1]. Alternatively, the patient may have suffered from primary APS (PAPS) and developed lupus later. There have been 20 cases reported of PAPS developing into SLE to date, although none of these involved interferon therapy [1]. There is much evidence for IFN- $\beta$  therapy causing lupus syndromes with some or all of the features of SLE. In this case, it is possible that IFN- $\beta$  therapy triggered full clinical SLE.

IFNs are glycoprotein cytokines involved in the immune response to viruses, tumours and parasites, and they may be linked to the pathogenesis of SLE. IFN- $\beta$  therapy has been associated with the development of autoimmune diseases. It is used to treat MS and myeloma. There are only few reported cases of SLE linked to IFN- $\beta$  therapy [2,3]. There are two previous reports of IFN- $\beta$  causing thrombotic microangiopathy. The first reports haemolytic uraemic syndrome that improved after discontinuation of the IFN- $\beta$  therapy [4]. The second details two MS patients developing a syndrome similar to thrombotic thrombocytopenic purpura following IFN- $\beta$  therapy [5]. One of these patients was a 44-year-old woman with a long history of MS who, during IFN- $\beta$  treatment, developed fever, thrombocytopenia, delirium and proteinuria; the kidney biopsy showed thrombotic microangiopathy although plasmapheresis therapy did not improve kidney function [5]. The other patient with optic neuritis and brain MR scan features of MS developed fever, rash and renal failure during IFN- $\beta$  therapy, which recovered completely following plasma exchange and steroid treatment [5].

In conclusion, we report a young man who, whilst being treated for presumed MS with IFN- $\beta$ , developed SLE, positive anti-phospholipid antibodies and acute renal failure due to thrombotic microangiopathy. It is difficult to speculate as to his original disease, whether it was MS or SLE/APS mimicking MS. Nevertheless, IFN- $\beta$  therapy was followed by the development of florid SLE with thrombotic microangiopathy. This patient may represent the most severe autoimmune reaction to IFN- $\beta$  to date. This case highlights

the need for careful assessment to rule out autoimmune disease when patients present with symptoms suggestive of MS and vigilance during treatment with IFN- $\beta$ .

*Conflict of interest statement.* None declared.

## References

1. Ferreira S, D'Cruz DP, Hughes GR. Multiple sclerosis, neuropsychiatric lupus and antiphospholipid syndrome; where do we stand? *Rheumatology (Oxford)* 2005; 44: 434–442
2. Borg FA, Isenberg DA. Syndromes and complications of interferon therapy. *Curr Opin Rheumatol* 2007; 19: 61–66
3. Crispin JC, Diaz-Jouanen E. Systemic lupus erythematosus induced by therapy with interferon- $\beta$  in a patient with multiple sclerosis. *Lupus* 2005; 14: 495–496
4. Ubara Y, Hara S, Takedatu H *et al.* Hemolytic uremic syndrome associated with beta-interferon therapy for chronic hepatitis C. *Nephron* 1998; 80: 107–108
5. Herrera WG, Balizet LB, Harberts SW *et al.* Occurrence of a TTP-like syndrome in two women receiving beta interferon therapy for relapsing multiple sclerosis. *Neurology* 1999; 52(Suppl. 2) A135

*Received for publication: 22.7.09; Accepted in revised form: 27.7.09*